

Unusual Presentation of PMM2-Congenital Disorder of Glycosylation With Isolated Strokelike Episodes in a Young Girl

Journal of Child Neurology
1-5
© The Author(s) 2019
Article reuse guidelines:
sagepub.com/journals-permissions
DOI: 10.1177/0883073819833543
journals.sagepub.com/home/jcn



Rajni Farmania, MD, DM¹, Puneet Jain, MD, DM^{1,2},
Suvasini Sharma, MD, DM³, and Satinder Aneja, MD^{3,4}

Abstract

Congenital disorders of glycosylation (CDG) are multisystemic inherited metabolic disorders with marked phenotypic variability. The most frequent described type is PMM2-CDG (earlier known as CDG Type Ia) which presents either with pure neurologic features or with combined neurologic and systemic features. The classical presentation is characterized by varied combinations of developmental delay, hypotonia, ataxia, dysmorphism, inverted nipples, and abnormal fat distribution. Strokelike episodes and seizures are known acute complications that usually occur on a background of developmental delay, ataxia, or dysmorphism. We report here a developmentally normal young girl who presented with isolated strokelike episodes and was diagnosed to have CDG Type Ia. This condition should be kept in the differentials of unexplained strokelike episodes in children. The diagnosis has important therapeutic and prognostic implications.

Keywords

PMM2, stroke, TIA, stroke, CDG

Received January 14, 2019. Received revised January 24, 2019. Accepted for publication February 2, 2019.

Congenital disorders of glycosylation (CDG) are a group of genetic disorders that affect protein and lipid glycosylation and glycosylphosphatidylinositol synthesis. PMM2-CDG (earlier known as CDG-Ia), caused by mutations in the PMM2 (Phosphomannomutase 2) gene, is the most frequent and best described form. It is caused by decreased activity of the enzyme phosphomannomutase 2.¹ The phenotype is heterogeneous, consisting of variable combinations of dysmorphism, developmental delay, abnormal subcutaneous fat distribution, liver involvement, coagulopathy, ataxia, axial hypotonia, and seizures.^{2,3} Strokelike episodes have been reported in 40% to 55% of children with CDG type Ia; however, these commonly occur on a background of developmental delay, ataxia, or dysmorphism.⁴ We report here a developmentally normal young girl who presented with isolated strokelike episodes and was diagnosed to have PMM2-CDG.

Case Report

A 6-year-old developmentally normal girl presented with sudden-onset weakness of right upper limb after falling from a chair. She was also noted to be lethargic and had 2 episodes of vomiting. There was no history of seizures, squint, facial asymmetry, or nasal regurgitation of food. There was no preceding history of fever, rash, cough, cold, or headache.

She was the second child of nonconsanguineous parents. The antenatal and perinatal history were uneventful. Her developmental milestones were age appropriate and she had good scholastic performance. Her 10-year-old elder sister was normal. Her mother had a history of a previous term still birth, and a second trimester termination of pregnancy for fetal abdominal wall defect. Her paternal aunt had a history of migraine.

On examination, she was afebrile and confused, responding to verbal commands with poor orientation to time, place, and person. She had stable vitals; weighed 18 kg (Z score 0.78), had a height of

¹ Division of Pediatric Neurology, Department of Pediatrics, BL Kapur (BLK) Super Speciality Hospital, Pusa Road, New Delhi, India

² Division of Neurology, Department of Pediatrics, The Hospital for Sick Children, Toronto, Ontario, Canada

³ Neurology Division, Department of Pediatrics, Lady Hardinge Medical College (LHMC) and associated Kalawati Saran Children Hospital, New Delhi, India

⁴ Department of Pediatrics, School of Medical Sciences & Research, Sharda University, Greater Noida, UP, India

Corresponding Author:

Suvasini Sharma, MD, DM, Division of Pediatric Neurology, Lady Hardinge Medical College and associated Kalawati Saran Children's Hospital, New Delhi 110001, India.

Email: sharma.suvasini@gmail.com

Table 1. Serial Clinical and Laboratory Investigations of the Reported Case.

	First episode	Second episode	Third episode
Age	6 y 2 mo	7 y 4 mo	9 y 2 mo
Clinical features	<ul style="list-style-type: none"> – Vomiting – Right upper limb monoparesis – Encephalopathy 	<ul style="list-style-type: none"> – Vomiting – Right hemiparesis with CN VII and VI N palsy – Encephalopathy 	<ul style="list-style-type: none"> – Vomiting – Right upper limb paresis with CN VII N palsy
Duration	4 d	2 d	3 d
Precipitating event	Trivial trauma (fall from chair)	Trivial trauma (fall while play)	None
Differential diagnoses considered	<ul style="list-style-type: none"> – Diffuse axonal injury – Cerebrovenous sinus thrombosis – Urea cycle defect 	<ul style="list-style-type: none"> – Familial hemiplegic migraine – Alternating hemiplegia of childhood – Acute intermittent porphyria – Mitochondrial disorder – Organic acidurias 	Diagnosis was already confirmed
Investigations			
CBC:			
Hemoglobin (g/dL)	11.5	11.3	12.3
TLC (per uL)	15 300	14 400	15 180
Platelet (lacs/uL)	6.28	4.59	5.39
Liver enzymes			
AST (U/L) [Normal: 0-32]	31	33	39
ALT (U/L) [Normal 10-35]	34	31	58
Coagulation profile (PT, aPTT)	Normal range	Normal range	Normal range
Blood ammonia	46 (18-102 ug/dL)	43	98
Arterial lactate	Normal	Normal	Normal
MR parenchymal and vascular (arterial and venous) imaging	Normal	Normal	Normal
EEG	Diffuse slowing	Diffuse slowing	Asymmetric background; left hemisphere more attenuated
Others:			
CSF study	Acellular, protein and sugar normal	–	–
Lipid profile	Normal	–	–
2D- Echocardiography	Normal	–	–
Homocysteine	–	10.5 (4-11 umol/l)	–
Serum Vitamin B12	–	199 (180-914 pg/ml)	–
Serum Folate	–	8.51 (5.9-24.8 ng/ml)	–
Serum ferritin	–	15.5 (11-307ng/ml)	–
Urine porphobilinogen	–	Normal	–
Abdominal ultrasonography	–	–	Fatty liver grade I
<u>Procoagulant workup</u>			
Protein C	–	64% (88%-120%)	61% (70%-140%)
Antithrombin III	–	40% (86%-116%)	53% (80%-120%)
Protein S	–	Normal	normal
Lupus anticoagulant, APLA IgM, IgG anticardiolipin antibody	–	Negative	Negative
Factor V Leiden, MTHFR mutation	–	–	–
Prothrombin G20210A mutation	–	–	–
TMS dried blood	–	Normal	–
Urine GCMS	–	No organic aciduria	–
Clinical exome sequencing	–	Likely pathogenic homozygous mutation at exon 4 of PMM2 gene, c.310C>G (p.Leu104Val)	–

(continued)

Table 1. (continued)

	First episode	Second episode	Third episode
Transferrin isoelectric focusing		Elevated asialotransferrin and disialotransferrin with low tetrasialotransferrin	
Treatment	Supportive	Supportive Aspirin was added after confirming diagnosis for secondary prophylaxis	Supportive

Abbreviations: ALT, alanine aminotransferase; APLA, antiphospholipid antibody; APTT, activated partial thromboplastin time; AST, aspartate aminotransferase; CBC, complete blood count; CN, cranial nerve; CSF, cerebrospinal fluid; EEG, electroencephalography; GCMS, gas chromatography mass spectroscopy; MR, magnetic resonance; MTHFR, methylene-tetrahydrofolate reductase; PT, prothrombin time; TLC, total leukocyte count; TMS, tandem mass spectroscopy.

106 cm (Z score -1.78), with a body mass index Z score of 0.46 per World Health Organization (WHO) Growth charts.⁵ There was no facial dysmorphism. The general physical and systemic examination was unremarkable. The cranial nerve examination including optic fundi examination was normal. Motor examination revealed reduced tone and power and absent muscle-stretch-reflexes in the right upper limb. The other 3 limbs were normal. The plantar responses were flexor bilaterally. The sensory system was normal on examination and there were no meningeal signs.

Investigations revealed normal hemogram, serum electrolytes, and liver and kidney function tests. The coagulation profile and the serum homocysteine levels were normal. The contrast-enhanced magnetic resonance imaging (MRI) of the brain (including diffusion-weighted images), magnetic resonance angiography, and venography were normal (Table 1). The electroencephalography (EEG), done on the second day of onset of symptoms, showed diffuse symmetric background slowing with no evidence of nonconvulsive status epilepticus. Cerebrospinal fluid examination showed unremarkable cytology, normal protein/sugar, and negative bacterial culture. The polymerase chain reaction test for herpes simplex virus was negative. Other tests (erythrocyte sedimentation rate, antinuclear antibody, arterial lactate, and blood ammonia) were also unremarkable. She improved completely without any focal deficit with conservative management over the next 2 days.

She was well for another 14 months when she had a similar episode of acute right-sided hemiparesis noted after a trivial fall. This time too, she improved completely with conservative management over the next 2 days. The routine investigations and the MRI brain were again normal (Table 1). In view of recurrent strokelike episodes, a metabolic disorder was suspected. The blood amino acid and acylcarnitine profile, and urinary organic acid analysis were normal. Procoagulant workup revealed low protein C and antithrombin III levels in the acute stage.

In view of unexplained etiology of recurrent strokelike episodes, clinical exome sequencing was done. This revealed a de novo likely pathogenic homozygous mutation at exon 4 of PMM2 gene [variant c.310C>G (p.Leu104Val)] suggestive of congenital disorder of glycosylation type 1a. The mutation was subsequently confirmed by Sanger sequencing. Subsequent transferrin isoelectric focusing showed elevated levels of

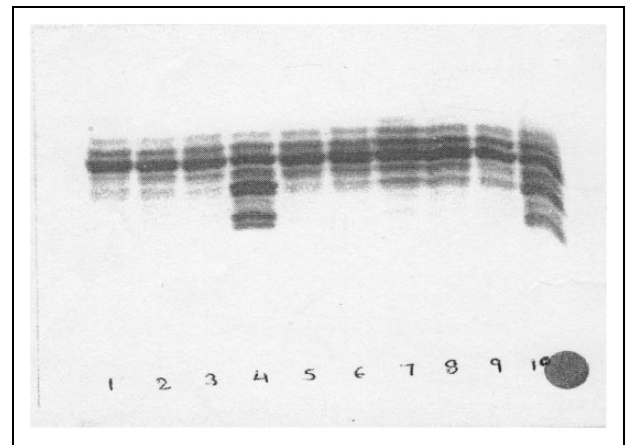


Figure 1. Isoelectric focusing (IEF) analysis for the reported patient. Lane 4 shows the isoforms for the patient. Lane 10 represents the positive control, and lanes 1 to 3 and 5 to 9 represent the negative controls. The results indicated elevated levels of asialotransferrin (observed, 20.95%; normal range, 0.19% to 5.68%) and disialotransferrin (observed 25.96%; normal range 8.02% to 17.94%) with low tetrasialotransferrin (observed 19.07%; normal range 28.78% to 45.70%) levels suggestive of congenital disorders of glycosylation type I.

asialotransferrin and disialotransferrin with low tetrasialotransferrin (Figure 1), supporting the diagnosis.

She was started on low-dose aspirin after the diagnosis was made. However, she suffered from a third similar episode 22 months after the second episode, which too improved over 3 days with conservative management. EEG (second day of illness) revealed asymmetric background with relative attenuation over the left hemisphere (Figure 2). The evaluation during the last episode revealed mild transaminitis (alanine aminotransferase [ALT] 58 IU/L [normal range: 10-35 IU/L]) and fatty liver on ultrasonography. Repeat procoagulant workup again showed low protein C and antithrombin III levels in the acute stage, and this continued to be low when the testing was repeated after 3 months. ALT also continued to be high (98 IU/L) on follow-up.

Discussion

Congenital disorders of glycosylation are multisystemic inherited metabolic disorders with marked phenotypic variability

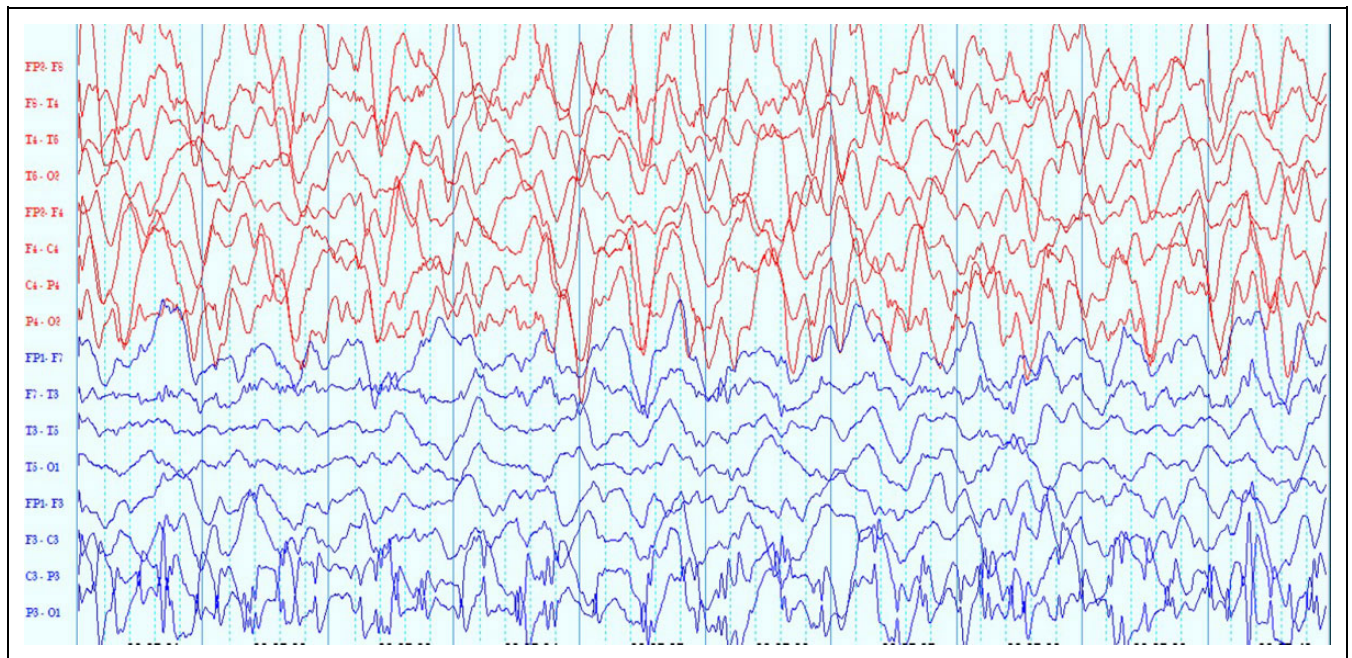


Figure 2. Electroencephalography (EEG) of the patient done on day 2 of right-sided weakness in the third episode. This EEG epoch shows diffuse 1.5- to 2-Hz delta activity (with superimposed theta frequencies). This activity was relatively attenuated over the left hemisphere. Note the electrode artefacts at P3 (bipolar longitudinal montage; low-frequency filter 1 Hz, high-frequency filter 70 Hz, sensitivity 7.5 $\mu\text{V/mm}$, time base 30 mm/s).

from very severe to mild disease. Three different patterns of neurologic presentation are (1) chronic static with neurodevelopmental delay, hypotonia, strabismus, and features of cerebellar dysfunction; (2) acute presentation with strokelike episodes and epilepsy, and (3) chronic progressive: microcephaly, retinopathy, and polyneuropathy.⁴ Nonneurologic findings include dysmorphism, failure to thrive, abnormal distribution of subcutaneous fat pads, feeding difficulties, cardiac features (pericarditis, cardiac malformation), gastrointestinal involvement (chronic diarrhea, liver failure), skeletal (kyphoscoliosis, osteopenia), kidney involvement (nephrotic syndrome, proximal tubulopathy), and coagulopathy.⁶ Milder phenotypes with just behavioral symptoms and failure to thrive are often underdiagnosed.^{7,8}

Strokelike episodes are clinically acute and transient neurologic deficits associated with altered mental state and sometimes with seizures. These episodes are reported in 40% to 55% cases of PMM2-CDG, presenting usually after 4 to 5 years of age in children with premorbid neurodevelopmental delay and ataxia.^{4,6} The duration of each episode varies from hours to months and are commonly precipitated by fever and injury. The neuroimaging findings are variable, even in different episodes in the same patient. MRI can be completely normal or may exhibit focal nonterritorial area of restricted diffusion or rarely an ischemic process with territorial infarct.⁹ Our patient presented at the age of 6 years and had a total of 3 such episodes in a span of 4 years. The precipitating event was trivial trauma in 2 of the episodes, neuroimaging finding were normal in each episode, and all the episodes resolved spontaneously over 3 to 4 days.

Differential diagnoses considered for isolated strokelike episodes in normally developing children include alternating hemiplegia of childhood, familial hemiplegic migraine, inherited metabolic disorders like urea cycle defects, mitochondrial disorders, homocystinuria and organic acidurias.^{10,11} Our patient was worked up for possibilities like post-trauma diffuse axonal injury, venous sinus thrombosis, and metabolic disorders. In the absence of any other clinical pointers, CDG was not suspected. However, clinical exome sequencing revealed PMM2-CDG, and the diagnosis was supported by subsequent biochemical testing of isoelectric transferrin focusing. The mutation has previously been reported as one of the compound heterozygous variants in a patient with mixed Asian ancestry.¹² However, in follow-up, she has developed liver involvement as evident by transaminitis and fatty liver on ultrasonography.

The pathophysiological mechanisms of strokelike episodes in CDG are not well understood.¹³ Three different mechanisms are hypothesized. First, they could occur via an ischemic phenomenon secondary to deficiency of anticoagulant proteins (protein C, protein S, and antithrombin III) along with platelet hyperaggregability especially during periods of catabolic stress.¹⁴ The second proposed mechanism is postictal Todd paresis, because around 75% of such events are accompanied by seizures and some are known to improve after antiepileptic drugs.⁶ The third and most recent suggested mechanism is attributed to the presence of abnormal calcium channel function due to aberrant N-glycosylation in these patients.¹⁵

In our patient, the mechanism of strokelike episodes is not clear. Although she has evidence of hypercoagulable state with

low protein C and antithrombin III levels, there has never been evidence of ischemic injury on MRI in any of the episodes. Her platelet and total leucocyte counts were raised during all the episodes. There is no evidence that these abnormal parameters are additional markers of CDG; hence, this could perhaps be due to stress response following strokelike events. There was no history of seizures or epileptic activity on EEG. Prevention of these episodes by low-dose aspirin is controversial since these cases have tendency both to bleed and also have thrombosis. Also, another reason for its limited role is because many patients have associated hepatic involvement, which may get further aggravated.¹⁶ Hence, an individualized approach is advisable. Our child had started developing hepatic involvement; hence, aspirin was stopped after the third episode.

In conclusion, we describe a young girl with an unusual presentation of PMM2-CDG, with isolated strokelike episodes. This condition should be kept in the differential diagnoses of unexplained strokelike episodes in children. The diagnosis has important therapeutic and prognostic implications.

Authors' Note

Puneet Jain is also affiliated with Division of Neurology, Department of Pediatrics, The Hospital for Sick Children, Toronto, Ontario, Canada. Suvasini Sharma is now affiliated with Neurology Division, Department of Pediatrics, Lady Hardinge Medical College (LHMC) and associated Kalawati Saran Children Hospital, New Delhi, India. Satinder Aneja is also affiliated with Department of Pediatrics, School of Medical Sciences & Research, Sharda University, Greater Noida, Uttar Pradesh, India.

Author Contributions

RF, PJ, SS, and SA provided clinical care to the patient. RF wrote the first draft of the manuscript, which was then read and approved by all the authors.

Declaration of Conflicting Interests

The author(s) declared no potential conflicts of interest with respect to the research, authorship, and/or publication of this article.

Funding

The author(s) received no financial support for the research, authorship, and/or publication of this article.

Ethical Approval

The IRB approval number is EC/AARCE/APPROVALLETTER/FEBRUARY/2019/32. Written informed consent was obtained from the parents for publication of this case report as per hospital guidelines.

References

- Sparks SE, Krasnewich DM. Congenital disorders of N-linked glycosylation and multiple pathway overview. 2005 Aug 15 [Updated 2017 Jan 12]. In: Adam MP, Ardinger HH, Pagon RA, et al, eds. GeneReviews® [Internet]. Seattle, WA: University of Washington Press; 1993-2018.
- Jaeken J, Matthijs G. Congenital disorders of glycosylation: a rapidly expanding disease family. *Annu Rev Genomics Hum Genet.* 2007;8:261-278.
- Grünwald S. The clinical spectrum of phosphomannomutase 2 deficiency (CDG-1A). *Biochim Biophys Acta.* 2009;1792:827-834.
- Miossec-Chauvet E, Mikaeloff Y, Heron D, et al. Neurological presentation in pediatric patients with congenital disorders of glycosylation type Ia. *Neuropediatrics* 2003;34:1-6.
- WHO growth reference 2007. <http://www.who.int/growthref/en/>. Accessed January 14, 2019.
- Schiff M, Roda C, Monin ML, et al. Clinical, laboratory and molecular findings and long-term follow-up data in 96 French patients with PMM2-CDG (phosphomannomutase 2-congenital disorder of glycosylation) and review of the literature. *J Med Genet.* 2017;54:843-851.
- Giurgea I, Michel A, le Merrer M, Seta N, de Ionlay P. Underdiagnosis of mild congenital disorders of glycosylation type Ia. *Pediatr Neurol.* 2005;32:121-123.
- Pancho C, Garcia-cazorla A, Varea V, et al. Congenital disorder of glycosylation type Ia revealed by hypertransaminasemia and failure to thrive in a young boy with normal neurodevelopment. *J Pediatr Gastroenterol Nutr.* 2005;40:230-232.
- Ishikawa N, Tajima G, Ono H, Kobayashi M. Different neuroradiological findings during two stroke-like episodes in a patient with a congenital disorder of glycosylation type Ia. *Brain Dev.* 2009;31:240-243.
- Freeze HH, Ng BG, Patterson MC. Disorders of glycosylation. In: Swaiman KF, Ashwal S, Ferriero DM, et al, eds. *Pediatric Neurology, Principles and Practice.* 6th ed. Philadelphia, PA: Elsevier; 2018:e759-e779.
- Testai FD, Gorelick PB. Inherited metabolic disorders and stroke part 1: Fabry disease and mitochondrial myopathy, encephalopathy, lactic acidosis, and strokelike episodes. *Arch Neurol.* 2010; 67:19-24.
- Westphal V, Enns GM, McCracken MF, Freeze HH. Functional analysis of novel mutations in a congenital disorder of glycosylation Ia patient with mixed Asian ancestry. *Mol Genet Metab* 2001; 73:71-76.
- Dinopoulos A, Mohamed I, Jones B, Rao S, Franz D, Degrauw T. Radiologic and neurophysiologic aspects of stroke-like episodes in children with congenital disorder of glycosylation type Ia. *Pediatrics.* 2007;119:e768-e772.
- Van Geet C, Jaeken J, Freson K, et al. Congenital disorders of glycosylation type Ia and IIa are associated with different primary haemostatic complications. *J Inherit Metab Dis.* 2001; 24: 477-492.
- Serra MI, Martínez-Monseny AF, López L, et al. Stroke-like episodes and cerebellar syndrome in phosphomannomutase deficiency (PMM2-CDG): evidence for hypoglycosylation-driven channelopathy. *Int J Mol Sci.* 2018;19(2).
- Arnoux JB, Boddaert N, Valayannopoulos V, et al. Risk assessment of acute vascular events in congenital disorder of glycosylation type Ia. *Mol Genet Metab.* 2008;93:444-449.