

Severe Factor X Deficiency Presenting as Febrile Seizure in an Infant

Meenal Garg, MD,* Mohammed Ramzan, MD,† Anand Kumawat, MD,‡
Jaikrishan Mittal, MD, DM,§ Satyendra Katewa, MD,†
and Piyush Gupta, MS||

Summary: Factor X deficiency is a severe inherited coagulation disorder, which is characterized by severe systemic bleeding manifestations in affected individuals. It is a rare disorder with a frequency of around 1:1,000,000 in the general population. We present the case of an infant with factor X deficiency who presented with complex febrile seizure. Although febrile seizures are very common in children, a closer scrutiny leads to neuroimaging and finding of intracranial bleed. Hematological and genetic investigations confirmed the diagnosis. A high index of suspicion should be maintained to diagnose uncommon bleeding disorders in children.

Key Words: factor X, factor X deficiency, rare bleeding disorder, febrile seizure

(*J Pediatr Hematol Oncol* 2019;00:000–000)

Factor X (FX) is a vitamin K dependent plasma glycoprotein, which plays a central role in the coagulation cascade being the first enzyme in the common pathway. Deficiency of FX is a rare hemorrhagic disorder and is the most severe of rare coagulation defects. The reported incidence in the general population is around 1:1,000,000.¹ As it is inherited as an autosomal recessive disorder, there is an 8- to 10-fold increase in the incidence in consanguineous populations such as in Iran.² The disorder usually manifests with severe systemic bleeding tendencies. Here we report an infant with severe FX deficiency who initially presented with complex febrile seizure (FS). A high index of suspicion led us to this uncommon diagnosis.

CASE DISCUSSION

An 8-month-old boy with normal birth and developmental history came to the emergency room with left-sided complex partial

Received for publication January 3, 2019; accepted January 27, 2019. From the *Department of Pediatric Neurology, Neoclinic Children Hospital; †Department of Pediatric Hemato-oncology, Manipal Hospital; ‡Department of Pediatrics, Sawai Man Singh Medical College and JK Lon Hospital; §Department of Pediatrics and Neonatology, Neoclinic Hospital; and ||Department of Corneal Surgery and Ophthalmology, SK Soni Hospital, Jaipur, Rajasthan, India.

Written informed consent was obtained from the patient's guardians for publication of the case and any accompanying images. A copy is available for review by the editor of this journal.

M.G.: conceptualized the study, acquired clinical data, and prepared the manuscript. M.R.: critically revised the initial manuscript. A.K.: acquired clinical data and helped in manuscript revision. J.M., S.K., and P.G.: conducted the literature search and manuscript editing.

The authors declare no conflict of interest.

Reprints: Meenal Garg, MD, Neoclinic Children Hospital, Nirman Nagar, Jaipur 302019, Rajasthan, India (e-mail: docmeenal@gmail.com).

Copyright © 2019 Wolters Kluwer Health, Inc. All rights reserved.

seizure of 15 minutes duration, which was aborted with midazolam nasal spray. He had a mild cough for 4 days and low-grade fever for 1 day. He was admitted for observation as a case of complex FS. In the hospital, he had a repeat brief left-sided seizure. There were no meningeal signs or focal neurological deficit. He was the first child of a nonconsanguineous marriage and there was no relevant family history. On careful questioning, parents recalled an episode of head trauma around 2 weeks back when the child had rolled out of bed and fell on the right side of his head. He had been irritable for some time but had no other symptoms since then. In view of the suggestive history of trauma and repeat focal seizures, neuroimaging was planned. Magnetic resonance imaging of the brain (Fig. 1) showed thin subdural hematoma over right temporo-parietal lobes, right cerebellar hemisphere, and along the right leaf of the tentorium. A small focus of hemosiderin residue was seen in the right temporal lobe.

The child was investigated in light of abnormal neuroimaging. Platelet count was normal, but both prothrombin time (94.2 s, normal: 9.5 to 12.3 s) and activated partial thromboplastin time (78.4 s, normal: 25.3 to 32.5 s) were found to be elevated. Further testing decreased the activity of FX (<1%). In view of prohibitive cost and limited availability of prothrombin complex concentrate (PCC), it was decided to use fresh frozen plasma (FFP) transfusions for prophylaxis. The patient was initially advised biweekly FFP transfusion with monitoring of FX levels. Genetic testing detected a homozygous missense variation in exon 1 of the *F10* gene (chr13:113777213C>A) that results in the amino acid substitution of Aspartic acid for Alanine at codon 15 (p.Ala15Asp; ENST00000375559). This mutation has been previously reported in 2 Indian patients with FX deficiency.³ The parents were counselled for further genetic testing and the need for regular prophylaxis, but the patient was on irregular follow-up. FX levels remained below 1% on repeat testing. Around 10 months after the initial presentation, the patient died due to spontaneous massive intracerebral hemorrhage.

DISCUSSION

A FS is a seizure accompanied by a temperature >100.4°F, without central nervous system infection, that occurs in children 6 to 60 months of age. FS is the most common convulsive event in children younger than 5 years and occur in 2% to 5% of all children.⁴ Focal, prolonged (>15 min), or multiple seizures are classified as complex⁵ and are associated with an increased risk of recurrent FSs and epilepsy.⁶ American Academy of Pediatrics guidelines recommend against neuroimaging in a child with simple FS.⁴ A few studies have also advised against neuroimaging in children with complex FS as it rarely affects the management.^{7,8} However, in the presence of suggestive history or neurological examination, investigations may be required.⁹ Also, focal, multiple, and prolonged FS (with increasing features of complexity) are more likely to have imaging abnormalities.¹⁰

FX deficiency is a rare bleeding disorder, which is caused by mutations in the FX gene located on the long arm of chromosome 13. The prevalence of heterozygous carriers is unclear. Heterozygotes may be completely asymptomatic or have skin, mucosa, gastrointestinal, or postoperative hemorrhage. They are usually diagnosed on the basis of family history or abnormal

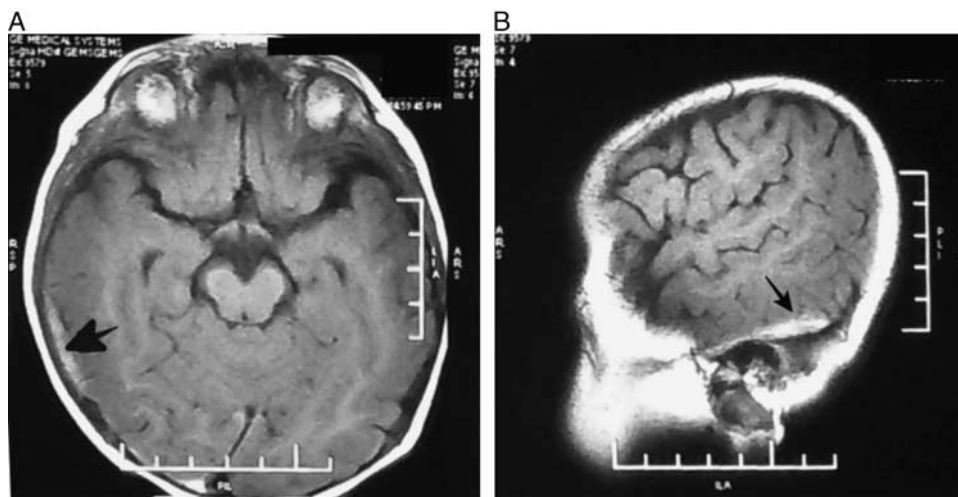


FIGURE 1. MRI brain. T2 fluid attenuated inversion recovery axial (A) and sagittal (B) images show subdural hematoma over right temporo-parietal lobes and along the right leaf of tentorium (marked by arrows).

preoperative laboratory testing.¹¹ Among homozygotes, the most common bleeding symptoms are mucocutaneous bleeds, easy bruising, epistaxis, gum bleeding, menorrhagia, and hemarthrosis. Besides the latter, other severe bleeding manifestations include intracranial, gastrointestinal, and umbilical cord bleeding in newborns.^{11,12} Intracranial bleeding has been reported in 9% to 26% of patients with FX deficiency in various studies.^{1,11,12} It is most common in the neonatal period and has also been reported antenatally.¹³ Patients with FX levels >0.56 IU/mL are generally asymptomatic, patients with FX levels <0.25 IU/mL may have spontaneous minor bleeding, and those with FX levels <0.1 IU/mL may have spontaneous major bleeding.¹⁴

In case of mild bleeding or minor surgery, injectable tranexamic acid may be used. A solution of tranexamic acid and fibrin glue may also be used to achieve local hemostasis. For severe bleeding or major surgery, FX replacement therapy can be accomplished with FFP or plasma-derived Factor IX concentrates (PCC) to maintain FX activity >0.2 IU/mL. In patients with a history of severe bleeding or suggestive family history, the use of twice-weekly PCC or twice-daily FFP has been suggested as prophylaxis to maintain trough FX activity >0.01 IU/mL in adults and >0.02 IU/mL in children. Pregnant women and neonates require aggressive monitoring and appropriate replacement therapy. Although an FX concentrate has become available, there is insufficient evidence to recommend its use.^{15,16}

The limited utility of neuroimaging in FS has been corroborated by many studies. However, a vigilant approach must be followed for every child presenting to the hospital with a seizure. Our patient suffered from a rare, severe coagulation disorder and was started on a potentially life-saving treatment. The treatment guidelines and therapeutic approaches in FX deficiency require further inquiry. Genetic testing and counselling should be considered imperative in all patients with FX deficiency.

REFERENCES

- Herrmann FH, Auerswald G, Ruiz-Saez A, et al. The Greifswald Factor X Deficiency Study Group. Factor X deficiency: clinical manifestation of 102 subjects from Europe and Latin America with mutations in the factor X gene. *Haemophilia*. 2006;12:479–489.
- Mannucci PM, Duga S, Peyvandi F. Recessively inherited coagulation disorders. *Blood*. 2004;104:1243–1252.
- Mota L, Shetty S, Idicula-Thomas S, et al. Molecular basis of factor X deficiency cases from India. *Haemophilia*. 2010;16:693–697.
- American Academy of Pediatrics. Febrile seizures: guideline for the neurodiagnostic evaluation of the child with a simple febrile seizure subcommittee on febrile seizures. *Pediatrics*. 2011;127:389.
- Nelson KB, Ellenberg JH. Predictors of epilepsy in children who have experienced febrile seizures. *N Engl J Med*. 1976;295:1029–1033.
- Sapir D, Leitner Y, Harel S, et al. Unprovoked seizures after complex febrile convulsions. *Brain Dev*. 2000;22:484–486.
- Teng D, Dayan P, Tyler S, et al. Risk of intracranial pathologic conditions requiring emergency intervention after a first complex febrile seizure episode among children. *Pediatrics*. 2006;117:304–308.
- Garvey MA, Gaillard WD, Rusin JA, et al. Emergency brain computed tomography in children with seizures: who is most likely to benefit? *Pediatrics*. 1998;133:664–669.
- Soden J, Koch TK. Brain abscess presenting as a febrile seizure. *Clin Pediatr (Phila)*. 2000;39:365–368.
- McAbee GN, Barasch ES, Kurfist LA. Results of computed tomography in neurologically normal children after initial onset of seizures. *Pediatr Neurol*. 1989;5:102–106.
- Acharya SS, Coughlin A, DiMichele DM. The North American Rare Bleeding Disorder Study Group. Rare bleeding disorder registry: deficiencies of factors II, V, VII, X, XIII, fibrinogen and dysfibrinogenemias. *J Thromb Haemost*. 2004;2:248–256.
- Peyvandi F, Mannucci PM, Lak M, et al. Congenital factor X deficiency: spectrum of bleeding symptoms in 32 Iranian patients. *Brit J Haematol*. 1998;102:626–628.
- De Sousa C, Clark T, Bradshaw A. Antenatally diagnosed subdural haemorrhage in congenital factor X deficiency. *Arch Dis Childhood*. 1988;63:1168–1170.
- Peyvandi F, Palla R, Menegatti M, et al. Coagulation factor activity and clinical bleeding severity in rare bleeding disorders: results from the European Network of Rare Bleeding Disorders. *J Thromb Haemost*. 2012;10:615–621.
- Bolton-Maggs PH, Perry DJ, Chalmers EA, et al. The rare coagulation disorders—review with guidelines for management from the United Kingdom Haemophilia Centre Doctors' Organisation. *Haemophilia*. 2004;10:593–628.
- Mumford AD, Ackroyd S, Alikhan R, et al. BCSH Committee, 2014. Guideline for the diagnosis and management of the rare coagulation disorders: a United Kingdom Haemophilia Centre Doctors' Organization guideline on behalf of the British Committee for Standards in Haematology. *Brit J Haematol*. 2014;167:304–326.