

## Solitaire Stent Retriever Mechanical Thrombectomy in a 6-Month-Old Patient with Acute Occlusion of the Internal Carotid Artery Terminus: Case Report

Hunter S. Futch<sup>1</sup>, Brian M. Corliss<sup>2</sup>, Adam J. Polifka<sup>2</sup>, Brian L. Hoh<sup>2</sup>, W. Christopher Fox<sup>2</sup>

■ **BACKGROUND:** Endovascular mechanical thrombectomy (MT) performed with stent retriever devices have proven efficacious in the treatment of adult patients with acute cerebral ischemia resulting from large-vessel occlusion. Recently, reports describing the use of MT in pediatric large-vessel occlusion have increased. However, these case reports are generally limited to older children and teenagers.

■ **CASE DESCRIPTION:** We report the use of a Solitaire (Medtronic, Minneapolis, Minnesota, USA) stent retriever for thrombectomy and revascularization of the right middle cerebral artery in a 6-month-old patient.

■ **CONCLUSIONS:** To our knowledge, this is the youngest patient reported to be treated with MT using a stent retriever. This case adds to the growing literature that supports the use of MT as a stroke intervention in pediatric patients.

### INTRODUCTION

Stent retrievers have changed the stroke treatment paradigm. These devices allow neurointerventionalists to quickly retrieve an arterial thrombus and restore blood flow to brain at risk of permanent ischemia. The use of stent-retrievers has significantly increased the odds of attaining an independent functional outcome following large-vessel occlusion when compared with intravenous thrombolytic therapy alone,<sup>1-5</sup> and the

use of stent-retrievers in concert with tissue plasminogen activator is now a Level I treatment recommendation for eligible adult patients presenting with acute stroke.<sup>6</sup> Although there are no current guidelines for the use of stent-retrievers in pediatric patients, similar interventional techniques have been described for the treatment of pediatric ischemic stroke.<sup>7</sup> As the result of low case volume and the heterogeneity of the disease, the literature concerning pediatric endovascular mechanical thrombectomy (MT) and other interventional stroke treatments remains in its infancy. Although these obstacles make the establishment of official guidelines challenging, thus far reports detailing MT for ischemic events in children are quite positive.<sup>8</sup> In this report, we describe the use of a Solitaire device in an infant and contribute to the evidence that MT devices may be deployed successfully in young patients.

### CASE REPORT

A 6-month-old male patient presented with eye movement abnormalities and was diagnosed with a suprasellar lesion on magnetic resonance imaging (MRI) (Figure 1A–B). During stereotactic biopsy for this lesion, bleeding through the cannula was reported, which was controlled via irrigation. Postoperative computed tomography (Figure 1C) was unremarkable. Tissue diagnosis revealed pilocytic astrocytoma. He was discharged from the hospital uneventfully.

Three weeks later, the patient was brought to an outside hospital emergency department with seizures. Computed tomography and subsequent MRI obtained after transfer to our institution revealed subarachnoid hemorrhage in the interhemispheric fissure and subacute infarction in the right anterior cerebral artery (ACA) territory and caudate (Figure 2A–B). Magnetic resonance angiography revealed pseudoaneurysm at the right A1 segment and another

### Key words

- Infant
- Mechanical thrombectomy
- Solitaire
- Stent retriever
- Stroke

### Abbreviations and Acronyms

- **ACA:** Anterior cerebral artery
- **DAC:** Distal access catheter
- **ICA:** Internal carotid artery
- **MCA:** Middle cerebral artery

■ **MRI:** Magnetic resonance imaging

■ **MT:** Mechanical thrombectomy

From the <sup>1</sup>University of Florida College of Medicine, Gainesville; and <sup>2</sup>Department of Neurological Surgery, University of Florida, Gainesville, Florida, USA

To whom correspondence should be addressed: W. Christopher Fox, M.D.  
[E-mail: [w.chrisfox@neurosurgery.ufl.edu](mailto:w.chrisfox@neurosurgery.ufl.edu)]

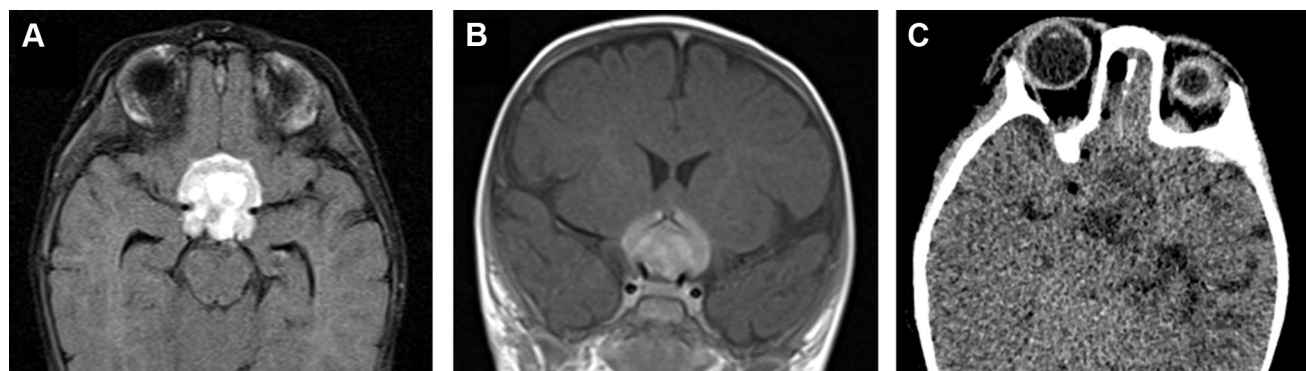
Citation: *World Neurosurg.* (2019).

<https://doi.org/10.1016/j.wneu.2019.03.038>

Journal homepage: [www.journals.elsevier.com/world-neurosurgery](http://www.journals.elsevier.com/world-neurosurgery)

Available online: [www.sciencedirect.com](http://www.sciencedirect.com)

1878-8750/\$ - see front matter © 2019 Elsevier Inc. All rights reserved.



**Figure 1.** (A–B) Magnetic resonance imaging reveals a hypothalamic mass in 6-month-old male who presented with nystagmus. Bleeding through the cannula was reported during stereotactic biopsy of the lesion, which was

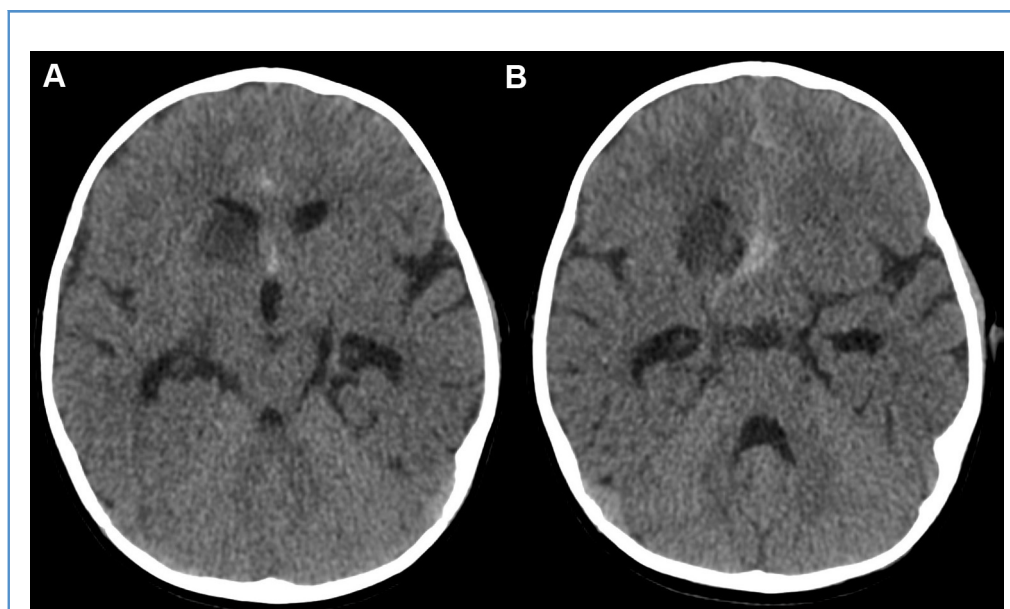
controlled via irrigation. (C) Postoperative computed tomography was unremarkable.

involving the right A1–2 junction. Catheter angiography was recommended to further delineate the pseudoaneurysms (Figure 3A–B) and likely proceed with endovascular treatment. The authors of this report did not perform the patient's brain biopsy, but per the operative report indicating brisk bleeding via the biopsy cannula, as well as his subsequent presentation, the etiology of the pseudoaneurysms was most likely iatrogenic.

The right A1–A2 junction aneurysm was approached from the left side, as this provided optimal access to the neck of the aneurysm. After initial angiography, a 3.3-French guide catheter was placed into the left internal carotid artery (ICA) under road-map guidance. An Echelon 10 (Medtronic, Minneapolis,

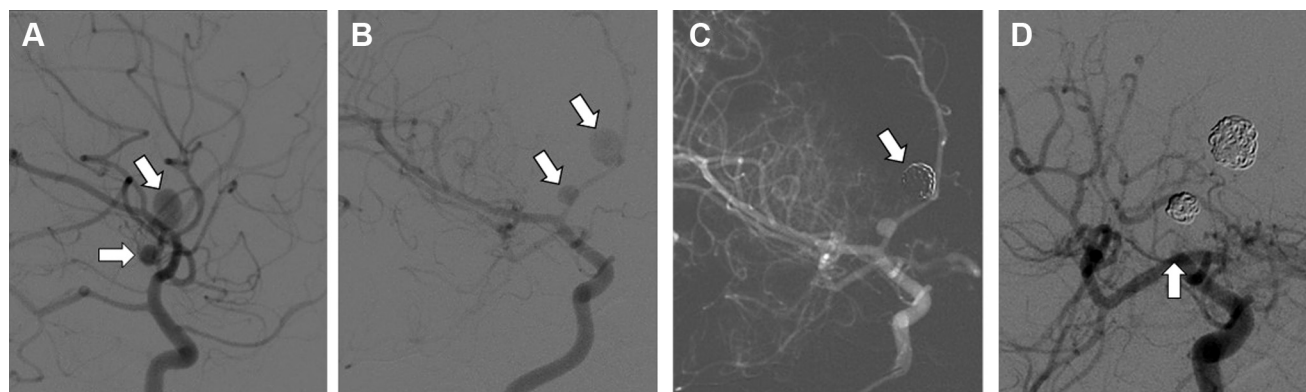
Minnesota, USA) microcatheter and a Synchro 10 (Stryker, Fremont, California, USA) microwire were used to navigate into the left A1 segment, across the anterior communicating artery, and into the pseudoaneurysm. Four coils were then placed and the microcatheter was removed. Follow-up angiography revealed obliteration of the A1–A2 junction aneurysm and baseline filling through the parent vessels (Figure 3C).

We then transitioned to treatment of the right A1 pseudoaneurysm. The 3.3-French guide catheter was replaced with a 4-French Berenstein catheter, placed in the right ICA, to improve visualization of follow-up angiography around the microcatheter. A Prowler 10 (Codman Neurovascular, Miami Lakes, Florida, USA)



**Figure 2.** (A–B) Axial computed tomography scan at the time of admission demonstrated subarachnoid hemorrhage in the interhemispheric fissure and

suprasellar cistern. Additionally, hypodensity of the caudate head was observed, consistent with infarction of the recurrent artery of Heubner.



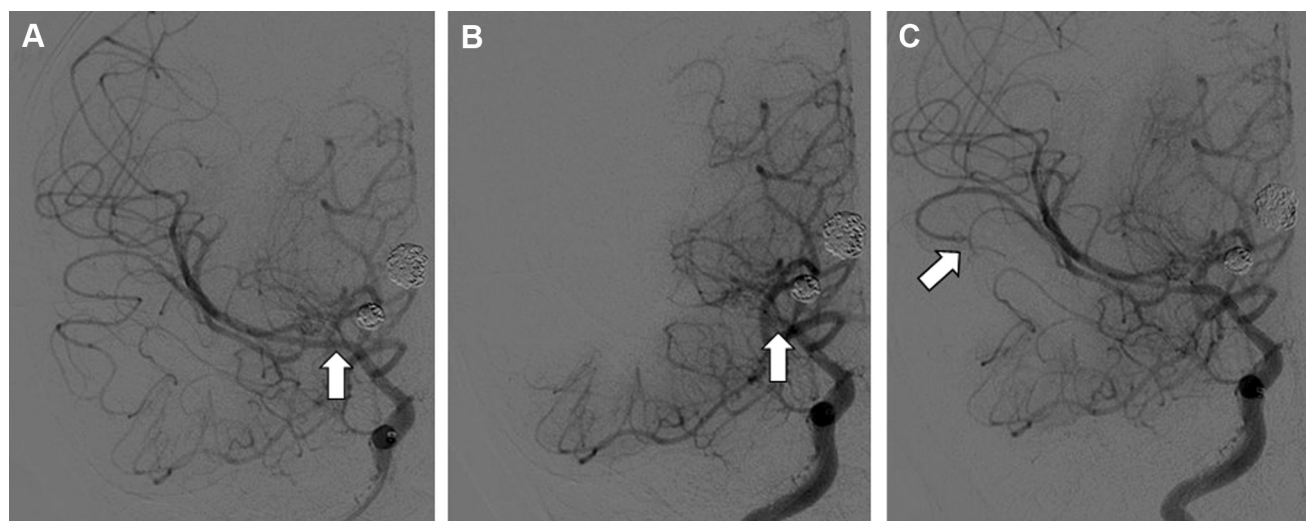
**Figure 3.** (A–B) Catheter angiogram revealed 2 pseudoaneurysms (arrows). The distal aneurysm appears to originate near the right A1–A2 junction and the origin of the recurrent artery of Heubner; vessel trauma in this area likely led to infarction seen on the pre-embolization computed tomography, as well as the pseudoaneurysm. (C) Endovascular coiling of

the pseudoaneurysm located on the right A1–A2 junction (arrow) is accomplished via the left internal carotid artery (ICA), with patency of parent vessel maintained. (D) Postcoiling angiogram of the proximal right A1 pseudoaneurysm reveals cutoff at the ICA terminus (arrow). Increased flow through the posterior communicating artery is seen.

microcatheter and Synchro 10 microwire were used to catheterize the aneurysm. Three coils were placed. Follow-up angiography revealed obliteration of the aneurysm. The microcatheter was removed and final follow-up angiography from the right ICA position revealed thrombus at the ICA terminus (Figure 3D) and no filling of the right middle cerebral artery (MCA) or ACA.

At the time of this case at our institution, we did not routinely heparinize patients before embolization of ruptured aneurysms—heparinization was usually reserved until after the dome of the aneurysm had been protected to avoid re-rupture. We felt this

prudent in this case, given the very high risk of rupture for dissecting aneurysms. In addition, we were concerned about inducing suprathreshold anticoagulation, given the heparin in the saline administered through the catheters (a reduced amount—0.03 units/kg/cc—compared with the typical 2 units/cc in adults) and the patient's very small size. Once thrombosis was identified, the patient was loaded with heparin according to weight, and the activated clotting time was monitored to achieve a value  $2\times$  normal. Attempts were made to disrupt the thrombus using the microwire/microcatheter in place. We elected not to



**Figure 4.** (A) Deployment of a Solitaire FR (4 × 20-mm) stent retriever allowed for complete revascularization of the middle cerebral artery (MCA) (arrow). (B) Delayed follow-up angiography demonstrated rethrombosis of

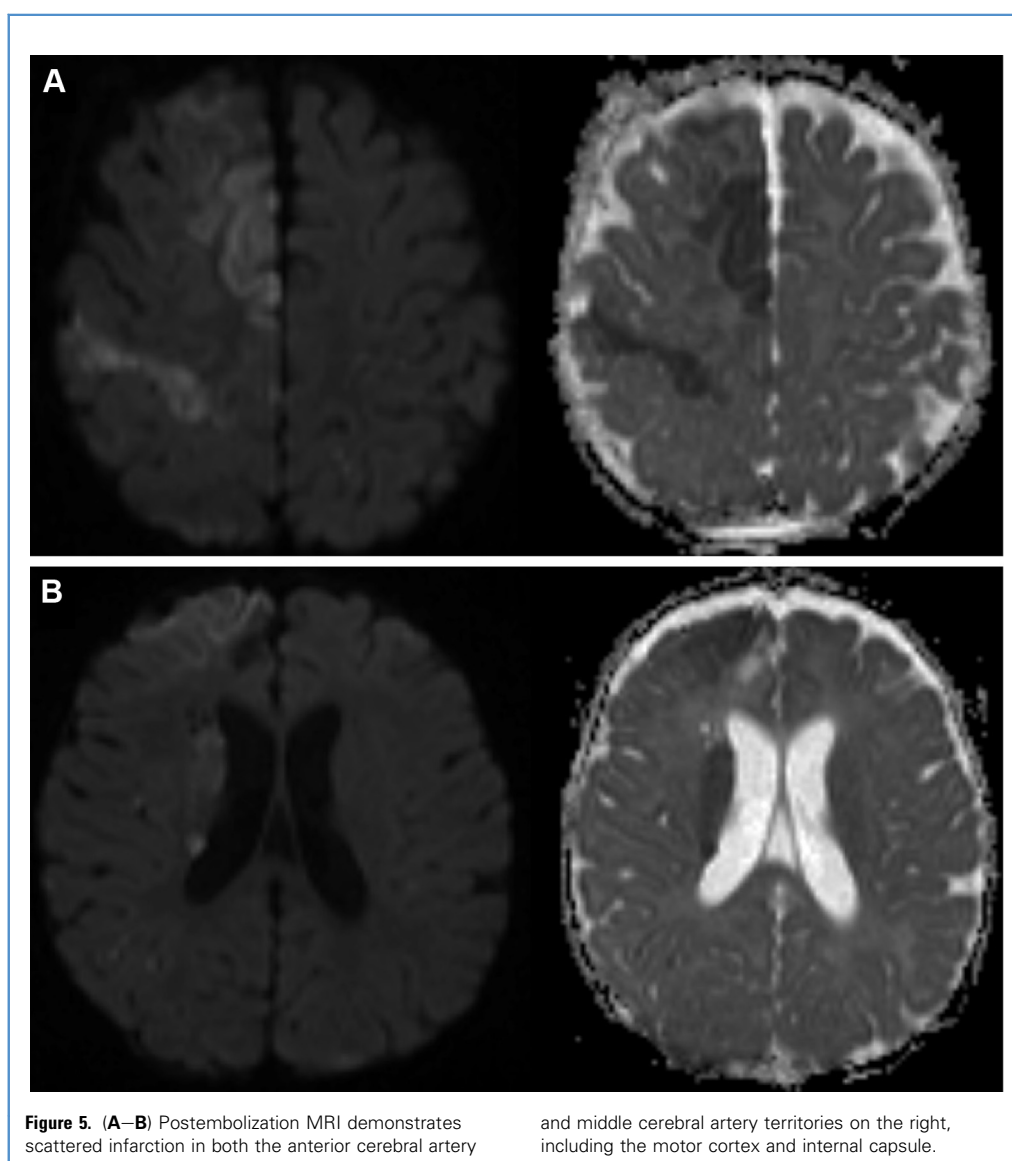
the MCA (arrow). (C) After a second Solitaire stent retriever deployment, the MCA remained patent (arrow).

treat with an intravenous glycoprotein IIb/IIIa receptor antagonist such as abciximab, given the patient's recent hemorrhage as well as the uncertain effects of this medication in a very young patient. The 4-French Berenstein guide catheter was then exchanged for an 038 distal access catheter (DAC) in preparation for MT. The microwire and microcatheter were navigated past the thrombus into the MCA, followed by the DAC. A Solitaire 4 × 20-mm stent retriever (Medtronic, Minneapolis, Minnesota, USA) was loaded through the DAC and the stent was successfully unsheathed. The stent was left in place for 5 minutes and then withdrawn into the guide catheter under constant aspiration. Follow-up angiography revealed Thrombolysis In Cerebral Infarction 3 revascularization of the right MCA distribution (Figure 4A). However, the right A1 segment remained without filling.

After 5 minutes, follow-up angiogram showed re-thrombosis of the right MCA segment (Figure 4B). A Prowler Select Plus and a

Synchro 2 standard microwire were then advanced through the distal access catheter to cross the area of thrombosis. The Solitaire 4 × 20-mm stent was redeployed and left in place for 5 minutes. The stent was then recaptured and removed under constant aspiration. Follow-up angiography revealed Thrombolysis In Cerebral Infarction 2B recanalization of the MCA territory. Slow filling was seen in the right anterior temporal artery, and a second follow-up angiogram showed loss of the anterior temporal artery (Figure 4C). However, the M1, M2, and distal MCA circulation remained patent. We performed an additional delayed angiogram to ensure there was no re-thrombosis, and at this point, the procedure was terminated.

Postoperatively, the patient experienced left hemiparesis and seizures, which were controlled with medication. A postoperative MRI showed scattered infarction in the MCA and ACA territories on the right side (Figure 5A–B). His hemiparesis improved



**Figure 5.** (A–B) Postembolization MRI demonstrates scattered infarction in both the anterior cerebral artery

and middle cerebral artery territories on the right, including the motor cortex and internal capsule.

significantly over 2 weeks. His tumor was treated with carboplatin and vincristine chemotherapy and 2 years after thrombectomy, he is doing well clinically with symmetric upper and lower extremity strength and no recurrence of tumor or pseudoaneurysm. MRI at the 2-year follow-up showed generalized cortical atrophy in the right ICA territory, whereas magnetic resonance angiography at this time demonstrated patency of the right MCA and ACA, with no recanalization of either pseudoaneurysm (Figure 6A–B).

## DISCUSSION

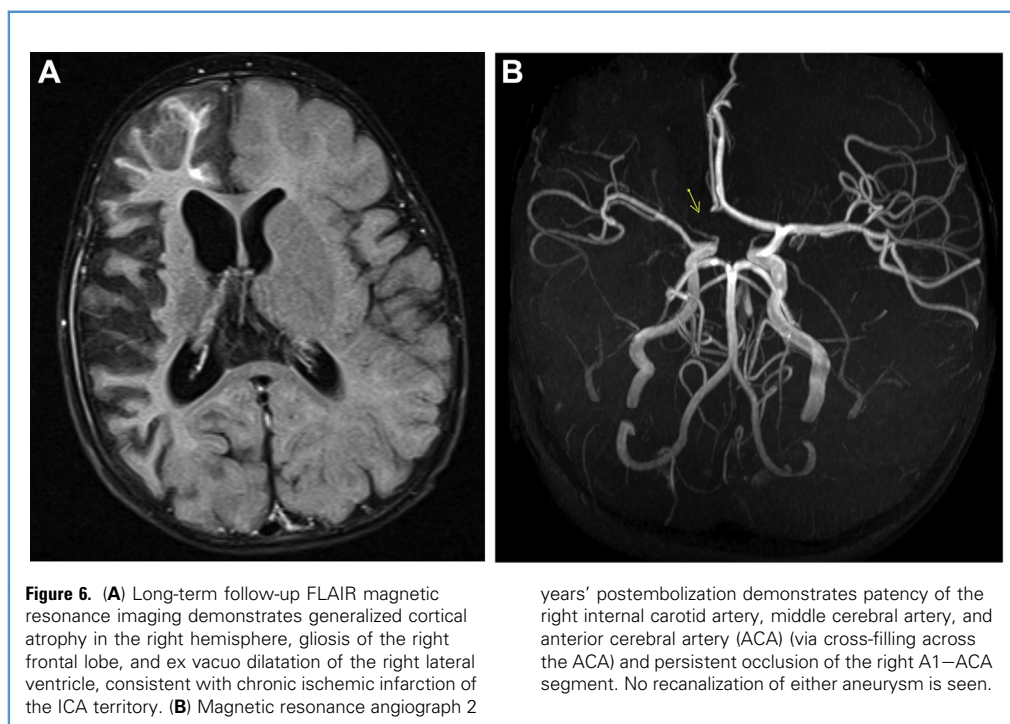
Pediatric cerebral ischemia is rare and usually secondary to underlying conditions predisposing to arterial thrombosis, such as sickle cell disease, or iatrogenic and related to therapeutic cardiovascular interventions, especially in the setting of left ventricular assist devices, extracorporeal membrane oxygenation, or cardiopulmonary bypass procedures. The rarity of spontaneous ischemic stroke in children, combined with the relative difficulty in diagnosis of the disease in very young patients, makes studying stroke in large case series or in randomized trials challenging. As such, the American Heart Association guidelines on the use of intravenous thrombolysis for arterial stroke generally recommend against its use outside of clinical trials.<sup>7</sup> These now decade-old guidelines make no specific recommendations regarding the use of endovascular reperfusion techniques.

In 2015, multiple positive trials were published demonstrating the efficacy of MT using a stent retriever in combination with intravenous thrombolysis.<sup>1–5</sup> Since then the development and implementation of new technologies has accelerated, and outcomes in adults presenting with stroke secondary to acute cerebral

large-vessel occlusion have improved. Although no such trials including pediatric patients exist, case literature in the stent retriever era illustrates sporadic use of this technology in children (Table 1).<sup>9–35</sup> These reports demonstrate the feasibility of achieving reperfusion in pediatric patients with the off-label use of stent-retrievers approved for use in adults.

The broad applicability of these technologies to children of all ages, however, is unclear. In contrast to adults, children have increased variability in terms of intracranial vessel size. The Solitaire comes in 2 diameters—4.0 and 6.0 mm—and is indicated for vessels 2.0–4.0 or 3.0–5.5 mm in diameter, respectively. In the case presented, the 4.0 × 20-mm Solitaire was deployed from the superior M2 segment (measuring approximately 1.5 mm) into the ICA (measuring about 2.2 mm), both smaller than the manufacturer's recommended and Food and Drug Administration–approved indication. However, stent retrievers are highly flexible and conformable and are frequently used off-label in adults to perform thrombectomy of the more distal cerebral vasculature, where the vessel may be less than 2 mm.

Presumably, the unknown of using stent retrievers in very young patients, as well as the relatively infrequency with which this patient population is affected by stroke, are reasons why the literature on the use of these devices in very young children is limited, whereas a larger number of cases have been reported in children aged 9–18 years. In one retrospective review of a single-institution series,<sup>30</sup> the median age of patients treated was 11.8 years, with the youngest patients (two 3-year-old patients) receiving only intravenous thrombolysis and not MT. Another study of pediatric stroke patients with a mean age of 6.7 years showed a similar trend, with older children (mean age 11 years) being more likely to



**Figure 6.** (A) Long-term follow-up FLAIR magnetic resonance imaging demonstrates generalized cortical atrophy in the right hemisphere, gliosis of the right frontal lobe, and ex vacuo dilatation of the right lateral ventricle, consistent with chronic ischemic infarction of the ICA territory. (B) Magnetic resonance angiograph 2

years' postembolization demonstrates patency of the right internal carotid artery, middle cerebral artery, and anterior cerebral artery (ACA) (via cross-filling across the ACA) and persistent occlusion of the right A1–ACA segment. No recanalization of either aneurysm is seen.

**Table 1.** Endovascular Mechanical Thrombectomy Procedures Reported in Pediatric Patients

| Study  | No. Patients | Age                        | Technique  |
|--|--------------|----------------------------|--|
| Gruber et al., 2000 <sup>9</sup>             | 1            | 6 years                    | Guidewire  |
| Tsvigoulis et al., 2008 <sup>10</sup>        | 1            | 6 years                    | Merci Retriever, POWERSAIL balloon                   |
| Grunwald et al., 2010 <sup>11</sup>          | 3            | 7, 16, 16 years            | Penumbra (7, 16 year-olds) Phenox (16 year-old)      |
| Modrau et al., 2011 <sup>12</sup>            | 1            | 10 years                   | Gooseneck snare                                      |
| Taneja et al., 2011 <sup>13</sup>            | 1            | 14 years                   | Solitaire  |
| Alnaami et al., 2013 <sup>14</sup>           | 1            | 8 years                    | Solitaire  |
| Dubedout et al., 2013 <sup>15</sup>          | 1            | 7 years                    | Capture system                                       |
| Fink et al., 2013 <sup>16</sup>              | 1            | 11 years                   | Solitaire  |
| Bodey et al., 2014 <sup>17</sup>             | 4            | 5, 6, 10, 15 years         | Solitaire (5, 6, 10 year-olds), Revive (15 year-old) |
| Rhee et al., 2014 <sup>18</sup>              | 1            | 9 years                    | Solitaire  |
| Stidd and Lopes, 2014 <sup>19</sup>          | 1            | 2 years                    | Trevo pro 14   |
| van den Wijngaard et al., 2014 <sup>20</sup> | 1            | 14 years                   | Solitaire  |
| Hu et al., 2014 <sup>21</sup>                | 1            | 9 years                    | Solitaire  |
| Maza et al., 2014 <sup>22</sup>              | 1            | 12 years                   | Solitaire  |
| Shaikh et al., 2015 <sup>23</sup>            | 1            | "Pre-teenager"             | Solitaire  |
| Huded et al., 2015 <sup>24</sup>             | 1            | 6 years                    | Solitaire  |
| Vega et al., 2015 <sup>25</sup>              | 1            | 11 years                   | Trevo clot retrieval                                 |
| Savastano et al., 2016 <sup>26</sup>         | 1            | 22 months                  | Solitaire  |
| See et al., 2016 <sup>27</sup>               | 1            | 6 years                    | Capture system                                       |
| Buompadre et al., 2017 <sup>28</sup>         | 1            | 8 years                    | Trevo  |
| Stowe et al., 2018 <sup>29</sup>             | 1            | 9 years                    | Trevo  |
| Tabone et al., 2017 <sup>30</sup>            | 3            | 4, 12, 14 years            | Not stated   |
| Nicosia et al., 2017 <sup>31</sup>           | 1            | 23 months                  | Solitaire  |
| Sun et al., 2018 <sup>32</sup>               | 1            | 9 months                   | Solitaire  |
| Bigi et al., 2018 <sup>33</sup>              | 6            | 7, 8, 10, 11, 14, 15 years | Unspecified stent retriever                          |
| Kim et al., 2018 <sup>34</sup>               | 1            | 14 years                   | Trevo  |

Adapted from Buompadre et al.<sup>28</sup>

be treated with endovascular techniques.<sup>33</sup> Given the serious consequences of hemispheric stroke and considering the soft, pliable nature of stent retrievers, we felt the benefit of MT outweighed the risk of using a stent retriever in this patient.

To date, although published reports have demonstrated the feasibility of endovascular reperfusion in pediatric patients, no study has demonstrated superiority of any reperfusion technique (intravenous thrombolysis, MT, intra-arterial thrombolysis) compared with standard of care, or an increased risk of complications with these interventions. One of the major limitations of these studies is the delay in diagnosis of stroke in pediatric populations and therefore the low number of patients who are candidates for reperfusion. In the present case, we demonstrate the efficacy of Solitaire thrombectomy in a very young patient, a rarely encountered clinical scenario, but one in which use of this

technique may greatly reduce the risk of permanent neurologic morbidity or mortality.

In summary, this case report demonstrates the safe use of a Solitaire stent retriever in a 6-month-old patient, to our knowledge the youngest patient yet reported to have undergone MT. It is appropriate for neuroendovascular surgeons to be conservative in the adoption of MT using stent retrievers designed for adults in pediatric patients. However, over the last decade a compilation of case reports has revealed that MT devices may be a safe option in children, particularly when the alternative of completed stroke has significant long-term consequences. A small but growing body of literature exists describing MT in the pediatric setting (Table 1).<sup>9-36</sup> An analysis of 68 published cases of acute ischemic stroke in patients <18 years old found that MT significantly increased rates of recanalization and good outcome.<sup>8</sup> The nature of pediatric

stroke and the current literature makes creating definitive treatment guidelines challenging. However, Solitaire MT may be

performed safely in very young patients, reducing the risk of permanent neurologic deficit after large-vessel occlusion.

## REFERENCES

- Berkhemer OA, Franssen PSS, Beumer D, et al. A randomized trial of intraarterial treatment for acute ischemic stroke. *N Engl J Med.* 2015;372:11-20.
- Campbell BCV, Mitchell PJ, Kleinig TJ, et al. Endovascular therapy for ischemic stroke with perfusion-imaging selection. *N Engl J Med.* 2015;372:1009-1018.
- Goyal M, Demchuk AM, Menon BK, et al. Randomized assessment of rapid endovascular treatment of ischemic stroke. *N Engl J Med.* 2015;372:1019-1030.
- Jovin TG, Chamorro A, Cobo E, et al. Thrombectomy within 8 hours after symptom onset in ischemic stroke. *N Engl J Med.* 2015;372:2296-2306.
- Saver JL, Goyal M, Bonafe A, et al. Stent-retriever thrombectomy after intravenous t-PA vs. t-PA alone in stroke. *N Engl J Med.* 2015;372:2285-2295.
- Powers WJ, Rabinstein AA, Ackerson T, et al. 2018 guidelines for the early management of patients with acute ischemic stroke. *Stroke.* 2018;49:e46-e110.
- Roach ES, Golomb MR, Adams R, et al. Management of stroke in infants and children: a scientific statement from a special writing group of the American Heart Association Stroke Council and the Council on Cardiovascular Disease in the Young. *Stroke.* 2008;39:2644-2691.
- Cobb MI-PH, Laarakker AS, Gonzalez LF, Smith TP, Hauck EF, Zomorodi AR. Endovascular therapies for acute ischemic stroke in children. *Stroke.* 2017;48:2026-2030.
- Gruber A, Nasel C, Lang W, Kitzmuller E, Bavinszki G, Czech T. Intra-arterial thrombolysis for the treatment of perioperative childhood cardioembolic stroke. *Neurology.* 2000;54:1684-1686.
- Tsigvoulis G, Horton JA, Ness JM, et al. Intravenous thrombolysis followed by intra-arterial thrombolysis and mechanical thrombectomy for the treatment of pediatric ischemic stroke. *J Neurol Sci.* 2008;275:151-153.
- Grunwald I, Walter S, Ghiath Shamdeen M, et al. New mechanical recanalization devices—the future in pediatric stroke treatment. *J Invasive Cardiol.* 2010;22:63-66.
- Modrau B, Sørensen L, Bartholdy NJ, von Weitzel-Mudersbach P, Andersen G, Rasmussen PV. Systemic thrombolytic therapy alone and in combination with mechanical revascularization in acute ischemic stroke in two children. *Case Rep Neurol.* 2011;3:91-96.
- Taneja SR, Hanna I, Holdgate A, Wenderoth J, Cordato DJ. Basilar artery occlusion in a 14-year old female successfully treated with acute intravascular intervention: case report and review of the literature: basilar artery occlusion. *J Paediatr Child Health.* 2011;47:408-414.
- Alnaami I, Buchholz H, Ashforth R, et al. Successful use of Solitaire FR for stroke in a pediatric ventricular assist device patient. *Ann Thorac Surg.* 2013;96:e65-e67.
- Dubedout S, Cognard C, Cancès C, Albuher JF, Cheuret E. Successful clinical treatment of child stroke using mechanical embolectomy. *Pediatr Neurol.* 2013;49:379-382.
- Fink J, Sonnenborg L, Larsen LL, Born AP, Holtmannspötter M, Kondziella D. Basilar artery thrombosis in a child treated with intravenous tissue plasminogen activator and endovascular mechanical thrombectomy. *J Child Neurol.* 2013;28:1521-1526.
- Bodey C, Goddard T, Patankar T, et al. Experience of mechanical thrombectomy for paediatric arterial ischaemic stroke. *Eur J Paediatr Neurol.* 2014;18:730-735.
- Rhee E, Hurst R, Pukenas B, et al. Mechanical embolectomy for ischemic stroke in a pediatric ventricular assist device patient. *Pediatr Transpl.* 2014;18:E88-E92.
- Stidd DA, Lopes DK. Successful mechanical thrombectomy in a 2-year-old male through a 4-French guide catheter. *Neurointervention.* 2014;9:94.
- van den Wijngaard I, Wermer M, van Walderveen M, Wiendels N, Peeters-Scholte C, Lycklama Å Nijeholt G. Intra-arterial treatment in a child with embolic stroke due to atrial myxoma. *Intervent Neuroradiol.* 2014;20:345-351.
- Hu YC, Chugh C, Jeevan D, Gillick JL, Marks S, Stiefel MF. Modern endovascular treatments of occlusive pediatric acute ischemic strokes: case series and review of the literature. *Child Nerv Syst.* 2014;30:937-943.
- Maza SS de la, Felipe AD, Matute MC, et al. Acute ischemic stroke in a 12-year-old successfully treated with mechanical thrombectomy. *J Child Neurol.* 2014;29:269-273.
- Shaikh H, Pukenas BA, McIntosh A, Licht D, Hurst RW. Combined use of Solitaire FR and Penumbra devices for endovascular treatment of cerebral venous sinus thrombosis in a child. *J Neurointerv Surg.* 2015;7:e10.
- Huded V, Kamath V, Chauhan B, Sapare A, Kekatpure M. Mechanical thrombectomy using solitaire in a 6-year-old child. *J Vasc Interv Neurol.* 2015;8:4.
- Vega RA, Chan JL, Anene-Maidoh TI, Grimes MM, Reavey-Cantwell JF. Mechanical thrombectomy for pediatric stroke arising from an atrial myxoma: case report. *J Neurosurg Pediatr.* 2015;15:301-305.
- Savastano L, Gemmete JJ, Pandey AS, Roark C, Chaudhary N. Acute ischemic stroke in a child due to basilar artery occlusion treated successfully with a stent retriever. *J Neurointerv Surg.* 2016;8:e33.
- See AP, Kochis MA, Khandelwal P, Orbach DB. Considerations in applying a new stent retriever in pediatric endovascular cerebral thrombectomy for acute ischemic stroke. *Pediatr Neurosurg.* 2016;51:263-268.
- Buompadre MC, Andres K, Slater L-A, et al. Thrombectomy for acute stroke in childhood: a case report, literature review, and recommendations. *Pediatr Neurol.* 2017;66:21-27.
- Stowe RC, Kan P, Breen DB, Agarwal S. Mechanical thrombectomy for pediatric acute stroke and ventricular assist device. *Brain Dev.* 2018;40:81-84.
- Tabone L, Mediamolle N, Bellesme C, et al. Regional pediatric acute stroke protocol: initial experience during 3 years and 13 recanalization treatments in children. *Stroke.* 2017;48:2278-2281.
- Nicosia G, Cicala D, Miron G, et al. Childhood acute basilar artery thrombosis successfully treated with mechanical thrombectomy using stent retrievers: case report and review of the literature. *Child Nerv Syst.* 2017;33:349-355.
- Sun LR, Pearl M, Bahouth MN, et al. Mechanical thrombectomy in an infant with acute embolic stroke. *Pediatr Neurol.* 2018;82:53-54.
- Bigi S, Dulcey A, Gralla J, et al. Feasibility, safety and outcome of recanalisation treatment in childhood stroke. *Ann Neurol.* 2018;83:1125-1132.
- Kim ES, Mason EK, Koons A, Quinn SM, Williams RL. Successful utilization of mechanical thrombectomy in a presentation of pediatric acute ischemic stroke. *Case Rep Pediatr.* 2018;2018:1-3.
- Wilson JL, Eriksson CO, Williams CN. Endovascular therapy in pediatric stroke: utilization, patient characteristics, and outcomes. *Pediatr Neurol.* 2017;69:87-92.e2.
- Zanaty M, Chalouhi N, Starke RM, et al. Endovascular stroke intervention in the very young. *Clin Neurol Neurosurg.* 2014;127:15-18.

*Conflict of interest statement: The authors declare that the article content was composed in the absence of any commercial or financial relationships that could be construed as a potential conflict of interest.*

Received 14 January 2019; accepted 4 March 2019

Citation: *World Neurosurg.* (2019).

<https://doi.org/10.1016/j.wneu.2019.03.038>

Journal homepage: [www.journals.elsevier.com/world-neurosurgery](http://www.journals.elsevier.com/world-neurosurgery)

Available online: [www.sciencedirect.com](http://www.sciencedirect.com)

1878-8750/\$ - see front matter © 2019 Elsevier Inc. All rights reserved.