

Mechanical Thrombectomy for Acute Ischemic Stroke in Pregnancy

Richard Blythe, MBChB (Hons), MRCP, Azza Ismail, MBBS, MRCP, PhD, and
Aaizza Naqvi, MBBS, MRCP

Intravenous recombinant tissue-plasminogen-activator (rtPA) and mechanical-thrombectomy (MT) are currently the only approved treatments for acute ischemic stroke. Their effectiveness was demonstrated in several clinical trials, and is therefore standard of care. Pregnant women were not included in these studies and consequently the effectiveness and safety in this group are unclear. We present a rare case of a patient in the third-trimester of pregnancy that underwent MT. A 29-year-old woman of 39 weeks' gestation presented with left facial-paresis, hemiparesis, and neglect. Her CT-Angiogram showed a large occlusive thrombus within the right M1-M2 segments. During pregnancy she had developed thrombocytopenia. There was initial treatment decision dilemma. In view of her history of thrombocytopenia, there was concern about administering rtPA due to the risk of bleeding. As the thrombus was large, rtPA may also be ineffective. MT was proposed by the Stroke Physician as the preferred treatment option. A concern from the Interventional-Radiologist was the risk of exposure to radiation and contrast agents. As the patient had a disabling stroke at a young age, decision was made to proceed with MT which started 141 minutes after symptom onset. The clot was aspirated without complications. Final check angiogram showed complete resolution of flow within the right middle cerebral artery territory. The patient underwent elective uncomplicated Caesarean-section 5 days later delivering a healthy new born. Severe stroke in pregnancy is rare, but has grave consequences for both mother and infant. Timely decision-making is crucial. Our case demonstrates that MT can be provided safely and effectively in the third trimester of pregnancy.

Key Words: Ischemic stroke—pregnancy—mechanical thrombectomy—
intravenous thrombolysis

Crown Copyright © 2019 Published by Elsevier Inc. All rights reserved.

From the The Department of Clinical Neurology, The Royal Hallamshire Hospital, Sheffield Teaching Hospitals, United Kingdom.

Received November 23, 2018; revision received February 7, 2019; accepted February 14, 2019.

No grant support.

Address correspondence to Richard Blythe, MBChB (Hons), MRCP, The Department of Clinical Neurology, The Royal Hallamshire Hospital, Sheffield Teaching Hospitals, United Kingdom. E-mail address: r.blythe@nhs.net.

1052-3057/\$ - see front matter

Crown Copyright © 2019 Published by Elsevier Inc. All rights reserved.

<https://doi.org/10.1016/j.jstrokecerebrovasdis.2019.02.015>

Background

Intravenous recombinant tissue-plasminogen-activator (rtPA) and mechanical-thrombectomy (MT) are currently the only approved treatments for acute ischemic stroke. Their effectiveness was demonstrated in several clinical trials, and is therefore standard of care.¹ Pregnant women were not included in these studies and consequently the effectiveness and safety in this group are unclear.^{2,3} We present a rare case of a patient in the third-trimester of pregnancy that underwent MT.

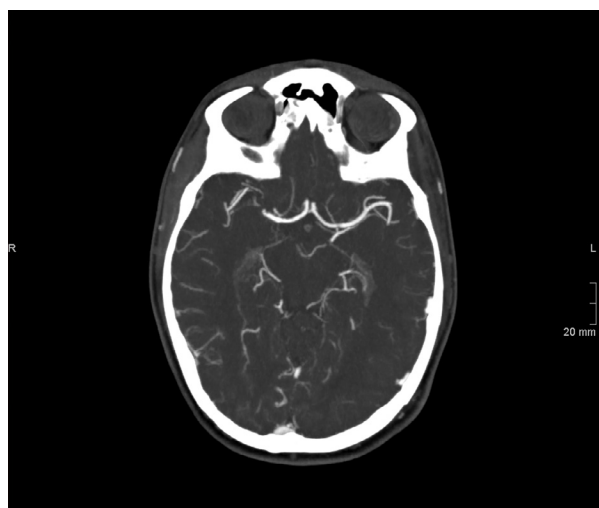


Figure 1. Axial CTA image at the level of the circle of Willis and both MCAs. Abbreviation: MCA, middle-cerebral-artery; CTA, CT angiogram.

Case report

A 29-year-old-woman of 39 weeks' gestation presented with left facial paresis, hemiparesis, and neglect. Her National Institute of Health Stroke Scale score was 11. Her CT-scan brain demonstrated hyper-dense right middle cerebral artery. She underwent CT-Angiogram which showed a large occlusive thrombus within the right M1-M2 segments (Fig 1). She had a previous history of transient Factor-XI deficiency and had developed gestational thrombocytopenia.

There was initial treatment decision dilemma. In view of her history of thrombocytopenia and clotting disorder, there was concern about administering rtPA due to the risk of bleeding. As the thrombus was large, rtPA may also be ineffective. Therefore MT was proposed by the Stroke Physician as the preferred treatment option. A concern from the Interventional Radiologist was the risk of exposure to radiation and contrast agents to the mother and fetus with MT. Iodinated contrast agents can cross the placenta and enter the fetal circulation or pass directly into the amniotic fluid. However, animal studies have reported no teratogenicity from its use.⁴ Despite this lack of known harm, it is generally recommended that contrast only be used if absolutely required.⁵ We know that fetal radiation dose in CT-scan brain is minimal as the uterus is positioned outside the field of view.⁶

As the patient had a disabling stroke at a young age, decision was made to proceed with MT which was started 141 minutes after symptom onset. The clot was aspirated without complications. Final check angiogram showed complete resolution of flow within the right-middle-cerebral-artery territory. The patient underwent elective uncomplicated Caesarean section 5 days later delivering a healthy new born. She was discharged home 7 days following admission. Modified Rankin Scale at 6 weeks was 0.

Conclusions

Severe stroke in pregnancy is rare, but has grave consequences for both mother and infant.^{7,8} Timely decision regarding treatment is crucial and has life changing effect as demonstrated in our case.^{2,3} Stroke patients who present within 4.5 hours of symptom onset should be offered rtPA, MT, or both depending on individual circumstances.⁹ Our case demonstrates that MT can be provided safely and effectively in the third trimester of pregnancy.

References

1. Goyal M, Menon B, Zwam W, et al. Endovascular thrombectomy after large-vessel ischemic stroke: a meta-analysis of individual patient data from five randomised trials. *Lancet* 2016;387:1723-1731. 23.
2. Van Alebeek M, de Heus R, Tuladhar A, et al. Pregnancy and ischemic stroke: a practical guide to management. *Curr Opin Neurol* 2018;31:44-51.
3. Cauldwell M, Rudd A, Nelson-Piercy C. Management of stroke and pregnancy. *Eur Stroke J* 2018;3:227-236.
4. Webb J, Thomsen H, Morcos S. The use of iodinated and gadolinium contrast media during pregnancy and lactation. *Eur Radiol* 2005;15:1234-1240.
5. The American College of Obstetricians and Gynaecologists. Guidelines for Diagnostic Imaging during Pregnancy and Lactation. 2017. Number 723
6. McCollough C, Schueler B, Atwell T. Radiation exposure and pregnancy: when should we be concerned? *RadioGraphics* 2007;27:909-917.
7. James A, Bushnell C, Jamison M, et al. Incidence and risk factors for stroke in pregnancy and the puerperium. *Obstet Gynaecol* 2005;106:509-516.
8. Swartz R, Cayley M, Foley N, et al. The incidence of pregnancy-related stroke: A systematic review and meta-analysis. *Int J stroke* 2017;12:687-697.
9. Intercollegiate Stroke Working Party. National Clinical Guidelines for Stroke. Fifth edition Royal College of Physicians; 2016.