

Cerebral embolism during edoxaban administration for venous thromboembolism in a patient with lung adenocarcinoma

A case report

Satoshi Nakao, MD, Takeshi Masuda, MD, PhD*, Shinjiro Sakamoto, MD, PhD, Kakuhiro Yamaguchi, MD, PhD, Yasushi Horimasu, MD, PhD, Shintaro Miyamoto, MD, PhD, Taku Nakashima, MD, PhD, Hiroshi Iwamoto, MD, PhD, Kazunori Fujitaka, MD, PhD, Hironobu Hamada, MD, PhD, Noboru Hattori, MD, PhD

Abstract

Rationale: The efficacy of direct oral anticoagulants (DOACs) in the treatment and prophylaxis of cancer-related venous thromboembolism (VTE) is reportedly similar to that of heparin. However, the effect of DOACs on the prophylaxis of cancer-related arterial thromboembolism (ATE) remains unclear. To our knowledge, we present the 1st case where cerebral ATE was encountered during edoxaban administration for VTE in a patient with lung adenocarcinoma.

Patient concerns: In March 2017, a 63-year-old female was diagnosed with lung adenocarcinoma (cT2aN3M1b stage IVa) along with having asymptomatic VTE; thus, 60 mg/day edoxaban administration was initiated. In addition, 1st-line chemotherapy generated a partial antitumoral response. However, owing to lung cancer progression, a secondary treatment with pembrolizumab administration was initiated. The patient suddenly experienced aphasia 11 days after pembrolizumab administration.

Diagnosis: The patient was diagnosed as multiple cerebral ATE using brain magnetic resonance imaging. However, VTE recurrence was not observed. Based on the findings of lung cancer progression and increased coagulation, cerebral ATE was diagnosed as Trousseau syndrome.

Interventions: DOAC administration was switched to heparin administration.

Outcomes: Coagulation profile normalized and aphasia improved without any further disease symptoms.

Lessons: We considered that DOACs are effective for the treatment and prophylaxis of VTE but may be insufficient for ATE prevention. Therefore, DOACs should be replaced with heparin to prevent ATE when cancer and coagulation become uncontrollable with DOAC.

Abbreviations: ATE = arterial thromboembolism, CT = computed tomography, DOACs = direct oral anticoagulants, NSCLC = non-small-cell lung cancer, TFs = tissue factors, VTE = venous thromboembolism.

Keywords: cerebral arterial thromboembolism, direct oral anticoagulants, heparin, lung adenocarcinoma, venous thromboembolism

1. Introduction

In patients with cancer, it is known that coagulation and platelet aggregation are promoted by the secretion of tissue factors (TFs),

mucin, and cysteine-protease in the bloodstream by cancer cells. These hematologic abnormalities induce venous and arterial thromboembolism, and Trousseau syndrome is well known to be a series of symptoms associated with these thromboembolisms.^[1] Evidence-based guidelines, such as the American Society of Clinical Oncology and the British Committee for Standards in Haematology,^[2,3] recommend low-molecular-weight heparin for cancer-related venous thromboembolism (VTE) because of its ability to prevent both hypercoagulation and platelet aggregation. On the contrary, although most of the direct oral anticoagulants (DOACs), such as edoxaban, specifically inhibit the coagulant factor Xa, their efficacy has been found to be similar to that of the conventional anticoagulant therapy (i.e., heparin plus warfarin) in cancer-related VTE treatment.^[4] Additionally, DOACs can be easily administered orally to patients. Therefore, DOACs are thought to be a feasible treatment option for VTE, which was mainly caused by hypercoagulation. However, arterial thromboembolism (ATE) in patients with cancer is caused by both the upregulation of coagulation and activation of platelets.^[1,5] Therefore, the effect of DOACs on the prophylaxis of cancer-related ATE still remains

Editor: N/A.

The authors have no funding and conflicts of interest to disclose.

Department of Respiratory Internal Medicine, Hiroshima University Hospital, Minami-ku, Hiroshima, Japan.

* Correspondence: Takeshi Masuda, Department of Respiratory Internal Medicine, Hiroshima University Hospital, 1-2-3 Kasumi, Minami-ku, Hiroshima 734-8551, Japan (e-mail: ta-masuda@hiroshima-u.ac.jp).

Copyright © 2019 the Author(s). Published by Wolters Kluwer Health, Inc. This is an open access article distributed under the terms of the Creative Commons Attribution-Non Commercial-No Derivatives License 4.0 (CCBY-NC-ND), where it is permissible to download and share the work provided it is properly cited. The work cannot be changed in any way or used commercially without permission from the journal.

Medicine (2019) 98:12(e14821)

Received: 13 November 2018 / Received in final form: 25 January 2019 /

Accepted: 5 February 2019

<http://dx.doi.org/10.1097/MD.0000000000014821>

unclear. In this case, the patient was administrated DOACs for non-small-cell lung cancer (NSCLC)-related VTE as secondary prophylaxis. However, she developed cerebral ATE with lung cancer progression, which improved following intravenous heparin, and no recurrence was observed. This is the 1st case to indicate that DOACs may be insufficient for preventing cancer-related ATE in patients with NSCLC.

2. Case presentation

In March 2017, a 63-year-old woman with no smoking or major medical history was incidentally observed to have a tumor in the left upper lobe on a computed tomography (CT) scan. As a result of a detailed examination, she was diagnosed as stage IVA (cT2aN3M1b) lung adenocarcinoma without active mutation, and the PD-L1 tumor proportion score was 90%. Brain metastasis and cerebral infarction were not observed at this time. Thereafter, chemotherapy with carboplatin and pemetrexed was initiated. Simultaneously, the patient had high D-dimer levels and was diagnosed with asymptomatic VTE such as deep vein thrombosis and pulmonary thromboembolism. Therefore, anticoagulation therapy with 60 mg/day edoxaban was initiated. The patient showed a partial response to chemotherapy, and D-dimer level decreased to reach the normal range. However, the lung cancer subsequently progressed. As a secondary treatment, pembrolizumab administration was initiated. At this point, plasma D-dimer levels increased to 2.3 $\mu\text{g/mL}$. On day 11 of pembrolizumab administration, she suddenly developed motility aphasia, and other neurologic examinations were repetitive defect as a higher brain dysfunction, right facial paralysis, right hypoglossal nerve paralysis. Blood test showed a further increase in plasma D-dimer levels (25.5 $\mu\text{g/mL}$) and a sustained increase in carcinoembryonic antigen. Thrombotic predisposition, such as protein C/S deficiency or antiphospholipid antibody syndrome, was not detected. Diffusion-weighted magnetic resonance imaging revealed acute ischemic lesions in the left temporal lobe (Fig. 1A). Additionally, several small ischemic lesions occurred in the left occipital lobe and right parietal lobe (Fig. 1B, C). However, vascular stenosis was not observed on a magnetic resonance angiogram. Findings from carotid ultrasonography and 24-hour electrocardiographic monitoring were normal. Transesophageal echocardiography

showed no *non-bacterial thrombotic endocarditis* findings and patent foramen ovale. From these observations, the cerebral infarction was diagnosed as Trousseau syndrome. Contrast-enhanced CT showed a large tumor, measuring 48 \times 20 mm in size, in the left upper lobe and an enlarged mediastinal lymph node. VTE that existed during the initial diagnosis was not observed on the CT scan.

For treating ATE lesions, edoxaban administration was switched to intravenous heparin administration at a dosage of 15,000 units/day. On day 11 of admission, the mode of administration was changed to a subcutaneous one. Consequently, plasma D-dimer levels rapidly began to decrease (being 1.1 $\mu\text{g/mL}$ on day 17 after heparin administration). Aphasia and cranial nerve symptoms also improved completely. Additionally, pembrolizumab administration achieved a partial response. On September 2018, lung cancer progression and Trousseau syndrome recurrence were not observed.

3. Discussion

Trousseau syndrome is well known to be a series of symptoms associated with VTE and systemic ATE especially in the brain owing to a hypercoagulable state caused by malignant tumors.^[1] Here, our patient was administrated with edoxaban as secondary prophylaxis for NSCLC related-VTE. However, lung cancer continued to progress, and cerebral ATE occurred without VTE recurrence. Previously, 2 cases of patients with gastric cancer who developed cerebral ATE during edoxaban administration for VTE treatment have been reported.^[5] However, to the best of our knowledge, ours is the 1st report on ATE development in a patient with NSCLC receiving edoxaban.

The mechanism of cancer-associated hypercoagulation has not yet been fully elucidated. Currently, it has been reported that cancer cells secreted TFs into the bloodstream, and the formation of TF-factor VIIa complex induces fibrin formation and platelet aggregation by producing thrombin. Moreover, cancer cells produce mucin, which in turn induces platelet aggregation by direct prothrombin activation and binding with selectin present on the platelet surface. Furthermore, cancer cells secreted plasminogen activator inhibitor-1, which inhibits fibrinolysis, and tumor-associated cytokines which induce the activation of monocytes, platelets, and vascular endothelial cells.^[1,6]

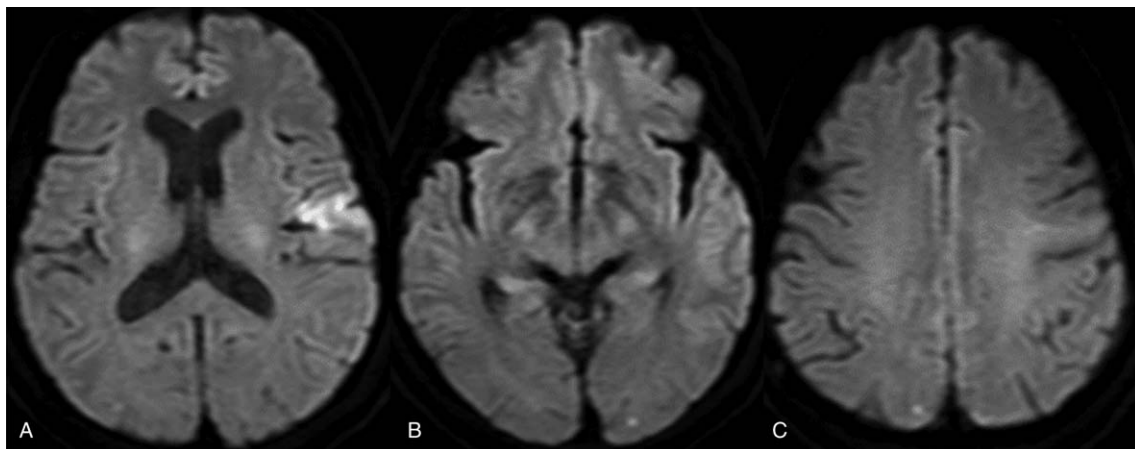


Figure 1. Diffusion-weighted magnetic resonance imaging revealed acute ischemic lesions in the left temporal lobe (A). Several small ischemic lesions were observed in the left occipital lobe and right parietal lobe (B, C).

Most of the DOACs specifically inhibit factor Xa. Thus, DOACs are considered to be effective for treating and preventing cancer-related VTE, which is the main cause of hypercoagulation. However, ATE in patients with cancer is caused by both the upregulation of coagulation and activation of platelets.^[1,5] Therefore, DOACs would be insufficient for preventing ATE. This is the reason why cerebral ATE occurred during DOAC administration in this present case. Contrastingly, heparin has various anticoagulant actions; it binds to antithrombin and inhibits the activation of Xa and thrombin. Additionally, heparin suppresses platelet activity by inhibiting the binding of mucin and selectin and inhibits vascular endothelial activation by tumor-associated cytokines.^[1,7]

The standard anticoagulant treatment for VTE manifesting as Trousseau syndrome is the administration of low-molecular weight heparin, as recommended in the evidence-based guidelines. Recently, DOACs, such as edoxaban, have been made available for VTE treatment. In a previous clinical trial involving patients with VTE, it was observed that compared with the warfarin group, the DOAC group showed similar effectiveness and lesser hemorrhagic complications. Furthermore, the therapeutic range and safety margin of DOAC are wider than those of warfarin.^[8] Additionally, in the “Hokusai VTE-cancer study,” it was revealed that the efficacy of edoxaban in inhibiting VTE recurrence and hemorrhagic complications in patients with cancer was not inferior.^[9] Therefore, DOACs are considered to be an acceptable option for cancer-related VTE. However, the effectiveness of DOACs in the prophylaxis of ATE, manifesting as Trousseau syndrome, needs to be examined in future studies.

In our case, multiple cerebral ATE occurred immediately after the administration of pembrolizumab, thereby indicating it to be the main cause of ATE. Actually, there has been a case report to suggest that pembrolizumab accelerates coagulability.^[10] However, pembrolizumab is generally known to have no direct effect on the promotion of thrombogenic tendency. There may have been another reason behind the patient experiencing ATE. Cancer cells tend to get disintegrated owing to the antitumor effect of pembrolizumab, and substances derived from cancer cells that cause hypercoagulation are temporarily released into the bloodstream; consequently, thrombus formation occurs. It seems that this underlying mechanism may have contributed toward multiple cerebral embolism in this case.

To the best of our knowledge, ours is the 1st case report revealing that DOACs are effective in NSCLC-related VTE treatment but may be insufficient in ATE prevention. Therefore, DOACs must be switched with heparin for preventing ATE when cancer and coagulation become uncontrollable during DOACs administration.

Author contributions

Writing – original draft: Satoshi Nakao.

Writing – review & editing: Takeshi Masuda, Shinjiro Sakamoto, Kakuhiro Yamaguchi, Yasushi Horimasu, Shintaro Miyamoto, Taku Nakashima, Hiroshi Iwamoto, Kazunori Fujitaka, Hironobu Hamada, Noboru Hattori.
Takeshi Masuda orcid: 0000-0003-3557-0049.

References

- [1] Varki A. Trousseau’s syndrome: multiple definitions and multiple mechanisms. *Blood* 2007;110:1723–9.
- [2] Lyman GH, Bohlke K, Khorana AA, et al. Venous thromboembolism prophylaxis and treatment in patients with cancer: American Society of Clinical Oncology clinical practice guideline update 2014. *J Clin Oncol* 2015;33:654–6.
- [3] Watson HG, Keeling DM, Laffan M, et al. Guideline on aspects of cancer-related venous thrombosis. *Br J Haematol* 2015;170:640–8.
- [4] Vedovati MC, Germini F, Agnelli G, et al. Direct oral anticoagulants in patients with VTE and cancer: a systematic review and meta-analysis. *Chest* 2015;147:475–83.
- [5] Gon Y, Sakaguchi M, Takasugi J, et al. Ischemic stroke in cancer patients treated with direct oral anticoagulants for venous thromboembolism. *Thromb Res* 2017;154:16–8.
- [6] Loreto MF, De Martinis M, Corsi MP, et al. Coagulation and cancer: implications for diagnosis and management. *Pathol Oncol Res* 2000;6:301–12.
- [7] Wahrenbrock M, Borsig L, Le D, et al. Selectin-mucin interactions as a probable molecular explanation for the association of Trousseau syndrome with mucinous adenocarcinomas. *J Clin Invest* 2003;112:853–62.
- [8] Van Es N, Coppens M, Schulman S, et al. Direct oral anticoagulants compared with vitamin K antagonists for acute venous thromboembolism: evidence from phase 3 trials. *Blood* 2015;124:1968–76.
- [9] Raskob GE, van Es N, Verhamme P, et al. Edoxaban for the treatment of cancer-associated venous thromboembolism. *N Engl J Med* 2017;378:615–24.
- [10] Horio Y, Takamatsu K, Tamanoi D, et al. Trousseau’s syndrome triggered by an immune checkpoint blockade in a non-small cell lung cancer patient. *Eur J Immunol* 2018;48:1764–7.