

Insurance and Flow-Alteration Superficial Temporal Artery to Middle Cerebral Artery (STA-MCA) Bypass in Management of Complex Anterior Intracranial Circulation Aneurysms in Postendovascular Era

Amol Raheja, Ashish Suri, Sanjeev A. Sreenivasan, Raghav Singla

■ **BACKGROUND:** Optimal management of complex anterior circulation aneurysms is an enigmatic challenge because of frequent involvement of major vessel bifurcation, choroidal vessels, and lenticulostriate/thalamostriate perforators. Cerebral ischemia associated with prolonged clipping time is a major concern pertinent to their surgical management, especially in patients with poor cross-flow. To circumvent this hurdle, single/double-barrel low-flow superficial temporal artery (STA) to middle cerebral artery (M3/M4-MCA) can be performed, which can maintain distal cerebral perfusion while facilitating safe clip reconstruction of complex MCA and supraclinoidal internal carotid artery (ICA) aneurysms involving ICA bifurcation or supraclinoidal ICA aneurysms with poor cross-circulation—insurance bypass, as well as supplement/alter blood flow after MCA aneurysm trapping—flow-alteration bypass.

■ **METHODS:** A retrospective chart review of consecutive neurosurgical patients operated over 2 years at this center was performed. Patients with complex MCA and ICA aneurysms who were treated with STA-MCA bypass were included. The clinical profile, pre- and postoperative images, intraoperative imaging, and patient outcomes were recorded. Surgical reconstruction of aneurysm was the treatment of choice due to involvement of choroidal/thalamostriate perforators, MCA/ICA bifurcation, complex aneurysm morphology, or dissecting/thrombosed nature of aneurysm. STA-MCA low-flow bypass was performed using M3/M4 segment of MCA as the recipient in anticipation of prolonged temporary clipping time on M1-MCA,

supraclinoidal ICA aneurysms with suspected ICA terminus involvement, or need for possible trapping of fusiform MCA aneurysm. The saccular/fusiform part of aneurysm was clip reconstructed and the partially thrombosed dissecting segment was opened for thrombectomy and trapped using proximal and distal clips after good patency of bypass was confirmed. The distal MCA flow was restored adequately and confirmed intraoperatively using indocyanine green angiography and micro-Doppler ultrasonography.

■ **RESULTS:** MCA ($n = 4$) and supraclinoid-ICA ($n = 1$) aneurysms were managed successfully using this strategy, which involved 6 STA-MCA bypass procedures (insurance and flow-alteration bypass, 3 each). Postoperative check angiograms demonstrated patent bypass in all 5 patients. Four patients had favorable outcome (modified Rankin Scale score 0/1); one had recovering hemiparesis and aphasia (modified Rankin Scale score 4).

■ **CONCLUSIONS:** This series highlights the surgical strategy and safety for successfully managing complex MCA and ICA aneurysms using low-flow STA-MCA revascularization procedures.

INTRODUCTION

Intracranial aneurysms are considered complex if associated with any one of the following: large or giant (>1.5 cm diameter) size, unfavorable angioanatomy (involvement of

Key words

- Internal carotid artery aneurysms
- Middle cerebral artery aneurysms
- STA-MCA bypass
- Surgical strategy
- Technical nuances

Abbreviations and Acronyms

- BOT:** Balloon occlusion test
DSA: Digital subtraction angiography
ICA: Internal carotid artery
ICG: Indocyanine green
MCA: Middle cerebral artery

mRS: Modified Rankin Scale score

STA: Superficial temporal artery

Department of Neurosurgery, All India Institute of Medical Sciences, New Delhi, India

To whom correspondence should be addressed: Ashish Suri, M.B.B.S., M.Ch., D.N.B.
[E-mail: surineuro@gmail.com]

Citation: World Neurosurg. (2019).

<https://doi.org/10.1016/j.wneu.2019.03.109>

Journal homepage: www.journals.elsevier.com/world-neurosurgery

Available online: www.sciencedirect.com

1878-8750/\$ - see front matter © 2019 Elsevier Inc. All rights reserved.

lenticulostriate perforators or choroidal vessels by the aneurysm or the presence of aberrant branch arteries originating from aneurysmal sac), previous endovascular or surgical treatment, aneurysmal shape (dissecting, fusiform, serpentine, or very broad neck saccular lesions), mycotic or infectious etiology, intraluminal thrombosis, atherosclerotic thickening of the neck, or calcification.^{1,2} Steinberg et al.³ demonstrated that conservative management of giant complex aneurysms exhibit poor natural history. Five-year morbidity and mortality rates of giant complex aneurysms have been reported to reach as high as 80% on conservative management with radiological surveillance. These patients experience complications from perforator thrombosis, subarachnoid hemorrhage, or mass effect.¹⁻³ Given their poor natural history and high rate of progression, giant intracranial aneurysms warrant aggressive treatment once identified. Multiple available treatment options for giant complex aneurysms include trapping with extracranial–intracranial bypass, aneurysm thrombectomy with clip reconstruction, aneurysm excision with in situ bypass, combined endovascular treatment and bypass surgery, and pipeline embolization devices.^{1,4-9} Despite the best of treatment options used from the current neurosurgical armamentarium, unfavorable outcomes often are seen in the management of such complex aneurysms.^{1,4-9}

Despite the advances in endovascular management, microsurgery still remains an invaluable treatment option for complex intracranial anterior circulation aneurysms.^{1,5-7,10} The surgical modality and operative strategy for complex intracranial aneurysms is determined by aneurysm morphology, location, and extent; vascular anatomy and involvement of lenticulostriate/choroidal vessels by aneurysm neck; rupture status; and hemodynamic characteristics of each patient.^{1,2,5-7,10,11}

Over the decades, evolution in the surgical management of complex anterior circulation intracranial aneurysms has witnessed a paradigm shift from Hunterian ligation of internal carotid artery (ICA) to microsurgical primary reconstruction or vessel occlusion (proximal/distal/complete trapping) with/without revascularization procedures.^{1,2,5-7,10,11} Bypass procedure is contemplated whenever either a parent artery is deliberately sacrificed or a prolonged temporary clipping time on proximal vessel is anticipated or there is a positive balloon occlusion test (BOT), especially for ICA aneurysms.^{1,2,5-7,10,11} However, a high incidence of false-negative BOTs in intracranial aneurysms provides an impetus for many neurosurgeons to plan and proceed with a bypass procedure based on the each patient's merits rather than the mere presence or absence of radiologic collateral circulation on cross-clamping. The goal of a revascularization procedure is to permanently reperfuse or transiently maintain perfusion in the involved vascular territory to prevent cerebral ischemia or infarction.^{1,2,5-7,10,11} The requirement and choice of revascularization procedure depends on the extent of collaterals on angiography, caliber of the donor/recipient vessels, expected duration of temporary vessel occlusion for primary reconstruction of aneurysm, and the anatomical location of planned vessel sacrifice for aneurysmal trapping.^{1,2,5-7,10,11}

Management of complex middle cerebral artery (MCA) aneurysms is especially challenging because of the fact that MCA is an end artery and is vulnerable to ischemic complications after therapeutic occlusions. Moreover, of the 3 main cerebral arteries, the MCA supplies the most eloquent and largest territories in the

cerebral hemispheres. A revascularization procedure should be contemplated for complex MCA aneurysm surgery while aneurysmal trapping (flow alteration/replacement bypass), or preserving distal perfusion during prolonged temporary parent artery occlusion (insurance/protective bypass), or less commonly as a salvage procedure after inadvertent iatrogenic injury to one of the major MCA branches (salvage/rescue bypass).^{1,2,5-7,10,11}

The current literature primarily deals with flow-alteration bypass, conventionally used to treat complex intracranial aneurysms.^{1,2,5-7,10,11} These can be both extracranial to intracranial i.e., extracranial–intracranial, low-flow superficial temporal artery (STA)-MCA bypass and high-flow interpositional bypass with cervical carotid artery, and reconstructive intracranial-to-intracranial bypass with end-to-end anastomosis after aneurysm excision, in-situ side-to-side bypass between parallel branches, and the double-reimplantation technique.^{1,2,5-7,10,11}

On the contrary, insurance bypass comprise mostly extracranial–intracranial STA-MCA low-flow bypasses, which are primarily performed to support MCA territory during its prolonged temporary occlusion or during the installation of high-flow cervical carotid artery to M2-MCA bypass.¹¹⁻¹³ STA-MCA bypass is a preferred approach for such cases because of the ease of harvesting the donor STA vessel, good-caliber match with the recipient M3/M4-MCA vessel, minimal temporary clipping duration, excellent long-term patency rates, nonrequirement of separate skin incision, and interpositional graft.¹⁴ There is dearth of literature on the role of insurance/protective bypass in managing complex intracranial aneurysms, especially pertaining to MCA aneurysms.¹¹⁻¹³ We present our initial experience and current philosophy regarding the importance of revascularization procedures in successful surgical management of complex intracranial anterior circulation aneurysms, with special emphasis to MCA aneurysms, and emphasize the usefulness of insurance and flow-alteration STA-MCA bypass procedures in facilitating a favorable outcome.

METHODS

Study Design

A retrospective chart review of consecutive neurosurgical patients operated at our tertiary care referral hospital during a period of 2 years, from March 2016 to February 2018, was performed. The in-hospital data were collected from a computerized patient record system and follow-up data were compiled using either outpatient visits or telephonic interviews. We included patients with complex intracranial anterior circulation aneurysms (irrespective of their age and subarachnoid hemorrhage grade) managed surgically using STA-MCA bypass, clip reconstruction, and/or aneurysmal trapping. Clinical profile, operative videos, intraoperative indocyanine green (ICG) angiography images, preoperative and postoperative imaging, and patient outcomes were recorded. The patency of bypass graft was assessed intraoperatively using ICG angiography and/or micro-Doppler flow measurements and during follow-up period by digital subtraction angiography (DSA).

Surgical Planning and Execution

A detailed preoperative planning, based on 3-dimensional reconstruction of DSA, is done to evaluate aneurysm site/extent, its

relevant anatomy, involvement of lenticulostriate or choroidal vessels by aneurysm neck, aberrant vessel arising from aneurysmal sac, and the degree of cross-flow from contralateral cerebral vasculature. Surgical planning for the need and execution of bypass procedure was carefully tailored to individual patient's requirement based on aneurysm morphology and hemodynamic characteristics (including the degree of cross flow, aneurysm relation with perforators, and involvement of major branch by aneurysm neck) for reducing iatrogenic morbidity. Ideally, patients who are likely to benefit from STA-MCA bypass have complex MCA aneurysms or ICA aneurysms with poor cross-flow or ICA aneurysms involving bifurcation irrespective of the cross circulation.

The precise role of STA-MCA bypass, i.e., insurance/flow-alteration and single-/double-barrel bypass (using frontal and/or parietal STA divisions) should be clearly defined before surgery. Recipient vessel is typically distal MCA branches—M3/M4 segment, as they have a better-caliber match with the donor STA vessel and also can sustain temporary clipping for a longer duration than a more proximal M1/M2 vessel. Adequate preparations and precautions should be taken during the operative procedure to ensure minimal overall ischemia time.

Once the bypass is completed using meticulous 10-0 nylon interrupted suturing technique and bypass patency is confirmed intraoperatively, attention is further diverted to tackle the aneurysm. The philosophy for managing complex aneurysms is that the simplest surgical approach feasible is usually the best approach. In other words, one should attempt clip reconstruction of aneurysm as the first choice, followed by more complex options such as proximal/distal occlusion or complete aneurysmal trapping or excision if simpler techniques are not feasible. In many cases, even the giant saccular/fusiform aneurysms with broad neck can be made clippable by simple technique of low-flow electrocoagulation under continuous saline irrigation.

RESULTS

Case 1

A 65-year-old hypertensive woman presented with sudden-onset severe headache and right upper limb weakness for 2 weeks. DSA demonstrated anterior communicating artery aneurysm and dissecting left MCA bifurcation aneurysm (**Figure 1, Table 1**). A double-barrel bypass, one intended as flow-alteration bypass and the other one as insurance bypass, was done between the STA and two M3 segments of MCA (**Video 1**). MCA bifurcation aneurysm was clipped along with intentional occlusion of inferior M2 division arising from aneurysmal dome (**Table 2**). ICG angiography was used to confirm bypass patency of flow-alteration bypass; insurance/temporary bypass flow was not seen as expected once normal circulation was restored. Check angiogram demonstrated patent flow-alteration bypass during follow-up. At 15 months' follow-up, she had near-complete recovery from her preoperative weakness and was able to carry out her usual duties and activities of daily living without any assistance, i.e., modified Rankin Score (mRS) score 1.



Video available at
www.sciencedirect.com

Case 2

A 2-year-boy presented with history of loss of consciousness and sudden-onset left hemiparesis at 2 months of age, which had gradually improved (**Table 1**). DSA demonstrated a right giant fusiform MCA bifurcation aneurysm (**Figure 2**). A single-barrel insurance STA—M3 segment MCA bypass was performed (**Table 2**). Clip reconstruction was done using straight clip and fenestrated clips. A check angiogram demonstrated well clipped aneurysm with no residual. Interestingly the insurance STA-MCA bypass remained patent in the postoperative period as well, suggesting its additional role of flow-augmentation as per the requirement of flow dynamics. The child was neurologically intact until the last follow-up at 18 months; mRS score 0.

Case 3

A 29-year-old man presented with one episode of sudden onset loss of consciousness and right hemiparesis for 2 months. DSA demonstrated a complex giant MCA bifurcation aneurysm extending along the posterior branch of the superior division of M2 (**Figure 3, Table 1**). The saccular segment was clipped; the dissecting segment opened, thrombus removed, and the segment was trapped at both ends (**Table 2**). A flow-augmentation left STA—M3 segment MCA bypass was performed (**Figure 3, Table 2**). Check-DSA demonstrated a well-clipped saccular component of aneurysm with no residual. At 1-one year follow-up, his mRS score was 1.

Case 4

A 65-year-old woman presented with sudden-onset severe throbbing headache and vomiting. DSA revealed a giant fusiform MCA bifurcation aneurysm (**Figure 4, Table 1**). A STA-MCA flow-alteration (replacement) bypass was performed (**Figure 4**). Once the patency of bypass was confirmed using micro-Doppler ultrasonography, partial trapping of aneurysm was performed using 2 curved clips with an attempt to preserve the communication through the aneurysmal sac between both the M2-MCA divisions arising from the aneurysmal sac wall. Intraoperative ICG angiography was instrumental in demonstrating the patent bypass filling larger M2-MCA division as well as occlusion of vascular communication between two M2-MCA divisions via aneurysmal sac, which led us to reposition aneurysm clips to maintain filling of inferior M2-MCA division (**Figure 4**). Postoperatively, the patient developed contralateral hemiparesis and aphasia, necessitating decompressive craniectomy. A check angiogram showed no evidence of filling of aneurysm, and patent parietal STA-MCA flow-alteration bypass. At 3 months follow-up, she gradually recovered her motor strength. She underwent a right occipital ventriculoperitoneal shunt and cranioplasty with autologous bone at subsequent follow up visit. Her Glasgow Come Scale score was E4 V1 M6 at last known follow-up, and she had moderately severe disability; mRS score 4.

Case 5

A 37-year-old woman presented with a sudden-onset excruciating headache in the left frontal region that gradually became generalized. This was followed by recurrent episodes of headache for the next 6 months along with progressive visual deterioration. DSA confirmed the presence of a large fusiform left supraclinoid

ICA aneurysm extending up to the ICA bifurcation (**Figure 5**, **Table 1**). Parietal STA to M4-MCA insurance bypass was performed. ICG angiography was used to confirm the bypass patency intraoperatively (**Figure 5**). Clip reconstruction of the aneurysm was performed (**Table 2**, **Figure 5**). Postoperatively, the patient developed mild weakness on the right side of the face and upper limb. Postoperative computed tomography of the head revealed a small infarct in the lenticular nucleus and adjacent internal capsule. A check DSA revealed a well-clipped ICA aneurysm with no residual and patent STA-MCA bypass, suggesting that the insurance bypass can also function as a flow-

augmentation (flow-alteration) bypass as per the circulatory flow demands (once the temporary clips are removed), providing an additional safety mechanism in place in case of inadvertent vasospasm or sluggish blood flow through the reconstructed aneurysmal wall or distal vessels. Her symptoms gradually improved and gained a mRS score of 1 at 6 months.

Summary of Results

Summarizing our results, a total of 4 ruptured complex MCA and 1 supraclinoid unruptured complex ICA aneurysm were managed successfully using this strategy in 5 patients, which involved a total

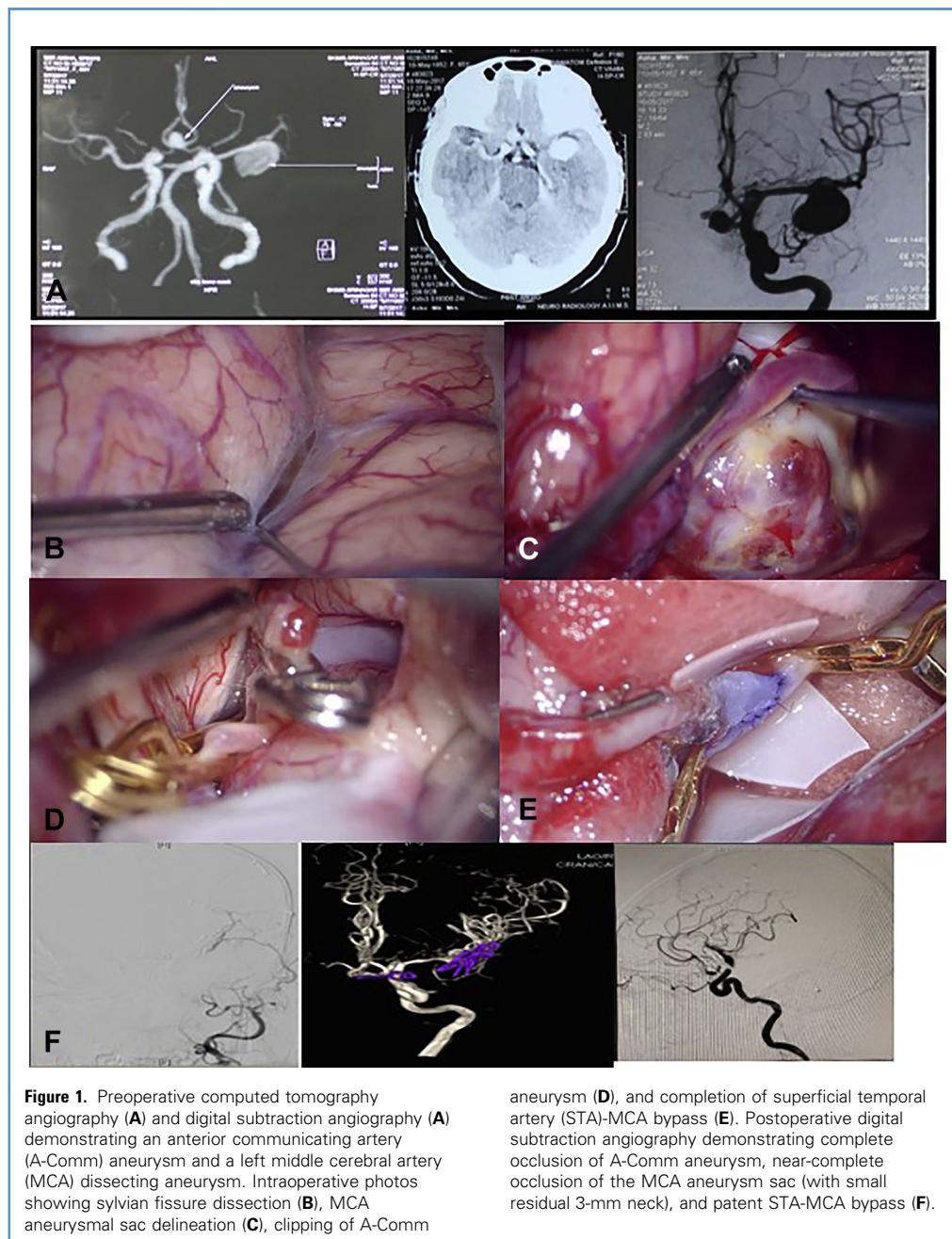


Table 1. Patient Profile and Surgical Procedure

No.	Age, years/Sex	Aneurysm Location	Size, mm	Presentation (SAH Grade)	Neurologic Deficits at Presentation*	Surgical Procedure	Complexity
1	65/F	Left MCA bifurcation + A-Comm	18x 15 (MCA) 9 × 7 (A-Comm)	H&H III+I WFNS III	Hemiparesis 4/5	Pterional + double STA- MCA bypass (IN + FA) + clipping of aneurysms	Large, dissecting, partly thrombosed, multiple
2	2/M	Right MCA bifurcation	28 × 20	H&H III Seizures	Nil	Right FTOZ + STA-MCA bypass (IN) + clip reconstruction	Giant, fusiform, partly thrombosed
3	29/M	Left MCA bifurcation (extending along superior division M2-MCA)	53 × 14	H&H III WFNS III	Hemiparesis 4/5	Left FTOZ + STA-MCA bypass (FA) + clip reconstruction of saccular part, trapping of dissecting aneurysm	Giant with separate saccular and dissecting components, partly thrombosed
4	65/F	Left MCA bifurcation	26 × 21	H&H II WFNS I	Nil	Left FTOZ + STA-MCA bypass (IN converting into FA) + trapping	Giant, fusiform, involving the branch origins
5	37/F	Left supraclinoid ICA	22 × 19	Visual deterioration (Unruptured)	Va 6/24; field cuts	Left FTOZ + Neck control + extradural clinoidectomy + STA- MCA bypass (IN) + reconstruction of aneurysm	Large, fusiform, location

SAH, subarachnoid hemorrhage; F, female; MCA, middle cerebral artery; A-Comm, anterior communicating artery; H&H, Hunt and Hess grade; WFNS, World Federation of Neurosurgical Societies grading; STA-MCA, superficial temporal artery-to-middle cerebral artery; IN, insurance bypass; FA, flow-alteration bypass; M, male; FTOZ, frontotemporal craniotomy with orbitozygomatic osteotomy; ICA, internal carotid artery; Va, visual acuity.

*Motor power assessment based on Medical Research Council (MRC) grading.

of 6 STA-MCA bypass procedures (insurance and flow-alteration bypass, 3 each). Temporary clipping time during each bypass procedure (M₃/M₄ MCA) and aneurysm reconstruction (M₁/M₂ MCA or ICA) ranged from 10 to 22 minutes and 4 to 36 minutes respectively. Postoperative check angiograms demonstrated patent bypass in all 5 patients. Aneurysm was completely occluded in all patients except a small 3-mm residual noticed in case 1. Four patients had favorable outcome (mRS score 0/1); 1 had recovering hemiparesis and aphasia (mRS score 4).

DISCUSSION

As compared with surgical clipping, the use of conventional endovascular techniques for complex anterior circulation

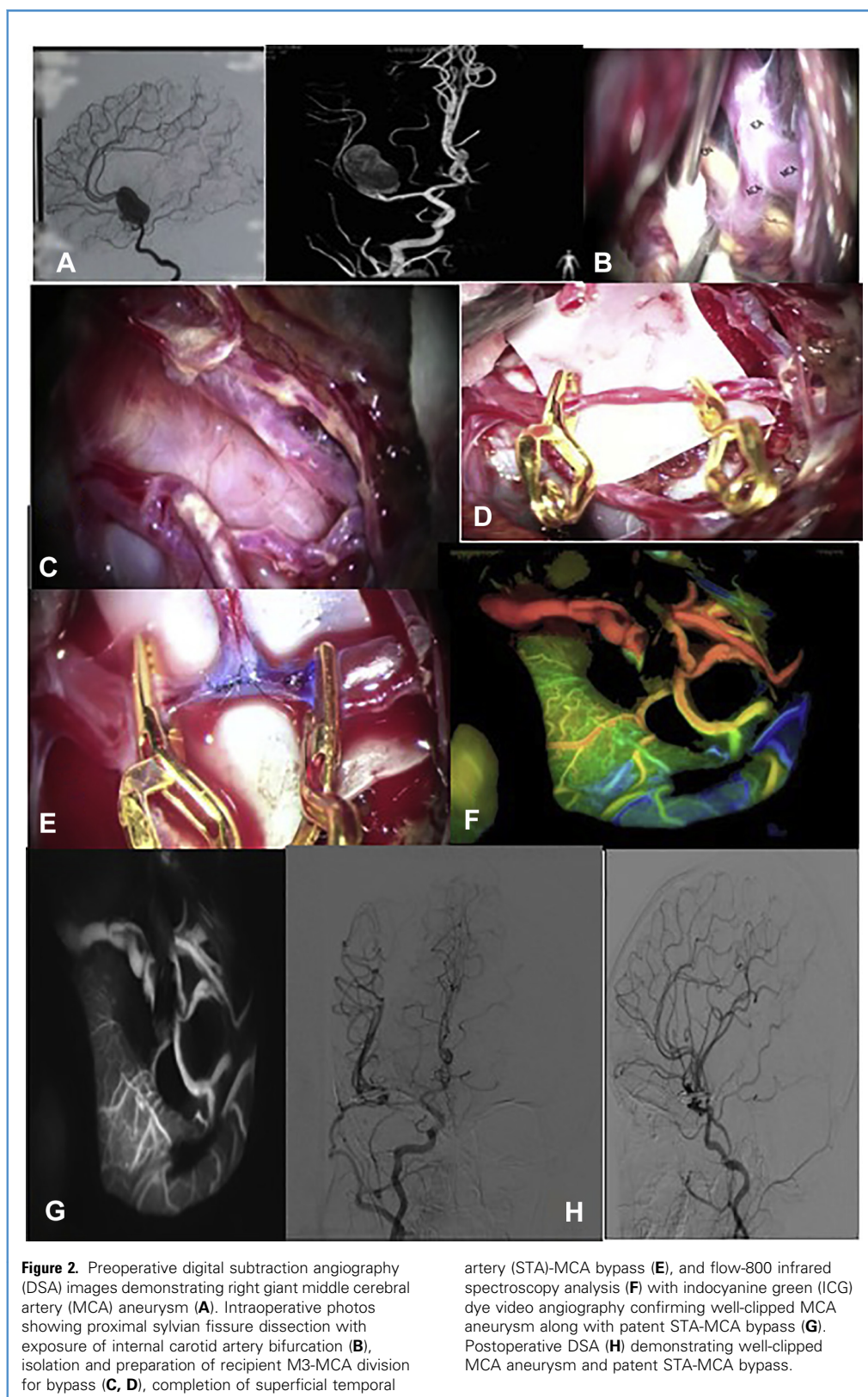
intracranial aneurysms (in particular MCA aneurysms) is still limited.^{5,7,15} The pipeline embolization device, a more recent innovation, represents an important advancement to tackle such complex aneurysms, targeting primary vessel reconstruction rather than endovascular occlusion.^{4,8,9} However, even flow-diverters have been associated with perforator infarcts, and their use in acute subarachnoid hemorrhage remains a matter of ongoing debate.^{4,8,9} Because the goal of aneurysm surgery is both aneurysm exclusion and blood flow reconstruction, cerebral revascularization remains a major treatment option whenever a prolonged temporary occlusion or definitive occlusion of parent vessel is required or there is a positive BOT and involvement of bifurcation (especially for ICA aneurysms).^{6,10,11} Intraoperative hemodynamic and electrophysiological assessment plays an important role in

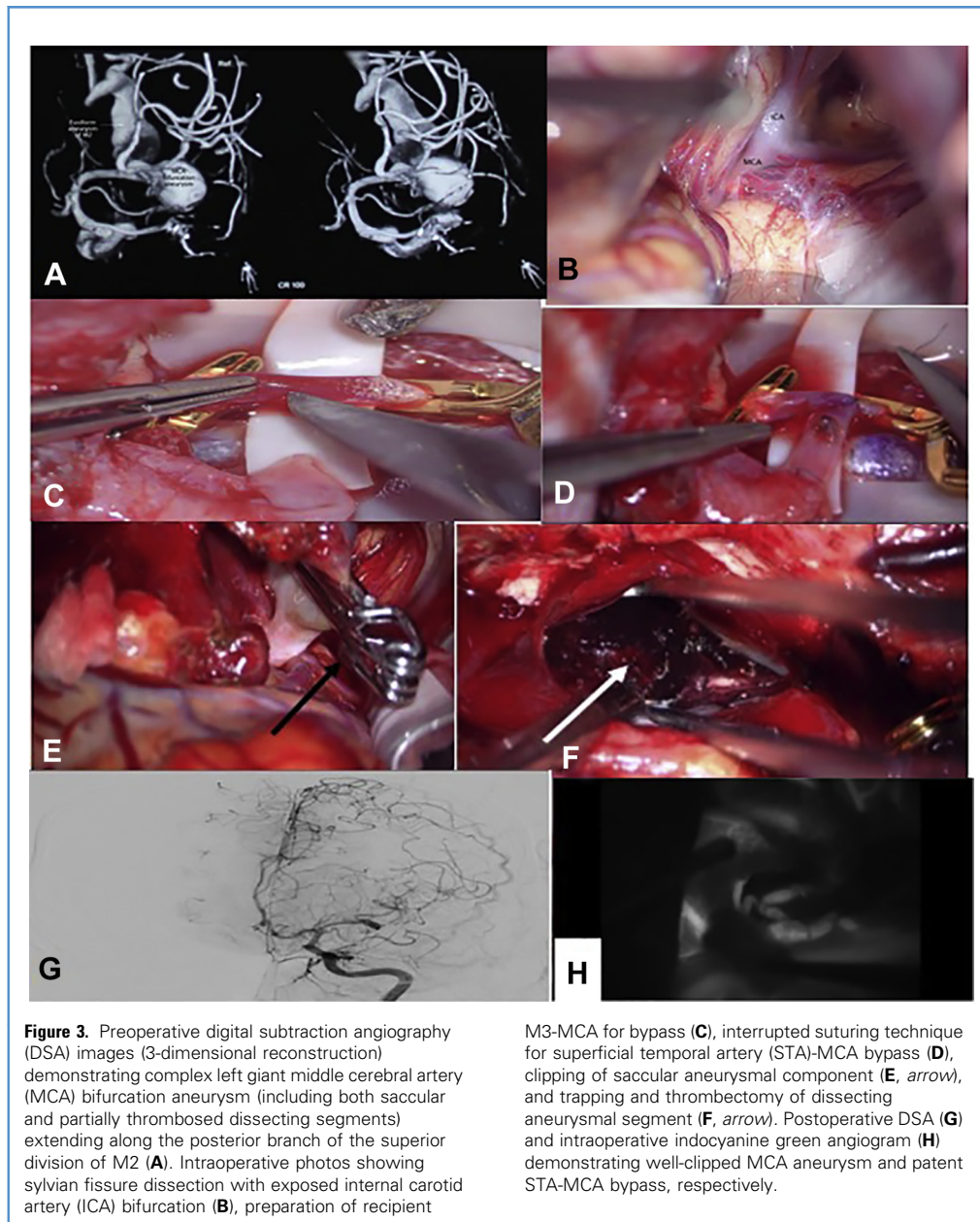
Table 2. Outcome Profile

Bypass No. (Single/Double)	Bypass Site*	Temporary Clip Time During Bypass	Temporary Clip Time During Aneurysm Reconstruction Indocyanine Green Dye	Patency of Bypass	Aneurysm Occlusion	Neurologic Outcome (mRS Score) at 6 Months/Last Follow-Up
1	Double barrel STA-M3 MCA	20 + 14	10 + 3	Patent (FA)	Small residual 3 mm	1
2	Single STA-M3 MCA	15	4	Patent	Complete	0
3	Single STA-M3 MCA	22	30 (maximum in a single stretch)	Patent	Complete	1
4	Single STA-M3 MCA	10	8	Patent	Complete	4
5	Single STA-M4 MCA	14	36	Patent	Complete	1

mRS, Modified Rankin Scale; STA, superficial temporal artery; MCA, middle cerebral artery.

*One bypass (flow alteration) out of double-barrel bypasses remained patent. Insurance bypass became nonfunctional soon after normal circulation was restored.



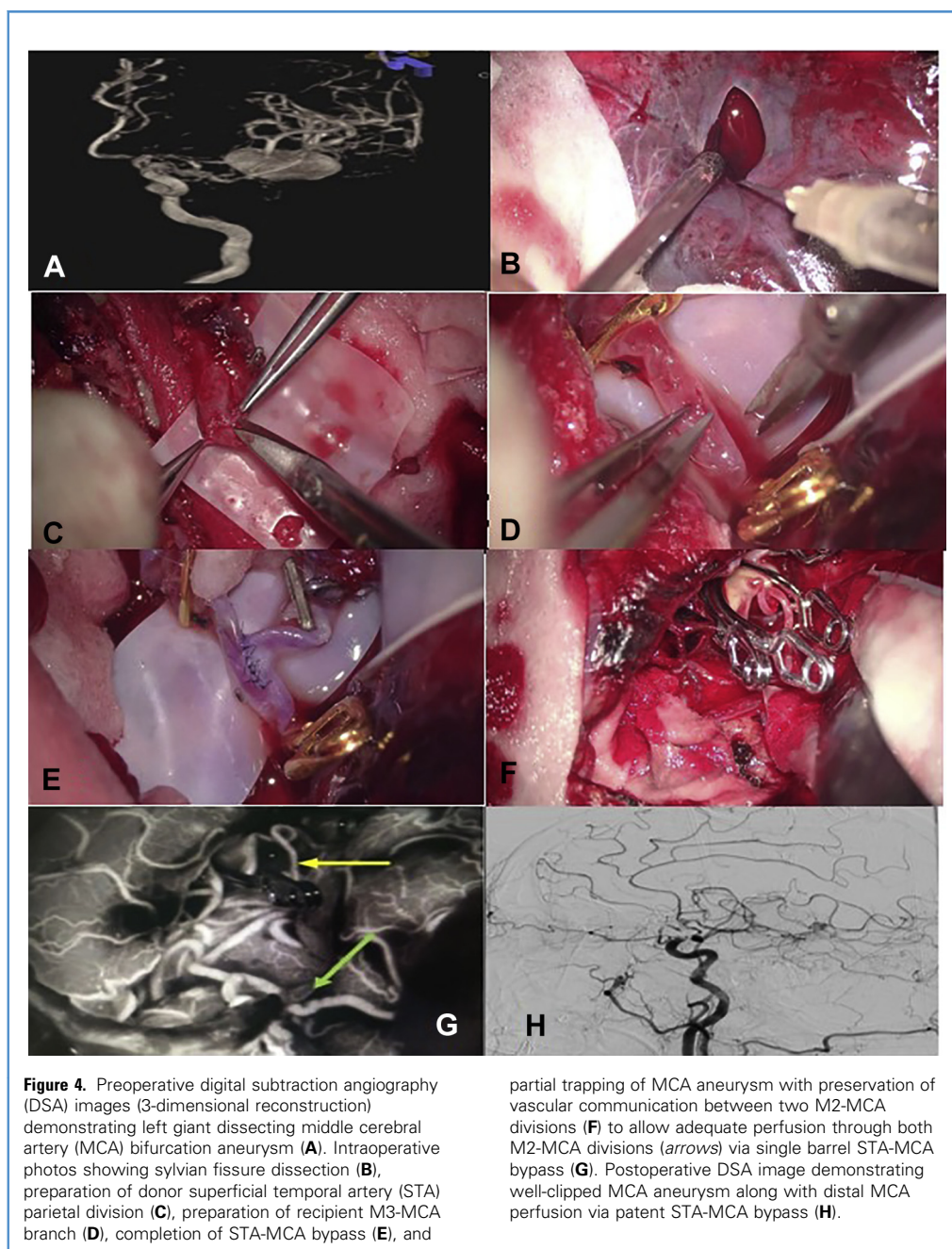


predicting the possibility of iatrogenic cerebral ischemia. Therefore, correspondingly, cerebral revascularization can be either used temporarily as a “protective/insurance” bypass, definitively as a “flow alteration/replacement bypass,” or less commonly as an emergency procedure, “salvage/rescue bypass,” after inadvertent iatrogenic injury to one of the major branch vessels.^{6,10,11} Several important factors governing the construction of an ideal bypass include the amount of flow required, donor/recipient vessels, and microanastomosis technique.^{6,10,11,16}

Flow-Alteration STA-MCA Bypass

The concept of flow alteration bypass relies on the induction of intra-aneurysmal thrombus formation, which prevents further

aneurysm growth and rupture.^{6,10,11,17-19} This can be achieved by either complete or incomplete trapping (proximal/distal outflow occlusion) of aneurysm.^{6,10,11,17-19} Proximal and distal outflow occlusion refers to blocking the parent vessel upstream and downstream of the aneurysm respectively. Proximal inflow occlusion stops the antegrade flow into the aneurysm and allows only retrograde flow into the aneurysm and its perforators, along with the blood supply to the downstream arterial territory from the bypass. On the contrary, distal outflow occlusion stops the downstream blood flow from the aneurysm and allows the antegrade flow into the aneurysm and its perforators. The bypass here supplies only the downstream arterial territory after occluded segment. One of the major concerns for distal outflow occlusion is that it may



paradoxically induce an increase in intra-aneurysmal pressure that might lead to rupture. However, this apprehension has been allayed by Horowitz et al.,¹⁸ using a mathematical model. They demonstrated that increase in intraluminal pressure is well within daily physiological variations and hence should not pose a significantly increased risk of aneurysmal rupture while achieving stagnation of blood flow and clot formation within aneurysm.¹⁸

Esposito et al.^{10,17} hypothesized that the extent of aneurysmal thrombosis after distal occlusion is inversely correlated to the presence, number, location, and size of arterial branches arising

proximal to the site of distal occlusion. We used this strategy of aneurysmal complete trapping and flow-alteration bypass in 3 of our complex MCA aneurysm patients (cases 1, 3, and 4) to achieve favorable outcome (mRS score 1) in 2 (cases 1 and 3), whereas case 4 had a poor outcome (mRS score 4, who developed hemiparesis and aphasia). Interestingly, in case 4 (poor outcome) preoperative planning was for an insurance STA-MCA bypass; however, after the bypass was executed, clip reconstruction of aneurysm was deemed not an appropriate surgical strategy. Hence after the aneurysmal trapping was done, the bypass served the role of

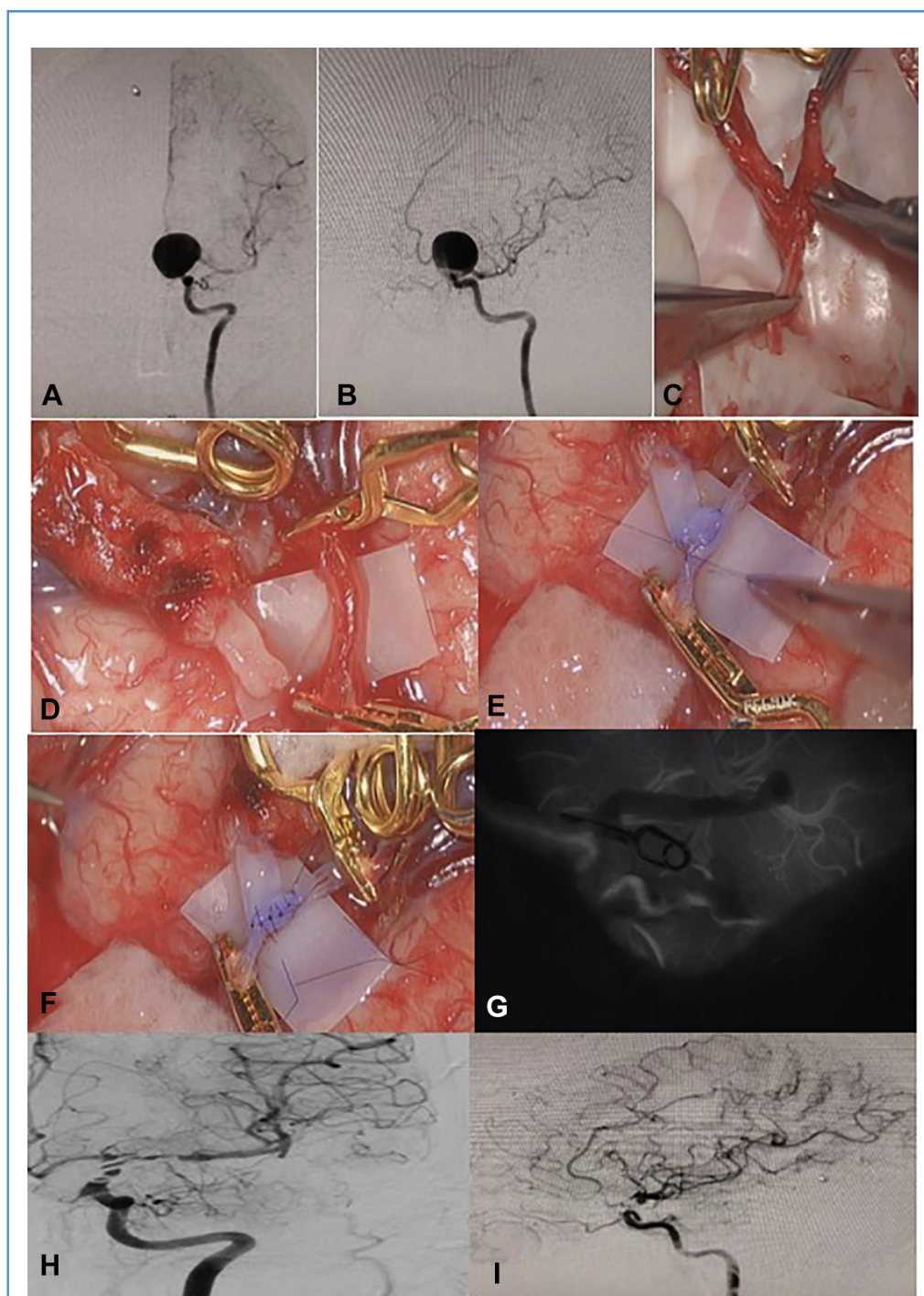


Figure 5. Preoperative digital subtraction angiography (DSA) images demonstrating large fusiform left supraclinoid internal carotid artery (ICA) aneurysm (**A**, **B**) possibly involving ICA terminus (bifurcation). Intraoperative photos showing preparation of donor superficial temporal artery (STA) parietal division (**C**), preparation of recipient M4-MCA branch (**D**),

interrupted suturing technique (**E**) and completion (**F**) of STA-MCA bypass, and flow patency of bypass being confirmed by indocyanine green angiogram (**G**). Postoperative DSA images demonstrating well-clipped ICA aneurysm and distal flow through MCA and anterior cerebral artery (**H**, **I**).

flow-alteration (or replacement) bypass along the superior M2-MCA division. However, the other M2-MCA division (inferior) was underperfused despite clip readjustment, possibly due to sluggish and turbulent blood flow through the residual aneurysmal sac, especially in the setting of thrombogenic and atherosclerotic walls with abnormal endothelium.

We believe that single-barrel STA-MCA bypass is adequate to replace the blood flow provided by either one of the two M2-MCA divisions. Hence in cases requiring sacrifice of either M2 divisions while trapping MCA bifurcation aneurysms, high-flow extracranial–intracranial or intracranial–intracranial bypass with interposition graft may not be the sole option, and a less-invasive option of STA-MCA bypass should be definitely contemplated. On the contrary, a single-barrel STA-MCA bypass may not be a suitable option if both the M2-MCA divisions are compromised while tackling aneurysm (as highlighted in our case 4). Whether a double-barrel STA-MCA bypass can be a solution in such cases needs further exploration. Besides a more objective and quantitative assessment of cerebral blood flow before and after bypass could establish more strict guidelines for feasibility of appropriate bypass strategy.¹⁶

Insurance STA-MCA Bypass

With contrast to flow-alteration STA-MCA bypass, which is quite well described in the literature, there are only handful of descriptions for insurance STA-MCA bypass available (Table 3).^{11–13} Insurance or protective bypass provides a temporary blood supply during direct clip reconstruction of aneurysm, where a prolonged clipping time is anticipated in view of complex aneurysm morphology. In essence, insurance bypass is primarily meant to tide over the intraoperative risk of cerebral ischemia, and its usefulness during the postoperative period is not well understood.^{11–13} In our case 1, insurance bypass became nonfunctional as soon as the parent vessel was reopened and physiological circulation was resumed, essentially emphasizing the fact that the patency of insurance bypass is inversely related to degree of restoration of normal physiological circulation after aneurysm reconstruction. In other words, insurance bypass becomes further more invaluable in case there are any circulatory deficiencies after

surgery, either due to vasospasm or mechanical constriction of vascular channels, which can put the patient at risk of ischemic complications during the postoperative period. This was well highlighted in our cases 2 and 5, where our insurance bypass remained well patent long after the surgery and was further contributing toward flow-augmentation in possibly underperfused brain from parent circulation.

Yet another indication of prophylactic or insurance bypass is the positive BOT (a surrogate for poor cross-flow from anterior and posterior communicating arteries) for complex supraclinoid ICA aneurysms and in patients with ICA aneurysms involving ICA terminus (similar to our case 5), especially where prolonged clipping time along with need of high-flow extracranial-to-intracranial bypass is anticipated and planned.¹² However, preoperative BOT can result in significant false-negative rates and inconsistencies, limiting their potential role in decision making process for management of complex intracranial aneurysms, especially with regards to use of bypass procedures.^{20,21} One of the earliest reports of use of insurance STA-MCA bypass for clipping of giant MCA aneurysms came from Kimura et al.¹³ back in 1993. They applied this innovative technique intraoperatively for a ruptured giant MCA aneurysm to allow prolonged temporary clipping of parent MCA vessel, ultimately culminating into a favorable clinical outcome.¹³

Hara et al.¹¹ documented the efficacy of temporary/insurance bypass in their series of 3 patients with complex MCA aneurysm. We used the similar strategy in 3 patients with complex anterior circulation aneurysms (2 MCA and 1 ICA aneurysms) to achieve favorable outcome in all patients (mRS score 0/1), as is also highlighted by previous literature.^{11–13} Lastly, there is also a role of insurance STA-MCA bypass in supplementing high-flow extracranial-intracranial bypass with interpositional graft, especially in patients at risk of intraoperative ischemia due to prolonged major vessel occlusion irrespective of the BOT results.¹²

Technical Nuances and Surgical Strategy for Management of Complex Intracranial Aneurysms

Among the surgical options for complex ICA and M1/M2-MCA aneurysms, direct clip reconstruction of the aneurysmal neck is

Table 3. Insurance STA-MCA Bypass for Aneurysm Surgery: Review of the Literature

Study	Number of Cases	Age, years/Sex	Clinical Presentation	Aneurysmal Type and Site	Occlusion Time of MCA, minutes	Surgical Complications with Bypass	Outcome
Kimura et al., 1993 ¹³	1	50/F	SAH	Giant MCA	40	Mild amnesic aphasia	Good
Hongo et al., 2003 ¹²	2 (Double insurance bypass)*	75/F 67/F	Diplopia SAH grade IV	Cavernous ICA P-Com ICA	30 + 46 28 + 55	None None	Resolving diplopia Transfer to rehab
Hara et al., 2016 ¹¹	3	64/M 64/F 73/M	Thrombosed Thrombosed Asymptomatic	Giant MCA Giant MCA Large MCA	N/A N/A N/A	None None None	Good Good Good
Present study	3	65/F 2/M 37/F	SAH grade IV SAH grade III Visual decline	Large MCA bifurcation Giant MCA bifurcation Large supraclinoid ICA	20 + 10 15 + 4 14 + 36	None None None	Good Good Vision improving

STA, superficial temporal artery; MCA, middle cerebral artery; SAH, subarachnoid hemorrhage; ICA, internal carotid artery; P-Com, posterior communicating; N/A, not available.

*Double-insurance bypass including both STA and radial artery bypasses.

always the preferred surgical option whenever technically feasible. The presence of dolichoectatic morphology, aberrant branch anatomy, and atherosclerotic aneurysm necks can prevent its safe clip reconstruction. In this situation, indirect aneurysm occlusion by proximal/distal occlusion/trapping is performed along with a flow-alteration bypass procedure depending upon the size of vascular territory being reperfused. This operative strategy may not achieve acute aneurysm obliteration, but it could significantly reduce the aneurysmal blood flow, hemodynamic stress, and induce gradual intra-aneurysmal thrombosis, thereby reducing the risk of rupture. However, the inability to reliably predict or control the extent and speed of aneurysmal thrombosis remains a major limitation of this technique.

Although there is no accurate predictor for cerebral ischemia after an M2-MCA occlusion, we advocate performing a flow-replacement STA-M3-MCA bypass in all cases requiring M2-MCA sacrifice. The decision to trap the aneurysm completely/partially relies on the origin of cortical branches and lenticulostriate perforators from the aneurysmal sac. More distally located complex M3-MCA aneurysms can be managed with simple parent artery sacrifice (if clip reconstruction is not feasible) and may not warrant additional flow augmentation using bypass. This can be confirmed with intraoperative changes in somatosensory-evoked potential and motor-evoked potential monitoring after temporarily occluding the parent vessel for 20 minutes. Any significant drop in these potentials during test occlusion may warrant flow replacement. Similar to our strategy, Tayebi Meybodi et al.¹ suggested that bypass strategy for prebifurcation aneurysms was determined by the involvement of lenticulostriate arteries, whereas the bypass strategy for MCA bifurcation aneurysms depend on the rupture status. On the contrary, the anatomical location of aneurysm in candelabra (sylvian, insular, or opercular) governed the bypass strategy for post-bifurcation aneurysms. Ashley et al.¹⁶ applied flow-assisted surgical planning and technique to decipher appropriate candidates for revascularization procedure and check adequacy of bypass respectively.

Complication Avoidance for STA-MCA Bypass

Despite its benefits, STA-MCA bypass procedure is not without complications. In a series of 10 patients with complex MCA aneurysms managed with STA-MCA bypass, Matano et al.²² demonstrated postoperative diffusion-imaging confirmed ischemic complications in 60% of patients, although majority of patients had favorable outcome. The observed ischemic complications included infarction in lenticulostriate artery territory and cortical vessels. They also attributed vasospasm as one of the contributing factors. They concluded that STA-MCA bypass adds to the temporary occlusion time of parent vessel over and beyond that required for temporary clipping of aneurysm surgery. Hence,

they advocated that adequate countermeasures are required to prevent ischemic complications. The risk of ischemic complications after STA-MCA bypass for aneurysm surgery is more than that for moyamoya disease and steno-occlusive arteriosclerotic diseases of ICA/MCA. This is because of the fact that no collateral pathway for MCA circulatory exists in aneurysm patients, in contrast to moyamoya disease and steno-occlusive arteriosclerotic diseases of ICA/MCA. In addition, patients with complex aneurysms cannot be subjected to antiplatelets (commonly used in patients with moyamoya disease and steno-occlusive arteriosclerotic diseases of ICA/MCA), which helps reduce the ischemic complications, due to a significant risk of hemorrhage.²² Lastly, safe temporary occlusion time of MCA trunk is believed to be only about 15 minutes, which is considerably shorter than the usual time required for vascular anastomosis.²² Therefore, we advocate a more distal anastomosis of STA to M3/M4-MCA segment, which is able to tolerate the longer occlusion time better than its more proximal counterpart. In addition, the caliber match between STA and M3/M4 segment is better than proximal segments. To avoid postoperative cerebral ischemia in complex MCA aneurysms being managed with supplementary bypass procedures, gentle operative manipulation to prevent mechanical trauma to graft, constant adventitial papaverine irrigation to avoid graft spasm, and judicious use of antiplatelet agents are of paramount importance. In addition, ensuring minimal cumulative temporary occlusion time of parent vessel by a well-orchestrated/planned surgical intervention further helps to reduce anastomosis-related ischemia. Finally, a pre-emptive decision and planning for bypass is likely to be more successful than a salvage STA-MCA bypass procedure when an aneurysm is already ruptured, especially at its neck, as it adds to the overall clipping time and negatively affects the anastomosis technique, leading to increased risk of graft occlusion and ischemic complications.^{10,11,22}

CONCLUSIONS

Adequate preoperative planning and meticulous surgical technique are vital for optimal outcome of STA-MCA bypass procedure. This series highlights the technical nuances and surgical strategy for successfully managing complex intracranial anterior circulation aneurysms using low-flow STA-MCA revascularization procedures, where prolonged clipping time on M1/M2-MCA is anticipated for clip reconstruction or there is a positive BOT with poor cross-flow in complex ICA aneurysms—insurance bypass—and where flow replacement is required for aneurysm trapping—flow alteration bypass. Surgical treatment with bypass (with or without occlusion method) for complex giant aneurysms provides a definitive and durable strategy of reducing the morbidity and mortality associated with them.

REFERENCES

1. Tayebi Meybodi A, Huang W, Benet A, Kola O, Lawton MT. Bypass surgery for complex middle cerebral artery aneurysms: an algorithmic approach to revascularization. *J Neurosurg.* 2017; 127:463-479.
2. Zhu W, Liu P, Tian Y, et al. Complex middle cerebral artery aneurysms: a new classification based on the angioarchitecture and surgical strategies. *Acta Neurochir.* 2013;155:1481-1491.
3. Steinberg GK, Drake CG, Peerless SJ. Deliberate basilar or vertebral artery occlusion in the treatment of intracranial aneurysms. Immediate results and long-term outcome in 201 patients. *J Neurosurg.* 1993;79:161-173.
4. Cruz JP, O'Kelly C, Kelly M, et al. Pipeline embolization device in aneurysmal subarachnoid hemorrhage. *AJNR Am J Neuroradiol.* 2013;34: 271-276.

5. Kalani MY, Zabramski JM, Hu YC, Spetzler RF. Extracranial-intracranial bypass and vessel occlusion for the treatment of unclippable giant middle cerebral artery aneurysms. *Neurosurgery*. 2013;72:428-435 [discussion: 435-436].
6. Seo BR, Kim TS, Joo SP, et al. Surgical strategies using cerebral revascularization in complex middle cerebral artery aneurysms. *Clin Neurol Neurosurg*. 2009;111:670-675.
7. Shi X, Qian H, Fang T, Zhang Y, Sun Y, Liu F. Management of complex intracranial aneurysms with bypass surgery: a technique application and experience in 93 patients. *Neurosurg Rev*. 2015;38:109-119 [discussion: 119-120].
8. Siddiqui AH, Abula AA, Kan P, et al. Panacea or problem: flow diverters in the treatment of symptomatic large or giant fusiform vertebral-basilar aneurysms. *J Neurosurg*. 2012;116:1258-1266.
9. Siddiqui AH, Kan P, Abula AA, Hopkins LN, Levy EI. Complications after treatment with pipeline embolization for giant distal intracranial aneurysms with or without coil embolization. *Neurosurgery*. 2012;71:E509-E513 [discussion: E513].
10. Esposito G, Regli L. Surgical decision-making for managing complex intracranial aneurysms. *Acta Neurochir (Suppl)*. 2014;119:3-11.
11. Hara T, Arai S, Goto Y, Takizawa T, Uchida T. Bypass surgeries in the treatment of cerebral aneurysms. *Acta Neurochir (Suppl)*. 2016;123:57-64.
12. Hongo K, Horiuchi T, Nitta J, Tanaka Y, Tada T, Kobayashi S. Double-insurance bypass for internal carotid artery aneurysm surgery. *Neurosurgery*. 2003;52:597-602 [discussion: 600-602].
13. Kimura M, Tanaka A, Matsuno H, Nagata S. Use of STA-MCA anastomosis for clipping of giant middle cerebral artery aneurysm—case report. *Neurol Med Chir (Tokyo)*. 1993;33:774-778.
14. Alaraj A, Ashley WW Jr, Charbel FT, Amin-Hanjani S. The superficial temporal artery trunk as a donor vessel in cerebral revascularization: benefits and pitfalls. *Neurosurg Focus*. 2008;24:E7.
15. Chen L, Kato Y, Sano H, et al. Management of complex, surgically intractable intracranial aneurysms: the option for intentional reconstruction of aneurysm neck followed by endovascular coiling. *Cerebrovasc Dis*. 2007;23:381-387.
16. Ashley WW, Amin-Hanjani S, Alaraj A, Shin JH, Charbel FT. Flow-assisted surgical cerebral revascularization. *Neurosurg Focus*. 2008;24:E20.
17. Esposito G, Fierstra J, Regli L. Distal outflow occlusion with bypass revascularization: last resort measure in managing complex MCA and PICA aneurysms. *Acta Neurochir*. 2016;158:1523-1531.
18. Horowitz MB, Yonas H, Jungreis C, Hung TK. Management of a giant middle cerebral artery fusiform serpentine aneurysm with distal clip application and retrograde thrombosis: case report and review of the literature. *Surg Neurol*. 1994;41:221-225.
19. Nussbaum ES, Madison MT, Goddard JK, Lassig JP, Janjua TM, Nussbaum LA. Remote distal outflow occlusion: a novel treatment option for complex dissecting aneurysms of the posterior inferior cerebellar artery. Report of 3 cases. *J Neurosurg*. 2009;111:78-83.
20. Mathis JM, Barr JD, Jungreis CA, et al. Temporary balloon test occlusion of the internal carotid artery: experience in 500 cases. *AJNR Am J Neuroradiol*. 1995;16:749-754.
21. Samson D, Batjer HH, Bowman G, et al. A clinical study of the parameters and effects of temporary arterial occlusion in the management of intracranial aneurysms. *Neurosurgery*. 1994;34:22-28 [discussion: 28-29].
22. Matano F, Murai Y, Tateyama K, et al. Perioperative complications of superficial temporal artery to middle cerebral artery bypass for the treatment of complex middle cerebral artery aneurysms. *Clin Neurol Neurosurg*. 2013;115:718-724.

Conflict of interest statement: The authors declare that the article content was composed in the absence of any commercial or financial relationships that could be construed as a potential conflict of interest.

Received 24 January 2019; accepted 11 March 2019

Citation: *World Neurosurg*. (2019).

<https://doi.org/10.1016/j.wneu.2019.03.109>

Journal homepage: www.journals.elsevier.com/world-neurosurgery

Available online: www.sciencedirect.com

1878-8750/\$ - see front matter © 2019 Elsevier Inc. All rights reserved.