

## IPILATERAL MOTOR SEIZURES

R. PRATAP CHAND

Consultant Neurologist, Department of Medicine, University Hospital, Kelantan, Malaysia

### Abstract:

A patient presented with elementary partial motor seizures on the same side as the cerebral lesion. A cerebral computerised tomographic scan showed a right medial frontal atrophic lesion and an electroencephalogram showed seizure discharges from the same region. The clinical significance and pathophysiology of ipsilateral seizures are discussed. (Aust NZ J Med 1986; 16: 234-235.)

**Key words:** Ipsilateral seizures, epilepsy.

The motor and sensory phenomena of elementary partial seizures occur on the side of the body contralateral to the cerebral epileptogenic focus and are useful in localising cerebral lesions. Partial seizures occurring on the same side of the body as the cerebral hemispheric lesion are termed ipsilateral seizures. These are exceedingly rare and have been reported in association with brain tumours, tuberculosis, and cerebral infarcts.<sup>1-3</sup> I describe a patient with an atrophic lesion secondary to craniocerebral trauma, who presented with ipsilateral motor seizures with secondary generalisation.

### CASE REPORT

A 21 year old, right handed Malay male presented with a history of four episodes of seizures during the previous six months. The attacks started with an aura of clonic twitching of the right upper limb for a few seconds, followed by loss of consciousness, generalised tonic clonic convulsions lasting 5-10 minutes, and post-ictal stupor and sleep. A partial seizure lasting a few minutes was witnessed once and consisted of abduction of the right arm at the shoulder and clonic jerking of the arm. Post-ictal paralysis of the limb was not observed. He had suffered a head injury at the age of 11 years owing to a fall from a tree, when he had lost consciousness for about an hour and then recovered without any residual deficits.

On examination, the patient had no neurological deficits. An old healed scar was seen over the left frontal region. X-ray examination of the skull was normal. A cerebral computerised tomography (CT) scan showed a linear non-enhancing hypodense lesion in the medial right fronto-polar region, suggestive of an old cerebral contusion, and residual cortical atrophy (Figs 1 and 2). An electroencephalogram (EEG) showed infrequent spike and slow wave discharges in the transverse runs, over the right medial frontal and central regions (Fig. 3). The seizures were controlled with oral carbamazepine (200 mg twice daily).

### DISCUSSION

The exact mechanism of ipsilateral seizures is poorly understood, although various hypotheses have been put

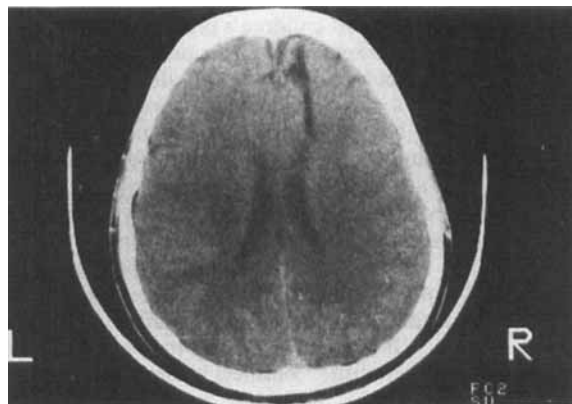

Figure 1: Computerised tomographic (CT) scan shows the linear non-enhancing lesion in the right medial frontal lobe and right fronto-polar cortical atrophy.

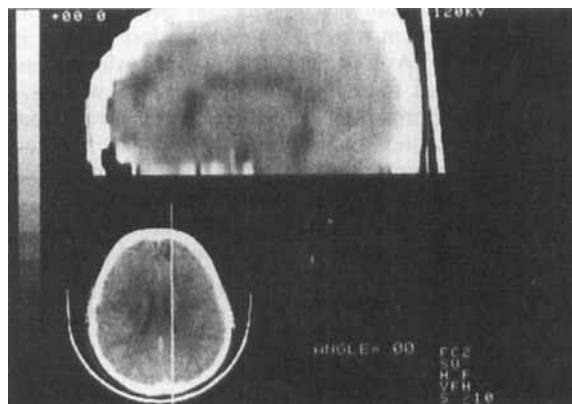


Figure 2: Sagittal reconstruction of CT scan shows the anatomical proximity of the lesion to the supplementary motor cortex.

Reprint requests to: Dr R. Pratap Chand, Consultant Neurologist, Dept of Medicine, University Hospital, Kubang Kerian, Kelantan, Malaysia.

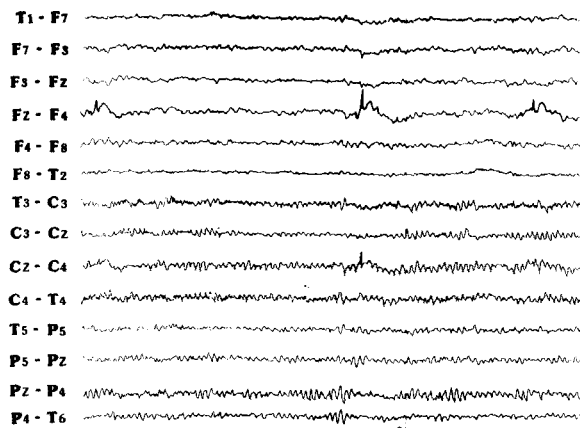


Figure 3: EEG shows infrequent spike and slow wave discharges arising from the Fz-F4 and Cz-C4 linkages.

forward. Experimental studies have shown that stimulation of the supplementary motor cortex and secondary somatosensory areas can give rise to motor and sensory responses, respectively, in the ipsilateral extremities.<sup>4,5</sup> Based on the anatomic proximity of the lesions to these areas, this mechanism has been invoked to explain ipsilateral seizures in most of the cases reported so far.<sup>1-3</sup> Chronic affection of the brain stem has been postulated to lead sometimes to ipsilateral epilepsy and was thought to be the reason in one of the six cases reported by Arseni and Maretsis.<sup>2</sup> The development of a mirror focus may explain ipsilateral seizures in some patients.<sup>6</sup>

In the present case, the anatomic location of the lesion on CT scan points to the supplementary motor cortex as the epileptogenic area (Fig. 1). In four of the seven cases reported by Ahuja and Tharakan, seizure discharges could not be demonstrated in the EEG, although the lesions had proximity to the above area. Ipsilateral epileptiform discharges could be demonstrated in our patient, and there was no evidence of a mirror focus. In view of its anatomic location, epileptiform discharges arising from the supplementary motor area may be difficult to record using scalp electrodes. This may be the reason for the absence of seizure discharges in the EEGs in the cases previously reported. However, long term recording using EEG telemetry may help to document the epileptogenic focus adequately in similar cases where interictal seizure discharges are scanty. In conclusion, ipsilateral seizure constitutes a rare clinical phenomenon that can lead to false clinical localisation of cerebral lesions. The EEG and CT scan should help to give the correct localisation.

Accepted for publication: 7 January 1986.

#### References

1. Kofman O, Tasker R. Ipsilateral and focal inhibitory seizures. *Neurology* 1967; 17: 1082-6.
2. Arseni C, Maretsis M. Focal epileptic seizures ipsilateral to the tumour. *Acta Neurochir (Wien)* 1979; 49: 47-60.
3. Ahuja GK, Tharakan J. Ipsilateral seizures. *Epilepsia* 1982; 23: 555-61.
4. Penfield WG, Welch K. The supplementary area of cerebral cortex. *Arch Neurol Psychiatry (Chicago)* 1951; 608: 289-317.
5. Penfield WG, Jasper HA. *Epilepsy and the functional anatomy of human brain*. Boston: Little, Brown and Co, 1954; 373-7.
6. Marsan CA, Gummit JR. Neurophysiological aspects of epilepsy. In: Vinken PJ, Bruyn GW, eds. *Handbook of clinical neurology*. Amsterdam: North Holland Publishing Co, 1974; 15: 30-59.