



How I do it: supra-tentorial unilateral decompressive craniectomy

Nicolas Desse¹ · Nathan Beucler¹ · Arnaud Dagain¹

Received: 23 November 2018 / Accepted: 20 March 2019
© Springer-Verlag GmbH Austria, part of Springer Nature 2019

Abstract

Background Decompressive craniectomy is a surgical way to treat intracranial hypertension, by removing a large flap of skull bone.

Method We report the case of a 48 years old right-handed man presenting an acute ischaemic stroke of all the right sylvian artery area, with rapid clinic deterioration then coma. Severe intracranial hypertension was confirmed by transcranial Doppler. In emergency, we decided to perform a right-side decompressive craniectomy.

Conclusion Six months later, he is in rehabilitation with “only” a left hemiplegia and a very good relational life. His modified Rankin score is 3. Decompressive craniectomy saved this patient’s life, that is why we think this surgical technique must be explained and mastered.

Keywords Decompressive craniectomy · Intracranial hypertension · Surgical technique

Relevant surgical anatomy

Surgical approach is on the left side or the right side, depending on the pathology. We try to maximise brain deliverance by realising a large bone flap.

Some anatomical points have to be anticipated before incision (Fig. 1). The most important structures to absolutely avoid are all the venous sinuses: the superior sagittal sinus on the vertex, the torcular and the lateral sinus running between the torcular and jugular veins on each side.

Some bone limits must also be known and, as far as it may be possible, avoided: the frontal sinus, the orbital area and the petrosal bone.

Neither peripheral nerves nor arteries are a problem in this surgery. Superficial temporal artery and middle meningeal

artery may be encountered. The frontotemporal branches of the facial nerve may not be affected.

Description of the technique

Under general aesthesia, the patient lies supine; the head is turned on the contralateral side of the lesion, with a support under the homolateral shoulder. The hair is quickly and widely sheared, and the skin is prepared as usual (iodine solution).

Skin incision begins 1 cm above the tragus and runs in a “question mark” shape from the temporal to the parietal then the frontal area. After quick haemostasis, we edge skin incision with pads and Raney clips. Temporal muscle is incised along the skin incision. Scalp and muscle are peeled in one layer and maintained with metallic hooks (Fig. 2a).

With our high-speed drill (Medtronic® Legend), we realise four burr holes: temporal, frontal, parieto-occipital and along the superior sagittal sinus. The flap must be at least 12 cm long between the frontal and occipital areas. After loosening the dura mater in the burr holes, the flap is realised by joining the burr holes with a craniotome, finishing by the fronto-occipital cut along the sinus. The bone flap is then carefully loosened and removed from the dura mater (Fig. 2b). The temporal fossa is then opened with a rongeur to complete the craniectomy.

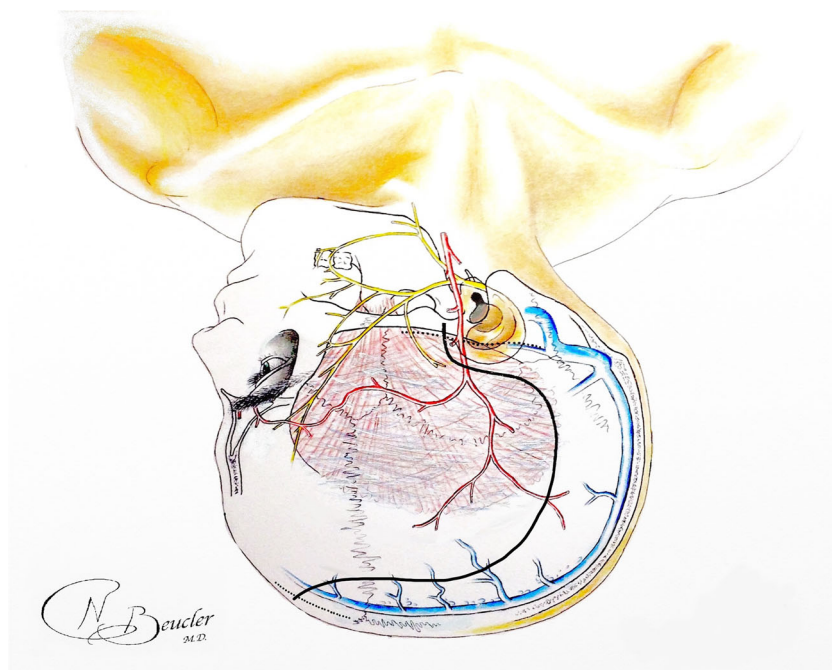
This article is part of the Topical Collection on *Neurosurgery general*

Electronic supplementary material The online version of this article (<https://doi.org/10.1007/s00701-019-03880-x>) contains supplementary material, which is available to authorized users.

✉ Nicolas Desse
nicolas.desse@neurochirurgie.fr

¹ Service de Neurochirurgie, Hôpital d’Instruction des Armées Sainte Anne, HIA Sainte Anne – BP600, 83800 Toulon Cedex 9, France

Fig. 1 Preoperative anatomical points and temporo-parieto-frontal incision line



The dura mater is opened in a star-like fashion (Fig. 2c). The brain usually herniates through the craniectomy, confirming intracranial hypertension. Haemostasis is carefully

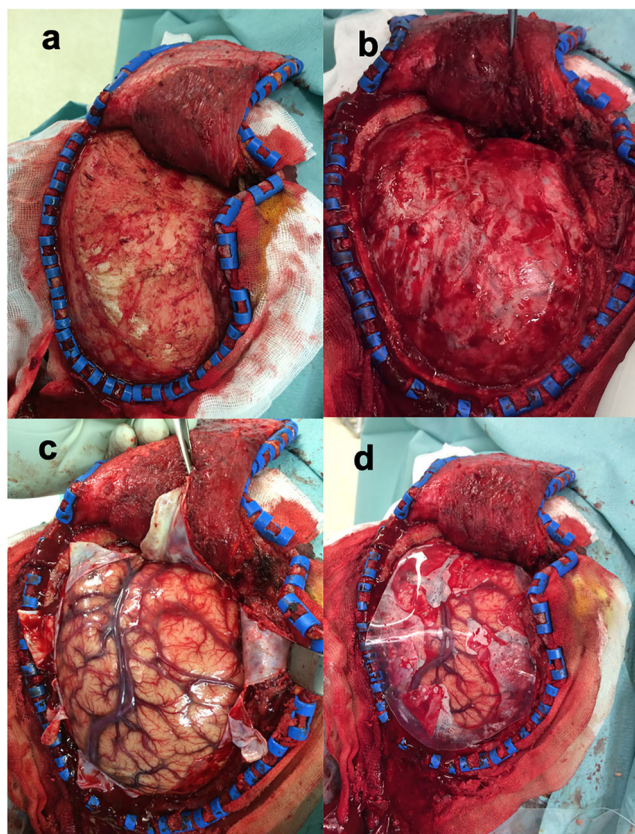


Fig. 2 Some steps of the surgery. Scalp and temporal muscle removed (a). After craniectomy (b). Star-like opening in the dura mater (c). With the silicone layer onto the brain (d)

checked, using haemostatic gauze (Surgicel®) and sometimes bipolar forceps. Before closure, we interleave a thin layer onto the brain, to protect it and to facilitate the forthcoming cranioplasty. We usually use a Silastic® silicone layer (Fig. 2d), but a synthetic dura mater can also be used. We avoid layer shift by securing it with two stitches on the dura mater.

The temporal muscle and then subcutaneous tissues are closed with overlock stitches, using a resorbable wire. Drainage is not always mandatory; it hinges on haemostasis quality. Skin is closed with staples and protected with a hood.

The bone flap management depends on institution habits. It can be cryo-preserved, thrown away or put into the abdominal wall (in war condition for example). Most of the time, we send it for cryo-preservation.

Indications

Decompressive craniectomy is considered when common medical interventions fail to control intracranial pressure.

It has a proven benefit in the management of malignant cerebral oedema after acute ischaemic stroke [10]. It also may be performed in traumatology, for intracranial pressure control or with the simultaneous evacuation of acute intracranial haematomas [2].

Historically, decompressive craniectomy was bifrontal [5]. Chosen in the DECRA study, this approach keeps some indications in post-traumatic diffuse cerebral oedema. Unilateral craniectomy is indicated for homolateral lesions like post-traumatic unilateral oedema, malignant acute stroke or subarachnoid haemorrhage [3].

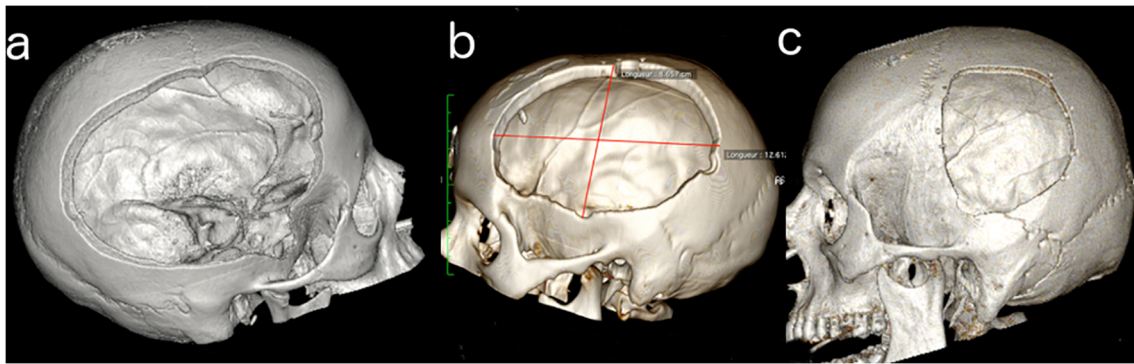


Fig. 3 Various sizes of craniectomy. Good size with temporal decompression (a). Good size but no temporal decompression (b). Too small (c)

The technical choice remains at the discretion of each surgeon, on the basis of computed tomographic imaging and after multidisciplinary discussion.

Limitations

From a technical point of view, there are no real limits, as long as a large bone flap is realised in a timely manner (i.e. before refractory intracranial pressure elevation).

How to avoid complications

First of all, the bone flap must be wide, but not too much. Its optimal diameter seems to be around 12 cm (Fig. 3) [8].

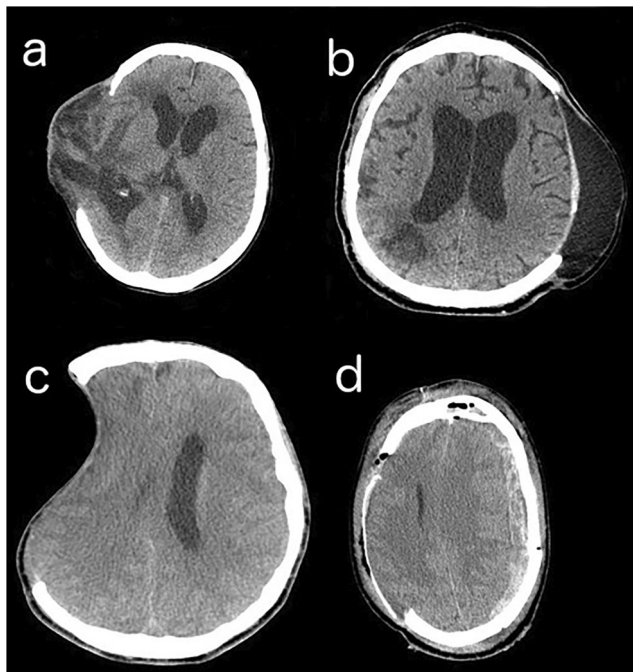


Fig. 4 : Decompressive craniectomy complications. Brain herniation (a). Hygroma (b). Sinking skin flap syndrome (c). Contralateral haemorrhage (d)

If it is too small, the risk is an extracranial herniation of the brain, with venous complications such as brain swelling or cortical vein compression (Fig. 4a) [6].

A too large bone flap may result sooner or later in CSF-linked complications [7, 9], such as subdural hygroma or hydrocephalus (Fig. 4b). If hygroma does not require any specific treatment, hydrocephalus may be treated by cranioplasty and sometimes simultaneously a ventriculoperitoneal shunt. Another complication of large craniectomy is a brain depression called “sinking skin flap syndrome” (Fig. 4c), associated with headache, cognitive and/or motor disorders, seizure, even coma then death [4]. An early cranioplasty, within three months after craniectomy, should normalise CSF circulation and avoid hydrocephalus [7] or sinking skin flap (SSF) syndrome.

Decompressive craniectomy is always made in emergency conditions, increasing infection incidence. Infections are facilitated by large scars, by using a synthetic layer to protect the brain and by frontal sinus and/or petrosal bone fractures. Moreover, these fractures must be considered and treated. For example, a frontal sinus fracture requires a cranialisation as soon as possible. Adapted antibiotic therapy is mandatory but most of the time, a surgical revision is needed for infectious area debridement.

Some other complications are hard to avoid, such as bleeding complications that may be encountered during or after surgery. In over fifty percent of the cases, decompressive craniectomy may cause or increase intracerebral contusion, usually on the same side as the craniectomy [1]. Furthermore, by lowering intracranial pressure, craniectomy can also release a contralateral haemorrhage, as a contusion or a subdural haematoma (Fig. 4d).

Specific perioperative considerations

After craniectomy, specific attention must be given to the boneless area.

Wound care must be done every two days (gentle hair wash is allowed). The hood must be kept loose, with the

craniectomy area clearly indicated on it. Staples are usually removed within two weeks.

Some fall prevention strategies must be considered (bed at the lowest level, supervision during mobilisation, non-skid shoes). A custom-made helmet may also be used to protect the head.

Specific information to give about this surgery

Decompressive craniectomy is “only” a lifesaving procedure, clearly associated with better intracranial pressure control and lower mortality than medical treatment, but also associated with higher rates of vegetative state [2].

This information must be communicated to the family, and surgery must be decided on a multidisciplinary basis and, as far as may be possible, surgeons must be aware of the patient’s previously stated wishes and personal values.

Compliance with ethical standards

Conflict of interest The authors declare that they have no conflict of interest.

References

1. Flint AC, Manley GT, Gean AD, Hemphill JC, Rosenthal G (2008) Post-operative expansion of hemorrhagic contusions after unilateral decompressive hemicraniectomy in severe traumatic brain injury. *J Neurotrauma* 25(5):503–512
2. Hutchinson PJ, Koliass AG, Timofeev IS, Corteen EA, Czosnyka M, Timothy J et al (2016) Trial of decompressive craniectomy for traumatic intracranial hypertension. *N Engl J Med* 375(12):1119–1130
3. Kakar V, Nagaria J, John Kirkpatrick P (2009) The current status of decompressive craniectomy. *Br J Neurosurg* 23(2):147–157
4. Kemmling A, Duning T, Lemcke L, Niederstadt T, Minnerup J, Wersching H et al (2010) Case report of MR perfusion imaging in sinking skin flap syndrome: growing evidence for hemodynamic impairment. *BMC Neurol* 10(1):80
5. Polin RS, Shaffrey ME, Bogaev CA, Tisdale N, Germanson T, Bocchicchio B et al (1997) Decompressive bifrontal craniectomy in the treatment of severe refractory posttraumatic cerebral edema. *Neurosurgery*. 41(1):84 92–discussion 92–4
6. Sedney CL, Julien T, Manon J, Wilson A (2014) The effect of craniectomy size on mortality, outcome, and complications after decompressive craniectomy at a rural trauma center. *J Neurosci Rural Pract* 5(3):212–217
7. Stiver SI (2009) Complications of decompressive craniectomy for traumatic brain injury. *Neurosurg Focus* 26(6):E7
8. Tagliaferri F, Zani G, Iaccarino C, Ferro S, Ridolfi L, Basaglia N et al (2012) Decompressive craniectomies, facts and fiction: a retrospective analysis of 526 cases. *Acta Neurochir* 154(5):919–926
9. Timofeev I, Santarius T, Koliass AG, Hutchinson PJA (2012) Decompressive craniectomy - operative technique and perioperative care. *Adv Tech Stand Neurosurg* 38:115–136
10. Vahedi K, Hofmeijer J, Juettler E, Vicaut E, George B, Algra A et al (2007) Early decompressive surgery in malignant infarction of the middle cerebral artery: a pooled analysis of three randomised controlled trials. *Lancet Neurol* 6(3):215–222

Publisher’s note Springer Nature remains neutral with regard to jurisdictional claims in published maps and institutional affiliations.

Key points:

- A multidisciplinary decision is needed, including the patient and/or family.
- Even if it seems not so complicated, anticipate anatomical pitfalls.
- Realise a large hair shearing, a large skin incision and a large bone flap.
- The dura mater must be widely opened.
- Haemostasis must be controlled.
- Do not forget to check the frontal sinus or petrosal bone.
- Protect the brain and facilitate cranioplasty by using an interlayer.
- Keep the hood loose, to avoid brain pressure through craniectomy.
- Time is brain, so try not to waste it.
- An early cranioplasty, within 3 months, is recommended to avoid CSF complications and to improve patient recovery.