



# Idiopathic Hypertrophic Pachymeningitis Mimicking Meningioma with Occlusion of Superior Sagittal Sinus: Case Report and Review of Literature

Anhui Yao<sup>1,2</sup>, Liyun Jia<sup>3</sup>, Benhan Wang<sup>2</sup>, Jiashu Zhang<sup>1</sup>, Jun Zhang<sup>1</sup>, Bainan Xu<sup>1</sup>

## Key words

- Idiopathic hypertrophic pachymeningitis
- Meningioma

## Abbreviations and Acronyms

**IgG:** Immunoglobulin G

**IHP:** Idiopathic hypertrophic pachymeningitis

**MRI:** Magnetic resonance imaging

**SSS:** Superior sagittal sinus

From the <sup>1</sup>Department of Neurosurgery, General Hospital of PLA, Beijing; <sup>2</sup>Department of Neurosurgery, The 988 Hospital of PLA, Zhengzhou; and <sup>3</sup>Department of Medical Genetics and Cell Biology, School of Basic Medical Science, Zhengzhou University, Zhengzhou, China

To whom correspondence should be addressed:  
Jun Zhang, M.D.

[E-mail: zjun\_301@126.com]

Anhui Yao and Liyun Jia are co-first authors.

Citation: *World Neurosurg.* (2019) 127:534–537.  
<https://doi.org/10.1016/j.wneu.2019.04.006>

Journal homepage: [www.journals.elsevier.com/world-neurosurgery](http://www.journals.elsevier.com/world-neurosurgery)

Available online: [www.sciencedirect.com](http://www.sciencedirect.com)

1878-8750/\$ - see front matter © 2019 Elsevier Inc. All rights reserved.

## INTRODUCTION

Idiopathic hypertrophic pachymeningitis (IHP) is an uncommon disease characterized by inflammatory fibrosis and thickening of localized or diffuse dura mater. IHP poses diagnostic challenges to attending clinicians due to its highly variable presentation. Chronic headache, loss of vision, diplopia, and other cranial nerve palsies are the most common clinical symptoms of IHP.<sup>1</sup> In addition to clinical subtlety and variability, IHP is also a great imposter because it can mimic other common neurologic conditions, such as prolactinoma.<sup>2</sup> IHP cases with thickened dura mater similar to meningioma requiring decompression surgery are especially rare. We describe a case of IHP mimicking meningioma. The patient presented with headache, left limb weakness, and epileptic seizure and underwent surgery to dissect the lesion.

■ **BACKGROUND:** Idiopathic hypertrophic pachymeningitis is a rare inflammatory condition with diffuse thickening of the dura mater, which may cause a compressive effect or vascular compromise.

■ **CASE DESCRIPTION:** A 40-year-old Chinese man presented with persistent headache for 6 months and a sudden epileptic seizure 2 days ago. Magnetic resonance imaging demonstrated a large (71 × 34 × 27 mm) extra-axial mass at the right frontal convexity with severe edema mimicking meningioma. The lesion and peripheral dura mater showed contrast enhancement. Additionally, the skull near the lesion was eroded. Meningioma was diagnosed, and the patient underwent surgery. During the operation, we found the lesion texture was very tough, and the superior sagittal sinus was occluded. Histopathologic findings revealed a large number of infiltrated lymphocytes with fibrosis and microabscess formation; intracranial idiopathic hypertrophic pachymeningitis was diagnosed. Follow-up magnetic resonance imaging performed 3 months after surgery demonstrated the enhancement was notably alleviated.

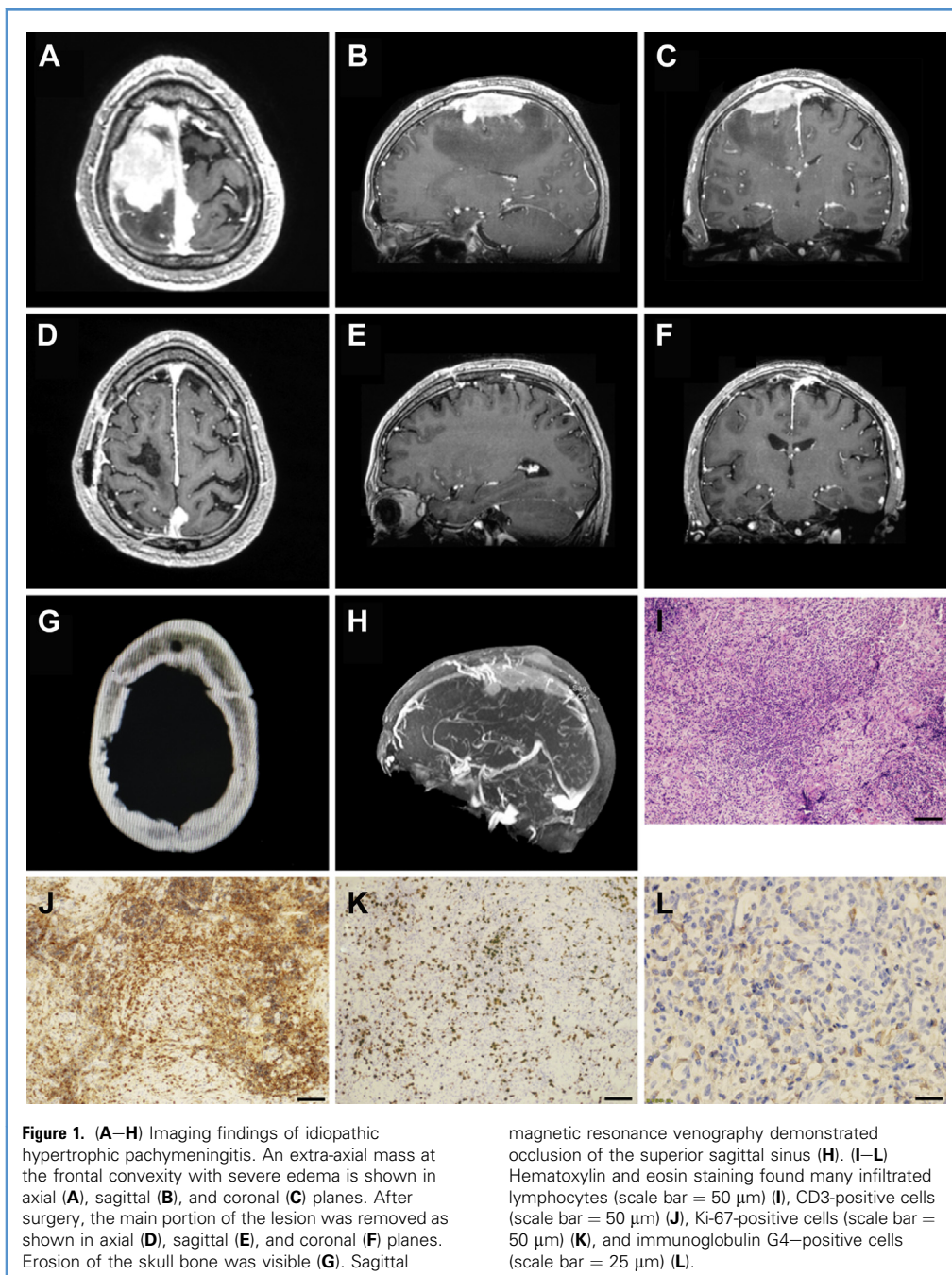
■ **CONCLUSIONS:** Idiopathic hypertrophic pachymeningitis should be part of the differential diagnosis of some cases of meningioma.

## CASE DESCRIPTION

A 40-year-old Chinese man with persistent headache and left limb weakness for 6 months was admitted to General Hospital of PLA. Two days before admission, the patient had a sudden epileptic seizure lasting 3 minutes. Brain magnetic resonance imaging (MRI) showed a large (71 × 34 × 27 mm) extra-axial mass located at the right frontal convexity with severe edema (Figure 1A–C). A preliminary diagnosis of meningioma was made, and the patient underwent neurosurgery. Preoperative examination found enhancement of the lesion with extensive meningeal tail sign. Magnetic resonance venography showed the superior sagittal sinus (SSS) was occluded (Figure 1H). Computed tomography scan showed the skull bone was eroded (Figure 1G). On preoperative examination, hepatitis B antibody and syphilis antibody were positive, but infectious disease was not present.

Surgical resection of the lesion was performed under neuromonitoring with somatosensory evoked potentials and

motor evoked potentials. We tried to remove the lesion using devascularization, debulking, and dissection. During the operation, we attempted devascularization from the dura mater first and found that the lesion was very tough. Subsequently, we used a number 15 knife to cut the lesion adjacent to the SSS. We found the sagittal sinus was occluded as shown on preoperative magnetic resonance venography. Consequently, we cut the lesion as well as the affected SSS. It was too tough to be cut by an ultrasonic cutting device. We debulked the lesion in the relatively safe area with number 15 knife. Finally, we dissected the lesion from the normal cortex. As the lesion adhered severely to the cortex, we did a subtotal resection and left a thin layer of lesion on the cortical surface. After surgery, the patient's left limb muscle strength was grade III, and the right limb was grade IV. On postoperative day 10, left limb muscle strength improved to grade IV, and the right limb was grade V. Pathologic findings showed a large number of infiltrated lymphocytes with fibrosis and microabscess formation



(Figure 1). Many CD3-positive, Ki-67-positive, and immunoglobulin G (IgG) 4-positive cells were also found. Intracranial IHP was diagnosed on the basis of these findings. The patient was also suspected to have a systemic autoimmune disease, but no disease fulfilled the

criteria. Postoperative MRI showed the main portion of the lesion was removed, and the enhanced thickening dura was alleviated (Figure 1D–F).

The patient was treated with 1 g/day of intravenous methylprednisolone for 3 days, followed by 50 mg/day (1 mg/kg/day)

of oral prednisolone. All clinical manifestations improved rapidly. After discharge, the patient was treated with 40 mg/day of prednisolone. The patient's limb muscle strength returned to normal with slightly poor flexibility at 3-month follow-up. MRI showed that there was no recurrence in

the operative area, and the thickened dura mater had no significant changes at 7 months.

## DISCUSSION

IHP is a rare clinical entity characterized by inflammatory fibrosis and thickening of the localized or diffuse dura mater without obvious underlying disease. In a few reported cases, IHP mimicked other common neurologic conditions. Lok et al.<sup>2</sup> reported a case of IHP mimicking prolactinoma with recurrent vision loss. Umegaki et al.<sup>3</sup> reported a case of IHP similar to subdural hematoma in the left parietal lobe with symptomatic stenosis of the SSS.<sup>3</sup> To our knowledge, Hosler et al.<sup>4</sup> reported the first case of IHP mimicking lymphoplasmacytic-rich meningioma. Our case is the second case of IHP mimicking lymphoplasmacytic-rich meningioma with occlusion of SSS.

There are also some cases of atypical lymphoplasmacytic-rich meningioma mimicking IHP.<sup>5,7</sup> Carcinomatous hypertrophic pachymeningitis is similar to giant cell arteritis.<sup>8</sup> Arrese et al.<sup>9</sup> reported a case of IHP of the cavernous sinus mimicking meningioma with complete occlusion of the carotid artery. IHP is similar to neurosarcooidosis.<sup>10</sup> In a cohort study comprising 20 cases, Dash et al.<sup>11</sup> highlighted the role of MRI in differentiating between IHP and secondary causes of hypertrophic pachymeningitis. IHP is a diagnosis of exclusion, and a dural pathologic examination is essential to exclude known causes, such as infectious, neoplastic, or autoimmune disorders.<sup>12</sup> Histopathologic findings include fibrosis and thickening dura with chronic inflammatory cell (lymphocytes and plasma cells) infiltration.<sup>12</sup> Some cases of IgG4-related hypertrophic pachymeningitis have been reported in the literature. Radiologically and histologically, IgG4-related hypertrophic pachymeningitis shares many common characteristics with IHP. However, IgG4-related hypertrophic pachymeningitis is confirmed by the immunohistochemical analysis of >10% IgG4-bearing plasma cells per high-power field and, often but not always, elevated serum IgG4 concentrations.<sup>12</sup> Most

importantly, IgG4+/IgG+ plasma cell ratio >40% is necessary for the diagnosis of IgG4-related hypertrophic pachymeningitis.<sup>12</sup> The present case indicated IHP with IgG4+/IgG+ <40% detected by immunostaining analysis.

Thus far, IHP cases involving the bone are even rarer. Lee et al.<sup>12</sup> reported a case of IgG4-related IHP in which the skull adjacent to the mass was focally enhanced. The diagnosis was confirmed by histopathologic findings. Lin et al.<sup>13</sup> also reported a case of IgG4-related IHP with skull hyperostosis. Noda et al.<sup>14</sup> reported a case of IHP manifesting with hyperostosis of the sphenoid ridge. In our case, the skull adjacent to the lesion eroded, and this condition has not been reported before.

The treatment of IHP is based on the possible underlying autoimmune mechanism. Analysis of the literature indicates that first-line therapy for IHP is steroids. However, no definite protocols for standard dose and duration in IHP have been proposed thus far. The average initial dose of prednisolone is 42.7 mg/day, and the average maintenance dose is 12.4 mg/day for long-term treatment. Recurrence occurred in many patients when the dose of prednisolone was reduced to 20 mg/day. Therefore, steroids should be tapered extremely slowly.<sup>15</sup> There are a few cases that are refractory to steroids or recur when steroids are tapered. An immunosuppressant, such as cyclophosphamide or methotrexate, is a second choice to treat steroid-refractory IHP. Uchida et al.<sup>16</sup> reported a steroid-resistant case of IHP in which use of low-dose oral methotrexate showed marked effectiveness. Accordingly, these authors recommended low-dose methotrexate as a more appropriate choice for IHP than steroid administration.<sup>16</sup> Jang et al.<sup>17</sup> reported 3 cases of steroid-refractory IHP treated by rituximab and suggested that rituximab can act as a good alternative therapy for steroid-refractory IHP. Besides taking a biopsy specimen for diagnosis, surgical intervention in 2 cases comprised craniotomy for decompression,<sup>18,19</sup> and in 2 other cases optic nerve decompression of the canal was performed.<sup>20,21</sup> Treatment of IHP with hydrocephalus was by means of

endoscopic third ventriculostomy in 1 patient.<sup>22</sup> In the case of our patient, the lesion was big with severe edema and occlusion of the SSS. Subtotal resection surgery was performed, and treatment with corticosteroids was administered after pathologic diagnosis. This therapeutic strategy resulted in complete resolution of neurologic symptoms and regression of lesions as evidenced by head MRI.

In previous reports, the clinical observation periods were often several years in duration. Complete recoveries of IHP are relatively rare. The disease is often progressive and requires prolonged treatment. The cause of IHP remains unclear, and studies to identify the etiology and disease process are indispensable for effective therapy.

## CONCLUSIONS

IHP is a rare, chronic inflammatory process with likely an immunologic etiology. The most frequently encountered neurologic manifestations include headache, loss of vision, diplopia, and paresis of other cranial nerves. The diagnosis of IHP is based on MRI and histopathologic findings. Based on the possible underlying autoimmune mechanism, immunosuppressive agents may be a rational therapy for this disease. However, the effectiveness of medical treatment is still uncertain, probably because the etiologic and pathologic processes are obscure. Studies to identify the etiology and disease process are indispensable for effective therapy.

## REFERENCES

1. Kupersmith MJ, Martin V, Heller G, Shah A, Mitnick HJ. Idiopathic hypertrophic pachymeningitis. *Neurology*. 2004;62:686-694.
2. Lok JY, Yip NK, Chong KK, Li CL, Young AL. Idiopathic hypertrophic pachymeningitis mimicking prolactinoma with recurrent vision loss. *Hong Kong Med J*. 2015;21:360-362.
3. Umegaki S, Osawa SI, Kimura K, et al. A case of hypertrophic pachymeningitis with symptomatic venous congestion due to sinus stenosis [in Japanese]. *No Shinkei Geka*. 2018;46:147-152.
4. Hosler MR, Turbin RE, Cho ES, Wolansky LJ, Frohman LP. Idiopathic hypertrophic pachymeningitis mimicking lymphoplasmacyte-rich meningioma. *J Neuroophthalmol*. 2007;27:95-98.

5. Russo A, Silvestro M, Cirillo M, Tessitore A, Tedeschi G. Idiopathic hypertrophic pachymeningitis mimicking hemispheric aneurysm: an unusual clinical case. *Cephalalgia*. 2018;38:804-807.
6. Hirunwiwatkul P, Trobe JD, Blaivas M. Lymphoplasmacyte-rich meningioma mimicking idiopathic hypertrophic pachymeningitis. *J Neuroophthalmol*. 2007;27:91-94.
7. Cha YJ, Lee SK, Chang JH, Kim SH. Report of a rare case of atypical lymphoplasmacyte-rich meningioma in the tentorium mimicking idiopathic hypertrophic pachymeningitis. *Brain Tumor Pathol*. 2016;33:216-221.
8. Chan JW. Acute monocular visual loss in carcinomatous hypertrophic pachymeningitis mimicking giant cell arteritis. *J Clin Rheumatol*. 2006;12:30-31.
9. Arrese T, Gonzalez P, Ramos A, Ruiz J, Lobato RD. Idiopathic hypertrophic pachymeningitis of the cavernous sinus mimicking meningioma with complete occlusion of the carotid artery [in Spanish]. *Neurociencia (Astur)*. 2005;16:63-66.
10. Christakis PG, Machado DG, Fattahi P. Idiopathic hypertrophic pachymeningitis mimicking neurosarcoidosis. *Clin Neurol Neurosurg*. 2012;114:176-178.
11. Dash GK, Thomas B, Nair M, Radhakrishnan A. Clinico-radiological spectrum and outcome in idiopathic hypertrophic pachymeningitis. *J Neurol Sci*. 2015;350:51-60.
12. Lee YS, Lee HW, Park KS, Park SH, Hwang JH. Immunoglobulin G4-related hypertrophic pachymeningitis with skull involvement. *Brain Tumor Res Treat*. 2014;2:87-91.
13. Lin CK, Lai DM. IgG4-related intracranial hypertrophic pachymeningitis with skull hyperostosis: a case report. *BMC Surg*. 2013;13:37.
14. Noda D, Tsugu H, Nishikawa W, Shigekawa S, Fukushima T, Nabeshima K. Case of idiopathic hypertrophic pachymeningitis presenting with hyperostosis [in Japanese]. *No Shinkei Geka*. 2008;36:717-723.
15. Ueda A, Ueda M, Mihara T, Ito S, Asakura K, Mutoh T. Hypertrophic pachymeningitis: three adult cases and a review of the literature [in Japanese]. *Rinsho Shinkeigaku*. 2011;51:243-247.
16. Uchida H, Ogawa Y, Tominaga T. Marked effectiveness of low-dose oral methotrexate for steroid-resistant idiopathic hypertrophic pachymeningitis: case report. *Clin Neurol Neurosurg*. 2018;168:30-33.
17. Jang Y, Lee ST, Jung KH, Chu K, Lee SK. Rituximab treatment for idiopathic hypertrophic pachymeningitis. *J Clin Neurol*. 2017;13:155-161.
18. Huang Y, Chen J, Gui L. A case of idiopathic hypertrophic pachymeningitis presenting with chronic headache and multiple cranial nerve palsies: a case report. *Medicine (Baltimore)*. 2017;96:e7549.
19. Oku T, Yamashita M, Inoue T, et al. A case of posterior fossa hypertrophic pachymeningitis with hydrocephalus [in Japanese]. *No To Shinkei*. 1995;47:569-573.
20. Hatano N, Behari S, Nagatani T, et al. Idiopathic hypertrophic cranial pachymeningitis: clinico-radiological spectrum and therapeutic options. *Neurosurgery*. 1999;45:1336-1342 [discussion: 1342-1344].
21. Hamada J, Yoshinaga Y, Korogi Y, Ushio Y. Idiopathic hypertrophic cranial pachymeningitis associated with a dural arteriovenous fistula involving the straight sinus: case report. *Neurosurgery*. 2000;47:1230-1233.
22. Barbieri FR, Novegno F, Iaquinandi A, Lunardi P. Hypertrophic pachymeningitis and hydrocephalus—the role of neuroendoscopy: case report and review of the literature. *World Neurosurg*. 2018;119:183-188.

*Conflict of interest statement:* This study was funded by the National Natural Science Foundation of China (Grant No. 81402455).

Received 1 March 2019; accepted 1 April 2019

Citation: *World Neurosurg.* (2019) 127:534-537.

<https://doi.org/10.1016/j.wneu.2019.04.006>

Journal homepage: [www.journals.elsevier.com/world-neurosurgery](http://www.journals.elsevier.com/world-neurosurgery)

Available online: [www.sciencedirect.com](http://www.sciencedirect.com)

1878-8750/\$ - see front matter © 2019 Elsevier Inc. All rights reserved.