



Pial Arteriovenous Fistula with Multiple Venous Aneurysms Resembling a Vein of Galen Aneurysmal Malformation; Case Report and Review of Literature

Mohammad Ghorbani¹, Christoph Wipplinger², Christoph J. Griessenauer^{3,4}, Seyed Ebrahim Hejazian¹, Fatemeh Zangji Abadi¹, Sina Asaadi^{1,5}

Key words

- Aneurysmal malformations
- Pial arteriovenous fistula
- Vein of Galen

Abbreviations and Acronyms

DSA: Digital subtraction angiography

pAVF: Pial arteriovenous fistula

VGAM: Vein of Galen aneurysmal malformation

From the ¹Division of Vascular and Endovascular Neurosurgery, Firoozgar Hospital, Iran University of Medical Sciences, Tehran, Iran; ²Department of Neurological Surgery, Weill Cornell Medicine, New York, New York, USA; ³Department of Neurosurgery, Geisinger Medical Center, Danville, Pennsylvania, USA; ⁴Research Institute of Neurointervention, Paracelsus Medical University, Salzburg, Austria; and ⁵Neuroscience Research Center, Shahid Beheshti University of Medical Sciences, Tehran, Iran

To whom correspondence should be addressed:
Sina Asaadi, M.D.

[E-mail: s.asaadi90@gmail.com]

Citation: *World Neurosurg.* (2019) 127:245-248.

<https://doi.org/10.1016/j.wneu.2019.04.061>

Journal homepage: www.journals.elsevier.com/world-neurosurgery

Available online: www.sciencedirect.com

1878-8750/\$ - see front matter © 2019 Elsevier Inc. All rights reserved.

INTRODUCTION

Pial arteriovenous fistulas (pAVFs) comprise approximately 4% of pediatric cerebral vascular anomalies. One or more arteries feed directly into a cortical vein without an intervening nidus, often accompanied by large venous pouches.¹ These anomalies are angiographically distinctive from arteriovenous malformations and vein of Galen malformations (VAGMs) because they lack a true vascular nidus and do not communicate directly with the vein of Galen.² Patients with pAVFs can present with radiologic findings resembling a VAGM; thus, it is essential to evaluate for both diagnoses. We describe a case of a pAVF in an 18-month-old boy with new-onset seizures who was referred to our institution with the preliminary diagnosis of a VAGM.

■ **BACKGROUND:** Pial arteriovenous fistulas are abnormal vascular connections between arteries and the cranial venous system on the surface of the brain in the pia mater. In contrast to vein of Galen aneurysmal malformations, they lack a true vascular nidus and may only indirectly involve the vein of Galen.

■ **CASE DESCRIPTION:** An 18-month-old boy was referred to us with a history of seizures, drowsiness, bulging cephalic veins, and cranial nerves palsy identified as vein of Galen aneurysmal malformation according to initial magnetic resonance imaging. Digital subtraction angiography showed a vertebrobasilar junction pial high-flow fistula between the basilar artery and anterior pontomesencephalic vein, causing retrograde flow, dilation, and tortuosity of the lateral and posterior mesencephalic vein as well as the vein of Galen. Endovascular treatment, including coil embolization of fistula site, was done successfully without complication resulting in recovery from previous symptoms and signs.

■ **CONCLUSIONS:** If cerebral venous dilations are encountered, one must keep in mind that the location of the fistula may not be in close proximity to the dilated veins, especially when there is a suspicion for vein of Galen aneurysmal malformation. Other pathologies, such as pial arteriovenous fistula, in a region away from the site of the vein of Galen must be considered.

CASE DESCRIPTION

In December 2016, an 18-month-old boy was referred to our institution with a history of new-onset tonic-clonic seizures and reduced level of consciousness for 4 days. The patient had no family history of seizures. General physical examination showed a drowsy infant with prominent bulging cephalic veins. Neurologic examination revealed left sixth and seventh nerve palsy. Magnetic resonance imaging with gadolinium performed initially at the referring facility reported 4 aneurysms including dilation in the vein of Galen (Figure 1A and B). One aneurysm measured 22 × 17 mm and exerted mass effect on the inferior part of the splenium as well as the posterior portion of the tectal plate. There was also a 20 × 17 mm aneurysm anterior and inferior to the pons and anterior to the medulla and a 15 × 12 mm aneurysm reaching posteriorly into the fourth ventricle. Dilated vessels were seen posteriorly and

laterally to the superior portion of the brainstem with aneurysmal formation seen superior to the left cerebellopontine angle about 9 mm in size with mass effect on the surrounding parenchyma.

The patient was referred to our medical center for further evaluation and treatment with the presumed diagnosis of a VGAM. Digital subtraction angiography (DSA) showed a high flow fistula at the vertebrobasilar junction between the basilar artery and anterior pontomesencephalic vein, causing retrograde flow, dilation, and tortuosity of the lateral and posterior mesencephalic vein as well as the vein of Galen (Figures 1C and D and 2A and B). We decided to perform endovascular embolization under general anesthesia. The treatment involved super-selective microcatheterization of the venous part of the fistula and occlusion of the fistula with 12 coils and complementary injection of Onyx embolic agent (Medtronic, Minneapolis, Minnesota, USA). No

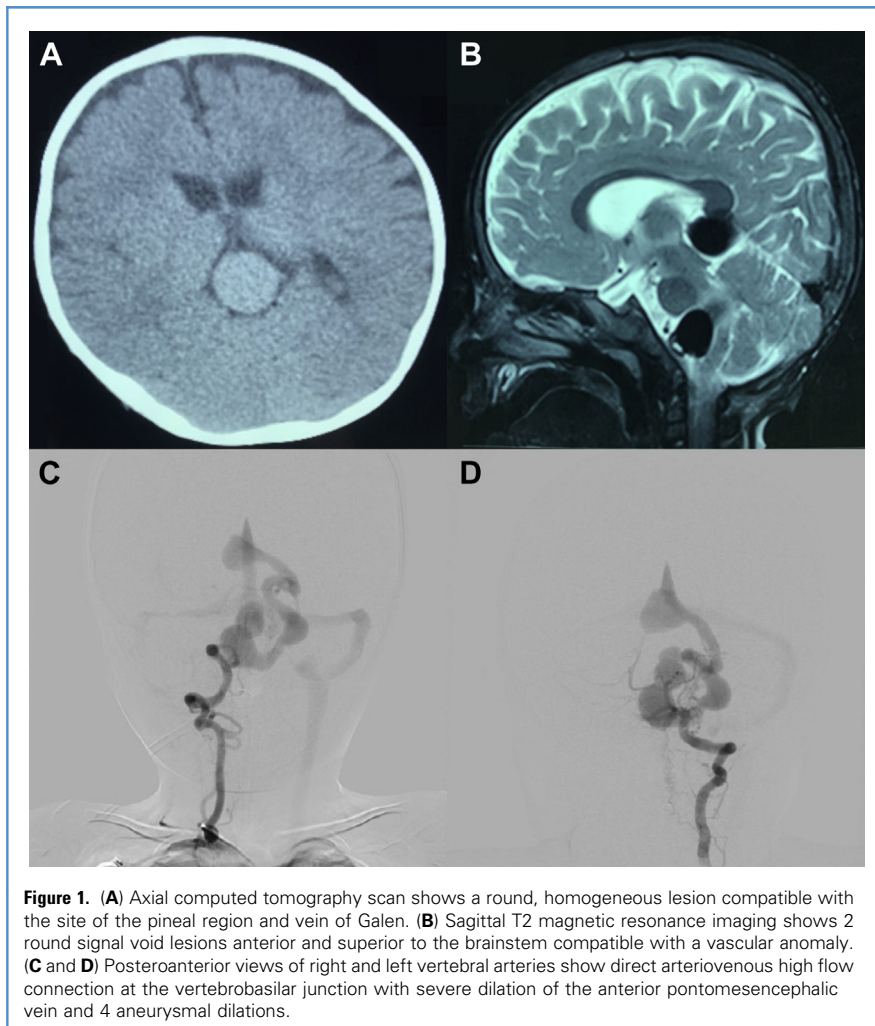


Figure 1. (A) Axial computed tomography scan shows a round, homogeneous lesion compatible with the site of the pineal region and vein of Galen. (B) Sagittal T2 magnetic resonance imaging shows 2 round signal void lesions anterior and superior to the brainstem compatible with a vascular anomaly. (C and D) Posteroanterior views of right and left vertebral arteries show direct arteriovenous high flow connection at the vertebrobasilar junction with severe dilation of the anterior pontomesencephalic vein and 4 aneurysmal dilations.

procedural or postprocedural complications occurred. Control DSA showed near-complete occlusion of the malformation (Figure 2C and D). The patient was discharged in stable condition 4 days after the intervention. At the follow-up visit after 1 month, cranial nerves were intact, and the patient had experienced no further seizures. Follow-up DSA at 1 year showed no evidence of residual fistula or recanalization.

DISCUSSION

We report a case of vertebrobasilar junction pAVF resulting in dilation of the vein of Galen, hydrocephalus, and seizures, resembling a VGAM.

Embryologic Origins

VGAM refers to a persistent embryonic median prosencephalic vein of Markowski

that develops between 6 and 11 weeks of gestation. Clinical manifestations can emerge at any age and mainly involve cardiac insufficiency, developmental delay, hydrocephalus, and seizures.³⁻⁵ In contrast, a vein of Galen aneurysmal dilation may originate from a subpial arteriovenous malformation adjacent to the cerebellum, brainstem, or deep supratentorial territories draining into a normally developed vein of Galen causing dilation due to venous overload. The degree of dilation is determined by associated flow-related stenosis or partial thrombosis at the junction between the vein of Galen and the straight sinus. In pAVF, in contrast to VGAM, the involved vein drains not only the arteriovenous malformation but also adjacent deep cerebral areas.^{6,7}

In most cases, these malformations are fed mainly by the internal carotid artery as

well as by meningeal branches of the internal and the external carotid arteries.⁸ In the present case of a pAVF, the posterior inferior cerebellar artery and the anterior inferior cerebellar artery were not affected. A high-flow fistula from the basilar artery arose between these arteries. This finding is of the interest for the hypothesis that the fistula originated from a fetal branch that normally disappears during embryonic brain development. The fistula drainage resulted in congestion of the cerebral venous system keeping the falcine sinus open during the prenatal stage and prevented its obliteration and replacement by the straight sinus.

Anatomic Differences Between VGAM and pAVF

There are few reports of dilations of the vein of Galen caused by pAVFs misdiagnosed as VGAM. However, in all previously reported cases, the fistulas were located more distally at the posterior cerebellar artery branches.⁹⁻¹¹ Han et al.⁹ reported an arteriovenous fistula between the anterior cerebral artery and the anterior pericallosal vein resulting in varix draining into the vein of Galen, leading to its dilation in the anterior fossa. Iizuka et al.¹⁰ described shunts located in the intraventricular choroid plexus, cistern verum interpositivum, and thalamus pulvinar nucleus. A case by Tawk et al.¹¹ reported VGAM with an associated venous pouch in the posterior fossa. In our case, the fistula was located more proximally at the vertebrobasilar junction leading to multiple venous dilations with shunt toward the vein of Galen. Therefore, this report is, to our knowledge, the first of its kind.

pAVFs located on the surface of the brain are often high-flow lesions, commonly leading to dilated venous pouches and causing multiple aneurysms secondary to the fistula.^{12,13} The number of pAVF cases reported in the prenatal period is surprisingly small compared with the number of cases of VGAMs, even when taking into account their extreme rarity. A possible explanation would be that many pAVFs are prenatally misdiagnosed as VGAM owing to their location and drainage into the vein of Galen.¹⁴ Similar to the vein of VGAM, the clinical presentation in patients with pAVFs leading to vein of Galen

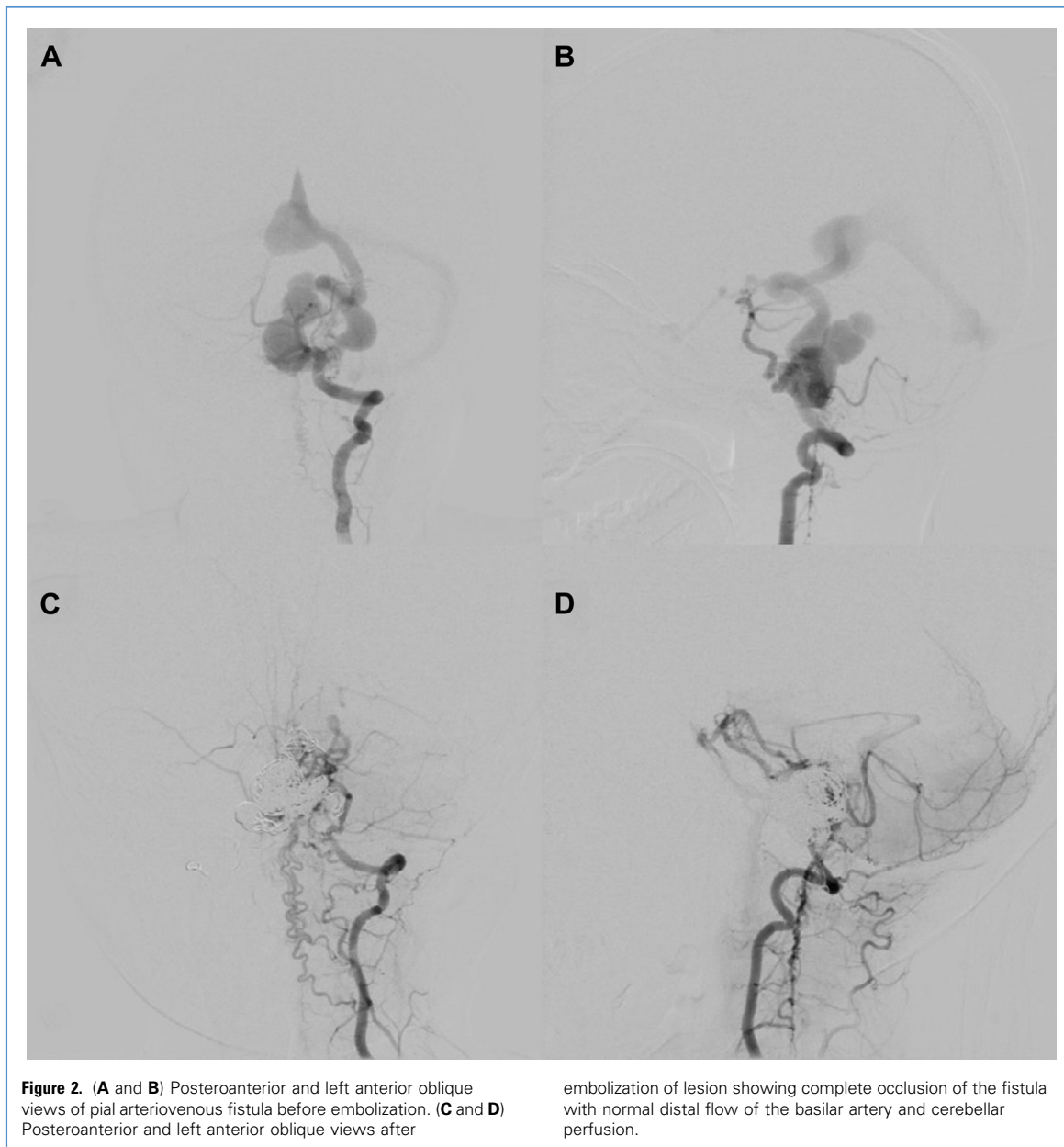

Figure 2. (A and B) Posteroanterior and left anterior oblique views of pial arteriovenous fistula before embolization. (C and D) Posteroanterior and left anterior oblique views after

embolization of lesion showing complete occlusion of the fistula with normal distal flow of the basilar artery and cerebellar perfusion.

aneurysmal dilation includes headache, exophthalmos, decreased visual acuity, intracranial murmur, subarachnoid hemorrhage, seizures, ataxia, and neurodevelopmental delay.^{8,15,16}

Diagnostic Distinction Between VGAM and pAVF

The diagnostic distinction between VGAM and pAVF is important because they require different treatment approaches. Clues to the diagnosis of pAVFs at cross-sectional

imaging include the presence of dilated vessels at the brain surface and asymmetric dilation of the pial feeding artery. This is best seen at the level of the circle of Willis, as feeders include anterior, middle, or posterior cerebral arteries. These findings can also be used to differentiate pAVFs from dural arteriovenous fistulas and may be accompanied by dilated venous pouches outside the brain parenchyma.¹⁷

Based on previous evidence, it can be concluded that pial vascular lesions

causing aneurysmal dilations in the vein of Galen are the main differential diagnosis of VGAM. Thus, in suspicious cases, especially in the presence of multiple venous aneurysms, congenital pAVF is a probable diagnosis. Another point suggesting a pathology other than VGAM is the existence of venous aneurysms in places unusual for VGAM. This was also true for the present case. Two of the 4 venous aneurysms were found in locations not compatible with VGAM as described

in previous reports. The diagnostic gold standard is DSA, which clearly showed the dilated veins and blood vessels. The occurrence of reflux into the normal cerebral venous tributaries causing dilated pouches confirmed the diagnosis of pAVF and excluded a VGAM.¹⁸

Treatment Options

Both endovascular and microsurgical approaches demonstrated acceptable results in the treatment of vein of Galen aneurysmal dilation.^{9,10} However, in a case report by Tawk et al.,¹¹ the VAGM regressed spontaneously after treating the associated hydrocephalus via ventriculoperitoneal shunting. Owing to recent advances, endovascular treatment of pediatric cerebellar vascular lesions has been described more frequently.^{19,20} We suggest the endovascular approach, as we believe that even though both microsurgical and endovascular options have similar efficacy, complications associated with open surgery as well as longer hospitalization times can be avoided. However, every case should be evaluated individually, and the risks and benefits of both procedures should be discussed with the patient and family.

CONCLUSIONS

If cerebral venous dilations are encountered, one must keep in mind that the location of the fistula may not be in close proximity to the dilated veins, especially when there is a suspicion for VGAM. Other pathologies, such as pAVF, in a region away from the site of the vein of Galen must be considered. The treatment approach and response may differ significantly from a VGAM. Therefore, a thorough work-up for possible differential diagnoses is mandatory to ensure the optimal treatment strategy and patient safety.

REFERENCES

1. Hetts SW, Keenan K, Fullerton HJ, et al. Pediatric intracranial nongalenic pial arteriovenous fistulas: clinical features, angioarchitecture, and outcomes. *AJNR Am J Neuroradiol*. 2012;33:1710-1719.
2. Weon YC, Yoshida Y, Sachet M, et al. Supratentorial cerebral arteriovenous fistulas (AVFs) in children: review of 41 cases with 63 non choroidal single-hole AVFs. *Acta Neurochir*. 2005;147:17-31.
3. Komiyama M, Nakajima H, Nishikawa M, et al. Vein of Galen aneurysms. Experience with eleven cases. *Interv Neuroradiol*. 2001;7(suppl 1):99-103.
4. Lasjaunias P, Ter Brugge K, Lopez Ibor L, et al. The role of dural anomalies in vein of Galen aneurysms: report of six cases and review of the literature. *AJNR Am J Neuroradiol*. 1987;8:185-192.
5. Mortazavi MM, Griessenauer CJ, Foreman P, et al. Vein of Galen aneurysmal malformations: critical analysis of the literature with proposal of a new classification system. *J Neurosurg Pediatr*. 2013;12:293-306.
6. Alvarez H, Garcia Monaco R, Rodesch G, Sachet M, Krings T, Lasjaunias P. Vein of Galen aneurysmal malformations. *Neuroimaging Clin North Am*. 2007;17:189-206.
7. du Toit J, Bam JA, Mngomezulu V. Endovascular treatment of vein of Galen aneurysmal malformation. *S Afr J Radiol*. 2009;13:4534.
8. Wagner MW, Vaught AJ, Poretti A, Blakemore KJ, Huisman TA. Vein of Galen aneurysmal malformation: prognostic markers depicted on fetal MRI. *Neuroradiol J*. 2015;28:72-75.
9. Han L, Wang J, Chen J, Lei T. Pial arteriovenous fistula with giant venous varix and dilation of vein of Galen, treated with surgical clipping. *Acta Neurochir*. 2013;155:1571-1572.
10. Iizuka Y, Kakihara T, Yoshimura N, Kimizuka T, Sumi Y, Kaneko K. Anatomical subcategorization for pediatric vein of Galen aneurysmal dilatation. A report of three cases. *Neuroradiol J*. 2007;20:551-561.
11. Tawk RG, Mohasseb G, Charbel FT, Debrun GM. Spontaneous disappearance of vein of Galen malformation and posterior fossa venous pouch. *Acta Neurochir*. 2002;144:1225-1231.
12. Hoh BL, Putman CM, Budzik RF, Ogilvy CS. Surgical and endovascular flow disconnection of intracranial pial single-channel arteriovenous fistulae. *Neurosurgery*. 2001;49:1351-1364.
13. Kakino S, Ogasawara K, Kubo Y, Ogawa A. Spontaneous pial single-channel arteriovenous fistulae with angiographically occult small feeding arteries: case report. *Surg Neurol*. 2008;69:187-190 [discussion: 191].
14. Koroglu M, Cil B, Yesildag A, Baykal B, Cekirge S, Oyar O. Prenatal diagnosis of intracranial pial arteriovenous fistula and endovascular treatment during the neonatal period. *Diagn Interv Radiol*. 2006;12:64-67.
15. Howarth RA, Reisner A, Chern JJ, Hayes LL, Burns TG, Berenstein A. Neurocognitive improvements following endovascular repair of vein of Galen malformation in a child. *J Neurosurg Pediatr*. 2015;15:197-202.
16. Iizuka Y, Suzuki M, Komura S, et al. Hydrovenous disorder in vein of Galen aneurysmal dilatation: special focus on tonsillar prolapse. *Neuroradiol J*. 2008;21:57-64.
17. Geibprasert S, Pongpech S, Jiarakongmun P, Shroff MM, Armstrong DC, Krings T. Radiologic assessment of brain arteriovenous malformations: what clinicians need to know. *Radiographics*. 2010;30:483-501.
18. Lasjaunias P. Vein of Galen Aneurysmal Malformation. *Vascular Diseases in Neonates, Infants and Children: Interventional Neuroradiology Management*. Berlin: Springer; 1997:67-202.
19. Garg M, Shambanduram S, Singh PK, et al. Management of pediatric posterior circulation aneurysms—12-year single-institution experience. *World Neurosurg*. 2018;116:e624-e633.
20. Chotali S, Agrawal A. Evolution of endovascular treatment in pediatric population. In: Agrawal A, Britz G, eds. *Pediatric Vascular Neurosurgery: Principles and Practice of Neurovascular Disorders (Part 1)*. Cham: Springer International Publishing; 2016:1-8.

Conflict of interest statement: The authors declare that the article content was composed in the absence of any commercial or financial relationships that could be construed as a potential conflict of interest.

Received 4 February 2019; accepted 6 April 2019

Citation: *World Neurosurg*. (2019) 127:245-248.
<https://doi.org/10.1016/j.wneu.2019.04.061>

Journal homepage: www.journals.elsevier.com/world-neurosurgery

Available online: www.sciencedirect.com

1878-8750/\$ - see front matter © 2019 Elsevier Inc. All rights reserved.