



# Recognizing Central Nervous System Involvement as a Progressive Feature of Microscopic Polyangiitis: A Diagnostic Dilemma

Tawnya Pancharovski, MD<sup>a</sup>, Saikrishna Patibandla, MD<sup>a</sup>, Aung Naing Lin, MD<sup>a</sup>, Ying Xian Liu, MD<sup>b</sup>, Stuart Green, MD<sup>c</sup>, Sima S. Pendharkar, MD<sup>a</sup>

<sup>a</sup>Department of Medicine, The Brooklyn Hospital Center, academic affiliate of the Icahn School of Medicine at Mount Sinai, clinical affiliate of Mount Sinai Hospital, Brooklyn, NY; <sup>b</sup>Department of Pathology, The Brooklyn Hospital Center, academic affiliate of the Icahn School of Medicine at Mount Sinai, clinical affiliate of Mount Sinai Hospital, Brooklyn, NY; <sup>c</sup>Department of Rheumatology, The Brooklyn Hospital Center, academic affiliate of the Icahn School of Medicine at Mount Sinai, clinical affiliate of Mount Sinai Hospital, Brooklyn, NY.

**KEYWORDS:** Microscopic polyangiitis; Vasculitis

Microscopic polyangiitis is an idiopathic autoimmune disease characterized by systemic vasculitis predominantly of small-caliber blood vessels with antineutrophilic cytoplasmic antibodies (ANCA), and it can have a variable presentation.<sup>1</sup> We present the case of a 57-year-old male smoker with central nervous system-related symptoms of left facial droop, dysarthria, and worsening left upper-extremity weakness and numbness due to multiple strokes as a manifestation of microscopic polyangiitis.

## PRESENTATION

A 57-year-old male smoker with a past medical history of hypertension, nonobstructive coronary artery disease, and bilateral hip osteoarthritis presented to the Emergency Department with a sudden onset of left facial droop and dysarthria on the morning of admission. Six weeks prior to admission, he developed intermittent petechial lesions on his buttock and lower extremities, and ulcers proximal to his ankles on the medial and lateral aspects. Three weeks prior to this presentation, he developed right shoulder pain with finger paresthesias in the right third to fifth digits. Two weeks prior, he had similar complaints with finger paresthesias in the left thumb, ring, and little fingers followed by left wrist drop. At that time, he was seen in the Emergency Department, diagnosed with left

radial nerve palsy, and discharged with a splint. Three days prior to admission, he fell at home. On the day of admission, he awoke with dysarthria and left facial droop. He reported low-grade fever but denied headache, dizziness, blurry vision, night sweats, nausea, vomiting, diarrhea, hematuria, hematochezia, hemoptysis, weight loss, bladder incontinence, or other urinary symptoms.

## ASSESSMENT

On admission, his vital signs were unremarkable. He was alert, awake, and oriented. His respiratory, cardiovascular, and abdominal examination were unremarkable. His lower extremities showed petechial lesions on the digits, scabbed necrotic ulcers on his ankles, and shiny atrophic skin with absent pedal and digital hair. There was no synovitis, evidence of rheumatoid arthritis, or sicca-related features. The initial neurological examination showed facial asymmetry with mild left facial droop, and mildly dysarthric speech. His left distal upper extremity showed 0/5 strength, with decreased sensation of the left upper extremity, and the right upper extremity showed 4/5 strength with intact sensation. The lower extremities showed 5/5 strength with intact sensation, except proprioception was absent in the feet bilaterally. He was seen by Neurology and thought to have a possible right middle cerebral subcortical acute ischemic stroke in the setting of bilateral lower-extremity vascular disease and possible bilateral upper-extremity mononeuritis.

Initial laboratory studies showed a leukocytosis of 15,000, with 1800 eosinophils and no thrombocytopenia. Electrolytes were within normal limits, while urinalysis was positive for 2-10 red blood cells, granular casts, and 3+ protein. His erythrocyte sedimentation rate was elevated at 115 (normal:

**Funding:** None.

**Conflict of Interest:** All authors have no conflict of interest to declare.

**Authorship:** All authors had access to data and a role in writing the manuscript.

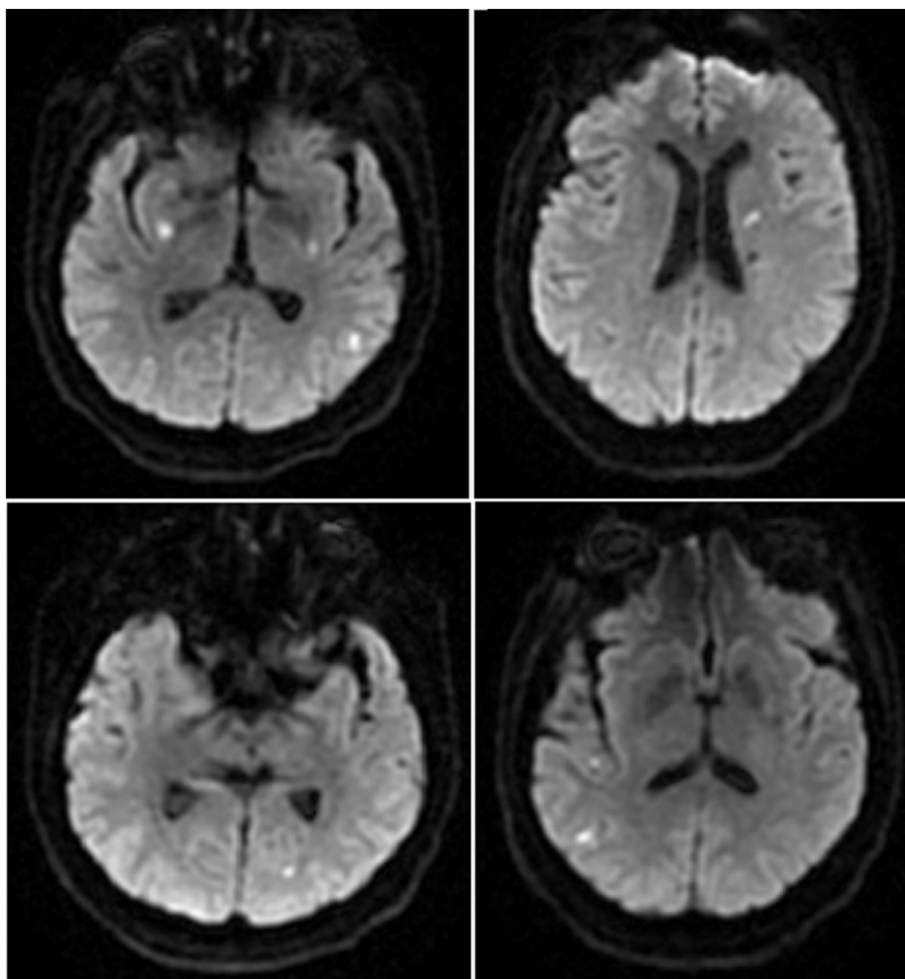
Requests for reprints should be addressed to Sima S. Pendharkar, MD, Department of Hospital Medicine, Brooklyn Hospital Center, 317 Hart Street, Brooklyn, NY 11206.

E-mail address: [pendharkars0@gmail.com](mailto:pendharkars0@gmail.com)

0-15 mm/h), and C-reactive protein was 140.84 (normal: <5 mg/dL). His chest x-ray study was unremarkable. A computed tomography scan of the head revealed an old infarct in the left corona radiata without evidence of acute ischemia or hemorrhage, and a computed tomography scan of the spine was significant for mild degenerative joint disease. The patient presented >4 hours after the onset of symptoms, and the Neurology team recommended medical management as per our stroke protocol. He was empirically treated with broad-spectrum antibiotics for suspicion of infective endocarditis based on minor clinical criteria, including vascular phenomena. Subsequent magnetic resonance imaging of the brain (Figure 1) showed scattered punctate foci involving the left corona radiata, bilateral basal ganglia, left parieto-occipital lobe, and bilateral temporal lobes compatible with multiple acute and sub-acute infarcts, while a magnetic resonance angiogram of the head and neck was unremarkable. No arrhythmia was seen on telemetry for 48-72 hours. Infective endocarditis was ruled out by 2 sets of negative blood cultures, and no vegetations were seen on transthoracic or transesophageal echocardiograms.

## DIAGNOSIS

Based on the eosinophilia, protein/creatinine ratio of 1.8, and urinalysis findings, he had further testing. Syphilis serology was negative. His thyroid-stimulating hormone was normal at 1.11 mIU/mL, and B12 was 161 pg/mL (normal: 213-816 pg/mL) with normal methylmalonic acid. A positive antinuclear antibody titer of 1:640, anti-Sjögren's-syndrome-related antigen A antibodies >8.0 (normal: <1.0), and rheumatoid factor  $\geq 320$  IU/mL (normal: <10 IU/mL) was found. A cyclic citrullinated peptide level was not obtained. The following antibodies were negative: anti-double-stranded DNA, anti-Smith, antiribonucleoprotein, anticardiolipin, immunoglobulin G, immunoglobulin M, beta-2 glycoprotein, and lupus anticoagulant. Antithrombin activity and Protein C and S were also within normal range. Serum immunofixation was negative for Bence Jones proteinuria, and there was a normal serum free kappa/lambda ratio of 1.33. At the time, the underlying etiology was unclear. Rheumatology was consulted for the constellation of multiorgan involvement and recommended ANCA and additional testing. He had positive perinuclear antineutrophil cytoplasmic antibodies (P-ANCA)



**Figure 1** Magnetic resonance imaging head without contrast images showing scattered punctate foci of restricted diffusion compatible with multiple acute/subacute infarcts of likely embolic etiology.

>1:640 (normal <1:20), with a myeloperoxidase (MPO) antibody level of 175 (normal: <1.0), and normal C3 and C4. A renal biopsy was not performed, as the patient was on aspirin and Plavix (Sanofi-Aventis, Bridgewater Township, NJ). A skin biopsy (Figures 2-3) from the lower-extremity ulcers showed perivascular inflammation and was consistent for acute vasculitis under the skin ulcer. The elevated MPO level, renal abnormalities, eosinophilia, proteinuria, skin biopsy, and clinical presentation supported the final diagnosis of microscopic polyangiitis.

## MANAGEMENT

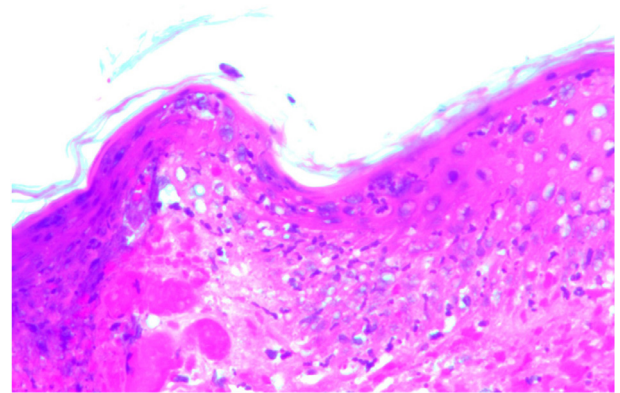
A pulse dose of methylprednisolone 1000 mg for 3 days was administered. Additionally, rituximab was initiated for induction therapy.<sup>1</sup> His neurological symptoms improved after the first cycle of rituximab; the P-ANCA titer and MPO level decreased to 1:80 and 14.4, respectively. A total of 4 cycles of rituximab was recommended. The patient was discharged to a physical rehabilitation facility after the first dose of rituximab, where he received the other doses with 60 mg of daily prednisone. Bactrim DS was given 3 times weekly for pneumocystis pneumonia prophylaxis.

## FOLLOW-UP

After 4 weeks of physical therapy, the patient's condition significantly improved. However, to our dismay, the patient collapsed at the rehabilitation facility and was found to be in asystole. He was resuscitated immediately and taken to the hospital. Unfortunately, the patient expired due to myocardial infarction and multiple organ failure.

## DISCUSSION

Primary small-vessel vasculitis may be ANCA associated or non-ANCA associated (eg, paraneoplastic or immune complex mediated), with strong evidence that ANCA specificity

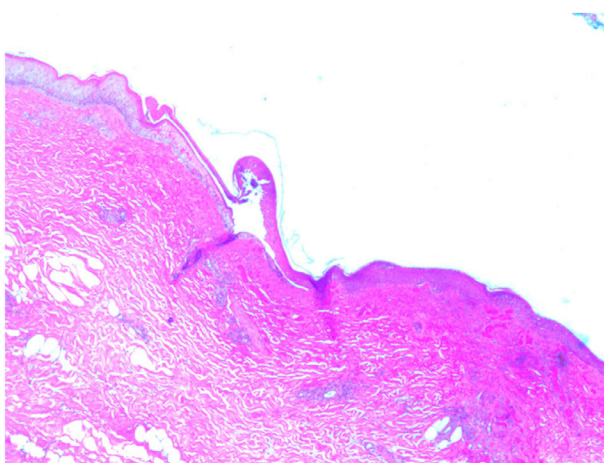


**Figure 3** 200× hematoxylin and eosin stain of skin biopsy showing necrotic squamous epithelium with neutrophils.

is helpful in providing distinct categories of disease process.<sup>2,3</sup> Granulomatosis with polyangiitis, microscopic polyangiitis, and eosinophilic granulomatosis with polyangiitis are ANCA-associated small-vessel vasculitides. The pathogenesis of these is thought to be that ANCA activate cytokine-primed neutrophils and monocytes, which express proteinase 3 (C-ANCA) and MPO (P-ANCA), leading to inflammation and necrosis of the blood vessel wall.<sup>4</sup>

While systemic vasculitides are uncommon in the US, the adult prevalence of microscopic polyangiitis specifically is estimated to be approximately 1.3 per 100,000 individuals, with an annual incidence of 1.6 per 100,000 individuals when adjusting for age and sex.<sup>5</sup> When diagnosing vasculitis, the nomenclature derived from the International Chapel Hill Conference does not specify criteria by which patients are classified to guide clinical care.<sup>6</sup> Thus, the criteria for microscopic polyangiitis are still being developed as we continue to observe unique and atypical case presentations.

Peripheral neuropathy such as mononeuritis multiplex with symmetric distal polyneuropathy is the characteristic presentation for microscopic polyangiitis. Epidural inflammation,<sup>7</sup> bilateral brachial plexopathy,<sup>8</sup> and lower extremity polyneuropathy<sup>9</sup> have also been reported. Central nervous system involvement occurs in only 5%-15% of patients.<sup>10</sup> Single or diffuse ischemic, hemorrhagic, or granulomatous lesions can occur, but the patient may also present with neurological findings such as headaches, cognitive impairment, focal paresis, or seizures.<sup>10</sup> Cerebrovascular involvement in MPO-ANCA-associated vasculitis has been reported in up to 4% of patients.<sup>11</sup> Clinical acumen is imperative in distinguishing these lesions from central nervous system infections and cardioembolic or atherosclerotic phenomena, as well as complications arising from collagen vascular diseases like systemic lupus erythematosus, rheumatoid arthritis, or Sjögren's syndrome. Once microscopic polyangiitis is diagnosed, glucocorticoids and either cyclophosphamide or rituximab should be administered for induction of remission; azathioprine or methotrexate is recommended for maintenance therapy.<sup>12</sup>



**Figure 2** 20× hematoxylin and eosin stain of skin biopsy showing acute inflammation and ulceration of the skin with focal blistering changes.

Our patient had neurological, renal, and dermatological features, but no pulmonary features. He presented after nearly 2 months of symptoms with multiple focal neurological deficits. Although an ischemic stroke was initially considered, the combination of mononeuritis multiplex with a relapsing and remitting course and multiple strokes made atherosclerotic disease very unlikely. Sjögren's syndrome can present with vasculitis, sensory or sensorimotor polyneuropathy, and various central nervous system features.<sup>13</sup> However, this was ruled out. The findings of neurological features with nonhealing atypical ulcers and petechiae, eosinophilia, proteinuria, and overall clinical picture were more suggestive of vasculitis. The ability to recognize this constellation of symptoms as one syndrome could result in the prevention of multifocal ischemic stroke, end organ damage, and permanent disabilities. Acknowledging that rare central nervous system manifestations are present in microscopic polyangiitis will help clinicians diagnose and initiate a treatment regimen in a timely manner, to prevent the devastating disease morbidity and mortality associated with this fascinating, yet potentially debilitating disease process.

## References

1. Chung SA, Seo P. Microscopic polyangiitis. *Rheum Dis Clin N Am* 2010;36(3):545-58.
2. Mansi IA, Opran A, Rosner F. ANCA-associated small-vessel vasculitis. *Am Fam Physician* 2002;65(8):1615-20.
3. McKinney EF, Willcocks LC, Broecker V, Smith KGC. The immunopathology of ANCA-associated vasculitis. *Semin Immunopathol* 2014;36(4):461-78.
4. Kamesh L, Harper L, Savage COS. ANCA-positive vasculitis. *J Am Soc Nephrol* 2002;13(7):1953-60.
5. Berti A, Cornec D, Crowson CS, Specks U, Matteson EL. The epidemiology of antineutrophil cytoplasmic autoantibody-associated vasculitis in Olmsted County, Minnesota: a twenty-year US population-based study. *Arthritis Rheumatol* 2017;69(12):2338-50.
6. Jennette JC. Overview of the 2012 revised International Chapel Hill Consensus Conference nomenclature of vasculitides. *Clin Exp Nephrol* 2013;17(5):603-6.
7. Kaaroud, Boubaker K, Beji S, et al. Microscopic polyangiitis: an unusual neurologic complication. *Saudi J Kidney Dis Transplant* 2011;22(2):331-4; . Available at: <http://www.sjkdt.org/article.asp?issn=1319-2442;year=2011;volume=22;issue=2;page=331;epage=334;aulast=Kaaroud>. Accessed November 26, 2018.
8. Naseri Alavi SA, Meshkini M, Pourlak T, Khabbazi A. Microscopic polyangiitis complicated with bilateral brachial plexopathy: a case report and review of the literature. *Rheumatol Int* 2016;36(7):997-1001.
9. Rašić S, Džemidžić J, Karasalihović Z, Herenda V, Rebić D. Microscopic polyangiitis presented with polyneuropathy of lower extremities and ANCA-associated glomerulonephritis: case report. *Bosn J Basic Med Sci* 2012;12(1):55-8.
10. Wludarczyk A, Szczeklik W. Neurological manifestations in ANCA-associated vasculitis - assessment and treatment. *Expert Rev Neurother* 2016;16(8):861-3.
11. Kurata A, Kawashima S, Terado Y, et al. AP-VAS 2012 case report: a case of systemic MPO-ANCA-associated vasculitis that demonstrated brain infarction and immunohistochemically MPO-positive capillaries. *CEN Case Rep* 2013;2(2):148-53.
12. Yates M, Watts RA, Bajema IM, et al. EULAR/ERA-EDTA recommendations for the management of ANCA-associated vasculitis. *Ann Rheum Dis* 2016;75(9):1583-94.
13. Perzyńska-Mazan J, Maślińska M, Gasik R. Neurological manifestations of primary Sjögren's syndrome. *Reumatologia* 2018;56(2):99-105.