



Clinical Vasospasm After an Extended Endoscopic Endonasal Approach for Recurrent Pituitary Adenoma: Illustrative Case and Systematic Review of the Literature

Eric Suero Molina¹, Alberto Di Somma², Walter Stummer¹, Francesco Briganti³, Luigi Maria Cavallo⁴

Key words

- Cerebral vasospasm
- Delayed cerebral ischemia
- Extended endoscopic

Abbreviations and Acronyms

CSF: Cerebrospinal fluid
CT: Computed tomography
DSA: Digital subtraction angiography
EEEA: Extended endoscopic endonasal approach
ICA: Internal carotid artery
MRI: Magnetic resonance imaging
SAH: Subarachnoid hemorrhage
TCD: Transcranial Doppler

From the ¹Department of Neurosurgery, University Hospital Münster, Münster, Germany; ²Department of Neurological Surgery, Hospital Clinic de Barcelona, Universidad de Barcelona, Barcelona, Spain; ³Unit of Interventional Neuroradiology, Department of Advanced Biomedical Sciences, "Federico II" University, Naples, Italy; and ⁴Division of Neurosurgery, Department of Neurosciences, Reproductive and Odontostomatological Sciences, Università degli Studi di Napoli "Federico II", Naples, Italy

To whom correspondence should be addressed:
 Eric Suero Molina, M.D.

[E-mail: eric.suero@ukmuenster.de]

Supplementary digital content available online

Citation: *World Neurosurg.* (2019) 128:29-36.

<https://doi.org/10.1016/j.wneu.2019.04.046>

Journal homepage: www.journals.elsevier.com/world-neurosurgery

Available online: www.sciencedirect.com

1878-8750/\$ - see front matter © 2019 Elsevier Inc. All rights reserved.

INTRODUCTION

Clinical vasospasm after transsphenoidal tumor resection is a rare but potentially devastating complication. Onset and course of symptoms of cerebral vasospasm resemble those of patients after non-traumatic subarachnoid hemorrhage (SAH). Because of a lack of specific scientific evidence, treatment and management of vasospasms after transsphenoidal surgery are performed in a similar way to nontraumatic SAH. So far, approximately 30 patients have been reported in the literature.¹⁻³ However, almost all these patients were operated in the microscopic era, and reports of vasospasm after an extended endoscopic endonasal approach (EEEA) are rare. As

■ **BACKGROUND:** Cerebral vasospasm causing delayed cerebral ischemia after transsphenoidal surgery is a rare but life-threatening complication. Reports in the literature after extended endoscopic endonasal approach (EEEA) are scarce. Considering the progressive use of this technique during recent years, a better understanding of the potential adverse effects after this procedure is needed. The aim of this report was to systematically analyze the current literature and discuss management and causes for cerebral vasospasm after EEEA surgery.

■ **METHODS:** We performed a systematic search of the literature according to the Preferred Reporting Items for Systematic Reviews and Meta-Analyses statement and aimed to discuss relevant risk factors for cerebral vasospasm after extended transsphenoidal surgery.

■ **RESULTS:** Thirty-four cases of delayed cerebral vasospasm after transsphenoidal surgery were identified. Among these, 4 were operated with an EEEA. We provide an extensive literature review and discuss causes and management of this delayed complication. We further present the case of a young woman who underwent resection for a large suprasellar recurrent pituitary adenoma. Surgery and initial postoperative course were uneventful. On the eighth postoperative day, the patient developed aphasia and brachiofacial paresis. Digital subtraction angiography (DSA) demonstrated cerebral vasospasm, and repeated intra-arterial nimodipine infusion was administered. The patient recovered completely and was discharged without neurologic deficits.

■ **CONCLUSIONS:** The threshold for DSA after unexplained neurologic deterioration after extended transsphenoidal surgery should be low, and cerebral vasospasm should be treated early and aggressively. Surgeons performing EEEA need to consider the possibility of this delayed complication.

extended endonasal approaches further develop, surgery is becoming more extensive, leading to more manipulation in the suprasellar space. Here, we present a case of an EEEA for resection of a recurrent pituitary adenoma with delayed postoperative vasospasm, to heighten awareness for this possible complication when faced with secondary neurologic deterioration. Furthermore, we performed a systematic search of the literature to evaluate contributing factors with the goal of early identifying patients at risk.

METHODS

We performed a systematic literature search according to the Preferred Reporting

Items for Systematic Reviews and Meta-Analyses statement.⁴ We searched the MEDLINE/PubMed database for articles published in English before November 2018 without neglecting publications of any earlier date. We searched for title and abstract using the following algorithm: "vasospasm" combined with "pituitary," "transsphenoidal," "macroadenoma," "microadenoma," "adenoma," "craniopharyngioma," or "transnasal." The original search delivered 187 records, with 89 articles remaining after removal of duplicates. After excluding nonrelevant articles, 29 articles were included in the qualitative synthesis of this review.^{1-3,5-27} We performed a cross-reference check and included other

Table 1. Cases of Vasospasm after EEEA from the Reviewed Literature

Study	Number of Patients	Age (years)/ Sex	Pathology	Classification	Suprasellar Extension	Approach	Preoperative Encasement/ Displacement of Arteries	Intraoperative CSF Leak/ Subarachnoid Space Opening	Intraoperative Complications
Zada et al., 2011 ²⁵	1	66/M	PA	Null-cell adenoma	Yes	EEEA	Yes	Yes	n.r.
Mansouri et al., 2012 ¹⁷	1	75/M	PA	Null-cell adenoma	Yes	EEEA	Yes	Yes	Bleeding from the (L) CV
Koutourousiou et al., 2014 ¹⁶	1	n.r./elderly	Meningioma	n.r.	Yes	EEEA	n.r.	n.r.	n.r.
Bierer et al., 2017 ⁶	1	54/M	Meningioma	Grade I	Yes	EEEA	Yes	Yes	n.r.
Current study	1	23/F	Rec. PA	Null-cell adenoma	Yes	EEEA	Yes	Yes	None

CSF, cerebrospinal fluid; SAH, subarachnoid hemorrhage; M, male; PA, pituitary adenoma; EEEA, extended endoscopic endonasal approach; n.r., not reported; ACA, anterior cerebral artery; L, left, R, right; PCA, posterior cerebral artery; i.a., intra-arterial; Tc, transcranial; RH, right hemiparesis; Sc, supraclinoid; MCA, middle cerebral artery; HT, hypertension; HV, hypervolemia; EVD, external ventricular drainage; HC, hydrocephalus; GOS, Glasgow Outcome Scale; F, female; Rec., recurrent; ICA, internal carotid artery; i.v., intravenous; CV, cavernous sinus; PA, pituitary adenoma.

articles when appropriate.²⁸ We reviewed all published articles reporting cases or discussing postoperative vasospasm after endonasal transsphenoidal surgery. Patients presenting with primary pituitary apoplexy and early vasospasm were not included because of the different natural history of the disease. For further evaluation, we selected only patients having undergone EEEA. If not clearly described, a transsphenoidal approach was assumed.

All procedures involving human participants were in accordance with the ethical standards of the institutional and/or national research committee and with the 1964 Helsinki Declaration and its later amendments or comparable ethical standards. Patient consent was acquired. For this type of systematic review, formal ethic committee consent is not required.

RESULTS

Among the reviewed articles, 34 cases of delayed vasospasm after transsphenoidal surgery could be identified, of which 4 were operated with an EEEA.^{6,16,17,25} Both meningioma (n = 2) and pituitary adenoma (n = 2) were reported as the underlying pathology. One patient was part of a large

clinical series; hence, further clinical details are missing.¹⁶ From patients with available data, every patient had an intraoperative cerebrospinal fluid (CSF) leak and suffered from postoperative hematoma in the subarachnoid space. All tumors had suprasellar extension and encasement or displacement of adjacent arteries. Onset of symptoms was at a median of 8 days (range, 7–11 days). Management was mainly performed with intra-arterial vasodilators, but also by induced hypertension and hypervolemia. All cases underwent subsequent surgery for hematoma evacuation, either transcranial^{6,25} or transsphenoidal.¹⁷ One patient suffered postoperative leak and meningitis. Mortality was reported in 2 cases (Table 1).^{16,17}

Clinical Presentation

A 23-year-old woman presented to the Division of Neurosurgery, Università degli Studi di Napoli “Federico II” with recurrence of a nonfunctioning pituitary adenoma. The patient had undergone a transsphenoidal subtotal microscopic resection in another department 2 years prior. Subtotal removal was achieved in the first surgery. Since then, because of partial hypopituitarism, the patient required

thyroid hormonal substitution and oral desmopressin (60 µg 2 times per day). Prior to admission, residual tumor from the first procedure with right-sided extension in the suprasellar space with encasement of the internal carotid artery (ICA) and displacement of the arteries of the anterior circulation was found to be progressive on magnetic resonance imaging (MRI) (Figures 1A and 1B). Ophthalmologic evaluation revealed a marked reduction in retinal sensitivity in the nasal field with beginning atrophy of the left optic nerve and a visual acuity of 6 of 10, whereas the patient was blind in her right eye.

Surgical Procedure. The suprasellar region was reached endoscopically through an endonasal transplanum approach. After performing a turbinectomy on the left side, the sphenoidal sinus was opened with subsequent removal of reconstruction material from the previous surgery. The bony opening was extended to the planum sphenoidale. The limits of the bone opening were the medial opticocarotid recess on both sides and the origin of the posterior ethmoidal arteries anteriorly. The tumor could be accessed after opening the dura. The subarachnoid space was opened, and the tumor was carefully

Table 1. Continued

Postoperative Day Onset	Clinical Symptoms Onset	SAH	Involved Vessel	Therapy	Duration of Symptoms	Cerebral Infarction	Follow-Up Surgeries	Other Complications	Outcome
8	Consciousness deterioration	Yes	ACA (L, R), PCA (L)	i.a. verapamil	No recovery	Yes	Tc hematoma evacuation	-	Death
7	RH, decreased consciousness	Yes	Sc ICA, MCA (L)	HT, HV	n.r.	Yes	Endoscopic hematoma evacuation, EVD	HC	Significant impairment, mild RH, GOS score 3
n.r.	n.r.	n.r.	n.r.	n.r.	n.r.	n.r.	n.r.	n.r.	Death
~11 days	Headache	No	A1, M1 (L, R), basilar	Antibiotics	n.r.	Yes	Twice for CSF leak repair	Nasoseptal flap necrosis, postoperative leak, meningitis	No "obvious" neurologic deficits
8	Brachiofacial paresis (L), aphasia	Yes	ICA, M1, A1 (R)	i.a. + i.v. nimodipine, HT	~14 days	Yes	No	-	Slight mouth asymmetry, no further neurologic deficit

dissected from adjacent arteries. Papaverine solution was used intraoperatively. After completing the resection, no residual tumor could be observed. Reconstruction was performed using periumbilical fat, a vascularized nasoseptal flap, and a mucoperichondrial turbinate flap. No lumbar drain was used (Figures 2A and 2B, and Video 1). The postoperative course was initially uneventful. Histopathologic analysis demonstrated a null-cell adenoma according to the latest World Health Organization classification.²⁹ The Ki67/MIB1 index was 3%, without p53 mutation.

Postoperative Events. Prophylactic therapy with intravenous nimodipine at a rate of 0.8 mg/h was initiated immediately after surgery. Vital signs and particularly systolic blood pressure were monitored cautiously. A routine computed tomography (CT) scan performed on the first postoperative day demonstrated minor pneumocephalus in the surgical field and a hyperdensity, compatible with a hematoma without mass effect, in the suprasellar space (Figures 3A–3C). The patient remained

asymptomatic. On the eighth postoperative day, a contrast-enhanced MRI was routinely performed showing complete removal of the tumor. However, it also demonstrated a constriction of the distal right ICA and proximal M1 segment of the middle cerebral artery. Remarkably, the patient was asymptomatic at that time. In the evening of the same day, however, the patient developed mouth asymmetry accompanied by slurred speech and moderate weakness of the upper left limb. A CT angiogram showed

filiform constriction of the A1 segment of the anterior cerebral artery, and the known narrowing of the middle cerebral artery and ICA on the right side, indicating vasospasm. Digital subtraction angiography (DSA) revealed severe vasospasm. Intra-arterial nimodipine (10 mg) was locally applied with immediate enlargement of the A1 and M1 segments (Figures 4A and 4B). Also, the intravenous nimodipine infusion rate was raised to 1.4 mg/h, and blood pressure elevated. On the ninth postoperative day, DSA and intra-arterial nimodipine (10 mg) application was repeated as response to another episode of worsening of the brachiofacial palsy. MRI

at this time revealed a region of restricted diffusion in the corona radiata and the lenticular nucleus within the basal ganglia on the right side. DSA on postoperative day 14 showed an improvement, and a further 5 mg of intra-arterial nimodipine was applied (Figures 4A and 4B). Except for slight mouth asymmetry, neurologic function recovered completely. No further complications were recorded. Follow-up MRI 3 months after surgery demonstrated the previously observed mild diffusion restriction, a complete tumor resection, and no subarachnoid blood (Figures 5A–5C). At the last day of follow-up, no facial paresis or other neurologic symptoms could be observed.

DISCUSSION

In nontraumatic SAH, vasospasm leading to delayed cerebral ischemia sometimes escalating to infarction is a large cause for mortality.³⁰ One of the first reported cases of cerebral vasospasm after transcranial tumor resection was in a pituitary adenoma.³¹ Clinical presentation often comprises hemiparesis and aphasia, and cranial nerve palsies, seizures, hypesthesia or paresthesia, and cognitive decline.^{1,3}



Video available at
www.sciencedirect.com

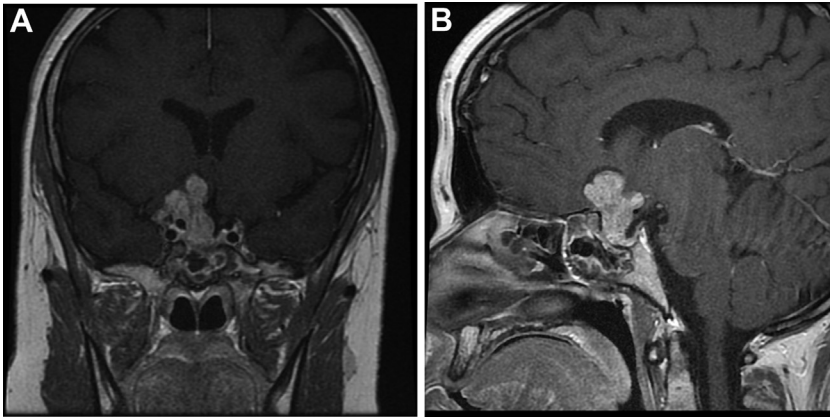


Figure 1. Preoperative magnetic resonance imaging with (A) coronal and (B) sagittal sequences demonstrating the large recurrence of a null-cell pituitary adenoma with suprasellar extension, encasement of the right internal carotid artery and cavernous sinus, and displacement of the anterior cerebral artery on the left side.

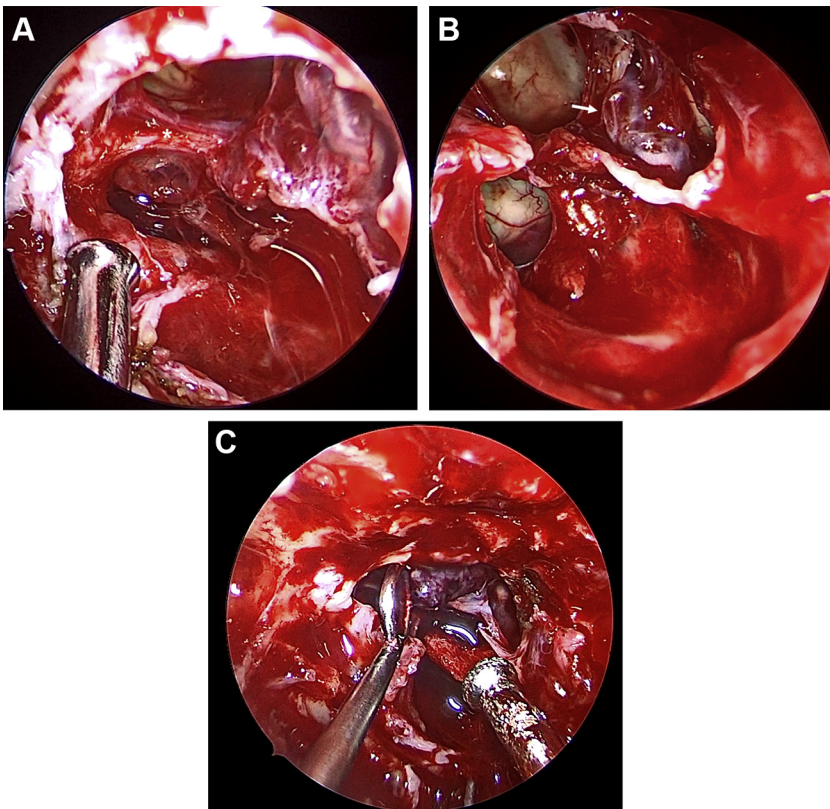


Figure 2. Intraoperative endoscopic imaging during an extended endoscopic endonasal transplanum approach with visualization of the (A) right optic atrophic nerve and (B) displacement of the anterior artery complex with the anterior communicating artery (*asterisk*) and recurrent artery of Heubner (*arrow*) and (C) gray-reddish appearance of the lesion.

Opening the Subarachnoid Space

Blood leakage into the subarachnoid space, as it is with nontraumatic SAH, has been strongly associated with cerebral vasospasm,³²⁻³⁵ and after transsphenoidal surgery blood spillage has been related to delayed constriction of vessels.²² However, vasospasm is reported to occur not solely in the immediate vicinity of the tumor bed, suggesting a multifactorial pathogenesis: the interaction of inflammation processes with blood products, specifically oxy- and methemoglobin releasing free radicals in the subarachnoid cisterns, decreasing levels of endothelial nitric acid, triggering lipid peroxidation, potentially damaging endothelia, and contributing to delayed cerebral ischemia.^{15,36,37} Not only the occurrence of SAH per se but also the size of the hematoma is relevant,⁷ as reported in nontraumatic SAH stratifying patients by location and volume of leaked blood.³⁸ Conversely, in a recent review, 61.5% of patients with delayed vasospasm did not have any intraoperative CSF leak and therefore had no blood in the subarachnoid space,³ whereas another publication reports cerebral vasospasm only in 26.7% of 15 evaluated patients with postoperative SAH after transsphenoidal surgery.¹⁵ Patients with tumor encasement of adjacent arteries on preoperative imaging are prone to develop vasospasm,³⁹ as was the case in all reviewed patients (**Table 1**).

Even though rare, it appears that fluid from the cystic portion of craniopharyngiomas can induce vasospasm.^{12,40} In an animal experiment, Kamal et al.¹² reported an onset of vasospasm 4 days after its instillation in the femoral vessel of rats.

Spasmogenic Substances

Vasoactive substances liberated from pituitary tumor or the hypothalamo-hypophyseal region (e.g., endothelin, angiotensin or lipid metabolites),⁴¹⁻⁴³ or influencing intracellular calcium levels, have been discussed in the context of delayed cerebral ischemia.⁴⁴ Hypothalamic damage or dysfunction caused by sympathetic activation with liberation of catecholamines can lead to secretion of spasmogenic factors.⁴⁵⁻⁴⁹ Others propose that hypothalamic dysfunction can induce polyuria

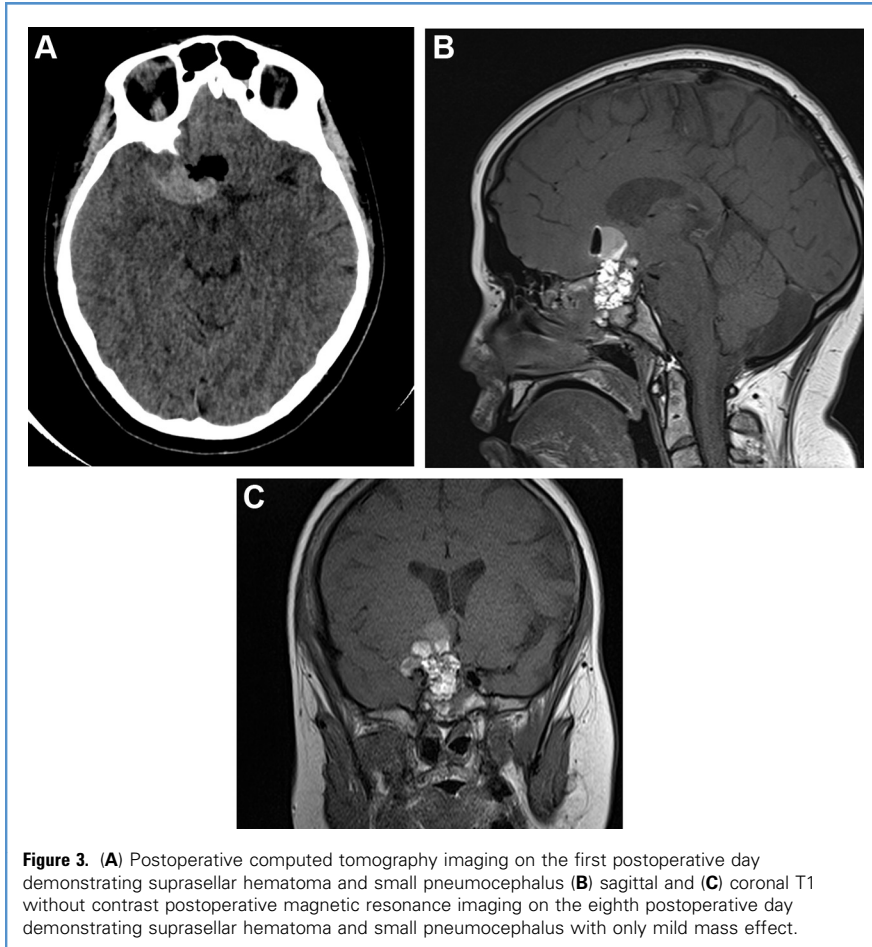


Figure 3. (A) Postoperative computed tomography imaging on the first postoperative day demonstrating suprasellar hematoma and small pneumocephalus (B) sagittal and (C) coronal T1 without contrast postoperative magnetic resonance imaging on the eighth postoperative day demonstrating suprasellar hematoma and small pneumocephalus with only mild mass effect.

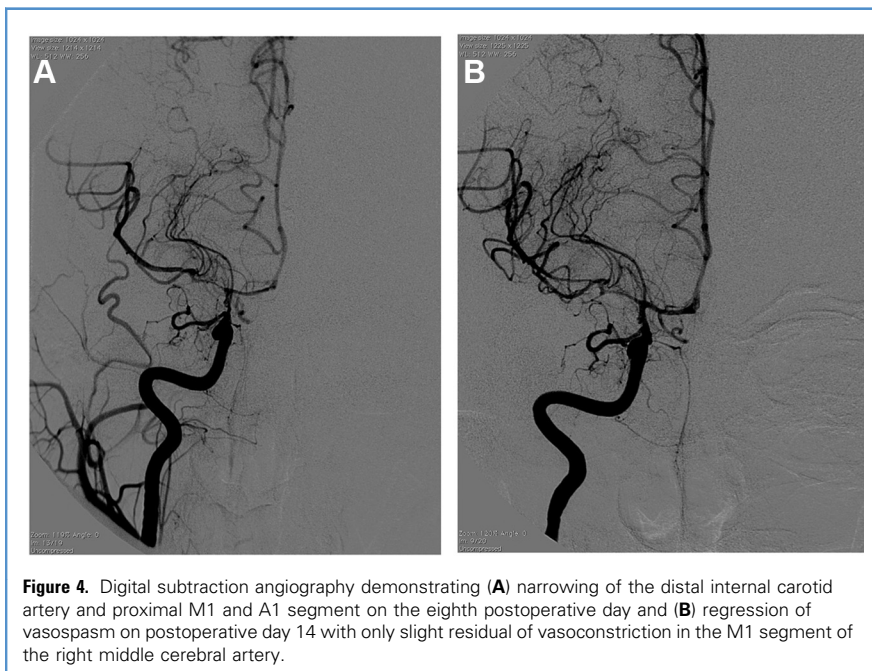


Figure 4. Digital subtraction angiography demonstrating (A) narrowing of the distal internal carotid artery and proximal M1 and A1 segment on the eighth postoperative day and (B) regression of vasospasm on postoperative day 14 with only slight residual of vasoconstriction in the M1 segment of the right middle cerebral artery.

leading to hypovolemia and vessel constriction.^{7,50} Larger tumors with suprasellar extension could be adjacent to the hypothalamus, making this region vulnerable for injury.

Although we deliberately dismissed cases initially presenting with pituitary apoplexy, it merits mention that secreting substances from necrotic pituitary tissue and blood can be vasoactive and lead to cerebral ischemia.^{9,51-54} However, these patients usually present with an earlier onset of symptoms.

Electrolyte and Fluid Disorders

Because of known diabetes insipidus prior to surgery, our patient received desmopressin regularly. No fluid disorder was observed postoperatively. Nevertheless, fluids need to be strictly controlled in this type of patients because diabetes insipidus after dehydration and volume contraction have also been reported to cause vasospasm.^{2,55} Fluid disorders might lead to microcirculation disturbances as a consequence of electrolyte imbalance and hypovolemia.¹² Cerebral salt wasting syndrome and hyponatremia are known risk factors for vasospasm in nontraumatic SAH,⁵⁶ and similar reports have shown comparable events after transsphenoidal surgery.¹⁵

Timing

After transsphenoidal surgery, a recent review indicated a mean onset of 8 days postoperatively.^{1,2} Another older review described 20 cases where the mean time of onset of symptomatic vasospasm ranged from 3 to 13 days postoperatively.²⁶ In our reviewed series, the mean onset time was 8 days (range, 7–11 days).

In the cases reviewed in this article, 1 patient developed vasospasm even after 11 days, where the underlying etiology was most probably meningitis after postoperative CSF leak. Meningitis^{8,14} and postoperative CSF leak³ have been previously associated with cerebral vasospasm after transsphenoidal surgery.

Management

Induced hypertension and prophylaxis with the calcium-antagonist nimodipine are well acknowledged therapies.^{38,39} However, nimodipine, as a vasodilator, leads to hypotension, which should be carefully monitored in these patients.

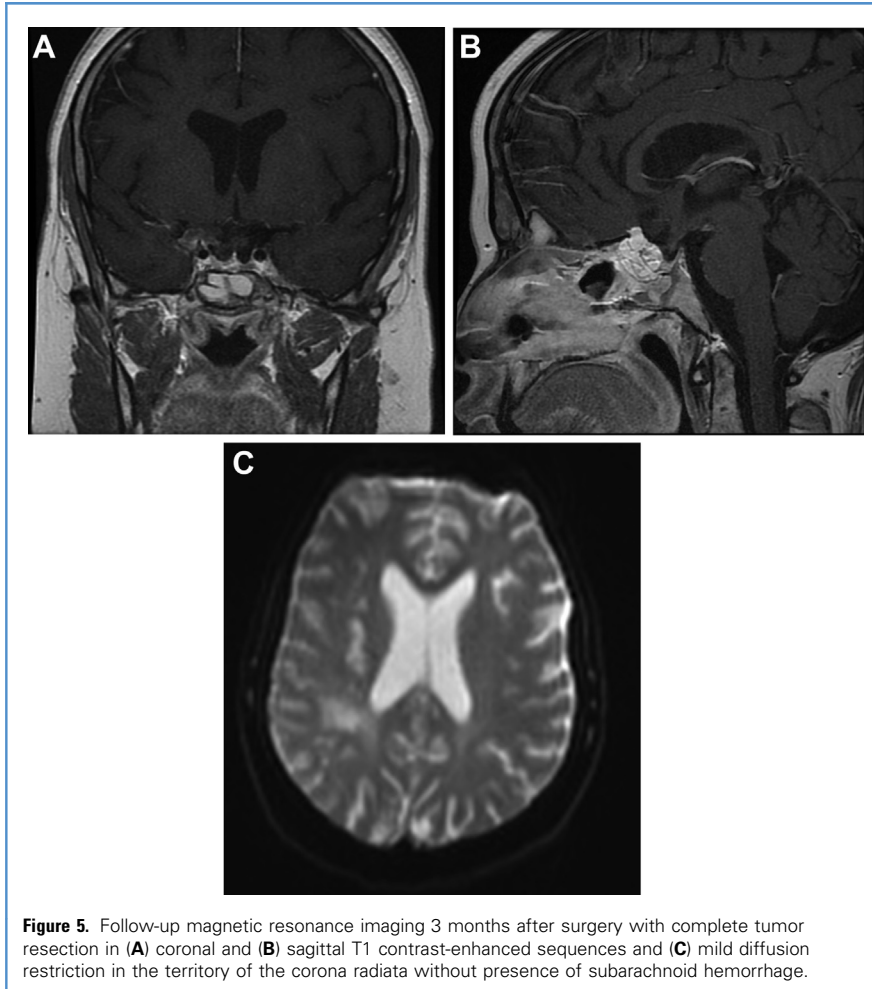


Figure 5. Follow-up magnetic resonance imaging 3 months after surgery with complete tumor resection in (A) coronal and (B) sagittal T1 contrast-enhanced sequences and (C) mild diffusion restriction in the territory of the corona radiata without presence of subarachnoid hemorrhage.

Reducing periods of hypotension before and after surgery, predominantly in elderly arteriosclerotic patients, seems furthermore to be favorable.⁵¹ Oral as opposed to intravenous nimodipine administration has been favored in the treatment of aneurysmal SAH. However, its actual value in preventing cerebral vasospasm remains uncertain.⁵⁷ As a matter of fact, despite nimodipine being started on postoperative day 1, our patient still developed vasospasm on the eighth day. The reasons for such complications remain unclear.

Even though evidence on hypervolemia does not support its benefit in the prophylaxis of vasospasm in nontraumatic SAH because of its vast complications (e.g., pulmonary edema^{58,59}), even modern case reports describe hypervolemia as a possible management option.^{9,17,18} More invasive therapies include balloon

angioplasty^{7,10,60} and intra-arterial nimodipine/papaverine applications. Doses reported for papaverine during intra-arterial injection ranged from 160 to 300 mg,^{15,19} whereas nimodipine was dosed at 2–10 mg.²⁰ Further controlled trials are needed to prove its efficacy.²⁰ In this context, von der Brölie et al.⁶¹ reported that single injections provide less complications compared with the continuous intra-arterial application of nimodipine. Additionally, balloon angioplasty should be carefully considered because injured or irradiated vessels are vulnerable and can potentially rupture.⁴¹

Symptomatic cerebral vasospasm may be preventable. Transcranial Doppler (TCD) is a well-acknowledged method for the diagnosis and monitoring for vasospasm.⁶² The discussed cases in this article identified common risk factors; therefore, elective daily TCD should be

carried out in patients with large sellar tumors with suprasellar extension and encasement or displacement of arteries, aggressive manipulation of suprasellar vessels during surgery, postoperative SAH, intra- and postoperative CSF leak, and/or postoperative meningitis. Induced hypertension could prevent manifest vasospasm, when detected early. It merits mention that several cases presented vasospasm in the supraclinoid ICA,^{3,7,17} which is not typically sound out during traditional TCD; hence, a transorbital evaluation of distal ICA flow should be considered.⁶³ Furthermore, the threshold for initiating DSA after transsphenoidal surgery and unexplained neurologic deterioration should be low.

It has to be stressed that while Eseonu et al.³ reported on transsphenoidal surgery of both microsurgical and endoscopic approaches, our case focused primarily on EEEA and the discussion of the occurrence of vasospasm after the surgical procedure.

In the presented case, even though prophylaxis with nimodipine was given, the patient developed symptomatic vasospasm. A TCD performed on a daily basis could have perhaps provided further information to adjust the postoperative management (e.g., blood pressure management) in our patient.

Limitations

The small number of patients discussed in this article is a limitation. Publication bias is a further problem because severe cases are more frequently published than minor ones. Furthermore, not all information available in the reviewed articles was as detailed as needed. Similarly, approaches were not always precisely described; therefore, we might have missed relevant articles.

CONCLUSIONS

Mechanisms of vasospasm after transsphenoidal surgery are still poorly understood. Cerebral vasospasm can potentially lead to a high morbidity and mortality in patients. The threshold for DSA after unexplained neurologic deterioration after transsphenoidal surgery should be low, and cerebral vasospasm should be addressed early and aggressively. Surgeons performing EEEA need to consider

the possibility of this delayed complication.

REFERENCES

- Alzhrani G, Sivakumar W, Park MS, Taussky P, Couldwell WT. Delayed complications after transsphenoidal surgery for pituitary adenomas. *World Neurosurg.* 2018;109:233-241.
- Alotaibi NM, Lanzino G. Cerebral vasospasm following tumor resection. *J Neurointerv Surg.* 2013; 5:413-418.
- Eseonu CI, ReFaey K, Geocadin RG, Quinones-Hinojosa A. Postoperative cerebral vasospasm following transsphenoidal pituitary adenoma surgery. *World Neurosurg.* 2016;92:7-14.
- Moher D, Liberati A, Tetzlaff J, Altman DG, PRISMA Group. Preferred reporting items for systematic reviews and meta-analyses: the PRISMA statement. *BMJ.* 2009;339:b2535.
- Al-Zubaidi AS, Afandi B. Severe digital vasospasm caused by cabergoline. *Saudi Med J.* 2005;26: 1153-1155.
- Bierer J, Wolf A, Lee DH, Rotenberg BW, Duggal N. Bilateral caudate nucleus infarcts: a case report of a rare complication following endoscopic resection of a tuberculum sellae meningioma. *Surg Neurol Int.* 2017;8:235.
- Bougaci N, Paquis P. Cerebral vasospasm after transsphenoidal surgery for pituitary adenoma: case report and review of the literature. *Neurochirurgie.* 2017;63:25-27.
- Camp PE, Paxton HD, Buchan GC, Gahbauer H. Vasospasm after trans-sphenoidal hypophysectomy. *Neurosurgery.* 1980;7:382-386.
- Chong MY, Quak SM, Chong CT. Cerebral ischaemia in pituitary disorders—more common than previously thought: two case reports and literature review. *Pituitary.* 2014;17:171-179.
- Friedman JA, Meyer FB, Wetjen NM, Nichols DA. Balloon angioplasty to treat vasospasm after transsphenoidal surgery. Case illustration. *J Neurosurg.* 2001;95:353.
- Hyde-Rowan MD, Roessmann U, Brodkey JS. Vasospasm following transsphenoidal tumor removal associated with the arterial changes of oral contraception. *Surg Neurol.* 1983;20:120-124.
- Kamal R, Jindal A, Suri A, Mahapatra AK. Effect of craniopharyngioma fluid on femoral vessels of rat. *Neurol Res.* 1999;21:796-798.
- Karimnejad K, Sweeney JM, Antisdell JL. Cerebral vasospasm following transsphenoidal hypophysectomy in the treatment of lymphocytic hypophysitis. *J Craniofac Surg.* 2016;27:988-991.
- Kasliwal MK, Srivastava R, Sinha S, Kale SS, Sharma BS. Vasospasm after transsphenoidal pituitary surgery: a case report and review of the literature. *Neurol India.* 2008;56:81-83.
- Kim EH, Oh MC, Kim SH. Angiographically documented cerebral vasospasm following transsphenoidal surgery for pituitary tumors. *Pituitary.* 2013;16:260-269.
- Koutourousiou M, Fernandez-Miranda JC, Stefko ST, Wang EW, Snyderman CH, Gardner PA. Endoscopic endonasal surgery for suprasellar meningiomas: experience with 75 patients. *J Neurosurg.* 2014;120:1326-1339.
- Mansouri A, Fallah A, Cusimano MD, Das S. Vasospasm post pituitary surgery: systematic review and 3 case presentations. *Can J Neurol Sci.* 2012;39:767-773.
- Nash R, Elwell V, Brew S, Powell M, Grieve JP. Management strategy for treatment of vasospasm following transsphenoidal excision of craniopharyngioma. *Acta Neurochir (Wien).* 2016;158: 2105-2108.
- Nishioka H, Ito H, Haraoka J. Cerebral vasospasm following transsphenoidal removal of a pituitary adenoma. *Br J Neurosurg.* 2001;15:44-47.
- Osterhage K, Czorlich P, Burkhardt TR, Rotermund R, Grzyska U, Flitsch J. Symptomatic vasospasms as a life-threatening complication after transsphenoidal surgery. *World Neurosurg.* 2018;110:180-188.
- Popugaev KA, Savin IA, Lubnin AU, et al. Unusual cause of cerebral vasospasm after pituitary surgery. *Neurol Sci.* 2011;32:673-680.
- Puri AS, Zada G, Zarzour H, Laws E, Frerichs K. Cerebral vasospasm after transsphenoidal resection of pituitary macroadenomas: report of 3 cases and review of the literature. *Neurosurgery.* 2012;71(1 suppl operative):173-180 [discussion: 180-181].
- Ricarte IF, Funchal BF, Miranda Alves MA, et al. Symptomatic cerebral vasospasm and delayed cerebral ischemia following transsphenoidal resection of a craniopharyngioma. *J Stroke Cerebrovasc Dis.* 2015;24:e271-e273.
- Svendgaard NA, Delgado TJ, Brun A. Effect of selective lesions in the hypothalamic-pituitary region on the development of cerebral vasospasm following an experimental subarachnoid hemorrhage in the rat. *J Cereb Blood Flow Metab.* 1986;6: 650-657.
- Zada G, Du R, Laws ER Jr. Defining the "edge of the envelope": patient selection in treating complex sellar-based neoplasms via transsphenoidal versus open craniotomy. *J Neurosurg.* 2011;114: 286-300.
- Aoki N, Origitano TC, al-Mefty O. Vasospasm after resection of skull base tumors. *Acta Neurochir (Wien).* 1995;132:53-58.
- Barrow DL, Tindall GT. Loss of vision after transsphenoidal surgery. *Neurosurgery.* 1990;27: 60-68.
- Cervoni L, Salvati M, Santoro A. Vasospasm following tumor removal: report of 5 cases. *Ital J Neurol Sci.* 1996;17:291-294.
- Lopes MBS. The 2017 World Health Organization classification of tumors of the pituitary gland: a summary. *Acta Neuropathol.* 2017;134:521-535.
- Frontera JA, Fernandez A, Schmidt JM, et al. Defining vasospasm after subarachnoid hemorrhage: what is the most clinically relevant definition? *Stroke.* 2009;40:1963-1968.
- Krayenbuehl H. [A contribution to the problem of cerebral angiospastic insult]. *Schweiz Med Wochenschr.* 1960;90:961-965 [in German].
- Fisher CM, Kistler JP, Davis JM. Relation of cerebral vasospasm to subarachnoid hemorrhage visualized by computerized tomographic scanning. *Neurosurgery.* 1980;6:1-9.
- Zabramski JM, Spetzler RF, Bonstelle C. Chronic cerebral vasospasm: effect of volume and timing of hemorrhage in a canine model. *Neurosurgery.* 1986;18:1-6.
- Boullin DJ, Tagari P, du Boulay G, Aitken V, Hughes JT. The role of hemoglobin in the etiology of cerebral vasospasm. An in vivo study of baboons. *J Neurosurg.* 1983;59:231-236.
- Duff TA, Feilbach JA, Yusuf Q, Scott G. Bilirubin and the induction of intracranial arterial spasm. *J Neurosurg.* 1988;69:593-598.
- Asano T. Oxyhemoglobin as the principal cause of cerebral vasospasm: a holistic view of its actions. *Crit Rev Neurosurg.* 1999;9:303-318.
- Provencio JJ, Vora N. Subarachnoid hemorrhage and inflammation: bench to bedside and back. *Semin Neurol.* 2005;25:435-444.
- Frontera JA, Claassen J, Schmidt JM, et al. Prediction of symptomatic vasospasm after subarachnoid hemorrhage: the modified Fisher scale. *Neurosurgery.* 2006;59:21-27 [discussion: 21-27].
- Bejjani GK, Sekhar LN, Yost AM, Bank WO, Wright DC. Vasospasm after cranial base tumor resection: pathogenesis, diagnosis, and therapy. *Surg Neurol.* 1999;52:577-583 [discussion: 583-584].
- Shida N, Nakasato N, Mizoi K, Kanaki M, Yoshimoto T. Symptomatic vessel narrowing caused by spontaneous rupture of craniopharyngioma cyst—case report. *Neurol Med Chir (Tokyo).* 1998;38:666-668.
- Ecker RD, Atkinson JL, Nichols DA. Delayed ischemic deficit after resection of a large intracranial dermoid: case report and review of the literature. *Neurosurgery.* 2003;52:706-710 [discussion: 709-710].
- Mawk JR, Ausman JJ, Erickson DL, Maxwell RE. Vasospasm following transcranial removal of large pituitary adenomas. Report of three cases. *J Neurosurg.* 1979;50:229-232.
- Pozzati E, Frank G, Nasi MT, Giuliani G. Pituitary apoplexy, bilateral carotid vasospasm, and cerebral infarction in a 15-year-old boy. *Neurosurgery.* 1987;20:56-59.
- Chang SD, Yap OW, Adler JR Jr. Symptomatic vasospasm after resection of a suprasellar pilocytic astrocytoma: case report and possible pathogenesis. *Surg Neurol.* 1999;51:521-526 [discussion: 526-527].
- Cardoso ER, Peterson EW. Pituitary apoplexy and vasospasm. *Surg Neurol.* 1983;20:391-395.

46. Hirschl RA, Wilson J, Miller B, Bergese S, Chiocca E. The predictive value of low-field strength magnetic resonance imaging for intraoperative residual tumor detection. *Clinical article. J Neurosurg.* 2009;111:252-257.
47. Wilkins RH. Hypothalamic dysfunction and intracranial arterial spasms. *Surg Neurol.* 1975;4:472-480.
48. Rosenbaum TJ, Houser OW, Laws ER. Pituitary apoplexy producing internal carotid artery occlusion. Case report. *J Neurosurg.* 1977;47:599-604.
49. Rovit RL, Fein JM. Pituitary apoplexy: a review and reappraisal. *J Neurosurg.* 1972;37:280-288.
50. D'Haens J, Baleriaux D, Mockel J, Flament-Durand J, Brotchi J. [Ischemic pituitary apoplexy and cerebrovascular accident]. *Neurochirurgie.* 1983;29:401-405 [in French].
51. Ahmed SK, Semple PL. Cerebral ischaemia in pituitary apoplexy. *Acta Neurochir (Wien).* 2008;150:1193-1196 [discussion: 1196].
52. Akutsu H, Noguchi S, Tsunoda T, Sasaki M, Matsumura A. Cerebral infarction following pituitary apoplexy—case report. *Neurol Med Chir (Tokyo).* 2004;44:479-483.
53. Banerjee C, Snelling B, Hanft S, Komotar RJ. Bilateral cerebral infarction in the setting of pituitary apoplexy: a case presentation and literature review. *Pituitary.* 2015;18:352-358.
54. Douleh DG, Morone PJ, Mobley B, Fusco MR, Chambless LB. Angioplasty is an effective treatment for vasospasm following pituitary apoplexy and tumor resection. *Cureus.* 2018;10:e2117.
55. Smith D, Finucane F, Phillips J, et al. Abnormal regulation of thirst and vasopressin secretion following surgery for craniopharyngioma. *Clin Endocrinol (Oxf).* 2004;61:273-279.
56. McGirt MJ, Blessing R, Nimjee SM, et al. Correlation of serum brain natriuretic peptide with hyponatremia and delayed ischemic neurological deficits after subarachnoid hemorrhage. *Neurosurgery.* 2004;54:1369-1373 [discussion: 1373-1374].
57. Connolly ES Jr, Rabinstein AA, Carhuapoma JR, et al. Guidelines for the management of aneurysmal subarachnoid hemorrhage: a guideline for healthcare professionals from the American Heart Association/American Stroke Association. *Stroke.* 2012;43:1711-1737.
58. Kiser TH. Cerebral vasospasm in critically ill patients with aneurysmal subarachnoid hemorrhage: does the evidence support the ever-growing list of potential pharmacotherapy interventions? *Hosp Pharm.* 2014;49:923-941.
59. van der Jagt M. Fluid management of the neurological patient: a concise review. *Crit Care.* 2016;20:126.
60. Eskridge JM, McAuliffe W, Song JK, et al. Balloon angioplasty for the treatment of vasospasm: results of first 50 cases. *Neurosurgery.* 1998;42:510-516 [discussion: 516-517].
61. von der Brölie C, Doukas A, Stopfer A, et al. Clinical course and monitoring parameters after continuous interventional intra-arterial treatment in patients with refractory cerebral vasospasm. *World Neurosurg.* 2017;100:504-513.
62. Aaslid R, Huber P, Nornes H. Evaluation of cerebrovascular spasm with transcranial Doppler ultrasound. *J Neurosurg.* 1984;60:37-41.
63. Conti A, Iacopino DG, Spada A, et al. Transcranial Doppler ultrasonography in the assessment of cerebral circulation arrest: improving sensitivity by transcervical and transorbital carotid insonation and serial examinations. *Neurocrit Care.* 2009;10:326-335.

Conflict of interest statement: The authors declare that the article content was composed in the absence of any commercial or financial relationships that could be construed as a potential conflict of interest.

Received 22 December 2018; accepted 4 April 2019

Citation: World Neurosurg. (2019) 128:29-36.

<https://doi.org/10.1016/j.wneu.2019.04.046>

Journal homepage: www.journals.elsevier.com/world-neurosurgery

Available online: www.sciencedirect.com

1878-8750/\$ - see front matter © 2019 Elsevier Inc. All rights reserved.