



A child with a stroke, drug-refractory epilepsy and congenital heart disease: can a hemispherectomy be safely performed between staged cardiac procedures?

Puneet Jain^{1,2} · Christoph Haller³ · Elizabeth Pulcine⁴ · Ayako Ochi¹ · Anne Dipchand⁵ · Shelly K. Weiss¹ · Vanessa Chin⁶ · George M. Ibrahim⁷

Received: 25 March 2019 / Accepted: 21 April 2019 / Published online: 2 May 2019
© Springer-Verlag GmbH Germany, part of Springer Nature 2019

Abstract

Background The safety of hemispherectomy between staged cardiac procedures is unknown and not previously reported.

Method Retrospective review of a case with drug-resistant epilepsy due to stroke following bidirectional cavopulmonary connection (BDCPC).

Results This report describes the first case of a successful pediatric peri-insular functional hemispherectomy in the setting of a BDCPC. A discussion of the complex preoperative planning from both a cardiac and neurological perspective is presented. Considerations regarding hemispherectomy and its effects on the cardiac physiology, and perioperative considerations are emphasized in clinical decision making.

Conclusions A multidisciplinary approach was critical in this child which led to a successful outcome.

Keywords Epilepsy surgery · Cardiac surgery · Congenital heart disease · Single ventricle · Disconnection · Cardioembolic stroke

Introduction

In children with complex comorbid cardiac and neurological disorders, treatment decisions may be challenging and evidence-based algorithms are lacking. Here, we report a case

of a child with complex congenital heart disease who developed drug-refractory epilepsy (DRE) secondary to a left middle cerebral artery (MCA) infarction following a bidirectional cavopulmonary connection (BDCPC) at 11 months of age. There are no reports of successful hemispherectomy in a

✉ George M. Ibrahim
george.ibrahim@sickkids.ca

Puneet Jain
puneet.jain@sickkids.ca

Christoph Haller
christoph.haller@sickkids.ca

Elizabeth Pulcine
Elizabeth.pulcine@sickkids.ca

Ayako Ochi
ayako.ochi@sickkids.ca

Anne Dipchand
anne.dipchand@sickkids.ca

Shelly K. Weiss
shelly.weiss@sickkids.ca

Vannessa Chin
vannessa.chin@sickkids.ca

¹ Epilepsy Program, Division of Neurology, Department of Pediatrics, The Hospital for Sick Children, Toronto M5G 1X8, Canada

² Division of Pediatric Neurology, Department of Pediatrics, BLK Kapur (BLK) Super Speciality Hospital, Pusa Road, New Delhi 110005, India

³ Division of Cardiac Surgery, The Hospital for Sick Children, Toronto M5G 1X8, Canada

⁴ Stroke Program, Division of Neurology, Department of Pediatrics, The Hospital for Sick Children, Toronto M5G 1X8, Canada

⁵ Labatt Family Heart Center, The Hospital for Sick Children, Toronto M5G 1X8, Canada

⁶ Department of Anesthesia, The Hospital for Sick Children, Toronto M5G 1X8, Canada

⁷ Division of Neurosurgery, The Hospital for Sick Children, Toronto, Ontario M5G 1X8, Canada

patient with this circulation. In BDCPC physiology, pulmonary blood flow is solely dependent on systemic venous return from the upper half of the body. The effects of a hemispherectomy on this systemic venous return are unknown. Challenges in the decision-making for early hemispherectomy in a child with a univentricular heart in the midst of a staged cardiac palliation are discussed.

Case

Diagnosis of congenital heart disease

After an unremarkable perinatal and neonatal period, the male infant was noted to have a cardiac murmur at 6 weeks of age during a routine well-baby check-up. Subsequent echocardiogram showed a double-outlet right ventricle, a rightward aorta, a large ventricular septal defect (VSD) anterior to the pulmonary artery (PA), a straddling mitral valve, severe mitral regurgitation, a hypoplastic transverse arch and isthmus, large patent ductus arteriosus, and an atrial septal defect. The infant was palliated with aortic arch reconstruction and PA banding at 2 months of age. Straddling of the mitral valve and a remote VSD precluded biventricular repair. At the age of 7 months, he underwent an elective Damus-Kaye-Stansel procedure, PA patch reconstruction, and placement of a modified Blalock-Taussig shunt with concomitant mitral valve repair. At this time, he was noted to have gross motor delay, attributable to his lack of mobility secondary to a combination of his complex heart disease, multiple hospitalizations, and surgical interventions.

Cavopulmonary connection complicated by postoperative MCA infarction

A bidirectional cavopulmonary connection (BDCPC) (Fig. 1) was performed at 11 months of age. This procedure involves anastomosis of the aorta and pulmonary artery to form a common outflow. Intracardiac mixing occurs at the atrial (and in some patients at the ventricular level). At stage II, the source of pulmonary blood flow is changed by connecting the superior caval vein to the pulmonary artery. As a result, pulmonary blood flow is exclusively dependent upon upper body venous return.

On the fourth postoperative day, the patient developed progressive encephalopathy and right hemiplegia. Magnetic resonance imaging (MRI) of the brain demonstrated a left proximal MCA infarct with thrombosis of the proximal M1 segment. A heparin infusion and neuroprotective measures were started. Continuous electroencephalography (EEG) showed multiple subclinical seizures arising from the left hemisphere (Fig. 2) requiring treatment with multiple anti-epileptic drugs.

No additional risk factors were identified on an extended stroke workup. The child was treated with enoxaparin and levetiracetam and transferred to a pediatric rehabilitation

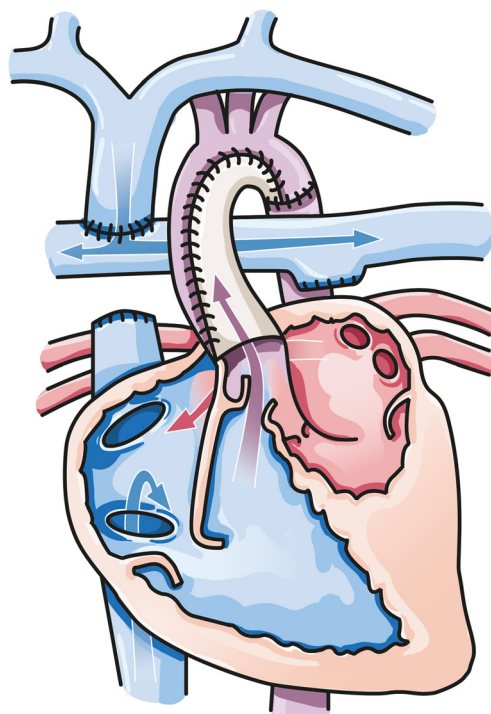


Fig. 1 Schematic depiction of BCPS physiology (stage II palliation). Aorta and pulmonary artery are anastomosed and reconstructed to form a common outflow. Intracardiac mixing occurs at the atrial (and in some patients at the ventricular level). At stage II, the source of pulmonary blood flow is changed by connecting the superior caval vein to the pulmonary artery. Upper body venous return is now the sole factor determining pulmonary blood flow. (Note that intracardiac anatomy does not exactly reflect the patient's anatomy)

hospital. He was subsequently transitioned to aspirin for stroke prophylaxis after prolonged therapy with enoxaparin.

Medically intractable epilepsy lateralized to infarcted hemisphere

Five months after the BDCPC procedure at the age of 16 months, the child developed multiple daily brief seizures (asymmetric tonic and drop attacks). His ictal and interictal EEG findings were left hemispheric (Fig. 3). Repeat MRI of the brain demonstrated a remote left MCA infarct with cystic encephalomalacia. The seizures shortly became drug-resistant. The patient was then deemed suitable for left functional hemispherectomy (FH) after a multi-disciplinary case discussion involving pediatric cardiologists, neurologists, hematologists, and neuro and cardiac surgeons.

Functional hemispherectomy

Aspirin was stopped 7 days prior to FH and enoxaparin was re-initiated as a bridge anticoagulation therapy. The antithrombotic therapy was transitioned to a heparin infusion 12 h prior to surgery. The patient underwent successful left FH at 28 months of age (17 months following the BDCPC).

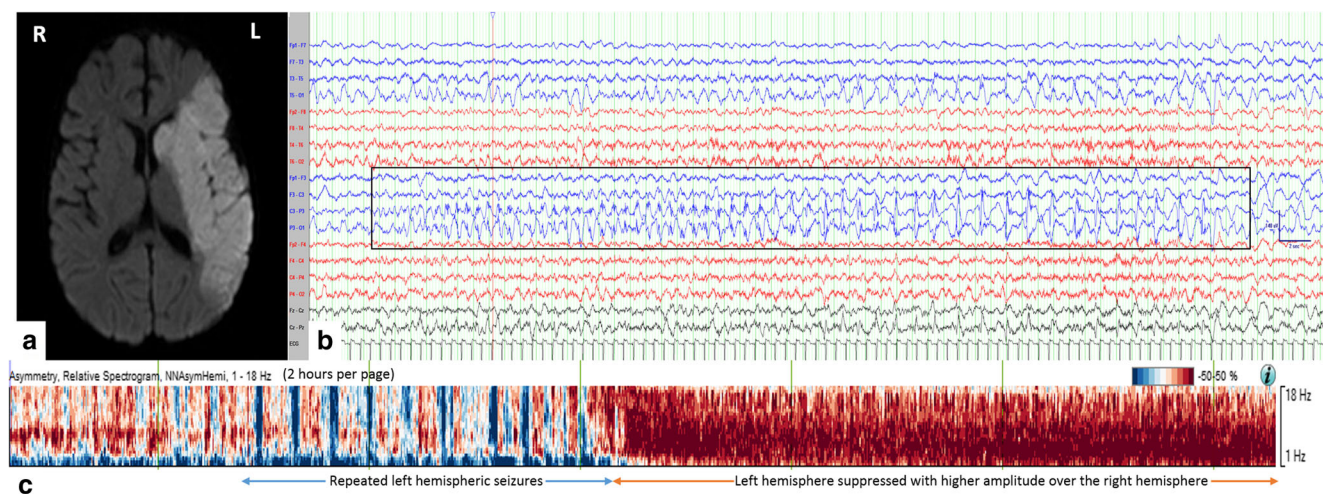


Fig. 2 Acute ischemic stroke at 11 months of age. A diffusion weighted axial MRI brain image (A) shows restricted diffusion in the left middle cerebral artery territory. Continuous EEG captured multiple subclinical seizures from the left hemisphere. Image (B) displays one electrographic seizure from P3 (low frequency filter 1 Hz, high frequency filter 70 Hz, notch filter 60 Hz, sensitivity 7 μ V/mm, timebase 15 mm/s). Asymmetry-relative spectrogram (Persyst software, AZ, USA) is shown in (C). “x” axis is the time (2 h per page), “y” axis is the frequency of the EEG

activity (1–18 Hz), and the “color” code denotes the hemisphere: blue represents left hemispheric activity and red color represents right hemispheric activity. It shows multiple electrographic seizures from the left hemisphere (apparent as multiple blue-colored pillars) followed by left hemispheric EEG suppression (apparent as diffuse red color denoting that the right hemisphere had higher amplitude activities across all frequencies)

Postoperative cardiac physiology was stable. The saturations ranged between 75 and 85%. Early postoperative echocardiography showed mild moderately reduced right-ventricle

systolic function, which was unchanged from previous. The right-sided BDCPC was unobstructed with laminar phasic flow.

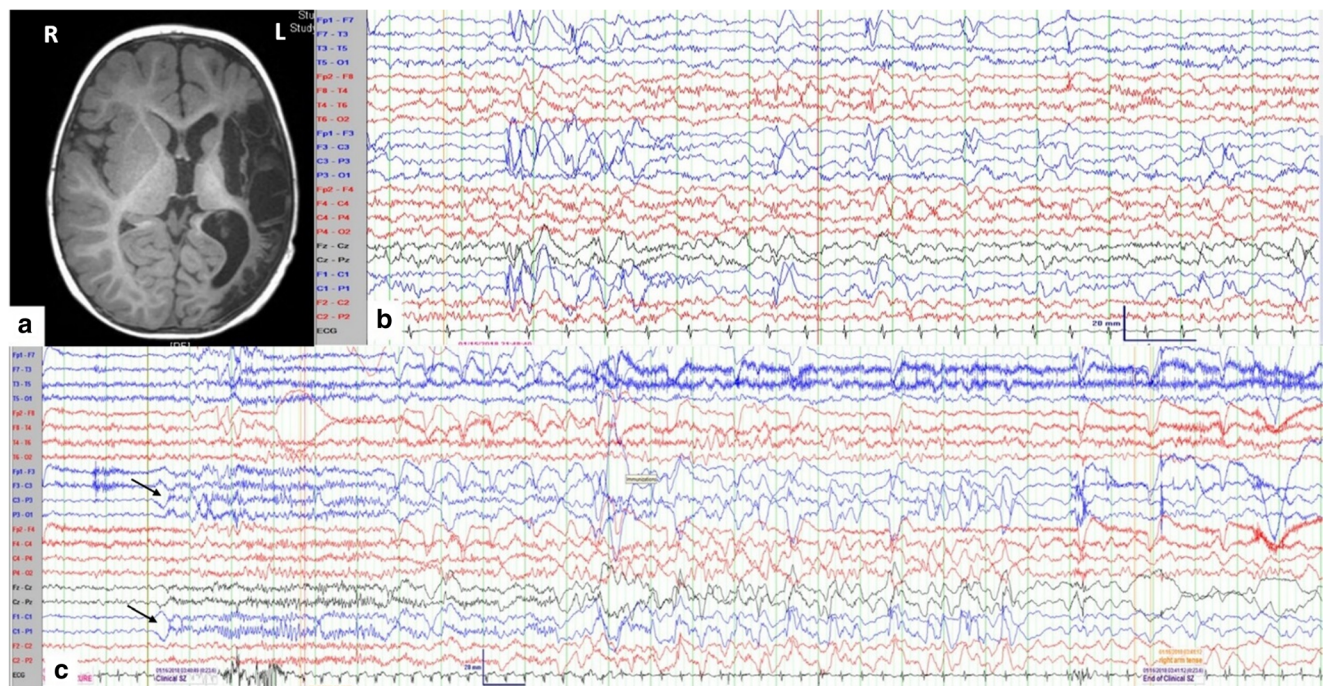


Fig. 3 Follow-up imaging and EEG. T1-weighted axial MRI brain image (A) shows encephalomalacia in the area of previous ischemic stroke. At 10 months after BCPS procedure (21 months of age), inter-ictal EEG (B) shows frequent spike-/sharp-and-slow waves with polymorphic delta activity over the left hemisphere, and asymmetric background beta activity, left hemisphere shows lower amplitude beta waves compared to the right hemisphere. Ictal EEG (C) reveals sudden onset delta waves prominent at C1/C3 (arrows) with subsequent evolution to diffuse 13–15 Hz spiky beta activity

(predominantly over left hemisphere); followed by semirhythmic delta mixed with spikes/sharp-waves at C3/P3/C1P1/CzPz till seizure termination (duration 24 s). Clinically, the patient was awake. With onset of ictal EEG change, the right upper limb became tonically extended with forward flexion of trunk resulting in a “drop.” He remained in flexed position for few seconds. (LFF 1 Hz, HFF 70 Hz, sensitivity 15 μ V/mm, timebase 30 mm/s, sampling rate 1024 Hz)

Postoperative heparin infusion was started 10 days after FH and was then transitioned to enoxaparin after 5 days due to limited intravenous access. The patient was discharged home on oral aspirin and his regular anti-epileptic drugs after 30 days of hospital admission with no thromboembolic or bleeding complications.

At the last follow-up (10 months after FH), the patient was seizure free with significant neurodevelopmental gains.

Discussion

This report describes a child with a functionally univentricular heart who developed drug-refractory epilepsy after an ischemic stroke following a cardiac procedure. He had improvements in neurodevelopmental skills and remained seizure free following functional hemispherectomy post-BDCPC.

Early hemispherectomy and neurodevelopment

Hemispherectomy is commonly performed in children with hemispheric epilepsy secondary to arterial ischemic stroke. Scavarda et al. [1] reported eight children with stroke-induced refractory epilepsy who underwent peri-insular hemispherectomy. Seven out of eight children were found to be seizure free after a median follow-up of 5 years. The impetus to expedite hemispherectomy is supported by data favoring early surgical treatment of catastrophic lateralized epilepsy in order to rescue or prevent neurodevelopmental consequences [2]. In the current report, this created a conflict between neurological and cardiac priorities, as the child was in the midst of a staged cardiac repair with a potentially vulnerable circulation.

Cardiac considerations for hemispherectomy post-BDCPC

In BDCPC physiology, pulmonary blood flow is solely dependent on systemic venous return from the upper half of the body. The effects of a hemispherectomy on this systemic venous return are unclear and mandate intensive diagnostic workup and interdisciplinary discussions. One potential option in the present case was to transition to an early Fontan circulation to add inferior vena cava (IVC) flow to pulmonary blood flow and reduce the potentially detrimental effects of the reduction of superior caval vein (SVC) flow. Pulmonary blood flow would then not be dependent on SVC flow alone and the effects of a hemispherectomy on cardiac physiology may be better tolerated. However, Fontan circulation at an earlier age or without optimal hemodynamics is not without its own potential risks from a cardiac perspective. There is also controversy in the event that an early conversion leads to earlier ventricular functional deterioration due to insufficient preloading. In the current report, the patient did not require an early Fontan procedure otherwise.

Alternatively, assuming an already reduced cerebral blood flow due to the full-territory MCA stroke, the effects of hemispherectomy on pulmonary blood flow may be tolerated without significant desaturation. In accordance with the latter hypothesis, preoperative MRI showed low SVC flow (1.6 L/min/m²) compared to reported indexed SVC flow [3]. The MRI flow measurements also revealed that approximately 45–55% of pulmonary venous blood flow originated from equally distributed aortopulmonary collaterals. This suggested that pulmonary blood flow may not be as sensitive to changes in SVC flow post hemispherectomy. Therefore, the decision was made to proceed with hemispherectomy.

A peri-insular hemispherectomy (hemispherotomy) may also be better tolerated by BDCPC circulation. As opposed to anatomical hemispherectomy, the peri-insular procedure maximally disconnects white matter tracts with only modest resection, namely the temporal lobe and opercular cortex. In a patient with vulnerable circulation, dependent on SVC return, an anatomical hemispherectomy may alter venous return and compromise the delicate cardiac physiology.

Antithrombotic considerations for hemispherectomy post-BDCPC

This case also highlights the decision-making around the choice and duration of appropriate antithrombotic therapy. The current patient received antithrombotic treatment for stroke prophylaxis, a common practice for children with complex congenital heart disease and prior stroke. However, there are no evidence-based data to guide treatment selection and duration, in part due to safety concerns and difficulty in running clinical trials in children with rare and heterogeneous cardiac conditions. This is reflected in guidelines, as differences in antithrombotic treatment recommendations exists between the American College of Chest Physicians [4] and the American Heart Association scientific statement on the management of stroke in infants and children [5]. In this unique case, there were no consensus-based guidelines or adult data to inform how best to optimize anticoagulation pre-and post-FH in a functionally univentricular heart in the setting of a BDCPC circulation. Thus, the decision and management relied on expert opinions, clinical experience and interdisciplinary consensus.

Conclusions

This report describes the first case of successful pediatric peri-insular functional hemispherectomy in the setting of a BDCPC. The report highlights the importance of collaboration and communication among pediatric cardiologists, neurologists, hematologists, cardiac anesthesiologists, and surgeons to understand the patient's cardiac physiology,

electrophysiology, thrombosis, and stroke risk when making complex decisions in the absence of high-level evidence. In decision-making about this case, there were no consensus guidelines based on evidence on which to rely. Therefore, it was critical to have a multi-disciplinary approach which led to the successful outcome for this child.

Compliance with ethical standards

Conflict of interest The authors declare that they have no conflict of interest.

Ethics Informed written consent was obtained from the parents of the reported case as per the hospital guidelines.

References

1. Scavarda D, Major P, Lortie A, Mercier C, Carmant L (2009) Periinsular hemispherotomy in children with stroke-induced refractory epilepsy. *J Neurosurg Pediatr* 3:115–120
2. Moosa AN, Jehi L, Marashly A, Cosmo G, Lachhwani D, Wyllie E, Kotagal P, Bingaman W, Gupta A (2013) Long-term functional outcomes and their predictors after hemispherectomy in 115 children. *Epilepsia* 54:1771–1779
3. Kotani Y, Honjo O, Shani K, Merklinger SL, Caldaroni C, Van Arsdell G (2012) Is indexed preoperative superior vena cava blood flow a risk factor in patients undergoing bidirectional cavopulmonary shunt? *Ann Thorac Surg* 94:1578–1583
4. Monagle P, Chan AKC, Goldenberg NA, Ichord RN, Journeycake JM, Nowak-Göttl U, Vesely SK (2012) Antithrombotic therapy in neonates and children: antithrombotic therapy and prevention of thrombosis, 9th ed: American College of Chest Physicians Evidence-Based Clinical Practice Guidelines. *Chest* 141:e737S–e801S
5. Roach ES, Golomb MR, Adams R, Biller J, Daniels S, Deveber G, Ferriero D, Jones BV, Kirkham FJ, Scott RM, Smith ER, American Heart Association Stroke Council; Council on Cardiovascular Disease in the Young (2008) Management of stroke in infants and children: a scientific statement from a Special Writing Group of the American Heart Association Stroke Council and the Council on Cardiovascular Disease in the Young. *Stroke* 39:2644–2691

Publisher's note Springer Nature remains neutral with regard to jurisdictional claims in published maps and institutional affiliations.