



Massive Epistaxis from Nontraumatic Cavernous Carotid Aneurysm Treated by High-Flow Bypass and Cervical Internal Carotid Artery Ligation: A Case Report and Review of the Literature

Kitiporn Sriamornrattanakul and Nasaeng Akharathamachote

Key words

- Carotid aneurysm
- Cavernous carotid aneurysm
- Cavernous segment of carotid artery aneurysm
- Epistaxis
- High-flow bypass

Abbreviations and Acronyms

CCA: Cavernous carotid aneurysm

ICA: Internal carotid artery

MCA: Middle cerebral artery

Division of Neurosurgery, Department of Surgery, Faculty of Medicine Vajira Hospital, Navamindradhiraj University, Bangkok, Thailand

To whom correspondence should be addressed:

Kitiporn Sriamornrattanakul, M.D.

[E-mail: kitiporn6823@gmail.com]

Citation: *World Neurosurg.* (2019) 128:23-28.

<https://doi.org/10.1016/j.wneu.2019.04.213>

Journal homepage: www.journals.elsevier.com/world-neurosurgery

Available online: www.sciencedirect.com

1878-8750/\$ - see front matter © 2019 Elsevier Inc. All rights reserved.

INTRODUCTION

Cavernous carotid aneurysm (CCA) is an uncommon pathologic entity. Such aneurysms constitute 1%–2% of all intracranial aneurysms and can be divided into traumatic and nontraumatic types.¹ Because it is located in the extradural space, clinical manifestation is different from other intradural aneurysms. The natural history is usually benign in small-sized aneurysms because of the small risk of subarachnoid hemorrhage. Symptomatic and giant aneurysms usually manifest signs and symptoms and mass effects in surrounding structures.²

Many reports describe traumatic CCA presenting with epistaxis and carotid-cavernous fistula, which was treated by endovascular technique with preservation of parent artery,³ or surgical trapping if the good cross flow was proved.⁴ Few reports have demonstrated surgical treatment with trapping and high-flow bypass in the case of failed endovascular treatment.⁵

■ **BACKGROUND:** Epistaxis is a rare presentation of the ruptured cavernous carotid aneurysm, especially the nontraumatic type. Both endovascular therapies and open surgeries have a role in the treatment with various outcomes, but the standard procedure is not well established. We report a successful high-flow bypass with cervical internal carotid artery ligation for aneurysm repair and review the related literature.

■ **CASE DESCRIPTION:** An 81-year-old man presented with massive epistaxis from the left nostril. The epistaxis was controlled by nasal packing. A saccular aneurysm of the cavernous segment of the left internal carotid artery projecting into the sphenoid sinus was revealed using computed tomography angiography. We treated this patient with high-flow bypass with ligation of the cervical internal carotid artery. Immediate postoperative computed tomography angiography showed complete disappearance of the aneurysm. Nasal packing was removed without further bleeding. No neurological deficit or complications were detected in the postoperative period.

■ **CONCLUSIONS:** In cases of massive or recurrent epistaxis without coagulopathy or nasal pathology, a cavernous carotid aneurysm should be considered. Immediate cessation of the bleeding is necessary. Flow-preservation bypass with proximal ligation of the parent artery is 1 of the effective procedures for the treatment of this condition with low morbidity.

Nontraumatic CCAs are an extremely rare cause of spontaneous epistaxis, with few documented cases. The management of such cases is challenging because of the relative anatomical inaccessibility of the bleeding point. With novel endovascular instruments, the majority of cases were treated by endovascular procedures.^{1,6,7}

We report a patient with nontraumatic CCA causing epistaxis who was successfully treated with surgical revascularization and proximal ligation of the internal carotid artery (ICA).

CASE REPORT

An 81-year-old man presented with massive epistaxis from the left nostril. Epistaxis was stopped by anterior nasal packing performed by otolaryngologists. On the third day of packing, recurrent epistaxis occurred after the removal of the packing; thus, nasal packing was

performed again. Computed tomography angiography revealed a 12-mm saccular aneurysm arising from the cavernous segment of the left ICA projecting into left sphenoid sinus. (Figures 1 and 2) Neurosurgeons were contacted for emergency consultation. The patient had been treated for prostate cancer for 1 year. No history of diabetes mellitus or hypertension was detected.

In our hospital, the endovascular procedure was not available; therefore, seeing the urgency of the condition, the neurosurgical treatment was selected for this patient and we planned to perform left cervical ICA ligation with high-flow bypass because of the universal revascularization concept. Allen test of left forearm was 4 seconds; therefore, left radial artery was selected for bypass graft.

The patient was placed in the supine position. The patient's head was fixed with a head clamp and his left arm was

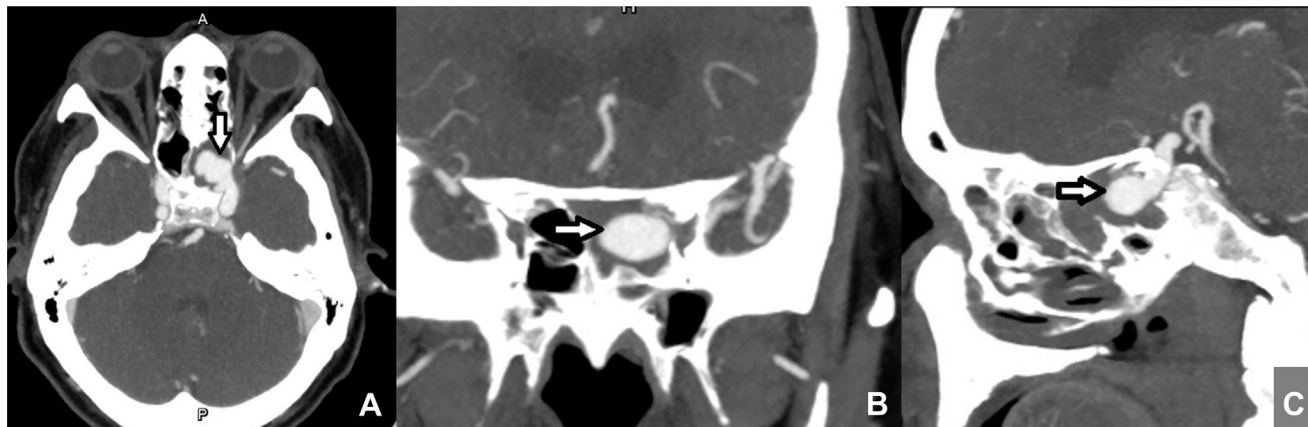


Figure 1. Preoperative images. (A) Axial, (B) coronal, and (C) sagittal view computed tomography angiography shows a saccular aneurysm of the cavernous segment of the left internal carotid artery (arrow) protruding into the sphenoid sinus.

placed on an armrest. The radial artery was harvested and filled with heparinized saline using pressure distention technique. A left cervical incision was made at the level of common carotid bifurcation to

expose the cervical ICA and external carotid artery; then, a left frontotemporal craniotomy was performed. The Sylvian fissure was opened widely to expose the inferior trunk of the M2 segment of the

middle cerebral artery (MCA) as the recipient vessel. The harvested radial artery graft was anastomosed to the M2 segment using the end-to-side interrupted suture technique, then passed through the chest tube via the infratemporal route to the cervical incision. The cervical external carotid artery was anastomosed to the radial artery graft using an end-to-side continuous suture technique. The cervical ICA was clamped with a bulldog clamp, and then a bypass graft was opened. After the confirmation of good blood flow in the bypass graft by Doppler and indocyanine green injection, the cervical ICA was permanently occluded with double ligations for proximal occlusion only, without the necessity for distal occlusion intracranially and anterior clinoidectomy.

The postoperative course was uneventful. The recovery of the patient went well and he had no neurological deficits. Nasal packing was continued, and no further epistaxis was detected after the operation. Immediate postoperative computed tomography angiography revealed good patency of bypass graft, complete thrombosis from cervical ICA to the aneurysm (Figures 3–5), and good retrograde flow from MCA to left ophthalmic artery (Figure 4).

Three days after the operation, the nasal packing was removed from the nostril, and no epistaxis occurred after the removal of the packing. The patient was discharged home 8 days after the operation with the Glasgow outcome score of 5.

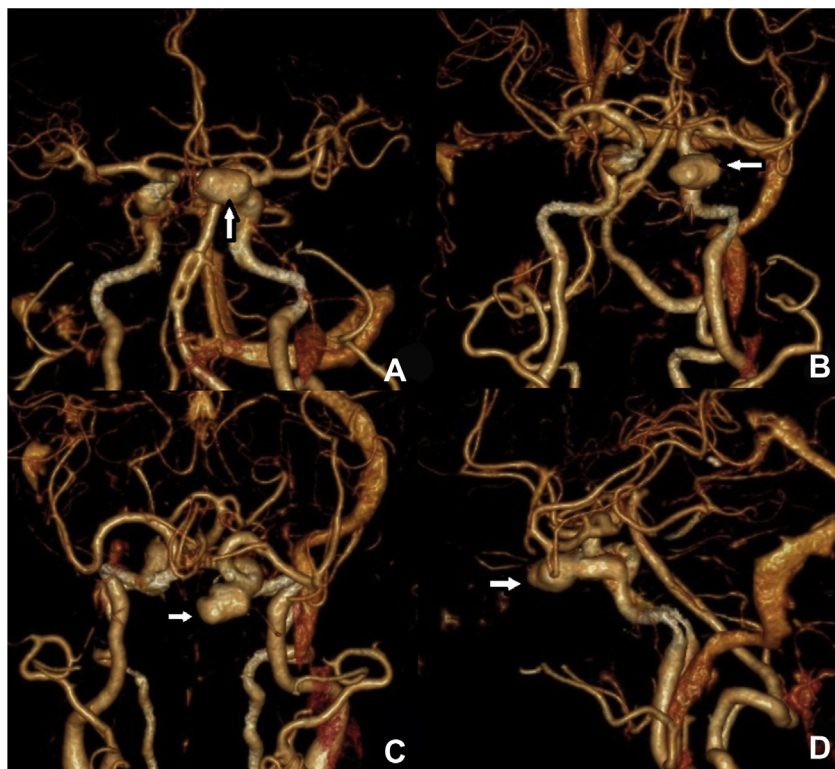


Figure 2. Preoperative 3-dimensional computed tomography angiography shows a saccular aneurysm of cavernous segment of the left internal carotid artery (arrow) projecting anteromedially. (A) Anteroposterior, (B) anterosuperior, (C) superior and (D) left lateral view.

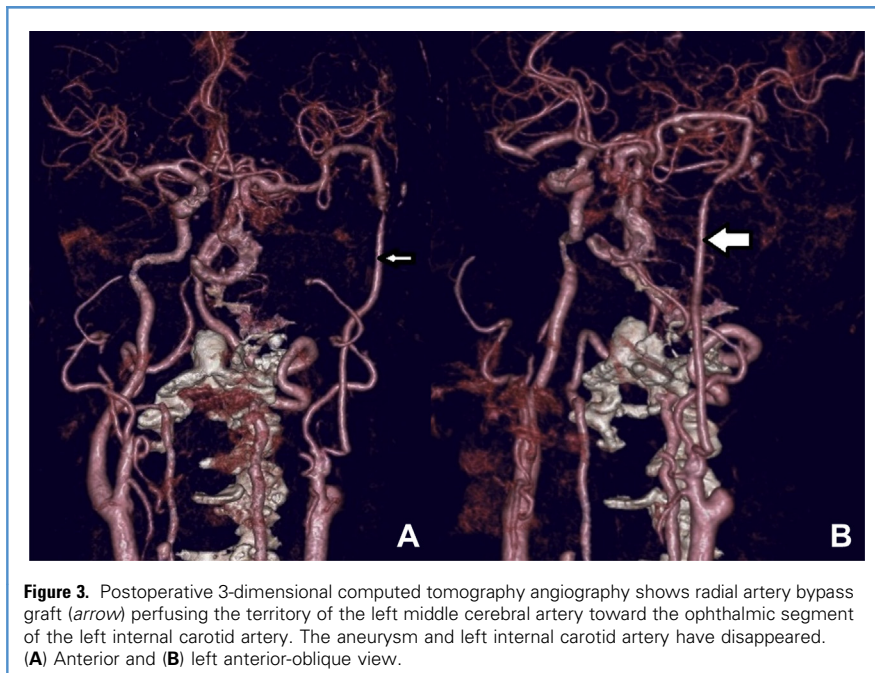


Figure 3. Postoperative 3-dimensional computed tomography angiography shows radial artery bypass graft (arrow) perfusing the territory of the left middle cerebral artery toward the ophthalmic segment of the left internal carotid artery. The aneurysm and left internal carotid artery have disappeared. (A) Anterior and (B) left anterior-oblique view.

DISCUSSION AND LITERATURE REVIEW

Aneurysms arising from the cavernous segment of the ICA rarely cause life-threatening complications. Two exceptions are: spontaneous subarachnoid hemorrhage and massive epistaxis from aneurysm rupture into the sphenoid sinus. Of the 2, epistaxis is rarer than subarachnoid hemorrhage and is most commonly from the rupture of a

pseudoaneurysm associated with head trauma.⁸ Carotid artery aneurysms are a rare cause of epistaxis and have an associated mortality rate of 30%.^{9,10} Epistaxis may be caused by the direct rupture of a CCA into the sphenoid sinus. The majority of the cavernous segment of internal carotid arteries have a thin shell of bone separating them from the sphenoid sinus; in 4% of the

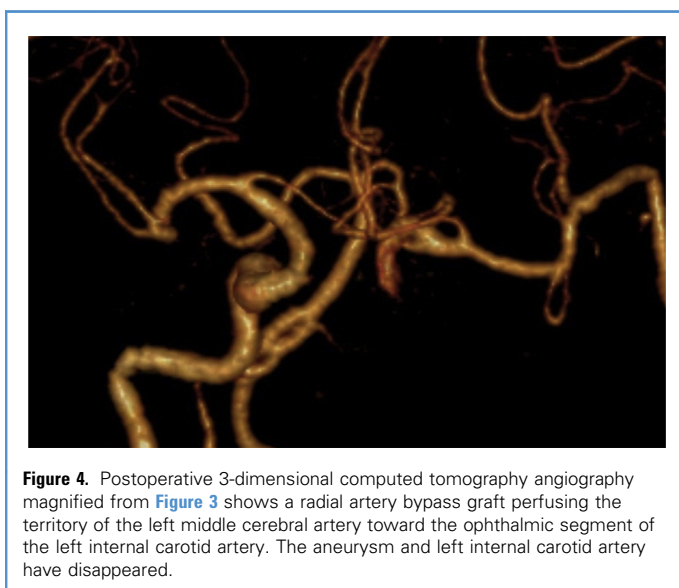


Figure 4. Postoperative 3-dimensional computed tomography angiography magnified from Figure 3 shows a radial artery bypass graft perfusing the territory of the left middle cerebral artery toward the ophthalmic segment of the left internal carotid artery. The aneurysm and left internal carotid artery have disappeared.

specimens, no bone separation is present.^{2,11}

Intracranial aneurysms rarely cause epistaxis, but should be considered in cases of massive blood loss uncontrolled by conventional nasal packing. Most reported cases involve a false (pseudo-) aneurysm of the ICA, causing epistaxis. Most reports result from pseudoaneurysms developing after head injury.⁶

In patients with massive or recurrent epistaxis without coagulopathy or nasal pathology, an internal carotid aneurysm should be included in the differential diagnosis. A history of head injury is usually present, but the absence of trauma does not exclude the possibility of this condition.^{12,13}

Open surgery for clipping of the aneurysm neck or proximal ligation of the ICA was the standard treatment before the advent of endovascular treatment. For the cavernous carotid artery aneurysm, direct exposure is a difficult and high-risk procedure. Endovascular therapy is advantageous over conventional surgical treatment because of the difficult accessibility to the cavernous sinus. Endovascular options for treatment include embolization of the aneurysm dome or complete occlusion of the ICA. If the ICA occlusion is planned, balloon occlusion test of the ICA with or without provocative test is needed to assess the collateral circulation. These endovascular procedures are reasonably safe and the aneurysm obliteration rate is high; however, the long-term outcome should be noted.⁹

Eleven reports of 12 nontraumatic CCAs presenting with epistaxis from 1989 to 2015 were summarized according to patient age, aneurysm characteristics, details of therapeutic procedures and treatment results (Table 1).

From the review of the reports (Table 1), the sacrifice of the parent artery (coil embolization or surgical ligation) has a 100% success rate for complete obliteration of the aneurysm (Table 2). The occluded parent arteries were 1 common carotid artery (with surgical ligation) and 5 ICA (3 cases with endovascular occlusion, 2 cases with surgical ligation). Transient hemiparesis occurred after the sacrifice of the ICA without bypass in 1 of 6 cases. This may be due to the false negative of the preoperative occlusion test. In one case

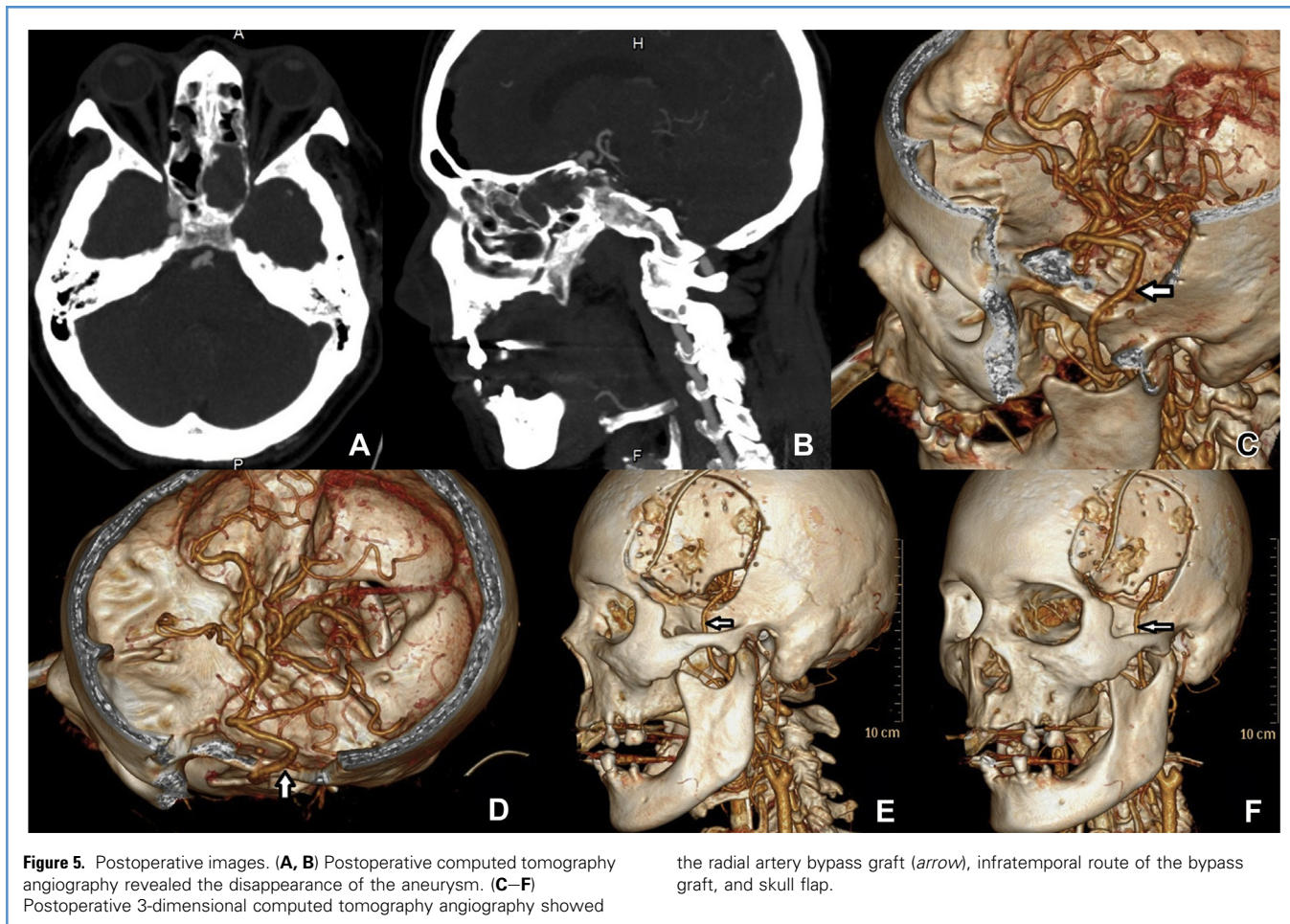


Figure 5. Postoperative images. (A, B) Postoperative computed tomography angiography revealed the disappearance of the aneurysm. (C–F) Postoperative 3-dimensional computed tomography angiography showed

the radial artery bypass graft (arrow), infratemporal route of the bypass graft, and skull flap.

of bypass and ICA ligation, the low-flow (superficial temporal artery–MCA) bypass was used. Embolization of the aneurysms with or without stenting showed a high recurrence rate (33%–60%); however, the number of cases was too small. Direct clipping of the aneurysm shows a high morbidity rate according to the surgical approach.

The authors selected a high-flow bypass with cervical ICA ligation for the treatment of this case. We used universal bypass because of the unavailable preoperative balloon occlusion test and high rate of false-negative results of the test.^{18–20} Proximal occlusion of the aneurysm was performed by ligation of the cervical ICA immediately after the accomplishment of a high-flow bypass without trapping with distal clipping of

intracranial ICA.² Immediately antegrade thrombosis of ICA to the aneurysm was expected after the ligation with retrograde flow from bypass graft to MCA and ophthalmic artery as the flow outlet, which preserved blood flow to the optic nerve. According to our knowledge, this is the first report of using high-flow bypass and cervical ICA ligation for the treatment of CCA presented with massive epistaxis.

The mechanism of CCA thrombosis after cervical ICA ligation was thought to be based on the “blind-alley formation” concept.² The principle of this treatment was similar to the surgical treatment of large or giant cavernous ICA aneurysms without active bleeding² because the active epistaxis was already stopped with nasal packing. With this concept, the

direct approach to the aneurysm, which was located in the cavernous sinus and the anterior clinoidectomy for placement of the clip on the ICA proximal to the origin of the ophthalmic artery, were not necessary and therefore the risk of cranial nerve injury was not exposed.^{21,22}

CONCLUSION

In cases of massive or recurrent epistaxis without coagulopathy or nasal pathology, a cavernous internal carotid aneurysm should be included in the differential diagnosis. Cessation of epistaxis is immediately required with local packing. Flow-preservation bypass with proximal ligation of the parent artery is one of the effective procedures for the treatment of this condition with low morbidity.

Table 1. Characteristics of Previously Reported Nontraumatic Cavernous Carotid Artery Aneurysm Presenting with Epistaxis^{1,6-9,12-17}

Reference	Age (y)	Side of Aneurysm	Size of Aneurysm	Treatment	Final Result
Chandy et al., 1989 ¹³	53	Left	No data	Left common carotid artery ligation after passing Mata's test	Good
Romaniuk et al., 1993 ¹⁴	68	Left	Giant	No treatment	No data
Pritz, 1994 ⁸	60	Left	No data, fusiform	Direct clip reconstruction using extradural/intradural approach	Good, left oculomotor nerve paresis
Teitelbaum et al., 1995 ¹⁵	78	Right	Large	Detachable coil embolization of the aneurysm	Good, delayed ischemic stroke resulting from infected coils
Davies et al., 2011 ⁶	72	Left	Large	First: Coil embolization of the aneurysm (recurrent epistaxis after 1 week) Second: further coils and silk stent (a further episode of massive epistaxis) Third: left internal carotid artery occlusion using Gugliemi detachable coils and an Amplatz plug (after successful balloon occlusion testing with single-photon emission computerized tomography)	Good
Chaboki et al., 2004 ⁹	73	Right	Large	Coil embolization of the aneurysm and the right ICA (after successful balloon occlusion testing with hypotensive challenge)	Good
Karkanevatos et al., 2005 ¹²	23	Left Right	Giant ectatic Giant ectatic	Left: ICA ligation under local anesthesia (after trial of 30 min of ICA clamping) Right: STA-MCA bypass followed by a right ICA ligation under local anaesthesia (2 weeks later)	Mild transient right hemiparesis Good
Honeybul et al., 2006 ¹⁶	56	Left	4–5 mm	Gugliemi detachable coil embolization of the aneurysm	Good
Lehmann et al., 2009 ¹⁷	41	Right	4 × 3 mm	First: Coil embolization of the aneurysm (recurrent epistaxis after 3 weeks resulting from revascularization of the aneurysm with a migration of the coil into the sphenoid sinus) Second: Coil embolization of the aneurysm and uncovered stent	Good
Nomura et al., 2010 ¹	77	Left	No data (partially thrombosed)	Coil embolization of the aneurysm and ICA (after successful balloon occlusion test)	Good
Akkari et al., 2015 ⁷	67	Left	4 mm	First: Coil embolization of the aneurysm with preservation of the left ICA patency Second: flow-diverter stents for small residual aneurysm after postoperative seventh day	Good

ICA, internal carotid artery; STA, superficial temporal artery; MCA, middle cerebral artery.

Table 2. Outcome of Various Treatment Modalities for Nontraumatic Cavernous Carotid Artery Aneurysm Presenting With Epistaxis^{1,6-9,12-17}

Treatment	Number of Treatments	Outcome (%)		
		Complete Obliteration	Recurrence/Residual	Complication
Coil embolization of aneurysm	5	2 (40%)	3 (60%)	Delayed ischemic stroke (20%)
Coil embolization of parent artery	1	1 (100%)	0	-
Coil embolization of aneurysm and stenting	3	2 (67%)	1 (33%)	-
Coil embolization of parent artery and aneurysm	2	2 (100%)	0	-
Ligation of parent artery without bypass	2	2 (100%)	0	Transient hemiparesis (50%)
Ligation of parent artery with bypass	1	1 (100%)	0	-
Direct clipping of aneurysm	1	1 (100%)	0	CN3 paresis (100%)

REFERENCES

- Nomura M, Shima H, Sugihara T, Fukui I, Kitamura Y. Massive epistaxis from a thrombosed intracavernous internal carotid artery aneurysm 2 years after the initial diagnosis—case report. *Neurol Med Chir (Tokyo)*. 2010;50:127-131.
- Sriamornrattanakul K, Sakarunchai I, Yamashiro K, et al. Surgical treatment of large and giant cavernous carotid aneurysms. *Asian J Neurosurg*. 2017;12:382-388.
- Ko JK, Lee SW, Lee TH, Choi CH. Traumatic carotid cavernous fistula with a connection between the supraclinoid internal carotid artery and cavernous sinus via a pseudoaneurysm presenting with delayed Life-threatening Epistaxis. *NMC Case Rep J*. 2017;4:43-46.
- Garg K, Gurjar HK, Singh PK, et al. Internal carotid artery aneurysms presenting with epistaxis - our experience and review of literature. *Turk Neurosurg*. 2016;26:357-363.
- Mizunari T, Murai Y, Kim K, Kobayashi S, Kamiyama H, Teramoto A. Posttraumatic carotid-cavernous fistulae treated by internal carotid artery trapping and high-flow bypass using a radial artery graft—two case reports. *Neurol Med Chir (Tokyo)*. 2011;51:113-116.
- Davies A, Dale O, Renowden S. Spontaneous rupture of an intra-cavernous internal carotid artery aneurysm presenting with massive epistaxis. *J Laryngol Otol*. 2011;125:1070-1072.
- Akkari M, Gascou G, Trévillot V, Bonafé A, Crampette L, Machi P. Endovascular management of a carotid aneurysm into the sphenoid sinus presenting with epistaxis. *Interv Neuroradiol*. 2015; 21:660-663.
- Pritz MB. Ruptured nontraumatic fusiform aneurysm of the cavernous carotid presenting with multiple episodes of epistaxis. *Surg Neurol*. 1994; 42:293-296.
- Chaboki H, Patel AB, Freifeld S, Urken ML, Som PM. Cavernous carotid aneurysm presenting with epistaxis. *Head Neck*. 2004;26:741-746.
- Mahmoud NA. Traumatic aneurysm of the internal carotid artery and epistaxis. (Review of literature and report of a case). *J Laryngol Otol*. 1979;93: 629-656.
- Inoue T, Rhoton AL Jr, Theeie D, Barry ME. Surgical approaches to the cavernous sinus: a microsurgical study. *Neurosurgery*. 1990;26:903-932.
- Karkanevatos A, Karkos PD, Karagama YG, Foy P. Massive recurrent epistaxis from non-traumatic bilateral intracavernous carotid artery aneurysms. *Eur Arch Otorhinolaryngol*. 2005;262:546-549.
- Chandy MJ, Rajshekhar V. Nontraumatic intracavernous carotid aneurysm presenting with epistaxis. *J Laryngol Otol*. 1989;103:425-426.
- Romaniuk CS, Bartlett RJ, Kavanagh G, Salam MA. An unusual cause of epistaxis: non-traumatic intracavernous carotid aneurysm. A case report with 12 year follow-up and review of the literature. *Br J Radiol*. 1993;66:942-945.
- Teitelbaum GP, Halbach VV, Larsen DW, et al. Treatment of massive posterior epistaxis by detachable coil embolization of a cavernous internal carotid artery aneurysm. *Neuroradiology*. 1995;37:334-346.
- Honeybul S, Barker S, Poitelea C, Ditchfield A. Multiple intracranial aneurysms presenting with epistaxis. *J Clin Neurosci*. 2006;13:394-397.
- Lehmann P, Saliou G, Page C, Balut A, Le Gars D, Vallée JN. Epistaxis revealing the rupture of a carotid aneurysm of the cavernous sinus extending into the sphenoid: treatment using an uncovered stent and coils. Review of literature. *Eur Arch Otorhinolaryngol*. 2009;266:767-772.
- Ishishita Y, Tanikawa R, Noda K, et al. Universal extracranial-intracranial graft bypass for large or giant internal carotid aneurysms: techniques and results in 38 consecutive patients. *World Neurosurg*. 2014;82:130-139.
- Lawton MT, Hamilton MG, Morcos JJ, Spetzler RF. Revascularization and aneurysm surgery: current techniques, indications, and outcome. *Neurosurgery*. 1996;38:83-92 [discussion 92-94].
- Javedan SP, Deshmukh VR, Spetzler RF, Zabramski JM. The role of cerebral revascularization in patients with intracranial aneurysms. *Neurosurg Clin N Am*. 2001;12:541-555.
- Houkin K, Kamiyama H, Kuroda S, Ishikawa T, Takahashi A, Abe H. Long-term patency of radial artery graft bypass for reconstruction of the internal carotid artery. Technical note. *J Neurosurg*. 1999;90:786-790.
- Dolenc VV. A combined epi- and subdural direct approach to carotid-ophthalmic artery aneurysms. *J Neurosurg*. 1985;62:667-672.

Conflict of interest statement: The authors declare that the article content was composed in the absence of any commercial or financial relationships that could be construed as a potential conflict of interest.

Received 17 March 2019; accepted 24 April 2019

Citation: *World Neurosurg*. (2019) 128:23-28.
<https://doi.org/10.1016/j.wneu.2019.04.213>

Journal homepage: www.journals.elsevier.com/world-neurosurgery

Available online: www.sciencedirect.com

1878-8750/\$ - see front matter © 2019 Elsevier Inc. All rights reserved.