

## Despite dystonia: natural history of delayed-onset pediatric secondary dystonia

Tal Krasovsky, Orly Bar, Uli Nachshon, Abigail Livny, Galia Tsarfaty, Amichai Brezner & Jana Landa

To cite this article: Tal Krasovsky, Orly Bar, Uli Nachshon, Abigail Livny, Galia Tsarfaty, Amichai Brezner & Jana Landa (2019) Despite dystonia: natural history of delayed-onset pediatric secondary dystonia, *Brain Injury*, 33:7, 952-958, DOI: [10.1080/02699052.2019.1606452](https://doi.org/10.1080/02699052.2019.1606452)

To link to this article: <https://doi.org/10.1080/02699052.2019.1606452>



Published online: 05 May 2019.



Submit your article to this journal [↗](#)

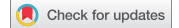

Article views: 33



View Crossmark data [↗](#)

CASE REPORT



## Despite dystonia: natural history of delayed-onset pediatric secondary dystonia

Tal Krasovsky<sup>a,b</sup>, Orly Bar<sup>a</sup>, Uli Nachshon<sup>a</sup>, Abigail Livny<sup>c,d,e</sup>, Galia Tsarfaty<sup>c,e</sup>, Amichai Brezner<sup>a</sup>, and Jana Landa<sup>a,e</sup>

<sup>a</sup>Pediatric Rehabilitation Department, Sheba Medical Center, Tel Hashomer, Ramat Gan, Israel; <sup>b</sup>Department of Physical Therapy, Faculty of Social Welfare and Health Sciences, University of Haifa, Haifa, Israel; <sup>c</sup>Department of Diagnostic Imaging, Sheba Medical Center, Tel Hashomer, Ramat Gan, Israel; <sup>d</sup>J. Sagol Neuroscience Center, Sheba Medical Center, Tel Hashomer, Ramat Gan, Israel; <sup>e</sup>Sackler Faculty of Medicine, Tel Aviv University, Tel Aviv, Israel

### ABSTRACT

**Background:** Dystonia is a movement disorder involving involuntary movements and/or postures of the limbs, trunk, neck or face. Secondary dystonia following brain injury is uncommon, with unfavorable long-term consequences. Given the limited evidence regarding pediatric secondary dystonia, this study's aim was to document the natural history of the condition and the effect of interventions on its symptomatology.

**Methods:** We describe three cases of girls (age 8 to 11 y) who developed dystonia secondary to an acquired brain injury, received intensive rehabilitation treatments and were followed for 8–33 months post-injury. In all three cases, secondary dystonia appeared 1–3 months post-insult.

**Results:** In none of the cases was there alleviation of dystonic symptoms over time despite physical and pharmacological interventions; in two cases the dystonic hand is now used as an assisting hand only, whereas in the third it is completely non-functional. However, despite their impairment, two girls achieved basic functional independence and one is partly independent in activities of daily living.

**Conclusions:** Rehabilitation professionals who work with pediatric patients susceptible to developing secondary dystonia should be aware of its possible consequences and inform families and staff. Intensive task-specific training during rehabilitation may be key to regaining overall functional capabilities despite residual impairment.

### ARTICLE HISTORY

Received 26 July 2018  
Accepted 8 April 2019

### KEYWORDS

Rehabilitation; acquired brain injury; hand function; movement disorders; case report

## Introduction

Dystonia is a movement disorder involving involuntary movements and/or postures of the limbs, trunk, neck or face (1). Dystonia may arise from genetic disorders (“primary”), or, less frequently (2) from peri-natal ischemia, infections, head trauma (3), medications or metabolic diseases (“secondary”) (4). Secondary dystonia usually is associated with lesions of the basal ganglia or the thalamus (5) often following ischemic stroke (6). In children, this phenomenon may manifest months or years after the original brain insult, and the mechanism underlying its appearance is still unclear (7). Treatment options include pharmacotherapy (8), botulinum neurotoxin injections (9), deep brain stimulation (10) and physical and occupational therapy (4). Management of pediatric secondary dystonia is especially challenging since both pharmacological treatments and deep brain stimulation are less effective in children with secondary, compared with primary dystonia (11). Given the detrimental long-term consequences of dystonia on activities of daily living and quality of life (12), documenting the natural history of pediatric secondary dystonia and the effect of interventions on its symptomatology is essential. Thus, the current work presents the long-term outcomes of three children who developed delayed secondary dystonia subsequent to brain injury. The three girls, with diverse patterns of injury etiology and symptom progression, underwent rehabilitation in a Pediatric Rehabilitation department and were evaluated

longitudinally using outcome measures addressing the different levels of the International Classification of Functioning, Disability and Health (ICF (13)). In absence of a clinical guideline for treatment of pediatric secondary dystonia (14), the aim of the current work is to evaluate their long-term progression in the different domains in light of the treatment received.

The three girls were admitted to Pediatric Rehabilitation approximately 1-month post-insult. During inpatient hospitalization, they received intensive physical and occupational therapy (daily sessions 5 times a week) as well as speech therapy, psychotherapy, and familial support. During outpatient hospitalization, treatment intensity was gradually decreased from 3 to 2 times a week. During therapy sessions, all three were treated with a therapeutic approach composed of the same principles: passive movement, strength training, somatosensory training (including use of neoprene splints) and task-specific training focused on function (15). Several strategies were attempted for task-specific functional training: (1) a computerized biofeedback system for upper limb movement (16), (2) a computerized kinect-based virtual reality system (17), (3) repetitive motor training intended to exit dystonic patterns, and (4) contextual functional training using everyday objects (e.g. a key, a bottle, a toothbrush, etc.). Bilateral arm use was encouraged during training when possible.

The girls were followed for 8–33 months post-injury and underwent routine evaluations of function according to the different levels of the ICF (Table 1): muscle strength (grip, pinch;

body function and structures domain), gross motor skill (Box and Blocks test (18)) and fine motor skill (Nine Hole Peg Test (19)), both in the activity domain of the ICF (capacity). In addition, activity performance and participation capabilities were assessed using the Hebrew version of the Pediatric Evaluation of Disability Inventory (PEDI) (20,21). The PEDI is a widely used criterion- and norm-referenced test of performance capabilities which is further divided into three subscales: functional skills (what the child can do), caregiver assistance (how much help the child is given) and social function (which was not addressed here since the children were in the hospital during test administration). For each subscale, performance capability is assessed for different activities. For the current work, PEDI functional skills and caregiver assistance scores for mobility (59 items) and self-care (73 items) were transformed into age-independent normative scaled scores, ranging from 0 to 100. The mean PEDI score within each age group is 50, and  $\pm 2SD$  from the mean (scores of 30–70) include 95% of children. A change of 11 points on the PEDI scaled score is considered clinically meaningful (22). Written informed consent was obtained from families according to the hospital's ethics review board.

### Case no. 1

BB was an 11 y old girl when she was involved in a car accident as a pedestrian. She was diagnosed with diffuse axonal injury (spanning both hemispheres and involving right frontal areas, right midbrain, and right corticospinal tract) and hemorrhage in the

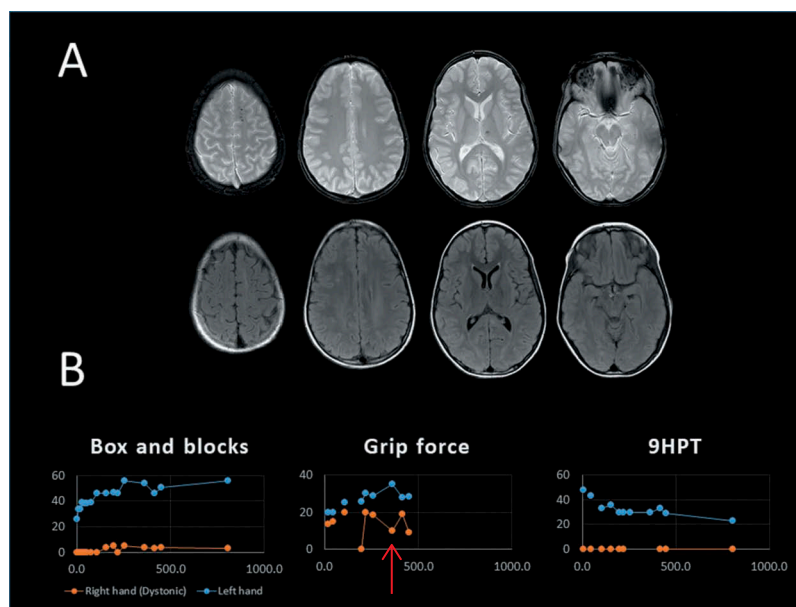
frontal lobe, left corpus callosum, left posterior horn of lateral ventricles and left thalamus (Figure 1(a)). Upon admission to rehabilitation, she had left hemiparesis (with no sensory deficits) but was able to grasp objects with her right (dominant) hand. She also had oral pharyngeal apraxia and mutism. She was completely dependent in all self-care activities (PEDI functional skills self-care : 41.2, mobility: 29.0; caregiver assistance self-care: 35.0, mobility: 40.9). In rehabilitation, her left (hemiparetic) arm improved in strength and control. BB was discharged from inpatient hospitalization 5 months post-injury, with PEDI functional skills scores of 65.3 (self-care) and 71.6 (mobility) and caregiver assistance scores of 66.9 (self-care) and 66.7 (mobility), indicating partial independence in activities of daily living (ADL).

Dystonia in her right hand was noticed 2 months post-injury as a static flexor posture in her right fingers. While proximal muscle strength in her right arm gradually improved, it was extremely difficult for her to extend her fingers. BB refrained from using her right hand except as an assisting hand, and hand dominance was fully transferred to the left within several weeks. Simultaneously, a dystonic posture appeared in her jaw and she was able to close her mouth only with assistance. Her oral dyspraxia worsened, and drooling appeared with effort. Seven months from injury, when discharged from inpatient hospitalization, BB was partly independent in ADLs (PEDI functional skills scores of 66.8 (self-care) and 79.8 (mobility) and caregiver assistance scores of 69.6 (self-care) and 68.5 (mobility)). However, the dystonic postures persevered, with involvement of the elbow and

**Table 1.** Evaluation of function in three representative time points for the three cases. The numbers represent raw score for each evaluation. In brackets: the number of standard deviations from age- and gender referenced norms (z-score).

Case	Evaluation	Time from admission (days)	Dominant side (dystonic) – Score (z-score)	Non-dominant side (not dystonic) – Score (z-score)
No. 1	Grip strength (lb)	17	13.33 (–2.46)	20.00 (–1.93)
		220	20.00 (–1.76)	30.00 (–0.8)
		449	9.0 (–4.19)	28.3 (–2.01)
	Lateral pinch (lb)	17	2.33 (–3.7)	4.60 (–2.17)
		220	5.00 (–2.43)	10.00 (0.08)
		449	1.0 (–4.3)	7.6 (–0.9)
	Box and Blocks (N)	17	0	34 (–3.91)
		220	0	46 (–2.51)
		449	4 (–7.4)	51 (–1.93)
	Nine Hole Peg Test (sec)	17	Unable	48 (9.4)
		220	Unable	30 (3.5)
		449	Unable	29 (3.2)
No. 2	Grip strength (lb)	0	18.3 (–0.67)	23.3 (–0.06)
		65	20.0 (–0.46)	32.3 (1.08)
		237	20.0 (–0.46)	30.0 (0.78)
	Lateral pinch (lb)	0	7.3 (–0.36)	6.0 (–0.68)
		65	6.3 (–0.76)	8.0 (0.04)
		237	8.0 (–0.08)	9.0 (0.39)
	Box and Blocks (N)	0	38 (–4.86)	49 (–2.19)
		65	34 (–5.65)	49 (–2.19)
		237	24 (–7.61)	45 (–2.96)
	Nine Hole Peg Test (sec)	0	36 (9.1)	27 (1.8)
		65	35 (8.6)	26 (1.5)
		237	60 (21.7)	29 (2.4)
No. 3	Grip strength (lb)	28	32.7 (0.77)	41.7 (2.06)
		98	31.7 (0.6)	44.0 (2.38)
		1016	16.7 (–1.8)	46.7 (2.74)
	Lateral pinch (lb)*	28	9.7 (0.48)	10.8 (0.73)
		98	12 (–9.96)	49 (–2.19)
	Box and Blocks (N)	28	40 (–4.47)	48 (–2.38)
		98	18 (–8.78)	58 (–0.46)
		1016	18 (–8.78)	58 (–0.46)
	Nine Hole Peg Test (sec)	28	39 (10.7)	27 (1.8)
		98	85 (34.9)	20 (–0.4)
		1016	80 (32.2)	25 (1.0)

\*Two measurements of lateral pinch are missing for technical reasons.



**Figure 1.** (a) MRI scan of BB taken 3 months following injury. Axial slices, Top row: a T2 gradient echo (GRE) scan, sensitive to paramagnetic blood products demonstrating small regions of hypointense lesions in the left and right frontal lobes, left thalamus and basal cistern. Bottom row: Fluid-attenuated inversion recovery (FLAIR) hyperintense foci in the same regions. (b) Evaluations of hand function for BB. 9HPT = Nine hole peg test. A red arrow marks occurrence of a Botulinum Toxin injection and its effect on grip force.

shoulder. During the effort, the arm assumed a dystonic posture with 90 degrees abduction of the shoulder, shoulder hyperextension and full flexion in the elbow, wrist, and fingers.

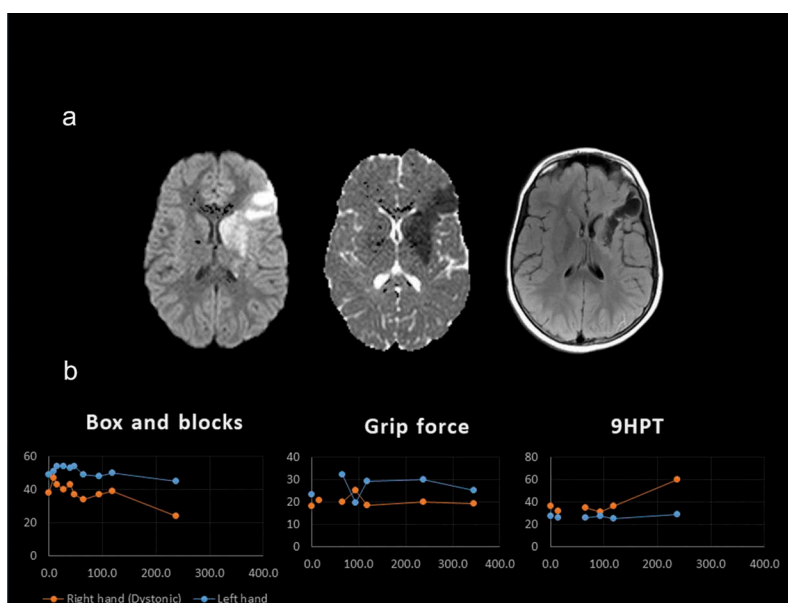
During rehabilitation, BB underwent botulinum toxin injections (Dysport; arm and hand: 275 units, jaw: 40 units) every three months to right arm muscles (deltoid, biceps brachii, pronator teres), hand muscles (opponens pollicis) and jaw muscles (digastric, pterygoid). Finger flexor muscles and lumbricals were injected and resulted in further reduced grip function (see, for example, Figure 1(b), red arrow: a reduction of ~50% in grip force following a Dysport injection, from 18.33lb to 10lb; a concurrent decrease in pinch strength was noted, from 5.16lb to 2lb – not in figure). However, BB's right grip force during rehabilitation achieved 20lb at most, which is still 1.76 standard deviations below age norms and lateral pinch was at most 5.6lb, 2.35 standard deviations below age norms. Thus, these limited forces were not considered functional and the injections to finger muscles as well as to distal arm muscles were continued considering their cosmetic value in alleviating the dystonic posture. Proximal injections to the arm were ineffective and were stopped. In contrast, injections to the jaw were continued and considered effective in enabling the mouth to close. BB received Tetrabenzine (25 mg, twice daily), which was replaced by Trihexyphenidyl (1 mg, twice daily) after 3 months due to lack of effect and a side effect of sleepiness. After 1 year, Trihexyphenidyl was discontinued as well due to lack of change in function. During sessions, bilateral functional training was emphasized and the use of the dystonic hand as an assisting hand was encouraged. The results of her functional arm evaluations are depicted in

Figure 1(b). BB attended outpatient rehabilitation for 16 months. Two years post-insult, she was able to use her dystonic hand as an assisting hand with a partial power grip (both power and pinch grip were over two standard deviations below age norms). Despite some return of grip force in her right hand (Figure 1(b)), the right arm did not regain either gross or fine motor function.

Four years post-insult, at age 15, BB is still limited in communication and eating due to her motor speech disorder (hyperkinetic dysarthria) associated with her dystonia. She is still mute. She still receives hydrotherapy, physical and language therapy (2–3 times a week), but further deterioration in her use of the dystonic hand occurred and her dystonic arm is completely non-functional, not even as an assisting hand. However, according to parental report, she is fully independent in ADLs and attends a regular school with some modifications.

### Case no. 2

EL was an 8 y old girl when she was hospitalized with acute ischemic left MCA stroke. An MRI revealed ischemic damage to the left frontal lobe, left basal ganglia, mainly putamen and globus pallidus (Figure 2(a)). EL Initially had right hemiparesis and central facial palsy, with slightly increased muscle tone in her right arm (with no sensory deficits). During her hospitalization (2 months as an inpatient, 1 year as an outpatient) the increased tone disappeared and muscle strength in her right arm returned to normal. She was independent in basic ADLs, with a PEDI functional skills self-care score which increased from 74.7 on admission to 93 after 2 months. Her PEDI mobility score was 100 since admission. Caregiver assistance scores increased from 76.7 (self-care) and 85



**Figure 2.** (a) MRI scan of EL taken following injury. Axial slices, Right: Two right images, taken immediately after injury, demonstrate restriction in diffusion weighted images in the territory of the left MCA including the left basal ganglia, in acute stage. Left: T2-FLAIR image, taken 6 months post-injury, demonstrates the chronic damage in the same regions. (b) Evaluations of hand function for EL. 9HPT = Nine hole peg test.

(mobility) on admission to 83.2 (self-care) and 100 (mobility) after 2 months, indicating a high level of functional independence in self-care activities and complete independence in mobility.

A dystonic posture in her right (dominant) arm appeared upon release from hospital (2 months post-insult), characterized by full elbow flexion with wrist extension and thumb flexion. She was initially able to exit this posture and performed bilateral movements, albeit slower and less precise, as can be seen in functional evaluations such as the Box and Blocks or 9 Hole Peg Test (Table 1, Figure 2(b)). Her grip and pinch force were within norms. In addition to the arm, EL developed dystonia in her right foot (dorsiflexion of the big toe) which resulted in a change in her gait pattern (right foot inversion, dragging of the foot). Five months post-insult, the dystonic arm pattern was extended to shoulder abduction and extension and hand dominance was fully transferred to the non-dystonic hand. It became increasingly difficult for EL to exit the dystonic posture and use her right arm as an assisting hand. Use of everyday objects during rehabilitation sessions and everyday life facilitated the process of exiting the dystonic posture, but the dystonic patterns worsened when the task was associated with increased fine motor requirements.

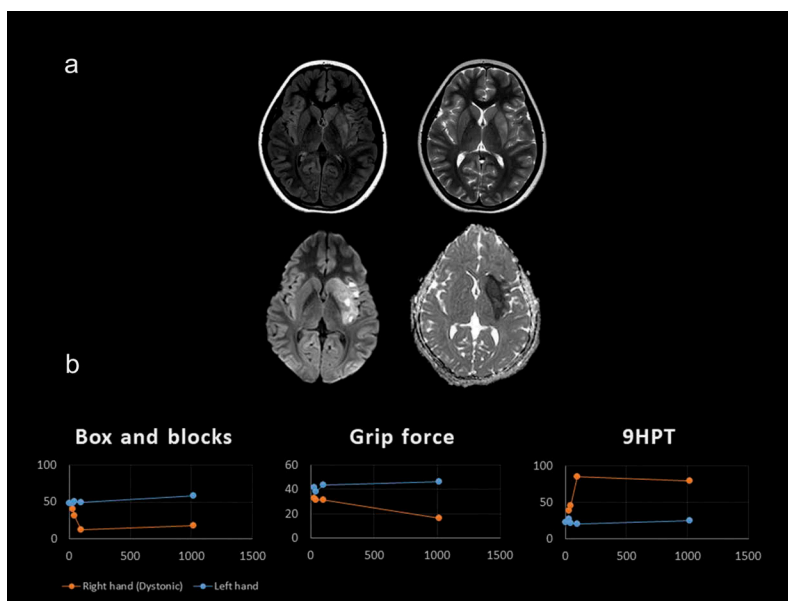
During hospitalization, EL was treated with Aspirin. Treatment with Tetrabenzine (12.5 mg, twice daily) was discontinued due to side effects (fatigue and mood disorders – crying). She was since then treated with Trihexyphenidyl (2.5 mg, twice daily) with a small improvement in function, but discontinued after 2 months. Botulinum toxin injections (Dysport; 125 units) were administered to the leg (tibialis posterior and extensor hallucis longus muscle), relieved toe dorsiflexion and improved the gait pattern. After 2 years, treatment effectiveness decreased, and dosage was increased to 300 units. Injections to the arm were not considered due to the extent of muscles involvement.

Following discharge from outpatient rehabilitation, EL continued to receive physical and occupational therapy 1–2 times a week (intermittently). Five years post-insult, EL's right hand is used as an assisting hand, and the dystonic pattern is variable and worsens with effort, both physical (e.g. gait) and cognitive (attentional demand). When the hand is not in use, increased tone appears in variable postures. EL's gait pattern is still affected by her dystonic foot. However, EL is independent in basic ADLs and attends a regular school (with an assistant) where she types with her left (non-dystonic) hand and uses the right hand effectively for stabilization.

### Case no. 3

MR was a healthy 9 y old girl when she was diagnosed with left MCA ischemic stroke several hours following a fall. An MRI revealed ischemic damage to the left insula, basal ganglia and corona radiata (Figure 3(a)). She was suspected with left internal carotid artery dissection which could have caused the stroke and during hospitalization she was also diagnosed with hyper-coagulation and is treated with Coumadin ever since. MR initially presented with right hemiparesis, central facial palsy, and aphasia. Movement in her right arm gradually returned. During her rehabilitation (2.5 months as an inpatient and 11 months outpatient), MR presented with a small change in self-care function and a larger change in mobility: her PEDI functional skills scores increased from 66.8 (self-care) and 49.7 (mobility) to 74.7 and 89.2 three months post-injury. Caregiver assistance scores changed from 63.4 (self-care) and 66.7 (mobility) to 74.5 and 66.7 (i.e. no change in mobility or self-care level of independence).

A dystonic posture in her right (dominant arm), involving abduction and internal rotation of the shoulder, flexion of the



**Figure 3.** (a) MRI scan of MR taken immediately following injury. Axial slices, top row: left, FLAIR image; right, T2 image, demonstrating ischemic changes in the basal ganglia. Bottom: Diffusion weighted imaging demonstrating acute restriction in the basal ganglia. (b) Evaluations of hand function for BB, 9HPT = Nine hole peg test.

elbow and flexion of wrist and fingers, appeared 1.5 months post-insult during motor effort. In addition, a dystonic pattern of external rotation appeared in her right foot. Associated movements appeared in the jaw, especially during performance of fine motor skills using her right arm, but these have decreased with time. Figure 3(b) highlights a deterioration in gross and fine motor skills during the first 3 months and stabilization since. Grip force in her right arm decreased somewhat with time. Two years post-insult MR reported decreased sensation (light touch) in her right arm (proximally and distally) and in her right foot.

Pharmaceutical interventions were not offered to the family due to the relative focal nature of the dystonic symptom. Injections of botulinum toxin were offered but rejected by the family.

Following discharge from outpatient rehabilitation, MR continued to receive hydrotherapy, physical therapy, and speech therapy once a week. Three years post-insult, MR is integrated in a regular school (with an assistant). She is partly independent in ADLs, and receives help in activities such as dressing, washing and tying shoelaces. Her right arm is used only as an assisting hand and the dystonic pattern is prominent. When asked to perform tasks with her right-hand MR is able to perform both power and pinch grips with limited force regulation. Flexor tone in the fingers is variable. MR is partly able to exit the dystonic pattern by using functional cues such as everyday objects, or cognitive strategies such as “to walk like a soldier”.

## Discussion

Secondary dystonia is extremely rare in adults (23). Although more common in children, rising up to 21% among children with basal ganglia stroke (6), literature dealing with secondary dystonia in children is scarce. Indeed, the experience of a child manifesting dystonic symptoms >1 month post-insult

can be disheartening for clinicians and families alike. The current work presents three cases with similar negative prognostic factors: the literature suggests that children with left side basal ganglia lesions (as two of the cases here) are more likely to develop secondary dystonia, possibly due to the lateralization of functions of praxis to the left hemisphere (24). Girls are more susceptible compared to boys (6) and younger age at insult may also be associated with increased symptom severity due to changes in brain metabolism (25). Thus, in these three cases, the prognosis of dystonia is quite guarded. Long-term follow-up of these three girls revealed several common features, despite different injury mechanisms: in all cases, symptom severity increased over time and response to treatment was generally poor. In the case of BB, dystonic symptoms were especially prominent and the ability to exit the dystonic posture was reduced compared with the other girls. This was probably due to her different injury mechanism; a complex bilateral diffuse axonal injury with left thalamic damage due to traumatic brain injury (unlike basal ganglia involvement with a unilateral lesion following a stroke for EL and MR). Her diffuse pattern of injury may involve different cerebello-thalamo-cortical pathways and may underlie the increased severity of dystonia in this case and the complete absence of hand use in the long run (26).

Despite the different injury mechanisms, the impact of dystonia in these three cases was consistent. Furthermore, our results demonstrated that impact varied according to the domain of the ICF evaluated. Grip and pinch forces, measures of impairment, were within age norms in two cases and unchanging in the third case – in all cases deficits in strength were unrelated to progression of dystonia. In contrast, the impact of dystonia on measures of activity capacity (Box and Blocks, 9HPT) in these girls was profound and increased with time. Finally, in two of the three cases complete independence in basic ADLs was achieved over time, and partial independence in the third case – as

evidenced by their PEDI scores and families' report. The ability to achieve functional independence in the presence of an aggravating activity limitation can be resolved by considering two main factors. The first is that in the three cases presented here, family played a crucial role and was fully committed to the rehabilitation process (27). Families assisted, among other things, with environmental modifications required to promote independence (e.g. specialized devices for one-hand operation of everyday objects). The second is that in all three cases, functional, meaningful bilateral task-specific training was used. We propose that this strategy was effective since it assisted the girls to exit the dystonic pattern initially, and later, when exiting the dystonic pattern was more difficult, enabled the use of compensatory motor patterns which promoted functional independence even without a significant decrease in dystonic symptoms. Task- and context-specific training are well-known principles of stroke rehabilitation (15,28), based on a large amount of evidence supporting the superiority of practice of motor tasks which are relevant to the patient (29) and providing rehabilitation in the patient's home and natural environment (30). In the prolonged follow-up following rehabilitation, support was provided for the girls and their families in setting motor goals relevant to them, specifically in ADLs and instrumented ADLs. We believe that similar to its role in focal dystonia (31), task-specific training enabled the transition of the girls to functional independence in the long run. To a certain extent, use of everyday objects in rehabilitation facilitated bilateral arm function and use of mental imagery (e.g. "walk like a soldier") improved the gait pattern. Another important factor to be considered in order to promote function in the long term is an early transfer of hand dominance. In delayed-onset movement disorders, hand dominance transfer is more likely to succeed at a younger age (25). We suggest that children with secondary dystonia may benefit from early training for transfer of hand dominance.

Management of dystonia in rehabilitation is multi-faceted, geared not only towards improvement of function of the affected body part, but towards functional improvement of the body as a whole, as it relates to activities of daily living and participation in the community. Thus, in the long-term follow-up of the cases described here, although function in the dystonic body part(s) gradually deteriorated, the children's functional capabilities improved with rehabilitation. This approach addresses one of the major concerns of families and children with dystonia (32), i.e. difficulties with ADLs and self-care. This work also highlights the importance of measurement of change following rehabilitation at the different levels of the ICF framework – since measurement solely on impairment-based scales may limit the appreciation of change over time in pediatric dystonia (32). An important limitation of the current work is that community participation and health-related quality of life measures were absent from the case descriptions. However, over 80% of variance in social participation of children after acquired brain injuries are explained by discharge self-care scores (33) indicating that some indication of social status can be inferred from existing scores.

Delayed-onset secondary dystonia in children typically responds poorly to pharmaceutical treatment (34). In the cases presented here, neither Tetrabenzine nor Trihexyp henidyl were associated with functional improvements, and the only pharmacological intervention which generated functional improvement was botulinum toxin injected to the jaw in one case and to the leg in another. Botulinum toxin-A was previously shown to promote hand function in children with dystonia following acquired brain injury (35), but the long-term follow-up of the cases presented here reveals the weakness of botulinum toxin-A, namely decreasing efficacy and a requirement to increase dosage to maintain efficacy. Botulinum toxin injections may also not be effective when the number of muscles to be injected is high, as was the case for the arm of BB. These factors, as well as possible weakness due to injections, should be considered carefully for this course of treatment.

In the three cases described here, several other treatments were considered but eventually not attempted. Constraint-induced movement therapy and inhibitory casting were not attempted due to unsuccessful prior experience and lack of supporting evidence. Deep brain stimulation of the globus pallidus, which is effective for children with primary dystonia (36) and cerebral palsy (37) is less effective in secondary dystonia in adults (38) and lacks supporting evidence in children (39), and thus was not used in these cases.

In conclusion, the three cases described here demonstrate a guarded prognosis for secondary dystonia in children, with limited effectiveness of interventions targeted at motor impairment of the dystonic limb. Rehabilitation experts who face the onset of secondary dystonia in children need to acknowledge its implications and prepare the child, family, and environment for possible functional outcomes of secondary dystonia. However, in order to achieve functional independence in these cases, we propose that clinicians focus on context- and task-specific training along with early transfer of hand dominance. Based on our experience, this rehabilitation approach can promote function in the long term in these rare cases.

## Disclosure Statement

The authors declare they have no conflict of interest.

## References

1. Fahn S, Eldridge R. Definition of dystonia and classification of the dystonic states. *Adv Neurol.* 1976;14:1–5.
2. Geyer HLBressman SB. The diagnosis of dystonia. *The Lancet Neurology.* 2006sep1;5(9):780–90. doi:10.1016/S1474-4422(06)70547-6.
3. Krauss JK, Jankovic J. Head injury and posttraumatic movement disorders. *Neurosurgery.* 2002 May 1;50(5):927–40.
4. Jinnah HA, Factor SA. Diagnosis and treatment of dystonia. *Neurol Clin.* 2015 Feb;33(1):77–100. doi:10.1016/j.ncl.2014.09.002.
5. Mehanna R, Jankovic J. Movement disorders in cerebrovascular disease. *Lancet Neurol.* 2013 Jun 1;12(6):597–608. doi:10.1016/S1474-4422(13)70057-7.
6. Soman T, Askalan R, Martin M, Allen A, Zak M, MacGregor D, Logan W. Predictors of dystonia in childhood Basal Ganglia

- stroke. *Neuropediatrics*. 2006;37(S1):TP121. doi:10.1055/s-2006-945715.
7. Tibussek D, Mayatepek E, Klee D, Koy A. Post stroke hemi-dystonia in children: a neglected area of research. *Mol Cell Pediatr*. 2015 Dec 1;2(1):14. doi:10.1186/s40348-015-0026-2.
  8. Bressman SB, Greene PE. Dystonia. *Curr Treat Options Neurol*. 2000 May 1;2(3):275–85. doi:10.1007/s11940-000-0009-y.
  9. Albanese A, Romito LM, Calandrella D. Therapeutic advances in dystonia. *Mov Disord*. 2015;30(11):1547–56. doi:10.1002/mds.26384.
  10. Vidailhet M, Jutras M-F, Grabli D. E. Deep Brain Stimulation for Dystonia. *J Neurol Neurosurg Psychiatry*. 2013;84:1029–1042.
  11. Mink JW. Special concerns in defining, studying, and treating dystonia in children. *Mov Disord Off J Mov Disord Soc*. 2013 Jun 15;28(7):921–25. doi:10.1002/mds.25548.
  12. Diamond A, Jankovic J. The effect of deep brain stimulation on quality of life in movement disorders. *J Neurol Neurosurg Psychiatry*. 2005;76(9):1188–93. doi:10.1136/jnnp.2004.057851.
  13. World Health Organization. International classification of functioning, disability and health: ICF. World Health Organization, Geneva; 2001.
  14. Luc QN, Querubin J. Clinical management of dystonia in childhood. *Pediatr Drugs*. 2017 Oct 1;19(5):447–61. doi:10.1007/s40272-017-0243-3.
  15. Thomas Lois H, Beverley F, Jacqueline C, Naoimh M, Louise C, Joanna H, Sutton Christopher J, Svetlana T, Watkins Caroline L. Repetitive task training for improving functional ability after stroke. *Stroke*. 2017 Apr 1;48(4):e102–3. doi:10.1161/STROKEAHA.117.017394.
  16. Carmeli E, Peleg S, Bartur G, Elbo E, Vatine J. HandTutorTM enhanced hand rehabilitation after stroke – a pilot study. *Physiother Res Int*. 2011;16(4):191–200. doi:10.1002/pri.v16.4.
  17. Kizony R, Weiss PL, Elion OHarel S, Baum-cohen i, krasovsky t, feldman y, shani m. Development and Validation Of Tele-health System for Stroke Rehabilitation. *Int J Disabil Hum Dev*. 2014;13(3):361–8.
  18. Mathiowetz V, Volland G, Kashman N, Weber K. Adult norms for the Box and Block Test of manual dexterity. *Am J Occup Ther*. 1985;39(6):386–91. doi:10.5014/ajot.39.6.386.
  19. Poole JL, Burtner PA, Torres TA, McMullen CK, Markham A, Marcum ML, Anderson JB, Qualls C. Measuring dexterity in children using the Nine-hole Peg Test. *J Hand Ther*. 2005;18(3):348–51. doi:10.1197/j.jht.2005.04.003.
  20. Haley S, Coster W, Ludlow LHaltiwanger J, Andrellos P. Pediatric evaluation of disability inventory. New England Medical Center Hospitals. Boston, MA; 1992
  21. Elad D, Barak S, Eisenstein E, Bar O, Herzberg O, Brezner A. Reliability and validity of Hebrew Pediatric Evaluation of Disability Inventory (PEDI) in children with cerebral palsy – health care professionals vs. mothers. *J Pediatr Rehabil Med*. 2012;5(2):107–15.
  22. Iyer LV, Haley SM, Watkins MP, Dumas HM. Establishing minimal clinically important differences for scores on the pediatric evaluation of disability inventory for inpatient rehabilitation. *Phys Ther*. 2003 Oct 1;83(10):888–98.
  23. Alarcón F, Zijlmans JCM, Dueñas G, Cevallos N. Post-stroke movement disorders: report of 56 patients. *J Neurol Neurosurg Psychiatry*. 2004 Nov 1;75(11):1568–74. doi:10.1136/jnnp.2003.011874.
  24. Johnson-Frey SH, Newman-Norlund R, Grafton ST. A distributed left hemisphere network active during planning of everyday tool use skills. *Cereb Cortex*. 2005 Jun 1;15(6):681–95. doi:10.1093/cercor/bhh169.
  25. Scott BL, Jankovic J. Delayed-onset progressive movement disorders after static brain lesions. *Neurology*. 1996;46(1):68–74. doi:10.1212/WNL.46.1.68.
  26. Stoessl AJ, Lehericy S, Strafella AP. Imaging insights into basal ganglia function, Parkinson's disease, and dystonia. *Lancet*. 2014 Aug 9;384(9942):532–44. doi:10.1016/S0140-6736(14)60041-6.
  27. Laatsch L, Harrington D, Hotz G, Marcantuono J, Mozzoni MP, Walsh V, Hersey KP. An evidence-based review of cognitive and behavioral rehabilitation treatment studies in children with acquired brain injury. *J Head Trauma Rehabil*. 2007;22(4):248–56. doi:10.1097/01.HTR.0000281841.92720.0a.
  28. Langhorne P, Bernhardt J, Kwakkel G. Stroke rehabilitation. *Lancet*. 2011;377(9778):1693–702. doi:10.1016/S0140-6736(11)60325-5.
  29. Bayona NA, Bitsensky J, Salter K, Teasell R. The role of task-specific training in rehabilitation therapies. *Top Stroke Rehabil*. 2005 Jul 1;12(3):58–65. doi:10.1310/YJW0-FK07-TGN7-AVW7.
  30. Hsieh Y, Chang K, Hung J, Wu C, Fu M, Chen C. Effects of home-based versus clinic-based rehabilitation combining mirror therapy and task-specific training for patients with stroke: a randomized crossover trial. *Arch Phys Med Rehabil*. 2018 Dec 1;99(12):2399–407. doi:10.1016/j.apmr.2018.03.017.
  31. Zeuner K, Molloy F. Abnormal reorganization in focal hand dystonia—sensory and motor training programs to retrain cortical function. *NeuroRehabilitation*. 2008;23(1):43–53.
  32. Lumsden DE, Gimeno H, Tustin K, Kaminska M, Lin J-P. Interventional studies in childhood dystonia do not address the concerns of children and their carers. *Eur J Paediatr Neurol*. 2015 May 1;19(3):327–36. doi:10.1016/j.ejpn.2015.01.003.
  33. Bedell GM, Dumas HM. Social participation of children and youth with acquired brain injuries discharged from inpatient rehabilitation: a follow-up study. *Brain Inj*. 2004 Jan 1;18(1):65–82. doi:10.1080/0269905031000110517.
  34. Bertucco M, Sanger TD. Current and emerging strategies for treatment of childhood dystonia. *J Hand Ther*. 2015 Apr 1;28(2):185–94. doi:10.1016/j.jht.2015.05.004.
  35. Guettard E, Roze E, Abada G, Lemesle C, Vidailhet M, Laurent-Vannier A, Chevignard DMP. Management of spasticity and dystonia in children with acquired brain injury with rehabilitation and botulinum toxin A. *Dev Neurorehabil*. 2009 Jan 1;12(3):128–38. doi:10.1080/17518420902927994.
  36. Kupsch A, Benecke R, Müller J, Trottenberg T, Schneider G-H, Poewe W, Eisner W, Wolters A, Müller J-U, Deuschl G. Pallidal deep-brain stimulation in primary generalized or segmental dystonia. *N Engl J Med*. 2006;355(19):1978–90. doi:10.1056/NEJMoa063618.
  37. Fehlings D, Brown L, Harvey A, Himmelmann K, Lin J-P, Macintosh A, Mink JW, Monbaliu E, Rice J, Silver J, et al. Pharmacological and neurosurgical interventions for managing dystonia in cerebral palsy: a systematic review. *Dev Med Child Neurol*. 2018. published online. doi: 10.1111/dmcn.13652.
  38. Eltahawy HA, Saint-Cyr J, Giladi N, Lang AE, Lozano AM. Primary dystonia is more responsive than secondary dystonia to pallidal interventions: outcome after pallidotomy or pallidal deep brain stimulation. *Neurosurgery*. 2004;54(3):613–21. doi:10.1227/01.NEU.0000108643.94730.21.
  39. Zhang JG, Zhang K, Wang ZC, Ge M, Ma Y. Deep brain stimulation in the treatment of secondary dystonia. *Chin Med J (Engl)*. 2006 Dec;119(24):2069–74. doi:10.1097/00029330-200612020-00008.