



Case Report

Tranexamic acid for treatment of pulmonary hemorrhage after tissue plasminogen activator administration for intubated patient



Snaha Sanghvi, DO, Anna Van Tuyl, MD, Josh Greenstein, MD, Barry Hahn, MD*

Department of Emergency Medicine, Staten Island University Hospital, Northwell Health, Staten Island, NY, United States of America

ARTICLE INFO

Article history:

Received 15 April 2019

Received in revised form 9 May 2019

Accepted 11 May 2019

Keywords:

Tranexamic acid

Tissue plasminogen activator

Pulmonary hemorrhage

Stroke

Intubation

ABSTRACT

Background: The risk of tPA in the treatment of stroke, is that approximately 5% of patients may have significant intracranial bleeding, increasing mortality to 45%. Use of tPA can also cause other forms of life-threatening bleeding, most commonly gastrointestinal bleeding. In this case review, we discuss the presentation and management of a patient with post-tPA pulmonary hemorrhage and the use of tranexamic acid (TXA) for the cessation of bleeding.

Case report: A 78-year-old female reported dysarthria, left-sided facial droop, left sided weakness of 1-hour duration with an initial NIH stroke scale (NIHSS) of 7. The patient had tPA administered, had an abrupt change in mental status and was ultimately intubated for airway protection. After endotracheal intubation, the patient began to hemorrhage from the endotracheal tube and was administered nebulized TXA totaling 2 g over the course of 20 min, with subsequent cessation of bleeding. tPA administration comes with inherent risks given the known bleeding complications and no consensus for the reversal of bleeding secondary to tPA. TXA may be a viable option in the setting of tPA induced pulmonary hemorrhage.

© 2019 Published by Elsevier Inc.

1. Introduction

Approximately 795,000 people in the United States suffer from strokes every year with stroke being the fifth leading cause of death nationally. Stroke is also the foremost cause of preventable long-term disability [1]. In patients meeting appropriate criteria, the initial treatment of ischemic stroke may include tissue Plasminogen Activator (tPA). The potential benefit of tPA is that nearly 45% of patients will recover without significant disability at three months if given within 3 h of onset of symptoms [2]. The risk of tPA is that approximately 5% of patients may have significant intracranial bleeding, increasing mortality to 45% [2]. Use of tPA can also cause other forms of life-threatening bleeding, most commonly gastrointestinal bleeding. In this case review, we will discuss the presentation and management of a patient with post-tPA pulmonary hemorrhage and the use of tranexamic acid (TXA) for the cessation of bleeding.

2. Case report

A 78-year-old female with a past medical history of hypertension, hyperlipidemia, and atrial fibrillation, not on anticoagulation, presented

to the emergency department. She reported dysarthria, left-sided facial droop, left sided weakness of 1-hour duration with an initial NIH stroke scale (NIHSS) of 7. The patient underwent computed tomography (CT) of the head, which showed no evidence of acute intracranial pathology. Since there was a high clinical suspicion for cerebrovascular accident, neurology was consulted and tPA was administered. Approximately 20 min after administration of tPA, the patient continued vomiting profusely, became less responsive to verbal and painful stimulus, and was unable to hold her head up. Due to this worsening in mental status the patient underwent rapid-sequence endotracheal intubation for airway protection.

Ten minutes after endotracheal intubation, the patient began to hemorrhage from the endotracheal tube with 300 cc of blood suctioned over the first 20 min. Video laryngoscopy was used to assess for bleeding in the supraglottic area. Since no source of bleeding was noted, the bleeding was suspected to be below the vocal cords. A subsequent chest radiograph showed a new opacity in the left lower lobe which was presumed to be pulmonary hemorrhage (Fig. 1). The patient was administered nebulized TXA totaling 2 g over the course of 20 min, with subsequent cessation of bleeding. In total, the patient had approximately 400 cc blood loss. After the bleeding was controlled, the patient was taken for a CT perfusion scan which showed occlusion of left PCA and left superior cerebellar artery with ischemic penumbra in the left occipital lobe and left superior cerebellum without core infarct. Also identified was a partially imaged left lower lobe ground-glass opacity, correlating to the location of the opacity on radiography, likely

* Corresponding author at: Department of Emergency Medicine, Staten Island University Hospital, 475 Seaview Avenue, Staten Island, NY 10305, United States of America.

E-mail address: ssanghvi4@northwell.edu (B. Hahn).

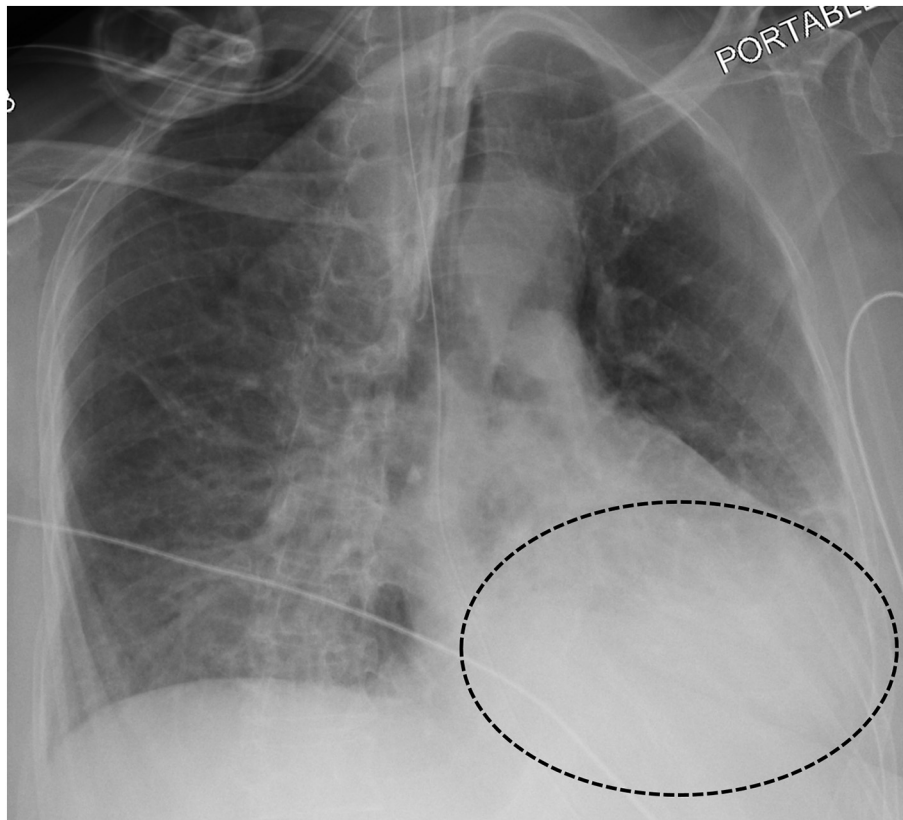


Fig. 1. Frontal chest radiograph demonstrating a retrocardiac parenchymal opacity (circle) obscuring the diaphragmatic border.

representing alveolar hemorrhage. The patient was extubated on hospital day 3 and discharged to home on hospital day 10 with an NIHSS of 0.

3. Discussion

Bleeding is a known complication of tPA administration. The mechanism of action of tPA involves binding to fibrin in a thrombus and converting the entrapped plasminogen to plasmin [3]. Unfortunately, there is no consensus for the reversal of bleeding secondary to tPA administration [4]. Currently, there is questionable efficacy of using cryoprecipitate or prothrombin complex concentrate (PCC) for reversal of tPA. Although, cryoprecipitate increases fibrinogen levels, it comes with an inherent risk of transfusion-lung injury [5]. Another disadvantage of cryoprecipitate is the necessity to thaw products prior to administration to the patient. PCCs, on the other hand, are not frozen and can be given rapidly. While PCCs are currently first-line treatment for warfarin-related intracranial hemorrhage, the potential for benefit is unclear when considering other causes of hemorrhage [6]. The downside to using PCC, is the increased risk of thrombotic events [7]. As an alternative, TXA is an antifibrinolytic that competitively inhibits the activation of plasminogen to plasmin [8]. TXA is a relatively safe alternative with the main adverse reaction being an allergic reaction. TXA has not shown to increase thrombotic events and is relatively quick to administer to the patient as it is readily available in most emergency departments [9]. Intravenous TXA given to patients with intracranial bleeding, not caused by tPA administration, has been shown to decrease hematoma expansion but carries an increased risk of ischemia [10]. Additionally, TXA has been used for recurrent pulmonary hemorrhages in patients with cystic fibrosis with success [11]. Nevertheless, there are no reports in the literature regarding the use of nebulized TXA in patients with tPA induced pulmonary hemorrhage.

tPA administration comes with inherent risks given the known bleeding complications and no consensus for the reversal of bleeding secondary to tPA. TXA may be a viable option in the setting of tPA induced pulmonary hemorrhage.

References

- [1] Impact of stroke (stroke statistics), Stroke Treatment 6 June 2016 www.strokeassociation.org/STROKEORG/AboutStroke/Impact-of-Stroke-Stroke-statistics_UCM_310728_Article.jsp, Accessed date: 13 August 2018.
- [2] Marler J. Tissue plasminogen activator for acute ischemic stroke. *New England Journal of Medicine* 1999;341(16):1240–1.
- [3] "Alteplase." DrugBank. www.drugbank.ca/drugs/DB000009; 12 Aug. 2018, Accessed date: 13 August 2018.
- [4] Kaur Gurmeen. Management of symptomatic post TPA hemorrhage in acute ischemic strokes: an expert consensus guideline. Blogging stroke. American Stroke Association; 27 Dec. 2017 journals.heart.org/bloggingstroke/2017/12/27/management-of-symptomatic-post-tpa-hemorrhage-in-acute-ischemic-strokes-an-expert-consensus-guideline.
- [5] Nascimento B, Goodnough LT, Levy JH. Cryoprecipitate therapy. *Br J Anaesth* 2014; 113:922–34.
- [6] Hemphill JC, et al. Guidelines for the management of spontaneous intracerebral hemorrhage: a guideline for healthcare professionals from the American Heart Association/American Stroke Association. *Stroke* 2015;46:2032–60.
- [7] Felton Diana, et al. Risk of venous thromboembolism after receiving prothrombin complex concentrate for warfarin-associated intracranial hemorrhage. *J Emerg Med* 2016;50(1):1–6.
- [8] National Center for Biotechnology Information. PubChem Compound Database; CID=5526. <https://pubchem.ncbi.nlm.nih.gov/compound/5526>. (accessed Aug. 13, 2018).
- [9] Shakur Haleema, et al. Effects of tranexamic acid on death, vascular occlusive events, and blood transfusion in trauma patients with significant haemorrhage (CRASH-2): a randomised, placebo-controlled trial. *The Lancet* 2010;376(9734):23–32.
- [10] French KF, White J, Hoesch RE. Treatment of intracerebral hemorrhage with tranexamic acid after thrombolysis with tissue plasminogen activator. *Neurocrit Care* 2012;17(1):107–11.
- [11] Graff GR. Treatment of recurrent severe hemoptysis in cystic fibrosis with tranexamic acid. *Respiration* 2001;68(1):91–4.