

Teaching Video NeuroImages: Foix-Chavany-Marie syndrome

William G. Mantyh, MD,* Adithya Chandregowda, PhD,* Jimmy R. Fulgham, MD, Kelly D. Flemming, MD, Ruple S. Laughlin, MD, and David T. Jones, MD

Neurology® 2019;92:e2620-e2621. doi:10.1212/WNL.0000000000007569

Correspondence

Dr. Jones
jones.david@mayo.edu

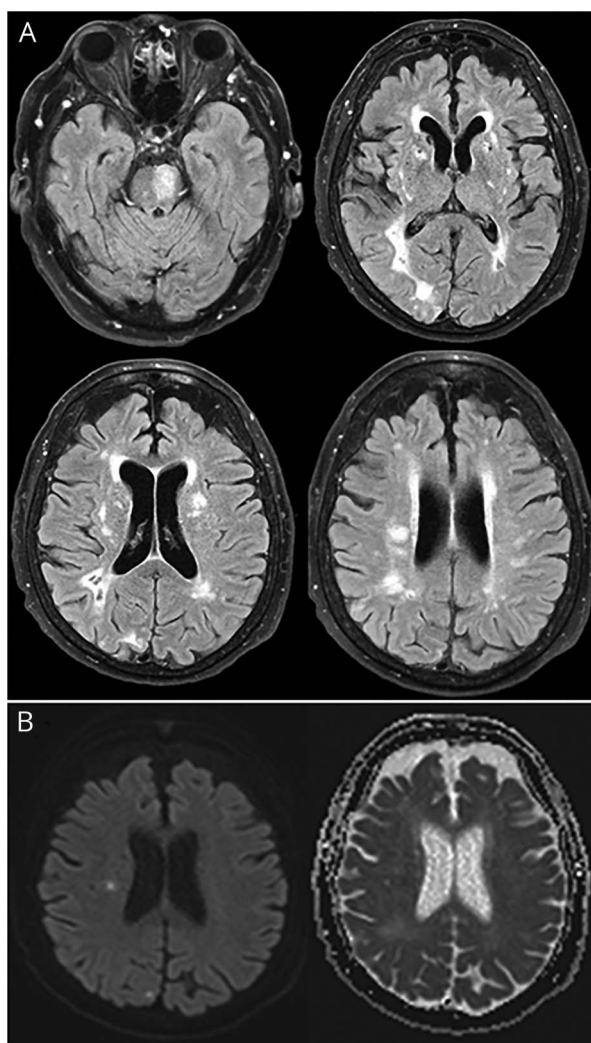
MORE ONLINE

→ **Teaching slides**
links.lww.com/WNL/A901

▶ **Video**

A 75-year-old woman with a history of multiple resolved hemiparetic strokes presented with unilateral ischemic stroke causing sudden loss of volitional control of the musculature crucial for speaking and swallowing. Automatic movements, such as laughter and yawning, were

Figure Neuroimaging of Foix-Marie-Chavany syndrome



(A) T2 fluid-attenuated inversion recovery (FLAIR) MRI demonstrates substantial preexisting ischemic burden, notably in the left pons. (B) Our patient compensated for these previous insults, until a small unilateral stroke of the right corona radiata caused bilateral weakness of the muscles crucial for speaking and swallowing.

*These authors contributed equally to this work.

From the Departments of Neurology (W.G.M., A.C., J.R.F., K.D.F., R.S.L., D.T.J.) and Radiology (D.T.J.), Mayo Clinic, Rochester, MN.

Go to Neurology.org/N for full disclosures. Funding information and disclosures deemed relevant by the authors, if any, are provided at the end of the article.

preserved (video 1 and figure). She was diagnosed with Foix-Chavany-Marie syndrome (FCMS). Lesions of the operculum or its projections to brainstem nuclei can cause FCMS.¹ Because these muscles receive bilateral innervation, a new unilateral lesion can produce sudden bilateral weakness if an old contralateral lesion was compensated by the intact hemisphere. Spontaneous movements, controlled by extra-pyramidal pathways, are preserved.²

Study funding

No targeted funding reported.

Disclosure

The authors report no disclosures relevant to the manuscript. Go to Neurology.org/N for full disclosures.

Appendix Authors

Name	Location	Role	Contribution
William G. Mantyh, MD	Mayo Clinic Rochester, MN	Author	Designed and conceptualized study, analyzed the data, drafted the manuscript for intellectual content
Adithya Chandregowda, PhD	Mayo Clinic Rochester, MN	Author	Designed and conceptualized study, analyzed the data, drafted the manuscript for intellectual content

Appendix *(continued)*

Name	Location	Role	Contribution
Jimmy R. Fulgham, MD	Mayo Clinic Rochester, MN	Author	Interpreted the data, revised the manuscript for intellectual content
Kelly D. Flemming, MD	Mayo Clinic Rochester, MN	Author	Interpreted the data, revised the manuscript for intellectual content
Ruple S. Laughlin, MD	Mayo Clinic Rochester, MN	Author	Interpreted the data, revised the manuscript for intellectual content
David T. Jones, MD	Mayo Clinic Rochester, MN	Author	Analyzed the data, drafted the manuscript for intellectual content

References

1. Weller M. Anterior opercular cortex lesions cause dissociated lower cranial nerve palsies and anarthria but no aphasia: Foix-Chavany-Marie syndrome and "automatic voluntary dissociation" revisited. *J Neurol* 1993;240:199–208.
2. Hopf HC, Muller-Forell W, Hopf NJ. Localization of emotional and volitional facial paresis. *Neurology* 1992;42:1918.