

● Brief Communication

ARTERIOVENOUS MALFORMATIONS—A SUMMARY OF 6 CASES TREATED WITH RADIATION THERAPY

MICHAEL G. POULSEN, F.R.A.C.R.

Radiation Oncologist, Queensland Radium Institute, Royal Brisbane Hospital, Herston, Brisbane 4029 Australia

Six cases of inoperable arteriovenous malformations (AVM) treated with conventional megavoltage radiation therapy are reviewed. One of the six cases had complete angiographic clearance of the AVM. None of the cases have had recurrent bleeding. One has had uncontrolled epilepsy. There were no treatment complications.

Arteriovenous malformations, Radiation therapy.

INTRODUCTION

Arteriovenous malformations (AVM) account for up to 3% of all intracranial masses,⁴ and are the second most common cause of nontraumatic subarachnoid hemorrhage. Management includes surgery, embolization and less commonly, radiation therapy. The purpose of this paper is to review our experience and the world literature on the management of intracranial A.V.M. with radiation therapy.

METHODS AND MATERIALS

Six cases of A.V.M. have been treated over the past 7 years at the Queensland Radium Institute. Table 1 summarizes the clinical details of the six patients. Patients were treated with a 4 MeV linear accelerator. The "treatment volume" was determined from the angiograms and CT scans and was kept as small as possible to limit the volume of normal brain treated. The prescribed minimum tumor dose (MTD) depended to a large degree on the size of the "treatment volume," that is, small volumes could be taken to much higher doses than large volumes. Doses varied between 4500 cGy MTD in 20 fractions over 4 weeks, to 7500 cGy MTD in 20 fractions over 4 weeks. Patients were treated daily, Monday to Friday. Three to 4 fields were used to limit the dose on normal brain. Follow-up visits were carried out predominantly by the neurosurgeon. Repeat angiograms have been completed in 3 out of 6 cases.

RESULTS

Case no. I (B.T.)

This 38-year old male presented in January 1981 with sudden onset of left hemiplegia. His past history had been unremarkable. A CT scan showed a very large haematoma in the right cerebral hemisphere and carotid angiograms revealed an AVM extending deep into the Sylvian fissure in a wedge shaped configuration. The apex of the wedge was in the region of the internal capsule. Surgery was undertaken with the bulk of the AVM being excised and marked with clips. However the deepest part could not be removed. The risk of further bleeding causing disruption of the motor fibres in the posterior limb and genu of the internal capsule was felt significant and therefore high dose small field radiation was recommended. The residual disease was treated to 7500 cGy MTD in 20 fractions over 4 weeks using two lateral field and an anterior and posterior field. The field size was 2.2 × 1.5 cm. There was no significant morbidity from the treatment. Ten months following radiotherapy, the angiography was repeated and this showed complete obliteration of the AVM (Fig. 1) The patient has remained fully mobile with only slight weakness in his left arm and leg.

Case no. II (S.D.)

This 17-year old male presented with sudden onset of right sided headache, left hemiplegia, and decreased conscious state. There was marked neck stiffness and lumbar puncture confirmed blood stained cerebrospinal fluid.

Acknowledgements—I would like to acknowledge Dr. J. Yeland, Dr. J. Smith, Dr. G. Merry, and Dr. G. Stuart who referred the patients to the Queensland Radium Institute and Professor K. Mead who treated them.

Accepted for publication 23 April 1987.

Table 1. Summary of the patients treated

	B.T.	S.D.	B.L.	P.T.	L.R.	J.C.
Age	38	16	12	31	17	30
Presentation	S.A.H.	S.A.H.	S.A.H.	S.A.H.	S.A.H.	S.A.H.
Symptoms	Hemiplegia	Hemiplegia ↓ conscious state	Headache, cranial nerve		Headache, hemiparesis, deeply unconscious	Epilepsy, hemiparesis
Site	Sylvian fissure on right side	Right basal ganglion	Left pons.	Post fossa	Right thalamus	Right frontal lobe
Surgery	Partial removal	No	No	Partial removal	No	No
Dose (cGy)	7500	6000	4500	5000	7000	5000
Fractions	20	20	20	20	30	20
Field no.	4	3	3	3	3	3
Size (cm)	2.5 × 1.6	3.3 × 1.6, 2	4 × 3.5, 4	4 × 4	2 × 2	6 × 7
Disease-free survival	3 years	3 years	6 years	6 years	17 months	39 months + deteriorating
Overall survival	3 yrs + alive	3 yrs + alive	6 yrs + alive	6 yrs + alive	17 months, alive LTFU	39 months, alive
CR on angiogram	Yes	No	No	No	No	No
Recurrent bleeding	No	No	No	No	No	No
Uncontrolled epilepsy	No	No	No	No	No	Yes
Recovery	Good, fully mobile	Good, mobile	Good, mobile	No neurological deficit	Not known	No

CR: Complete regression; LTFU: Lost to follow-up.

Initial management consisted of IV dexamethasone and Ecaprol. A CT scan showed a deep right hemisphere intracerebral hematoma in the region of the right basal ganglion. There was some midline shift to the left and early hydrocephalus. Angiograms showed a deep AVM fed by the lenticulostriate artery involving the caudate nucleus and the thalamus. Mass effect had displaced the anterior cerebral vessels to the left. The lesion was considered inoperable and irradiation was recommended. 5500 cGy MTD was delivered in 20 fractions over 4 weeks using 2 lateral fields and a vertical field. Field size measured 3.3 × 1.6 cm. A further 500 cGy dose was given to a smaller volume 2 cm in diameter to cover the feeding vessels. Treatment was well tolerated and he continued to regain his strength throughout his radiotherapy. At 2 months, there was no neurological deficit apart from some difficulty in carrying out fine rapid movements of his left hand. Repeat angiograms at this stage showed the AVM had reduced slightly in size. Angiograms 12 months post treatment showed no further change. At 3 years post treatment he has had no further bleeding.

Case no. III (B.L.)

This 12-year old aboriginal boy presented in April 1979 with an 8 day history of headache, diplopia, and unsteadiness of his gait. Physical findings were of a left 7th nerve palsy, right 10th nerve palsy, left 6th nerve palsy, right and left medial rectus palsy, voluntary ptosis,

incoordination of both eyes and a positive Kernigs sign. CT scan showed an irregular enhancing mass with calcification in the left pons and extending into and encroaching on the 4th ventricle. Angiograms revealed an inoperable AVM in the left pons. Radiotherapy was recommended and the patient received 4500 cGy in 20 fractions over 4 weeks using two lateral fields and a vertical field. The field size measured 4 × 3.5 cm. Nine months post treatment, he was walking well with good coordination. Angiograms were repeated 5 months post treatment and this showed little change in the size of the AVM.

Case no. IV (P.T.)

This 31-year old male presented with a subarachnoid hemorrhage in May 1979. Arteriograms revealed an AVM in the posterior fossa. The fossa was explored and the tumor partly removed. Post-operative radiotherapy was given to the area of residual disease, receiving a dose of 5000 cGy in 20 fractions over 4 weeks using 2 lateral fields and a posterior field. The field size measured 4 × 4 cm. Six years post treatment he is well with no neurological deficit. Angiograms have not been repeated.

Case no. V (L.R.)

This 17-year old boy presented in May 1982 with a 24 hr history of headache and vomiting followed by an epileptic fit. On admission he was deeply unconscious with extensor spasm and left hemiparesis. A grade IV

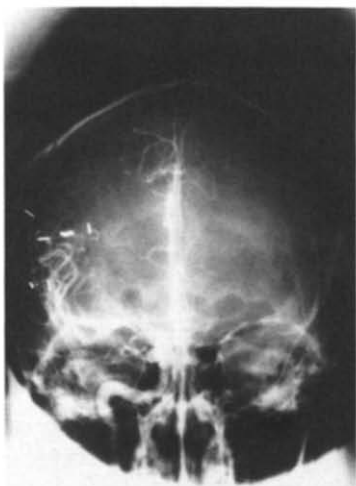
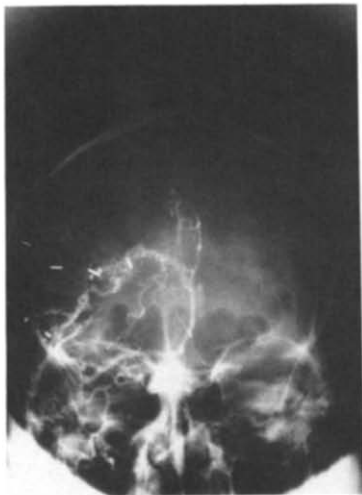
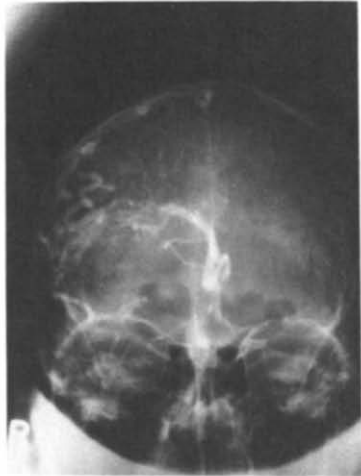


Fig. 1. (A) Angiogram of Case Number 1 at presentation; (B) Angiogram of Case Number 1 following surgery showing residual AVM medial to the clips; (C) Angiogram of Case Number 1 following surgery and radiation showing complete regression of the AVM.

subarachnoid hemorrhage was diagnosed. Angiograms showed an AVM in the region of the right thalamus. It was considered inoperable and radiation was recommended. The lesion was treated to 5000 cGy MTD in 20 fractions over 4 weeks using 3.5 cm diameter fields. A further boost of 2000 cGy in 10 fractions was given through a 2 cm diameter field to the feeding vessels. He tolerated treatment well. Seventeen months following his radiation treatment he was readmitted with headache. Repeat CT scan showed the AVM to be essentially unchanged. Angiograms have not been repeated.

Case no. VI (J.C.)

This 30-year old male presented in July 1982 with right sided focal fitting, headache, and right hemiparesis. The fits had been present for 10 years. Angiograms showed a large AVM on the medial surface of the left frontal lobe extending deeply into the cerebrum. It was supplied by both anterior cerebral arteries and the left posterior cerebral artery. The lesion was inoperable and radiation therapy was recommended. He received a dose of 5000 cGy in 20 fractions over 4 weeks through two lateral fields measuring 6×7 cm and a vertical field measuring 6×4 cm. His general health remained stable until September 1985 when his epilepsy became increasingly difficult to control. Results of repeat angiograms are not yet available, but it is considered that radiation treatment has failed to control his disease.

One of the six cases treated has had complete angiographic clearance of the AVM. Two others have had repeat angiograms which showed little change but one of these was done only 5 months post treatment and this may have been too early to detect response. Three other cases had follow up C.T. which showed persistent A.V.M. (Table 1). There have been no cases of repeat bleeding and the minimum follow-up period is 17 months. One patient has had uncontrolled epilepsy. There have been no radiation induced complications.

DISCUSSION

Surgery is the traditional treatment for A.V.M. Twenty-five years ago this was associated with a mortality of 9% and a morbidity of 9%.¹¹ This led to consideration of a non-surgical treatment. These included embolization by pellets and tissue adhesives,^{10,14} cryotherapy,¹⁷ stereotactic radiosurgery,⁹ proton beam therapy,⁸ and external beam radiotherapy and simple observation or conservative treatment.¹

To treat or not to treat

There has been considerable debate in the literature whether to treat surgically or conservatively (i.e. no intervention). Olivecrona and Riives¹² favor surgical treatment (mortality 9%) over conservative treatment. In the Co-operative Study by Perrett and Nishioka,¹³ radical removal was performed in 139 cases with a mortality of

12% and conservative treatment or palliative surgery was performed in 368 cases with a mortality of 20%. In another series with conservative treatment the annual mortality rate from conservative treatment varied from 1.3 to 1.6 percent per annum.⁸ One hundred and three cases in the co-operative study had conservative treatment and 5% died of hemorrhage or its sequelae and 71 were known to be alive at the end of the study. In the Guidetti and Delitala series,⁵ those 95 patients receiving surgery had a postoperative mortality of 6.3% and none of those successfully treated had a rebleed. However, 50 cases were treated conservatively and this group had a mortality of 20% and 17 patients developed a new hemorrhage. Current surgical mortality figures have improved because of improved neurosurgical techniques and anesthesia; now the mortality is approximately 5%.¹⁸ In other series, better results have been obtained in those treated conservatively.^{1,15} It is impossible to draw definite conclusions regarding the preferred method of management as criteria for selection of treatment vary widely from series to series. It would seem, however, justified to offer a patient with inoperable A.V.M. an alternative treatment, given that conservative treatment carries a mortality of the order of 20%.

The role of conventional radiotherapy

Most reports using conventional radiation have been anecdotal, and have not had angiographic follow-up; in some the details of radiation are not given.¹³ In 1928, Cushing and Bailly³ remarked on the poor results with radiotherapy and later Olivecrona and Ladenhim¹¹ confirmed those impressions.

Nevertheless, isolated well-documented reports of regression of A.V.M. following external beam radiotherapy have appeared in the literature.^{3,16} The only large survey using conventional radiation was by Johnson.⁷ He reviewed Manchester's experience over a 20-year period where 100 cases were treated using doses of 4000–5000 cGy in 3 weeks with megavoltage radiotherapy. Only 20 cases had angiographic follow-up. Nine cases have been cured, 5 have improved, 5 have shown no change, and 1 has increased in size. There were no complications of treatments.

Non-conventional radiotherapy

Both proton beam⁸ and stereotactic radiosurgery⁹ have been used to treat A.V.M's. These facilities are highly specialized and confined to a small number of radiotherapy facilities throughout the world. Most centers will never have access to such sophisticated equipment but they are worthy of mention. Both series have treated large numbers of patients and have been well followed.

Using a proton beam, Kjellberg from Boston, Massachusetts has treated 74 cases with follow-up ranging from 2 to 16 years. There were two deaths from hemorrhage within the first 12 months. Seventy-five percent of pa-

tients have had no further hemorrhage after treatment. Follow-up angiograms were performed in 62 cases and 20% had complete obliteration of the malformation, 56% had a reduction in size by 50% or more and 13% were unchanged. They concluded that the therapy was a useful technique that was associated with little risk, but there was little protection from rebleeding before 12 months had elapsed.

In Stockholm, a special stereotactic gamma unit using 179 cobalt sources had been developed for radiosurgery. Patients are treated in a single fraction, delivering 5000 to 12500 cGy. Leksell⁹ reported on 204 cases of A.V.M. treated. In a series of 67 patients followed for 2 years where the fields of radiation completely covered the whole malformation, there was total obliteration of the pathological vessels in 85% of cases. Again, there was a long latency of 6 to 18 months before obliteration occurred.

Mechanism of action of radiotherapy

Obliteration of the A.V.M. appears to be secondary to progressive endarteritis and late radiation necrosis. In the series treated with proton beam,⁸ pathological analysis of the lesion was available in three cases (two operatively, one at autopsy). The surgical specimens grossly resembled a ball of twine and the lumens of nearly all the vessels were either totally occluded or greatly reduced in size. The walls were extremely thick and in many of the larger arteries and veins normal vascular layers could not be distinguished. Elastic tissue, endothelial cells, smooth muscle cells, and adventitial fibroblasts appeared to be replaced by homogeneous collagenous material. The brain tissue between thickened vessels contained mainly astrocytic glia cells. One would expect the pathological changes to be identical in those treated with photons.

Spontaneous thrombosis and regression of A.V.M's have been documented in the literature.^{2,6} It is not known how commonly this occurs. This may have accounted for some of the obliterations following radiotherapy, but it is impossible to prove. Perhaps the changes in the vessel wall predisposed thrombosis.

Complications of radiotherapy

The great advantage of radiotherapy over surgery is that radiotherapy has no treatment mortality. However, as the doses required to produce objective benefit are high, there have been some reported neurological sequelae. In Leksell's series,⁹ there were five cases of mild hemiparesis out of the 204 cases treated with radiosurgery. In Kjellberg's series⁸ treated with protons, 66 of the 74 patients were treated without complication. There was a dose volume effect, that is, for a given complication rate, small volumes could be treated to higher doses than large volumes. Data on the complication rate of conventional x-ray therapy is non-existent. One would expect a lower complication rate using conventional fractionated

radiotherapy compared to Leksell and Kjellberg series who treated their patients to high dose in a single fraction. These high doses can only be given without complication if critical areas of normal brain are not included in the high dose volume. If for instance, there is brain tissue within the A.V.M. then this tissue stands a high chance of being necrosed.

CONCLUSIONS

Conventional X ray therapy can result in angiographic resolution of A.V.M's, but this is an uncommon

event (one out of six cases). With a minimum follow-up of 17 months, we have had no cases of recurrent bleeding. One patient has had increasing difficulty in controlling his epilepsy. The treatment is well-tolerated and we have had no radiation induced complications.

Where A.V.M's are inoperable, radiation is a worthwhile modality of treatment, that offers a small chance of complete eradication of A.V.M's and a moderately good chance of preventing recurrent bleeding. Control is better when the A.V.M. is small, as high doses can be delivered.

REFERENCES

1. Anderson, F.M., Korbin, M.: Arteriovenous anomalies of the brain. A review and presentation of 37 cases. *Neurology* **8**: 89-101, 1958.
2. Conforti, P.: Spontaneous disappearance of cerebral arteriovenous angiomas. Case report. *J. Neurosurg.* **34**: 432-437, 1971.
3. Cushing, H., Bailey, P.: *Tumour Arising From the Blood Vessels of the Brain. Angiomatous Malformations and Hemangioblastoma.* Springfield III, Charles C Thomas. 1928, p. 219.
4. Gilroy, J., Stirling Meyer, J.: *Medical Neurology*, 3rd edition. New York, Macmillan. 1979, p. 633.
5. Guidetti, B., Delitala, A.: Intracranial arteriovenous malformations. Conservative and surgical treatment. *J. Neurosurg.* **53**: 149-152, 1980.
6. Hansen, J.H., Sogaard, I.: Spontaneous regression of an extracranial and intracranial arteriovenous malformation. Case report. *J. Neurosurg.* **45**: 338-341, 1976.
7. Johnson, R.T.: Radiotherapy of cerebral angiomas with a note on some problems in diagnosis. In *Cerebral Angiomas Advances in Diagnosis and Therapy*. Pia, H.W., Gleave, J.R.W., Grote, E., Zierski, J. (Eds.). Berlin/Heidelberg, New York, Springer-Verlag. 1979, pp. 256-266.
8. Kjellberg, R.N., Hanamura, T., Davis, K.R., Lyons, R.N., Adams, R.D.: Bragg peak proton beam therapy for arteriovenous malformations of the brain. *New Eng. J. Med.* **309**(5): 269-274, 1983.
9. Leksell, L.: Stereotactic radiosurgery. *J. Neurol. Neurosurg. Psych.* **46**: 797-803, 1983.
10. Lussenhop, A.J., Spence, W.T.: Artificial embolization of cerebral arteries: Report of use in a case of arteriovenous malformation. *JAMA* **172**: 1153-1155, 1960.
11. Olivecrona, H., Ladenhim, J.: *Congenital Arteriovenous Aneurysms of the Carotid and Vertebral Systems.* Berlin, Springer-Verlag, 1957.
12. Olivecrona, H., Riives, J.: Arteriovenous aneurysms of the brain. Their diagnosis and treatment. *Arch. Neurol. Psych.* **59**: 567-602, 1948.
13. Perrett, G., Nisioka, H.: Arteriovenous malformations analysis of 545 cases of cranio-cerebral arteriovenous malformations and fistula reported to the co-operative study. *J. Neurosurg.* **25**: 267-490, 1966.
14. Stein, B.M., Wolpert, S.M.: Surgical and embolic treatment of cerebral arteriovenous malformations. *Surg. Neurol.* **7**: 359-369, 1977.
15. Svien, H.J., McRae, J.A.: Arteriovenous anomalies of the brain. Fate of patients not having definite surgery. *J. Neurosurg.* **23**: 23-28, 1965.
16. Tognetti, F., Andreoli, A., Cuscini, A., Testa, C.: Successful management of an intracranial arteriovenous malformation by conventional radiation. *J. Neurosurg.* **63**: 193-195, 1985.
17. Walder, H.A.: Application of cryotherapy in arteriovenous aneurysms: An experimental and clinical study. *J. Neurol. Neurosurg. Psych.* **34**: 105, 1971.
18. Wilson, C.B., York, C.: Current surgical management of neurologic disease. In *Intracranial Arteriovenous Malformations*, Wilson, C.B., Hoff, J.T. (Eds.). Edinburgh, Churchill Livingstone. 1980, pp. 182-185.