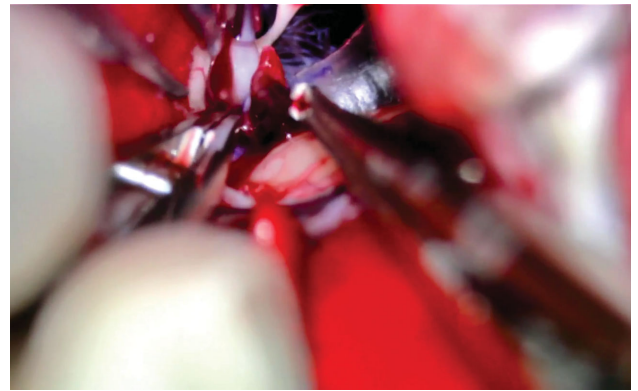


# Successful Emergency Rescue Open Embolectomy for Failed Endovascular Thrombectomy in Acute Ischemic Stroke: 2-Dimensional Operative Video

David Yuen Chung Chan, FRCS , Anderson Chun On Tsang, FRCS, Frederick Chun Pong Tsang, FCSHK, Lai Fung Li, FRCS, Wai Shing Ho, FRCS, LLB, MBA, Wai Man Lui, FRCS, Gilberto Ka Kit Leung, FRCS, MS, PhD, LLM

Division of Neurosurgery, Department of Surgery, Li Ka Shing Faculty of Medicine, The University of Hong Kong, Queen Mary Hospital, Hong Kong

**Correspondence:** Gilberto Ka Kit Leung, FRCS, MS, PhD, LLM, Administrative Block AB701, Division of Neurosurgery, Department of Surgery, Li Ka Shing Faculty of Medicine, The University of Hong Kong, Queen Mary Hospital, 102 Pok Fu Lam Road, Hong Kong. Email: [gilberto@hku.hk](mailto:gilberto@hku.hk)



Watch now at <https://academic.oup.com/ons/advance-article-abstract/doi/10.1093/ons/onz140>

This operative video demonstrates an open surgical thrombectomy for a 61-yr-old woman with failed endovascular embolectomy in acute ischemic stroke. Good functional outcome can be achieved when this operation is timely performed within the therapeutic window. This patient has atrial fibrillation. She was admitted for sudden onset of left-sided hemiplegia and aphasia. National Institutes of Health Stroke Scale (NIHSS) was 20/42 before the operation. Computed tomography (CT) cerebral angiogram showed right internal cerebral artery (ICA) occlusion from the cervical portion. Urgent intra-arterial (IA) thrombectomy was started 2 h after symptom onset, but failed despite the use of a stentriever and a large-bore aspiration catheter together. Emergency rescue open thrombectomy was performed with right pterional craniotomy 6 h after symptom onset. Sylvian fissure was

dissected to expose the supraclinoid ICA, ICA bifurcation, A1, and M1. A transverse arteriotomy was made at the ICA bifurcation and open surgical thrombectomy was performed. Reperfusion was established in 86 min after skin incision. Intraoperative indocyanine green video-angiography showed patent flow over ICA bifurcation to M1 and A1. She had a good recovery with the return of the left-sided power and was discharged home. At 2-mo postoperative assessment, she was able to walk unaided independently. The modified Barthel Index (BI) was 74/100. Her activity of daily living was independent. We must emphasize IA thrombectomy is the standard treatment, and the role of open surgery remains a potential rescue procedure. Good functional outcome can be achieved when emergency rescue open thrombectomy is performed within the therapeutic window.

**KEY WORDS:** Surgical embolectomy, Craniotomy, Large vessels occlusion, Rescue, Stroke

*Operative Neurosurgery* 0:1–2, 2019

DOI:10.1093/ons/onz140

Received, September 27, 2018. Accepted, February 27, 2019.

## Disclosures

The authors have no personal, financial, or institutional interest in any of the drugs, materials, or devices described in this article.

## Acknowledgments

We thank Dr Amelia Ng, Department of Anesthesia and Intensive Care, Prince of Wales Hospital, for her contribution in the audio narration for this

operative video. We also thank the Residents of Neurosurgery, Neurology and Interventional Radiology at the University of Hong Kong, Queen Mary Hospital, for their contribution in patient care and acquisition of data.

## COMMENTS

**T**he authors present an excellent case with successful acute thrombectomy through open craniotomy after failure of

endovascular approach. Recently, mechanical thrombectomy is popular and is changing the guidelines of acute stroke. Novel advanced procedures are launched every day. In my experience, successful recanalization by an endovascular route can be reached in over 90% of cases. In spite of the fact that the thrombectomy through craniotomy is not innovative and optimal, it is still an alternative choice. This article encourages neurosurgeons to participate into the field of ischemic stroke and extends the surgical indication (not only to wait for decompressive craniectomy).

**Ching-Chang Chen**  
*Taoyun, Taiwan*

**P**ercutaneous mechanical thrombectomy has been proven as the best treatment for emergency large intracranial arterial vessel occlusion to minimize injuries from ischemic cerebral infarct and to enhance long-term neurological outcome. The clinical benefits may be applicable to selected patients presenting ischemic neurological symptoms up to 24 hours from “last known normal.” Despite tremendous advances in technology and techniques, technical failures can occur infrequently.

There is ongoing debate and research into best practices in such challenging circumstances.

In this interesting video presentation, the authors described a successful microsurgical middle cerebral artery/internal carotid artery embolectomy facing endovascular failure. The surgical principles are well demonstrated. Obviously, time is of the essence. With the combination of early decision of surgical intervention, rapid response of the surgical team, superb skills, and probably very good collaterals of this patient, successful recanalization was achieved in time for an excellent outcome.

The authors should be commended for their perseverance and eventual accomplishment of a successful rescue. However, such a case is extraordinarily rare in today’s mechanical thrombectomy era. Almost all thrombectomy failures today are the results of some local vessel pathology, usually baseline atherosclerotic stenosis. Theoretically, open embolectomy via craniotomy may be a rescue maneuver for refractory emergent large vessel occlusion. However, its role may become largely historical as endovascular technology continue to advance.

**Y. Jonathan Zhang**  
*Houston, Texas*