



## Mirror Distal Anterior Cerebral Artery Aneurysms in a Patient with Subarachnoid Hemorrhage

Christoph Schwartz<sup>1,3</sup>, Behnam Rezai Jahromi<sup>1</sup>, Ahmad Hafez<sup>1</sup>, Jussi Numminen<sup>2</sup>, Martin Lehecka<sup>1</sup>, Mika Niemelä<sup>1</sup>

### Key words

- Coil embolization
- Distal anterior cerebral artery aneurysms
- Endovascular treatment
- Intracerebral hemorrhage
- Mirror aneurysms
- Outcome
- Subarachnoid hemorrhage

### Abbreviations and Acronyms

**CT:** Computed tomography

**DACAA:** Distal anterior cerebral artery aneurysm

**ICH:** Intracerebral hemorrhage

**SAH:** Subarachnoid hemorrhage

**WFNS:** World Federation of Neurological Surgeons

From the Departments of <sup>1</sup>Neurosurgery and <sup>2</sup>Neuroradiology, Helsinki University Hospital, University of Helsinki, Finland; and <sup>3</sup>Department of Neurosurgery, University Hospital Salzburg, Paracelsus Medical University, Salzburg, Austria

To whom correspondence should be addressed: Christoph Schwartz, M.D.

[E-mail: ext-christoph.schwartz@hus.fi]

Citation: *World Neurosurg.* (2019) 129:101-104.  
<https://doi.org/10.1016/j.wneu.2019.05.259>

Journal homepage: [www.journals.elsevier.com/world-neurosurgery](http://www.journals.elsevier.com/world-neurosurgery)

Available online: [www.sciencedirect.com](http://www.sciencedirect.com)

1878-8750/\$ - see front matter © 2019 Elsevier Inc. All rights reserved.

### INTRODUCTION

Distal anterior cerebral artery aneurysms (DACAAs) are a rare entity; only approximately 5% of all intracranial aneurysms are found in this specific region.<sup>1,2</sup> It has been estimated that 27%–44% of patients with a DACAA harbor multiple intracranial aneurysms, which is higher than for aneurysms in other locations, and 4% of patients have been found to have mirror DACAAs.<sup>2-5</sup> In patients with acute subarachnoid hemorrhage (SAH), this can sometimes prove to be a problem, as the source of bleeding may not be definitely identifiable in those cases. This can be especially problematic in patients in whom occlusion of all aneurysms is not feasible by a single treatment modality or within a single treatment session. We present a rare case of a patient

■ **BACKGROUND:** Mirror distal anterior cerebral artery aneurysms (DACAAs) are a rare finding in patients with subarachnoid hemorrhage, with only a few cases reported.

■ **CASE DESCRIPTION:** A 40-year-old man was admitted for sudden-onset headache, nausea and vomiting, and transient right arm hypoesthesia. Computed tomography scan showed a subarachnoid hemorrhage with intracerebral hemorrhage within the interhemispheric fissure, but computed tomography angiography failed to identify any aneurysms. Subsequent digital subtraction angiography with three-dimensional reconstructions revealed 1.5-mm-diameter mirror DACAAs on the A3 segments. However, the definite rupture site remained unidentifiable. After interdisciplinary consultation, endovascular treatment was favored, and complete occlusion of both DACAAs was achieved by coiling without stent placement. During coiling of the right DACAA, a thrombus in the right callosomarginal artery formed, and treatment with abciximab (ReoPro) was initiated to dissolve the thrombus. After treatment, the patient presented with right leg paresis; however, computed tomography did not show any ischemia, intracerebral hemorrhage increase, or vasospasm. Over the following days, the leg paresis improved, and the patient achieved increased mobilization. He was transferred for further rehabilitation 16 days after hemorrhage. The leg paresis had recovered to a grade 3/5.

■ **CONCLUSIONS:** Rapid identification of the rupture site in patients with subarachnoid hemorrhage and multiple aneurysms is crucial for initiating optimal treatment. In patients with mirror aneurysms in close proximity to each other, this is not easily accomplished, complicating treatment decisions. Although clipping has been the standard for DACAA occlusion, coiling should be taken into consideration as a viable alternative.

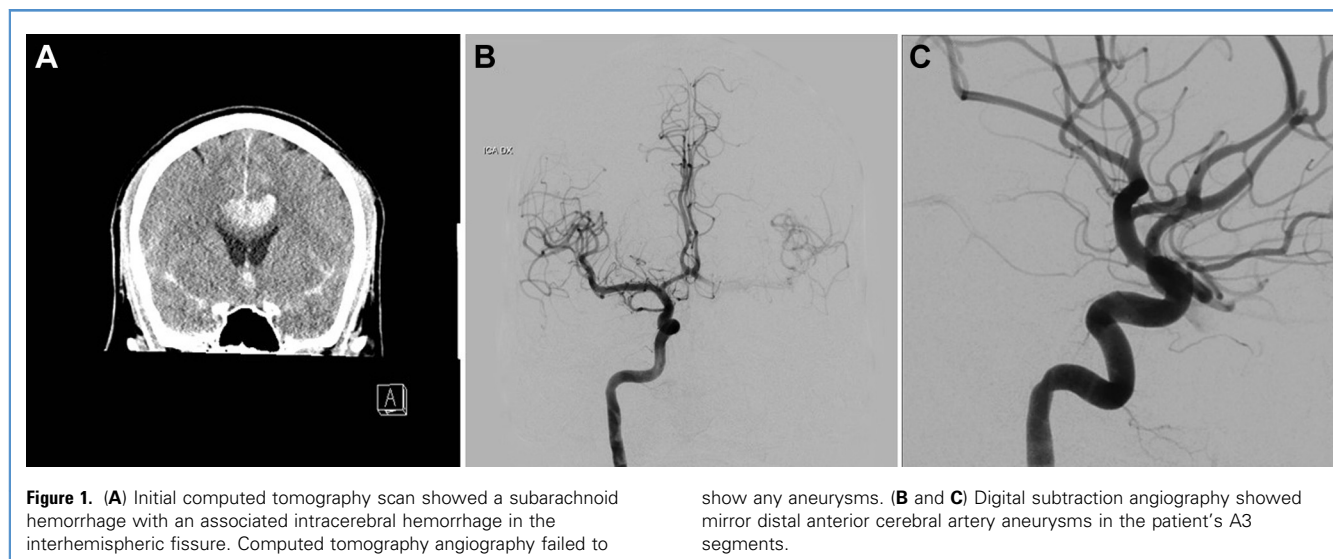
with mirror DACAAs who experienced an SAH with associated intracranial hemorrhage (ICH). We provide a detailed description of the patient's signs and symptoms as well as radiologic findings and discuss treatment considerations and the course of treatment.

### CASE DESCRIPTION

#### Patient Presentation and Imaging

A 40-year-old male nonsmoker presented to the emergency department with sudden-onset headache, nausea and vomiting, and transient hypoesthesia of the right upper extremity. On initial examination, the patient's Glasgow Coma Scale score was 15,

and no focal neurologic deficit was recorded. Cranial computed tomography (CT) and CT angiography were immediately performed and showed an SAH, which clinically corresponded to a World Federation of Neurological Surgeons (WFNS) grade I, and an interhemispheric ICH; however, no aneurysms could be detected on CT angiography (Figure 1A). We next performed digital subtraction angiography, which showed small, bilateral mirror DACAAs located on the A3 segments with a maximum diameter of 1.5 mm each (Figures 1A, B, 2A and B). The exact rupture site, however, remained unidentifiable. No other intracranial aneurysms or vascular anomalies were found.



### Aneurysm Occlusion

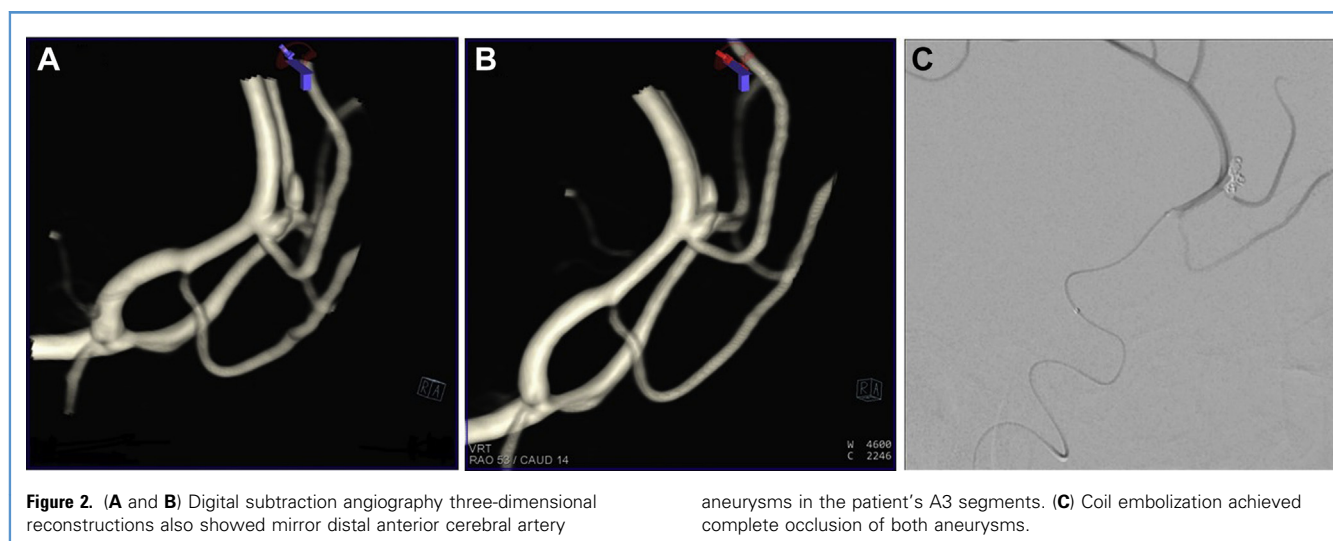
We decided to proceed with endovascular treatment of the mirror DACAAs. The right-sided aneurysm was occluded first by coil embolization, followed by coiling of the left aneurysm; no stenting of the aneurysm necks was required. During the coiling procedure of the right-sided aneurysm, a thrombosis of the callosomarginal artery was detected, and treatment with abciximab (ReoPro) was initiated, immediately dissolving the thrombus. At the end of the procedure, complete occlusion of both aneurysms (Raymond-Roy Occlusion Classification class I) was recorded (Figure 2C).

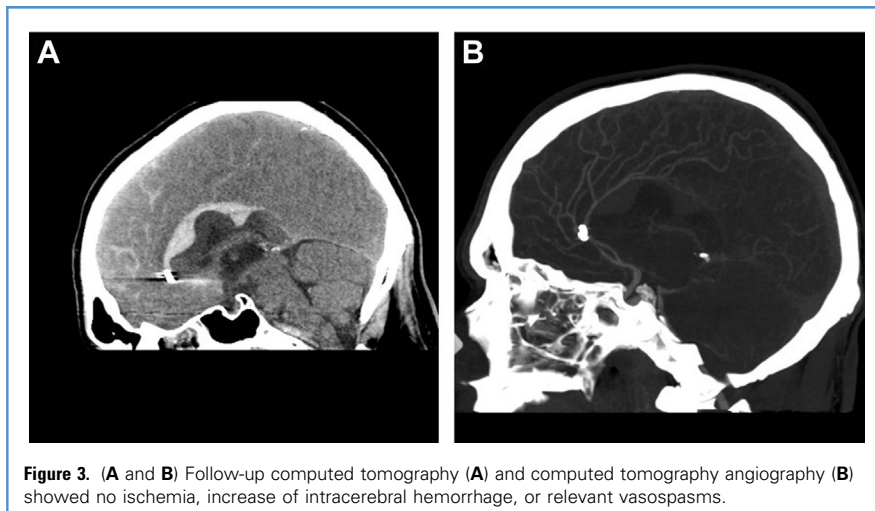
Endovascular treatment was initially favored over clipping because the space-occupying effect of the ICH was limited, and the patient showed no neurologic deficit on admission.

### Postinterventional Course and Outcome

After aneurysm occlusion, the patient was transferred to the neurosurgical intensive care unit, and intravenous abciximab treatment was continued for 12 hours. The patient's sedation was slowly reduced after the procedure, and he could be extubated approximately 1.5 hours after aneurysm conclusion. According to our in-house protocol for vasospasm

prophylaxis, we started with oral nimodipine (60 mg daily 6×) treatment. On neurologic evaluation after extubation, the patient presented with paralysis of the right leg without any other new deficits. A CT scan showed no increase of ICH, no ischemia, and only minimal enlargement of the ventricular temporal horns. Over the next hours and days, the patient's leg paresis slowly but consistently started to improve. On day 6 after the SAH, however, the patient showed fluctuating deterioration of the leg paresis, clinically suspicious of vasospasm. CT and CT angiography were performed, which failed to detect any relevant vasospasm or





**Figure 3.** (A and B) Follow-up computed tomography (A) and computed tomography angiography (B) showed no ischemia, increase of intracerebral hemorrhage, or relevant vasospasms.

ischemia (Figure 3A and B). The nimodipine medication was changed to intravenous administration (2 mg per hour), and strict blood pressure management (i.e., systolic blood pressure >170 mm Hg) was initiated. Over the following days, the patient's condition stabilized, and the leg paresis then showed consistent improvement. The patient was transferred to the regular ward, where intensive physiotherapy was conducted. At day 16, the patient was transferred to the rehabilitation unit; he was able to walk with help, and the leg paresis had improved to grade 3/5. Nimodipine was continued until day 21. Follow-up digital subtraction angiography was scheduled to be performed in 6 months.

### DISCUSSION

Although DAACAs have been found to be associated with other aneurysms, it is rare that a patient will have mirror aneurysms in this distinct location, and only a few similar cases have been reported in detail (Table 1).<sup>6-9</sup> Our case had several challenges with regard to deciding on the patient's optimal course of treatment that warrant further discussion. On one hand, the patient had mirror DACAs, which were in very close proximity to each other. Thus, it was not possible for us to identify the source of hemorrhage. On the other hand, treatment decisions were further complicated by an associated ICH.

The correct identification of the rupture site and hemorrhaged aneurysm in a patient with multiple aneurysms is of utmost

importance to initiate optimal treatment and achieve swift aneurysm occlusion. The most indicative findings for the most likely ruptured aneurysm are the distribution of blood within the subarachnoid space/cistern as well as the location of an associated ICH, if present. As seen in our case, these parameters may prove difficult to interpret if the aneurysms are located in close proximity to each other. Other factors, which may be used as indicators in this regard, are aneurysm size and volume, angioarchitecture, and multilobulated morphology. In patients with multiple intracranial aneurysms, larger size (>7 mm) and irregular, complex morphology were found to be the strongest predictors for aneurysm rupture.<sup>10</sup> Digital subtraction angiography may provide more detailed depiction of the aneurysm anatomy than CT angiography and help with treatment planning. In our patient, however, neither CT angiography nor digital subtraction angiography were able to identify the ruptured aneurysm. In such a case, all aneurysms requiring treatment ought to be occluded in one sitting, if feasible, as performed in our patient.

Microsurgical clipping and endovascular coiling provide specific risk/benefit profiles, and their respective advantages and disadvantages should be carefully counterbalanced against each other. One major advantage of microsurgical clipping is that removal of an associated ICH within the interhemispheric fissure may be additionally performed. It is important to note that DACAs tend to bleed into the adjacent brain parenchyma in case of

**Table 1.** Prior Case Reports of Mirror Distal Anterior Cerebral Artery Aneurysms

Reference	Patients	Other Vascular Anomaly	SAH/WFNS Grade	ICH	Symptoms	Treatment	Rupture Site Identified	Outcome and Complications
Mizunari et al., 2011 <sup>6</sup>	1	None	Yes/WFNS II	Yes	Headache	Clipping 2×	NA	Long-lasting vasospasm, but no new deficit
Mori et al., 1995 <sup>7</sup>	1	None	Yes/WFNS I	No	Headache	Clipping 2×	Yes	No new deficit
Singh et al., 2018 <sup>8</sup>	1	None	Yes/WFNS IV	Yes	Headache, initial LOC	Clipping 2×	Yes	New hemiparesis
Sousa et al., 2002 <sup>9</sup>	2	PCOM aneurysm; none	Yes/WFNS II; yes/WFNS V	Yes; yes	Headache; headache	Clipping 2×; clipping 2×	Yes; yes	Transient paraparesis but no permanent new deficit; death

ICH, intracerebral hemorrhage; NA, not available; LOC, loss of consciousness; PCOM, posterior communicating artery; SAH, subarachnoid hemorrhage; WFNS, World Federation of Neurological Surgeons.

rupture and consecutive SAH, and 28%–53% of patients will experience an associated ICH.<sup>2,11,12</sup> Most commonly, ICH will affect the frontal lobes, the corpus callosum, or the cingulate gyrus, thereby causing typical clinical symptoms, such as cognitive deficits, akinetic mutism, and unilateral or bilateral leg paresis, as seen in our patient.<sup>13–15</sup> Reasons for the high incidence of an associated ICH may be the small volume/space within the interhemispheric cistern and the close proximity of the aneurysm sac to the adjacent brain tissue. Prior data have shown that although an associated ICH was found to be predictive for unfavorable outcome in patients with ruptured DACAAAs, patients with ICH did show relatively good overall clinical status.<sup>2</sup> Removal of the hematoma might lead to faster recovery of the patient and remission of associated neurologic symptoms caused by space-occupying blood clots. Moreover, it may also reduce the risk of secondary vasospasm.<sup>8</sup> In most cases, both distal anterior cerebral arteries and associated aneurysms can readily be accessed by a unilateral interhemispheric approach; if need be, the lower part of the falx can additionally be resected to gain further exposure. Nonetheless, clipping of DACAAAs poses specific challenges to the surgeon owing to their often deep interhemispheric locations and overall lack of space during aneurysm dissection. Furthermore, great attention must be given to preservation of all larger bridging veins to avoid secondary venous infarctions, and retraction of the often edematous and vulnerable brain parenchyma, especially in patients with SAH, should be kept to a minimum. From our experience, neuronavigation can be of great help to plan the craniotomy and the optimal trajectory to the aneurysm. Having said that, endovascular treatment may prove difficult due to the small parent artery, often broad-necked aneurysms, and distal location.

We believe that in this specific case an attempt of ICH removal during clipping might have been associated with considerable risk for the following reasons: 1) The hematoma extended far posteriorly along the corpus callosum (Figure 3A), and only the anterior part could have been easily

removed during the clipping procedure; 2) the interhemispheric fissure provides only limited space, and extensive manipulation, especially in patients with SAH, might cause additional neurologic damage; and 3) the space-occupying effect of the ICH was judged as only moderate. Moreover, as complete occlusion of both DACAAAs was deemed achievable by the neurointerventionalists, it was not regarded as an absolute necessity to determine which one of the DACAAAs had actually ruptured, which again could have been more likely determined by microsurgical clipping of the aneurysms. Our patient eventually showed good improvement of neurologic status, and follow-up imaging showed no increase of the hematoma or ischemia, thus affirming our initial treatment decisions.

## CONCLUSIONS

Only a few patients with SAH and mirror DACAAAs have been reported so far, and optimal treatment remains challenging. In our patient, owing to the close proximity of the aneurysms to each other, the rupture site could not be definitely identified. Furthermore, the associated ICH, a common feature of ruptured DACAAAs, further complicated treatment decisions. For all complex aneurysm cases, interdisciplinary discussion of treatment options should occur, and the optimal treatment should be agreed on. Although microsurgical clipping has been the gold standard for DACAA occlusion, treatment of these aneurysms is also feasible by current endovascular techniques. Thus, endovascular treatment constitutes a viable treatment alternative and should also be taken into consideration.

## REFERENCES

1. de Sousa AA, Dantas FL, de Cardoso GT, Costa BS. Distal anterior cerebral artery aneurysms. *Surg Neurol.* 1999;52:128-135 [discussion: 135-136].
2. Lehecka M, Lehto H, Niemelä M, et al. Distal anterior cerebral artery aneurysms: treatment and outcome analysis of 501 patients. *Neurosurgery.* 2008;62:590-601 [discussion: 590-601].
3. Dashti R, Hernesniemi J, Niemelä M, et al. Microneurosurgical management of middle cerebral artery bifurcation aneurysms. *Surg Neurol.* 2007;67:441-456.

4. Ellamushi HE, Grieve JP, Jäger HR, Kitchen ND. Risk factors for the formation of multiple intracranial aneurysms. *J Neurosurg.* 2001;94:728-732.
5. Inagawa T. Multiple intracranial aneurysms in elderly patients. *Acta Neurochir (Wien).* 1990;106:119-126.
6. Mizunari T, Murai Y, Kobayashi S, Sakai N, Teramoto A. Long-lasting narrowing of the parent artery after bilateral clipping of mirror-image aneurysms of distal anterior cerebral arteries: a case report. *J Nippon Med Sch.* 2011;78:178-183.
7. Mori T, Fujimoto M, Shimada K, Shin H, Sakakibara T, Yamaki T. Kissing aneurysms of distal anterior cerebral arteries demonstrated by magnetic resonance angiography. *Surg Neurol.* 1995;43:497-499.
8. Singh SK, Jain K, Jain VK, Saroha A. Mirror image of bilateral DACA aneurysm with its successful surgical management. *Surg Neurol Int.* 2018;9:80.
9. Sousa J, Iyer V, Roberts G. 'Mirror image' distal anterior cerebral artery aneurysms. A case report of two patients with review of literature. *Acta Neurochir (Wien).* 2002;144:933-935 [discussion: 935].
10. Bhogal P, AlMatter M, Hellstern V, et al. Difference in aneurysm characteristics between ruptured and unruptured aneurysms in patients with multiple intracranial aneurysms. *Surg Neurol Int.* 2018;9:1.
11. Steven DA, Lownie SP, Ferguson GG. Aneurysms of the distal anterior cerebral artery: results in 59 consecutively managed patients. *Neurosurgery.* 2007;60:227-233 [discussion: 234].
12. Proust F, Toussaint P, Hannequin D, Rabenoïna C, Le Gars D, Fréger P. Outcome in 43 patients with distal anterior cerebral artery aneurysms. *Stroke.* 1997;28:2405-2409.
13. Choudhari KA. Subarachnoid haemorrhage and akinetic mutism. *Br J Neurosurg.* 2004;18:253-258.
14. Endo H, Shimizu H, Tominaga T. Paraparesis associated with ruptured anterior cerebral artery territory aneurysms. *Surg Neurol.* 2005;64:135-139 [discussion: 139].
15. Greene KA, Marciano FF, Dickman CA, et al. Anterior communicating artery aneurysm paraparesis syndrome: clinical manifestations and pathologic correlates. *Neurology.* 1995;45:45-50.

*Conflict of interest statement:* The authors declare that the article content was composed in the absence of any commercial or financial relationships that could be construed as a potential conflict of interest.

Received 23 April 2019; accepted 30 May 2019

Citation: *World Neurosurg.* (2019) 129:101-104.  
<https://doi.org/10.1016/j.wneu.2019.05.259>

Journal homepage: [www.journals.elsevier.com/world-neurosurgery](http://www.journals.elsevier.com/world-neurosurgery)

Available online: [www.sciencedirect.com](http://www.sciencedirect.com)

1878-8750/\$ - see front matter © 2019 Elsevier Inc. All rights reserved.