



# The dynamic nature of the sense of ownership after brain injury. Clues from asomatognosia and somatoparaphrenia

Daniele Romano<sup>a,b,\*</sup>, Angelo Maravita<sup>a,b</sup>

<sup>a</sup> Department of Psychology, Università degli Studi di Milano-Bicocca, Milan, Italy

<sup>b</sup> NeuroMi – Milan Center for Neuroscience, Università degli Studi di Milano-Bicocca, Milan, Italy

## ARTICLE INFO

### Keywords:

Body ownership  
Body representation  
Body schema  
Right brain damage  
Somatoparaphrenia  
Body awareness

## ABSTRACT

The sense of ownership is the feeling that a body part belongs to ourselves. Brain damage may disrupt this feeling, leading to somatoparaphrenia (SP), i.e., the delusion that one's limbs belong to someone else. This delusional feeling is typically associated with profound motor and somatosensory deficits.

We reviewed the cases of SP reported so far in the literature outlining the clinical and neuroanatomical profile of SP. We then investigated and reported three new peculiar cases of SP that allow new insights into the theoretical framework of this neuropsychological condition. We thus propose an innovative theoretical account that integrates previous evidence and the new cases described. We suggest that a defective update of the ongoing dynamic representation of the body finalised to perception and action, may be the key for the disownership feelings of patients with SP. The erroneous spatial representation of the limb contralateral to the lesion would have the logical consequence of delusional misattribution of the seen own arm.

## 1. Introduction

Our body, the object we know the best (de Vignemont, 2011), holds very complex and dedicated representations in the brain, being a unique reference for sensory-motor experiences (Berlucchi & Aglioti 1997, 2010).

The feeling that a given body part belongs to ourselves is a fundamental aspect of the neural representation of the body: this is typically defined as the *sense of ownership* and is an implicit, essential, determinant of any current sensory or motor event (Romano et al., 2015b). Brain damage may dramatically disrupt body ownership, leading to a number of symptoms, among which the most striking is somatoparaphrenia (de Vignemont, 2011). Somatoparaphrenia (SP) is a neuropsychological condition characterised by delusional feelings about the patient's own body (Gerstmann, 1942; Giuseppe Vallar and Ronchi, 2009; Feinberg and Venneri, 2014).

SP is rather uncommon, typically observed in the acute post-ictal phase and characterised by the illusory sense of disownership of the patient's contralesional limbs. Crucially, in SP, the denied limbs are attributed to other individuals that are typically around the patient during the examination – e.g., caregivers and relatives (Gandola et al., 2012; Invernizzi et al., 2013; Feinberg et al., 2010). Sometimes the ownership misattribution involves someone who is not, or could not possibly be currently present (Pugnaghi et al., 2011; Bottini et al.,

2002). The presence of a ownership misattribution is a key element distinguishing SP from asomatognosia, a different impairment of sense of ownership that is characterised by the failure of having a continuous sensation, feeling or judgment that one's body part (typically the impaired limb) belongs to the patient (Jenkinson et al., 2018). In other words, SP features dense sense of disownership toward the impaired limb (asomatognosia), coupled with delusional attribution of that limb to someone else.

The neurological and cognitive processes impaired in SP are still to be further clarified. As far as the associated neurological symptoms, it is clear that isolated hemiplegia or hemianesthesia cannot fully account for the presence of SP, given that most patients affected by profound sensory and motor deficits are not somatoparaphrenic. However, the impact of each of these neurological symptoms on SP needs further investigation. As far as the cognitive mechanisms, on one side SP has been attributed to a disruption of the conscious and stable features of the body representation. Those features are responsible for the explicit attribution of limb ownership, the so-called body image, likely favoured by severe motor and proprioceptive deficits (Daprati et al., 2010; Geschwind, 1965). On the other side, it was recently proposed that spatial and dynamic aspects of body representation, the so-called body schema, may have a crucial impact in the occurrence of SP (Romano et al., 2014; Salvato et al., 2016; Vallar and Ronchi, 2009).

In the present paper, we first provide a comprehensive and critical

\* Corresponding author. piazza Ateneo Nuovo, 1, 20126, Milano. Italy.

E-mail addresses: [daniele.romano@unimib.it](mailto:daniele.romano@unimib.it) (D. Romano), [angelo.maravita@unimib.it](mailto:angelo.maravita@unimib.it) (A. Maravita).

review of published cases of SP ( $N = 130$ ). A key aspect is the focus on the association of SP with other neurological deficits and on the dynamic relation of delusional feelings of the patients to the space around them. This particular view of SP suggests considering such a striking phenomenon in a dynamic body-space relation. This theoretical framework seems to be supported by the investigation of three particular cases of SP, which are reported for the first time in this paper. We thus propose a novel theoretical framework for understanding SP in light of previous theories and the new cases.

Specific case descriptions of SP can be tracked back at the end of XIX Century (see Anton 1893 reported in Vallar and Ronchi, 2009), but systematic investigations of altered body representation and their putative neurological underpinnings have been reported in the seminal work by Head and Holmes in 1911, where the concept of body schema was formally introduced. With Gerstmann (1942) and his first definition of SP, the new fundamental question about the neurological nature of the sense of body ownership was raised, becoming a central issue of neuropsychology and cognitive neuroscience (Critchley, 1953; Vallar and Coslett, 2018).

Although SP is a rare condition, its potential contribution to the understanding of the physiological and pathological sense of ownership is undoubted. In the present section of the paper, we provide an operative definition of SP that allows identifying a large homogeneous group of patients among all those described in the literature.

In the seminal work by Gerstmann, (1942) two patients were reported who presented with a sense of disownership for one arm which they attributed to someone else. This deficit was not isolated since the same patients concurrently showed a pathological embodiment of other people's limbs in their own body (Gerstmann, 1942). The initial definition of SP incorporated a varied group of symptoms, including the denial of ownership of an affected body part, but also several other conditions which were considered part of the same core deficit. These conditions included misoplegia (i.e. the aversive behaviour toward the affected limb), anosognosia (i.e. the unawareness of neurological deficits), and other milder signs of extraneity for body parts (Critchley, 1953). However, all those additional deficits do not necessarily hold the same underlying cognitive mechanisms and neural substrates, calling for the necessity of a sharper definition of SP (Jenkinson et al., 2018).

SP can be currently defined as an acquired condition characterised by the delusional belief that a body part does not belong to one's own body (i.e., asomatognosia (Jenkinson et al., 2018)), and is attributed to someone else. Those beliefs do not depend on a generalised delirium or psychiatric disorder (Fotopoulou et al., 2011; Gandola et al., 2012; Romano et al., 2014; Feinberg and Venneri, 2014; de Vignemont, 2011; Jenkinson et al., 2018), but to a modular disruption of consciousness, selectively targeted to a single body part or body side (Bisiach et al., 1991; Bottini et al., 2002). We used this operative definition of SP to identify the cases of SP in the literature.

## 2. Anatomical substrates of somatoparaphrenia

The study of SP has been limited to the description of single case studies for several years; this approach limited early conclusions on neural underpinnings as the deficit typically manifests in cases of large strokes. More recently, the issue of identifying the anatomical underpinning of SP has been approached involving larger samples of patients (see Table 1).

The first group study was published by Feinberg and colleagues (Feinberg et al., 1990), who investigated 12 patients presenting with denial of ownership (i.e., asomatognosia). Every patient of the study had right hemisphere stroke, with lesions overlapping in the supra-marginal gyrus of the inferior parietal lobule and its subcortical connections within the posterior corona radiata (Feinberg et al., 1990). Critically, the attribution to another person of the impaired limb was not confirmed in each patient so that conclusions might be unspecific to SP.

More recently Baier and Karnath (Baier and Karnath, 2008) mapped the lesions of 12 patients with altered sensation of limb ownership including patients with SP, but also patients showing other body awareness impairments (e.g., misoplegia, personification of the limb, *kinesthetic hallucinations*). The authors found the right posterior insula as a critical region of overlap among patients (Baier and Karnath, 2008), although, given the patient selection, this may not be specific for somatoparaphrenic patients.

In order to overcome the above uncertainties in anatomo-clinical correlations, Feinberg et al., (2010) replicated their original study distinguishing now cases with asomatognosia showing unelaborated errors regarding the ownership of their limb, from cases with full SP (i.e. asomatognosia together with the delusional attribution of the affected limb to another person). They found that all patients involved in the study with or without SP had a significant *temporo-parietal* involvement. They also noticed a partial and less common involvement of other structures such as the insula that was previously described by Baier and Karnath. Interestingly patients with denial of ownership had an additional right medial frontal involvement than patients without asomatognosia and showed overall larger lesions. Furthermore, matching the conditions of asomatognosia and SP with the control group of hemiplegic patients without denial of ownership, patients with unelaborated asomatognosia only showed more massive medial frontal damage, while patients with SP showed, also, significant involvement of right *orbitofrontal* structures (Feinberg et al., 2010).

In a successive study, Gandola et al., (2012), investigated 22 patients matched for the presence or absence of neglect, *motor* deficits and anosognosia. Half of the cases presented with SP the other half did not. The inclusion criteria for SP group were selected as to include only patients who firmly denied the ownership of the limb, attributing the arm to someone else. In this study, SP was associated with large fronto-temporo-parietal lesions, a network typically involved in the occurrence of neglect, hemiplegia and anosognosia. This study did not find a specific association of SP with insular damage, while they noteworthy observed specific damage in subcortical white matter regions and grey nuclei (Gandola et al., 2012).

The subcortical pattern was further characterised by voxel-based analysis that showed an association between SP and the damage of subcortical white matter of the right hemisphere, (internal capsule, corona radiata, superior longitudinal fasciculus and superior fronto-occipital fasciculus, body of corpus callosum and white matter in the depth of the temporal pole and the hippocampus), basal ganglia and thalamus (ventrolateral nucleus, ventral posterior lateral nucleus, ventral anterior nucleus, and lateral posterior nucleus).

In addition to the subcortical lesions, the middle and inferior frontal gyri, the postcentral gyrus, the right hippocampus and amygdala were also significantly associated with the presence of SP (Gandola et al., 2012; Romano et al., 2014). Interestingly it was concluded that the lesions more critically associated with SP predominantly affected the white matter (Gandola et al., 2012).

The lesion pattern identified for SP should be considered as a part of a larger disruption that involves a larger network which is typically observed in patients with neglect and hemiplegia (Karnath et al., 2004; Doricchi et al., 2008; Vallar and Perani, 1986; Bartolomeo et al., 2007) and comprises a fronto-temporal and rolandic operculum circuit together with basal ganglia, the corona radiata and the superior longitudinal fasciculus.

The importance of subcortical lesions in SP was already noticed in different single case reports (Healton et al., 1982; Bisiach and Geminiani, 1991; Bottini et al., 2002), as well as in the first group study by Feinberg et al. who specifically suggested the involvement of corona radiata in verbal asomatognosia (Feinberg et al., 1990). The predominant role of subcortical regions in SP is corroborated by a recent study by Moro and co-workers (Moro et al., 2016) who found that subcortical lesions in basal ganglia and white matter were significantly associated with a disturbed sense of body ownership with

**Table 1**  
Brain structures associated with somatoparaphrenia in the different studies.

Study	Brain Structures involved	Inclusion Criteria	Sample (n, clinical picture)
Feinberg et al., 1990	Right hemisphere prevalence. Supramarginal gyrus. Posterior corona radiata	Sense of disownership (asomatognosia), ownership attribution to others (somatoparaphrenia) not investigated in all cases and not distinguished in lesion mapping	12, asomatognosia
Baier and Karnath (2008)	Right posterior insula	All the confabulation toward affected limb classified as somatoparaphrenia without specification of the contents of confabulation.	12, general confabulations toward affected limb
Feinberg et al., 2010	General temporo-parietal. Right medial frontal & right orbitofrontal specific for asomatognosia with limb attribution.	Asomatognosia with confabulation about limb ownership compared with asomatognosia without limb ownership attribution.	7, asomatognosia with attribution; 6, asomatognosia without attribution
Gandola et al., 2012	Subcortical white matter of the right hemisphere. Basal ganglia & thalamus. Middle & inferior frontal gyri Right hippocampus & amygdala	Somatoparaphrenia defined as a sense of disownership plus limb attribution to someone else. Controls were matched for age, education and the presence of motor deficits, neglect, and anosognosia	11 with somatoparaphrenia; 11 without somatoparaphrenia
Romano et al., 2014	Right white matter: posterior limb of the internal capsule & corona radiata. Basal ganglia & thalamus. Right hippocampus & amygdala.	Somatoparaphrenia defined as a sense of disownership plus limb attribution to someone else.	4, somatoparaphrenia
Moro et al., 2016	Right basal ganglia & surrounding white matter.	Patients selected for the presence of a sense of disownership plus limb attribution to someone else, classified as disturbed sense of ownership	17, impaired sense of ownership

misattribution in their four patients. A crucial aspect of Moro et al. study is the accurate control of patients' symptoms, in order to dissociate patients with disrupted sense of ownership from those only affected by anosognosia. Additionally they dissociated the involvement of subcortical areas associated with disrupted sense of ownership from lesions associated with neglect.

It has been proposed that a lesion of subcortical grey nuclei or to the white matter tracts that connect those structures with cortical sensory-motor and associative areas, could be critical for the feeling of disownership, as it may lead to a deficit in the construction of a coherent body representation that includes the affected limb. In this model, a critical disconnection would occur between afferent information arising from the affected body part (bottom-up processes) and pre-existing body representations computed by higher-order cortices (top-down processes) (Berti, 2013; Tsakiris et al., 2006; Tsakiris and Fotopoulou, 2008; Gandola et al., 2012; Romano et al., 2014).

Finally, the right hippocampus, its white matter and the amygdala have been proposed as a contributing neural underpinning of SP (Gandola et al., 2012; Romano et al., 2014). While the hippocampus may have a pivotal role causing a deficit in storing memory for the spatial location of body parts (Carpenter et al., 1995), the amygdala may worsen any right hemispheric residual processing of sensory information related to the paralysed limb, depriving the contents of such processing of emotional connotations (Gandola et al., 2012; Romano et al., 2014).

SP following left hemisphere lesions without inverse lateralisation of linguistic functions is very rare. In one case SP appeared in an ambidextrous patient following a broad left hemisphere stroke (Ronchi et al., 2013), and in another case, transient SP has been reported in a patient with a left fronto-parietal meningioma (Beato et al., 2010).

### 3. Clinical features of somatoparaphrenia

Fig. 1 reports the clinical features of SP and its association with main neurological deficits (see also the table in supplementary material for the case-by-case report of the literature review).

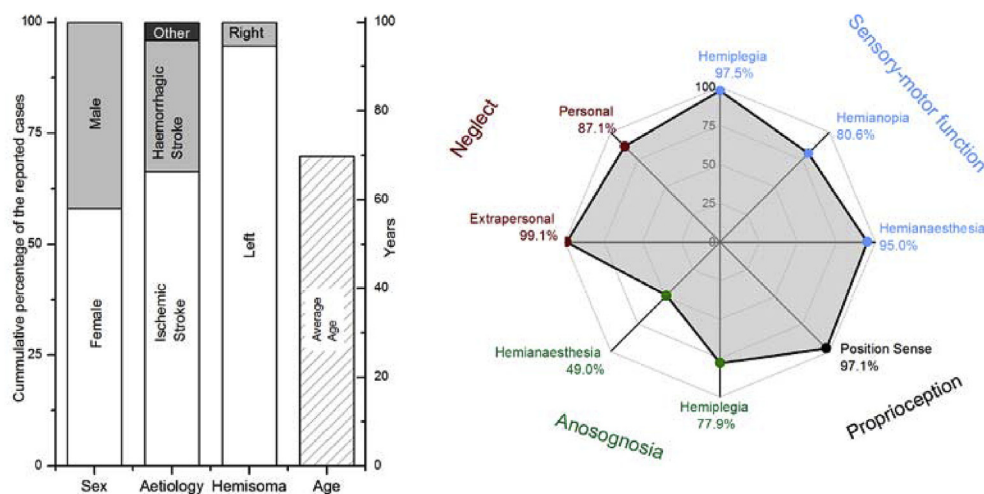
SP typically occurs following right hemisphere lesions (97.5%) and is more frequently observed after intraparenchymal stroke (95.5%), although cases following neoplastic lesions or subdural hematoma have been reported as well (Weinstein and Kahn, 1950; Beato et al., 2010; Halloran, 1946). While SP is considered a rare condition, more general alterations of body representation have been reported in up to 15% of

right brain damage patients (Baier and Karnath, 2008; Moro et al., 2016) suggesting that SP might be sometimes misdiagnosed or unnoticed by clinicians. Baier and Karnath studied 79 post-stroke right brain-damaged patients, finding 12 cases with abnormal attitudes towards their affected limbs, 6 of whom (7.5%) showed frank SP; Moro et al. (2016) reported similar numbers.

The body part interested is typically affected by a neurological deficit, usually including motor (97.5%) and somatosensory impairment (95.0%).

SP mostly affects the upper left limb, contralateral to the typical right-sided brain damage, even if a few cases are described of delusions following left hemisphere damage (Miura et al., 1996; Schiff and Pulver, 1999; D'Imperio et al., 2017). It is worth noting that since SP is typically investigated using interviews, some left brain-damaged patients might go undiagnosed due to aphasia. A systematic investigation of lower limb somatoparaphrenia is lacking in the literature, so although it is a frequent clinical observation in the authors experience, it is seldom reported in scientific clinical case descriptions. The few cases that reported the investigation of the lower limb found that it could be associated (Halligan et al., 1993) or dissociated (Bolognini et al., 2014) with disrupted sense of ownership of the upper limb. SP usually follows massive hemispheric damages (Gandola et al., 2012) so that it is always associated with other deficits in body awareness and space processing. Anosognosia, unilateral spatial neglect (i.e., the inability to explore/represent the contralesional side of the extra-personal space), or personal neglect (i.e., the inattention toward sensory or motor aspects of the contralesional side of the body) (Vallar, 1998), due to the overlap of anatomical substrates (Bottini et al., 2009), are frequently associated to SP. Both personal and extrapersonal neglect are associated with SP, but there are cases of SP without personal neglect (12.9%), while almost all the cases reported did show extrapersonal neglect (99.1%). The only two cases reported as somatoparaphrenic without extrapersonal neglect are extremely peculiar and showed an unclear clinical profile. The patient described by Cereda and colleagues showed transient SP following selective damage to the right insula (Cereda et al., 2002). The other patient, described by Garcin et al. (1938, reported in Vallar and Ronchi, 2009), had no signs of disownership for the contralesional limb but showed a pathological embodiment of nurse's hand when his hand was covered. The diagnosis in this patient is therefore questionable.

Also position sense – i.e., the ability to localise one's body parts through proprioception – is typically compromised in somatoparaphrenic patients (97.1%). Two cases reported with SP and preserved



**Fig. 1.** Sum-up of the clinical features of the cases of somatoparaphrenia described in the literature. The left panel shows the cumulative probability of having somatoparaphrenia based on: the gender, aetiology, and affected hemisoma. The mean age is reported as well. The right panel shows the frequency of association of symptoms typically reported in association with somatoparaphrenia. Symptoms are roughly divided with a colour map as to highlight the distinction between neglect, anosognosia, proprioception, and primary sensory-motor deficits. (For interpretation of the references to colour in this figure legend, the reader is referred to the Web version of this article.)

ability in localising one's arm did not exhibit disownership of impaired limbs and were classified as somatoparaphrenic patients because of visual and auditory hallucinations emerging from the left limb with additional misoplegic behaviours (Nightingale, 1982; Starkstein et al., 1990). Although these patients were described as SP, they do not fit with the current, more strict and coherent, definition of SP, so they were not included in our count. Another, more recent, case reported by Beato (Beato et al., 2010) showed disownership for the right upper limb, in the absence of any associated neurological deficit, following a frontal meningioma, thus resulting in a very peculiar form of SP. One last patient recently observed by our group (Romano et al., 2014), was able to reach her affected hand with the unimpaired one, calling for preserved proprioception. However, the position of the impaired hand was not manipulated so that her ability to update the location of her left arm is unknown. With some uncertainty related to these two peculiar patients, position sense seems to be tightly related to the sense of disownership.

Anosognosia for hemiplegia – i.e., the lack of awareness for the acquired motor deficit – is so frequently associated with SP, that for a long time it has been considered as a milder form of the same deficit (Critchley, 1953). While early studies suggested that anosognosia and SP always coexist (Heilman, 1991; Bottini et al., 2009), clear dissociations have been recently documented. The study by Invernizzi et al. (2013) described five cases of SP without anosognosia for hemiplegia. They showed that the lesion pattern of those patients was largely overlapping to that described for SP (Gandola et al., 2012; Feinberg et al., 2010; Romano et al., 2014), but different from that associated with anosognosia for hemiplegia (Berti et al., 2005).

Other delusional phenomena are associated with SP, such as the feeling that another person is in the contralesional hemispace (*feeling of a presence*), the experience of supernumerary limbs, misoplegia, or changes in physical sensations about the arm (e.g., the hand is perceived as colder, heavier, bigger). Such additional phenomena which can be present even without the typical core misattribution feeling about the affected arm, are, sometimes, the primary clinical manifestations of patients, posing doubts for their inclusion as cases of SP (see Vallar and Ronchi, 2009, for a collection). This classification may often prevent to create homogeneous groups, making it hard to classify patients for clinical purposes and to understand the results of research investigations. The inspection of our cases collection shows that SP is typically accompanied by profound sensory-motor impairments on the left hemisoma, as well as contralesional hemianopia (80.6%). However, dissociations have been reported for each of these primary sensory functions. For example, none of the twelve patients described by Feinberg (Feinberg et al., 1990) presented with hemianopia. Moreover, a few different patients did not show a somatosensory deficit (see table

in the supplementary material). Interestingly patients presenting with clear limb disownership and preserved motor functions have not been described in the literature, leaving room for the motor deficit as a necessary condition for SP.

However, the original case reported in the present manuscript (e.g., Case #1), provides a clear dissociation of SP and motor deficit of the affected limb.

These dissociations support the idea that none of the primary sensory-motor deficit is necessary for the emergence of SP even if they are frequently associated. Proprioception, up to now, seems to be an exception being necessary to SP. However, the rarity of cases with very mild proprioceptive deficit suggests that more observations are needed to further qualify the implication of proprioception in the emergence of SP. In particular, we could not clearly identify in the literature, or in our new cases, a clear situation of perfectly spared position sense in SP patients (see P2 and P3 for a record of SP in presence of partially spared position sense). Conversely, the non-necessity of kinaesthesia impairment for SP appears to be confirmed by the condition of P2 presented in the current study. On this line, it was shown that primary sensory functions and SP are differently modulated by manipulations that affect the processing of sensory information. For example, Moro et al. (2004) observed that crossing the hands (i.e. putting the affected hand in the portion of space to the same side of the lesion) improved somatosensory deficit but not disownership sensation. Analogously vestibular stimulation was found to improve SP, as well as neglect, but not necessarily and simultaneously primary sensory-motor functions (Ronchi et al., 2013; Bisiach et al., 1991).

#### 4. Investigation of the new cases

We present here three new cases that bring new insight into the clinical associations and the cognitive underpinnings of SP. These cases are already included in the counting of Fig. 1, they are reported in the table in supplementary material as well.

##### 4.1. Neurological assessment

Standardised neurological assessment was performed in each patient following the procedure proposed by Bisiach and colleagues (Bisiach et al., 1986) for assessing basic motor, somatosensory and visual functions at the bedside. Following this procedure, motor functioning is classified with a score of 0 for fully preserved movements, 1 for slight hyposthenia, 2 for severe hyposthenia, and 3 for hemiplegia without any preserved antigravity movement. The same procedure is used to assess tactile sensitivity and visual field: 0 indicates spared function, 1 indicates extinction (i.e., the inability to detect stimuli



contralateral to the lesion side when presented simultaneously to an ipsilateral one, together with preserved detection of unilateral stimuli on both sides), 2 indicates mild deficit, and 3 severe deficit. Proprioception was tested placing the patient's impaired hand in two different positions (palm up and palm down). On each trial, the patient was asked to put his/her unimpaired hand in the same position, while keeping the eyes closed. Proprioception was also tested by positioning the patient's contralesional body part (index finger or hand) in two different positions (up or down) asking the patient, on each trial, to mimic that posture with the homologous finger ipsilateral to the lesion side. Finally, personal neglect was assessed adopting the procedure suggested by Bisiach and colleagues where the patient is asked to reach for his/her impaired left hand using the healthy right one (Bisiach et al., 1986). In this test patients score 0 if they reach the left hand without hesitation, 1 if they can reach it smoothly with initial hesitation, 2 if they cannot find the left hand while exploring the left hemispace, and 3 if they cannot find the left hand and the exploration is limited to the right side of space.

#### 4.1.1. Assessment of anosognosia

Awareness of neurological deficits (i.e., anosognosia) was also tested following the procedure proposed by Bisiach and colleagues adopting a standardised four-point scale (Bisiach et al., 1986). In this scale, the value 0 is given when the patient declares his/her deficit spontaneously after a general question about his/her clinical state; 1 if the patient reports the deficit after a specific question about the affected function; 2 if the deficit is acknowledged only after demonstration by the examiner (mild anosognosia); 3 if the acknowledgement of the disorder cannot be achieved in any way (severe anosognosia).

For tactile sensitivity, the objective demonstration was done by showing to the patient that the hand was touched while he/she was saying that there was no concurrent stimulation. For visual stimuli, the patient was invited to turn the head and orient attention to the left side while the examiner was continuously providing the target visual stimulus.

#### 4.1.2. Neuropsychological screening

A short neuropsychological screening was performed in order to test for the presence of neglect, which is typically associated with SP, and of gross impairments of the general cognitive state. The Mini Mental State Examination (MMSE) (Folstein et al., 1975) was employed to test the general cognitive state. The assessment of neglect was performed through the Albert cancellation test (Albert, 1973) and the clock drawing test (Mondini et al., 2003). All the three patients showed a mild-to-severe deficit in the MMSE. Moreover, defective performances in cancellation tests suggested for the presence of extrapersonal neglect, while the clock drawing test performance was normal for patient P1, and strongly impaired for patients P2 and P3. All the patients were oriented in time and space and did not show generalised confabulations (see Table 2 for a sum-up of the assessments).

#### 4.1.3. Assessment of somatoparaphrenia

SP was investigated by interviewing patients in search of delusional feelings referred to their contralesional upper limb. The interview typically started by placing the patient's contralesional left hand in front of him/her and asking a sequence of questions: "What is this? Whose hand is this? Where is your hand?". The first question was always asked, while the other two were asked depending on the patient's response to the first one. Patients were considered somatoparaphrenic if they denied the ownership of their contralesional limb and attributed that limb to someone else (Invernizzi et al., 2013; Romano et al., 2014).

### 4.2. Case report #1 (P1)

#### 4.2.1. Somatoparaphrenia with preserved voluntary movements

The first patient is a 66 years old man, right-handed, with eight

years of education, who worked as a mechanic. He was admitted to hospital following a large haemorrhagic stroke in right fronto-parietal regions involving both cortical and sub-cortical structures.

The patient was assessed 37 days after the stroke. At that time, he was alert and collaborative throughout the assessment. The standard neurological examination revealed deep left hemianopia and impairment of tactile sensitivity on the left limbs. On the motor side, the patient showed motor weakness for the left limbs, but he was able to perform voluntary movements with the hand and fingers, as well as with the entire left lower limb. Moreover, he was unable to localise the impaired hand when asked to reach for it with the unimpaired one. He had a remarkable position sense and kinesthetic sensitivity deficit; he could not detect the actual position of his left hand and his performance in the detection of passive movements of wrist and fingers was at chance level. He was also unaware of his neurological deficits, acknowledging only a slight motor impairment for which he seemed to be not at all worried. The patient showed consistent somatoparaphrenia, attributing the ownership of his left hand to the examiner. It is remarkable that when asked to pay attention to the hand and tell whose hand was that, he first performed some pronosupination movements in front of his face, then firmly assessed that the hand belonged to the experimenter. A short report of the patient interview is reported below.

#### 4.2.2. Patient #1 (P1) interview

*Examiner (E)*, (after passively positioning P1's left hand in front of his face while he was keeping the eyes closed) *Open your eyes, whose hand is this?*

*P1*: (looking at his hand) *it is yours.*

*E*: are you sure?

*P1*: Yes I'm sure.

*E*: so this is not your hand?

*P1*: Not at all.

*E* (after putting P1's left hand again in front of his face while he was keeping the eyes closed): *Look at this. What is it?*

*P1*: (looking at his hand) *This is your hand!*

*E*: Is this mine?

*P1*: Yes, yes. This is your hand.

*E*: (putting P1's left hand again in front of his face while he was keeping the eyes closed) *Look again, whose hand is this?*

*P1*: (starts moving the hand, twisting it palm up and palm facing down a couple of time while looking at it): *Yes I told you, I can see it well, this is your hand! My hand is resting down.*

*E*: From 1 to 10, how sure you are that this is my hand?

*P1*: I would say 8.

#### 4.2.3. Case report #1 short discussion

Case #1 surprisingly shows that SP may present with preserved voluntary motor function, suggesting that hemiplegia is not a necessary condition for SP, and that even the possibility to perform voluntary actions while assessing limb ownership is not enough to recover from limb misattribution. Notably, this patient had an associated severe impairment of proprioception and tactile sensitivity, thus being completely unable to localise the hand in space.

### 4.3. Case report #2 (P2)

#### 4.3.1. Somatoparaphrenia with preserved tactile and kinesthetic sensitivity

The second case was an 84 years old woman, right-handed, with 11 years of education.

She was admitted to hospital following a hemorrhagic stroke in the right temporo-occipital region, also involving the thalamus, the basal ganglia and the internal capsule. Reportedly, in the acute phase of the disease, the patient showed severe left hemiplegia, hemianesthesia and hemianopia, together with severe unilateral spatial neglect, and, crucially, delusion about the ownership of the paretic limb.

**Table 2**

Sum up of the three novel cases described. \*indicates a severe deficit, ± corresponds to a mild deficit, - suggest for a spared function. N+ indicate the presence of neglect, while N- its absence. Scores of MMSE are reported uncorrected. Scores of primary functions in the table are those obtained during the standard evaluation. It is worth noting that during the in-depth evaluation, patients showed a more complex scenario also for the primary functions. For example, P1 showed severe hyposthenia during the objective neurological examination, but his behaviour during the in-depth assessment showed a much less severe condition for primary motor function.

	#P1	#P2	#P3
<i>Standard Neurological Examination</i> (Bisiach et al., 1986)			
Motor function	2 ± (Hypostenia)	3*	3 *
Tactile Sensitivity	3*	1 ± (Extinction)	3 *
Visual Field	3*	3*	3 *
Anosognosia for Motor function	2*	0 -	0 -
Anosognosia for Tactile Sensitivity	3*	1 -	3 *
Anosognosia for Visual Field	3*	1 -	1 -
Personal Neglect	2*	2 *	1 ±
Position Sense	*	±	±
Kinesthesia	*	-	*
Albert Test (Albert, 1973)	N+	N+	N+
Clock Drawing Test (Mondini et al., 2003)	10 - N-	0 * N+	3 * N+
MMSE (Folstein et al., 1975)	23 ±	21*	18 *
Brain lesion	Right fronto-parietal haemorrhage, involving cortical and sub-cortical structures	Right temporo-occipital haemorrhage, also involving thalamus, basal ganglia, and internal capsule	Right insulo-temporo-parietal ischemia, involving cortical and subcortical structures

We fully assessed the patient in the sub-acute phase, one month after the stroke. The short neuropsychological assessment showed severe spatial neglect and a slightly impaired performance at the MMSE, mainly due to the interference of neglect on the visuospatial tasks.

The patient also showed a remarkable inability to localise the impaired left arm. When asked to reach for her left hand with the right one, she hesitated to start the movement, and she could not eventually reach the hand. This case became particularly interesting since while showing severe motor impairment for the left arm, and dense left hemianopia, she had nearly unimpaired tactile sensitivity (except for the presence of tactile extinction), and she was fully aware of the motor and visual impairments. Moreover, despite severe personal neglect, the patient showed a dissociation in her proprioceptive impairment. Kinesthetic sensitivity was fully preserved (e.g., she was always able to detect if her impaired arm or hand was passively moved). By contrast, position sense featured the consistent, although not perfect, ability to reproduce the configuration of the left hand (Table 3) but an inability to localise it in space.

Crucially for the scope of this study, when she was interviewed about the sense of limb ownership, the delusions emerged, and the patient referred a strong sense of disownership towards the left arm, attributing it to the examiner.

4.3.2. Patient #2 (P2) interview

Examiner (E) (after passively positioning the left hand on the table):

**Table 3**

P2 assessment of kinaesthetic sensitivity and proprioceptive postural localisation. During each trial, the patient was asked to report if the limb was moved or not and then to reproduce the same posture with the other limb (e.g., moved up or down). Movements were interleaved with 10 catch trials where any movement was performed. The number of correct answer/number of total tests are reported.

Body Part	Has the hand been moved? (kinesthetic sensitivity)	Reproduce the posture. (proprioceptive postural localisation)
Shoulder	20/20	7/10
Elbow	20/20	10/10
Wrist	20/20	8/10
Finger	20/20	10/10

Close your eyes and, with the right hand, try to reach your other hand. P2 (looking for the left hand in the last place where the hand was positioned before it was moved for the test): *It should be around here, but I can't find it. I don't really know where it is.*

E (after moving P2's hand in front of her face, while she was keeping her eyes closed): *Open your eyes, what is this?*

P2: This is my hand

E: Is this yours? Are you sure?

P2: yes, I feel that you are touching it.

E: and if you could only look at it?

P2: I don't know, it looks like it is mine

E: (After a few minutes E moves P2's left hand towards her face, after putting it on a pillow in order to reduce tactile cues): *Now open your eyes. What is this?*

P2: a hand

E: whose hand is this?

P2: I don't know

E: Whose might it be?

P2: It could be mine, but I don't really feel like it's mine. No it is not mine. It is swollen and it does not move, I don't feel like it is mine.

E: So whose might it be?

P2: it could be someone else's hand, but I don't know ... I guess it's yours.

P2 (then, after spontaneously touching the left hand with the right one): *No no, this is mine, now I feel it, I recognise it. It's mine!*

4.3.3. Case report #2 short discussion

In this case, SP was less pronounced and emerged only when tactile cues were reduced. P2 could easily distinguish her hand when touched. Moreover, she had spared kinesthesia, and the proprioceptive deficit was specifically related to the inability to localise the impaired hand in space when asked to reach for it with the unimpaired hand. Position sense was only moderately impaired, however, intriguingly, her ability to reproduce the posture of her left arm was dissociated by her ability to map the arm in space. One may speculate that the patient could reconstruct the arm posture from the sensory analysis of connected body segments, although being unaware of their overall spatial location. This specific aspect might be related to her spatial neglect or motor neglect. Whatever the cause of her inability to localise the arm in space, this aspect seemed to be crucial to generating SP. Her peculiar form of SP suggests that spared kinesthesia is not enough to allow a proper feeling

of ownership. Moreover, the quick recovery from SP when receiving touches, suggests that the sense of body ownership can emerge thanks to the dynamic multisensory update of body representation. A similar recovery of a sense of ownership following perceived tactile event was described for patients presenting with pathological embodiment, supporting the idea that the sense of ownership is dynamically modulated by online multisensory integration (Fossataro et al., 2018).

#### 4.4. Case report #3 (P3)

##### 4.4.1. Somatoparaphrenia at specific spatial locations

P3 was a 74 years old man, right-handed, with 13 years of education.

The patient was admitted to the hospital because of a large ischemic stroke that affected the right insulo-temporo-parietal regions, involving both cortical and subcortical structures.

The patient was highly collaborative and was tested twice, 22 and 29 days after the stroke. The patient presented with strong unilateral spatial neglect. The abnormal score at MMSE was characterised by the inability to perform all the tests with a visuospatial component, and difficulties in the back-counting subtest. The neurological examination showed a complete hemisindrome with deep left-sided motor, tactile and visual impairments. He was aware of the visual field and motor deficits, but not of his tactile sensitivity deficit. When asked to reach his left hand with the right one, he could accomplish the task with just some initial hesitation a behaviour classified as mild personal neglect. It is also worth noting that proprioception of the left arm was only partially altered. When he was asked to reproduce the posture of the impaired hand (which could be unpredictably bended upward/downward) with the right healthy one, he was able to perform correctly in 18 out of 25 trials.

When interviewed about the ownership of his left arm the patient showed a peculiar, fluctuating form of SP. In particular, he tended to lose the feeling of ownership of his hand contralateral to the lesion side, which he attributed to the examiner, shortly after the limb was passively moved. When we first assessed limb ownership, the patient recognised his hand resting on the table, as his own. Critically, when the hand was passively moved in front of his face by the examiner, the patient misattributed the hand to the examiner, while searching for his left hand on the table, i.e. at the last position where he acknowledged correct ownership. Surprisingly, if the hand was kept in the new position for a while, he now correctly attributed the hand to himself, but misattributed it to the examiner again, when the hand was moved back on the table. Intriguingly, when the examiner's hand was placed at the position occupied by the patient's hand before passive movement, the patient attributed that hand to himself. The whole procedure was repeated during both the first and second examination, with identical results (see video from the second evaluation in the [supplementary material](#)).

##### 4.4.2. Patient #3 (P3) interview

Examine (E) (indicating P3 left hand on the table): *What is that?*

P3: My hand.

E: whose hand is this?

P3: it is mine.

E: How much are you sure that this is your hand?

P3: This is 100% mine!

E: (after moving P3's left hand in front of his face while he was keeping the eyes closed): *Open your eyes, what do you have now in front of your face?*

P3: a hand.

E: whose hand is this?

P3: it is yours.

E: is this mine?

P3: yes, it is your hand.

E: How much are you sure that this is my hand?

P3: I would say 100%. I believe this is your hand.

E: Is there any chance that the hand you have in front is yours?

P3: No. This is your hand.

E: So, where is your left hand?

P3: It's down there, on the table

E: So whose hand is this one in front of your face?

P3: It is yours.

E: Now close your eyes and with the right hand, try to reach for your other hand.

(The patient hesitates, and then reach his hand in the air, in front of his face. After that, E put P3's left hand back on the on the table and points at it): *Whose hand is this?*

P3: this is your hand

E: and where is your left one?

P3 (searches in the air, in front of his face): *It should be here, but I can't find it.*

E: (puts his own hand in front of the patient): Can you tell me whose hand is this one, in front of you?

P: it is mine

E: from 1 to 10, how sure you are that the hand is yours?

P: I would say 8

##### 4.4.3. Case report #3 short discussion

This last case shows that the sense of ownership follows the perceived location of the impaired arm. Consistent misattribution of the patient's hand to the examiner, and vice-versa, were observed following passive movements of the affected hand. This behaviour is reminiscent of the pathological embodiment patients described by Garbarini and colleagues who, following a stroke, show the peculiar behaviour of incorporating in their own body representation, alien hands placed in their contralesional space (Garbarini et al., 2013, 2015, 2014), a behaviour already described by Gerstman (Gerstmann, 1942). In analogy with P2, the quick recovery and re-emergence of SP following postural changes suggests an impairment in the dynamic updating of body representation.

## 5. Discussion

### 5.1. Classic cognitive models to explain somatoparaphrenia

A clear, shared explanation for SP is still lacking. No specific premorbid psychopathological pattern has been associated with the occurrence of SP (Vallar and Ronchi, 2009). The fundamental deficit is most likely related to right-hemisphere-based body awareness representations and processes. However, other factors, such as premorbid psychopathology, or motivational issues, may be relevant in shaping the somatoparaphrenic delusion in the individual patient, suggesting that a multidimensional account may better explain the full set of symptoms of SP (Feinberg, 2013; Feinberg et al., 2010).

From an historical perspective, one of the first attempt to explain the presence of confabulations regarding the paralysed left arm in patients with right-hemisphere lesions was proposed by Geschwind who hypothesised a disconnection of perceptual regions from the language areas of the left hemisphere (Geschwind, 1965). Similarly, Gazzaniga suggested that the left hemisphere acts as an 'interpreter' of ongoing experience that aims at keeping coherent the perceived world. In somatoparaphrenic patients, it would construct elaborate and false interpretations of actions or perceptions whose content or cause are unknown, due to incomplete information coming from defective sensory feedback (Gazzaniga, 1989).

With a different perspective, body awareness deficits have been viewed along the continuum of the implicit-explicit dualism. SP was supposed not to emerge if the body part can be automatically processed.

The denial of ownership would only appear when the patient is explicitly asked about the affected limb. The investigation of body ownership would require to consciously access information about limb ownership by voluntarily directing attention to the affected limb (Daprati et al., 2010). In this view, disownership feelings would not emerge spontaneously from the disruption of a self-specific embodiment module, instead they became evident from the detection of the disruption (de Vignemont, 2011). This proposal is reminiscent of the discovery theory of anosognosia (Levine et al., 1991), where patients are paralysed, but they deny the impairment. Within this view, a person needs to monitor one's performance and question about one's motor abilities to detect anomalies (Levine et al., 1991).

Similarly, people have a default hypothesis about the boundaries of one's own body that is not re-computed every time. It is only if a discrepancy is detected that this assumption is questioned. Anecdotal support to the defective awareness hypotheses is that patients do not always report disownership feelings by themselves, but they have to be asked about it.

In partial support of this hypothesis healthy individuals in which the right hemisphere is pharmacologically inactivated through amobarbital, causing a transient experience of loss of corporeal awareness closely similar to the one observed in brain-damaged patients, experiencing feelings of disownership and impaired estimation of motor ability (Meador et al., 2000).

A distinction between the implicit and explicit representation of the body has been summarized by stating that the body schema is generally for unconscious action, and the body image is generally for perception and conscious action (de Vignemont, 2010). By following this dissociation, the models presented so far would put SP in the domain of body image impairment, as it is associated with the explicit experience of body ownership. However, several and more recent observations suggest that SP also manifest at a more implicit level, overcoming the pure body schema/body image dualism.

In a recent perspective, SP is explained in terms of predictive coding models (Friston, 2010). In the model proposed by Ishida and co-workers, SP is described as the result of an imbalance between multiple body representation that contributes to putting the boundaries between the "self" and "other" body. When the specific self-body representation is disrupted by a brain damage, the probability that one's body part is tagged as belonging to oneself decreases and this is more likely attributed to another person, especially during interpersonal activities (e.g., like during medical assessment) (Ishida et al., 2015).

Another possible perspective is that a defective multisensory integration mixed with an impaired spatial representation (i.e., the presence of neglect) is implicated in SP (Vallar and Ronchi, 2009). This hypothesis has been investigated in the context of the relationship between spatial sensory processing and the sense of body ownership. In this line, it has been shown that the dissociation between the "subjectively felt" (first person) and "objectively seen" (third person) body perspectives can modulate the sense of body ownership (Fotopoulou et al., 2011). Fotopoulou and her colleagues found that looking at one's body in a frontal mirror (third-person perspective) can increase the sense of ownership for the impaired arm.

In a different study Romano et al., found a reduced reactivity to approaching harmful stimuli selective for the impaired limb in SP but not in anosognosia or control group, suggesting a reduction of monitoring of the peripersonal space around one's own body (Romano et al., 2014). On the same line, it was also shown that SP is modulated by the position of the experimenter in space changing the experience of ownership if the questions were raised from the right or the left side of space (Salvato et al., 2016). These studies support the idea that SP should be considered in terms of body-space interaction and not limited to the body.

The picture that comes from the literature review suggests that SP originates from a profound detachment of the patient's affected body part from the patient's body representation. The conscious access to

limb ownership seems to be prevented by a mixture of sensory deprivation and defective subjective explanation of such a deep sensory deficit. Notably, although only few studies attempted to modulate SP, there is evidence that the sense of ownership in these patients can be modulated in very short time. For example, D'Imperio and colleagues found that by changing the arm position or providing multisensory stimulation is possible to influence the sense of ownership in one patient presenting with SP for the right hand (D'Imperio et al., 2017). Similarly, Bolognini and co-workers restored the sense of ownership of one SP patient by using a multisensory stimulation approach (Bolognini et al., 2014). Similar examples of quick change in the sense of ownership of SP patients have been obtained changing the viewpoint of the body during the examination (Jenkinson et al., 2013), and changing the spatial side kept by the examiner during the assessment (Salvato et al., 2016). The quick plasticity of the sense of ownership suggests that the key defective mechanism should be more likely individuated in the dynamic representation of the body, than in its more stratified and long lasting representation of body features.

## 5.2. A novel key mechanism contributing to somatoparaphrenia: the defective updating of the body schema

We intend to focus on a new mechanism that may be critical in founding SP, emerging from the present case-studies, that is still located within the body-space interaction theoretical framework. Our idea is that the sense of disownership in SP may critically emerge from a deficit in updating the dynamic representation of the body in space (e.g., the body schema).

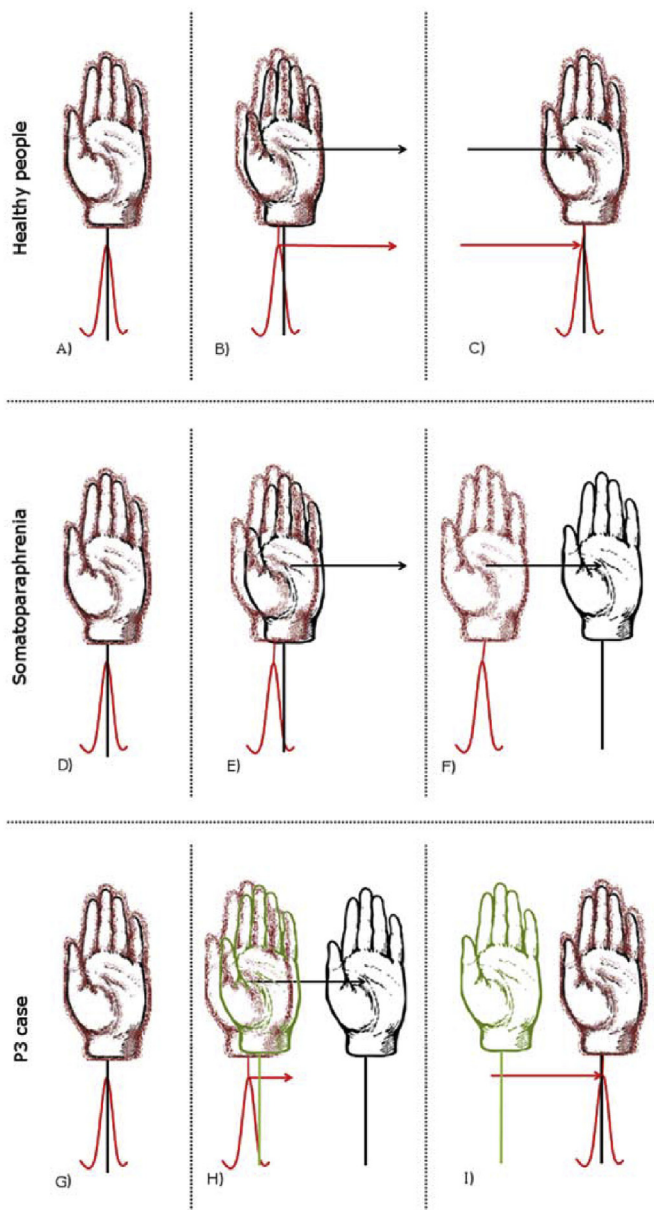
The first two cases presented in this paper showed in a clear-cut way that SP does not depend on any specific primary sensory or motor deficit. An exception seems to be the deficit of position sense, which seems to be invariably associated with SP: notably, however, position sense could be partially spared in SP (see case 2 and 3) and is surely not sufficient to generate SP per se.

P1 showed a preserved motor activity of the affected hand, a condition that is particularly uncommon. Specifically, misattribution of limb ownership in this patient occurred right after the execution of voluntary movements of the affected hand. P2 showed SP in the absence of tactile and kinesthetic loss, and with proprioceptive deficit limited to the position sense, indicating that also dense somatosensory deficits are not necessary for SP, even if they are frequently associated with it and may contribute to deepening the patient's delusion (Beato et al., 2010; Weinstein and Kahn, 1950; Cereda et al., 2002). Notably, despite these preserved functions, both patients had poor performances when asked to localise the impaired arm with the other hand. Considering previous literature and our first two cases, the only symptoms that seem to be invariably associated with SP are extrapersonal neglect, and the ability to localise the affected body part in space. These core deficits appear to be always accompanied by one primary sensory-motor deficit and anosognosia for sensory or motor deficit, although none of them seems to be necessary.

Our third case was able to recognise his hand as his own in the last updated location, while, once passively moved, he failed. Notably, once the new site was updated, he started to show SP for his hand when brought back into the original position. Fluctuations are typically observed in SP. However, our observations can unlikely be explained by mere fluctuations of SP, since P3 flipped from SP to normal ownership in a few seconds and in a somehow repetitive way, without any other evident intervening confounds. On the other hand, one may wonder whether the typical fluctuations that characterize SP do not depend, at least in part, on fluctuations of the testing situation, whereby the hand position, or the relative position of the examiner during the testing, would appear less reliable to the patient. Those potential spatial confounds may contingently boost or attenuate the occurrence of SP delusion.

It has been proposed that the lesions in patients presenting with SP





**Fig. 2.** The figure represents the proposed cognitive mechanism underlying somatoparaphrenia. Red fuzzy drawings represent the subjective mental representation of the affected hand and the estimation of its spatial location (red graphic lines below). Black solid drawings and lines represent the actual location of the hand. Green hand represents another person's hand and its location. The first row shows a hypothetical normal situation. (A) The subjective and objective spatial representations of the hand perfectly coincide. (B) When the hand is passively moved (black arrow) the subjective representation of the hand in space is immediately updated (red arrow), thus maintaining an efficient representation of hand ownership with the hand at the new position (C). In the second row, a hypothetical situation of a somatoparaphrenic patient is shown. (D) When the hand is stationary, in a position where the patient still represents it, ownership can be acknowledged, (E) however when the hand is passively moved, the patient do not update hand location representation, (F) so that the real hand can fall outside the area where hand is still represented, causing the sense of disownership. In the last row, the process of case P3 is represented. (G) The patient has normal sense of ownership in the stationary hand situation. (H) When the hand is passively moved (black arrow) the hand representation of P3 is slowly updated (short red arrow), possibly due to partially, but not completely, disrupted sensory-motor function and proprioception. If now, another person's hand (green hand) is put within the limit of the current, dislocated hand representation, the alien hand can be felt by the patient as part of his own body. (I) When such a slow update is complete, then the spatial location of the hand and its subjective representation coincide again and the sense of ownership is restored. (For interpretation of the references to colour in this figure

legend, the reader is referred to the Web version of this article.)

might impair the construction of coherent body representation, to the point that patients deny the ownership of the affected limb (Berti, 2013). We reasoned that at least one source of information about the body must be either abolished or degraded to the point that it provides noisy signals. This condition would affect the updating of a coherent body representation that could be specifically identified in the body schema. The body schema is the cognitive system that integrates all the information about the body and continually updates its representation in space to properly interact with the environment (de Vignemont, 2010). The failure to update the location of one's own body in space would cause a dense sense of disownership for the affected body part (Fig. 2) as a logical consequence of feeling one's body in a different place. A proprioceptive impairment may affect the spatial representation of the body, so that a patient does not have a mapping of the arm in space at any given moment. In this case, in lack of somatosensory information, vision would be enough to inform about the spatial location of the arm, resulting in a correct sense of ownership. This hypothesis would explain why a patient with profound proprioceptive deficit would not show SP.

Our hypothesis would be that SP would involve an erroneous, not absent, representation of the contralesional limb. In this view, it would be crucial to the emergence of SP that the patient still has a representation of the arm at any given moment, regardless of any concurrent deficit of position sense. Position sense might be so tightly related to SP because it conveys most of the dynamic information about space-body relation. Its deficit would, therefore, strongly affect the ability of updating the map of the body in space. Following the same reasoning, SP may also emerge because of a disconnection between the primary information of position sense and the areas processing the remapping of that information in a spatial framework (i.e., the body schema). In the latter case all the information needed to have a proper sense of ownership would be available, but fails to integrate from primary information to the body schema. This hypothesis is in line with the most recent observations about the lesion pattern associated with SP, which recognizes the crucial involvement of subcortical white matter of the right hemisphere (Gandola et al., 2012; Moro et al., 2016). This lesion pattern fits with the idea of disconnecting primary sensory-motor functions from associative areas that do more elaborated processing; possibly leading to a deficit in the dynamic construction of a coherent body representation.

The case of rapidly fluctuating somatoparaphrenic delusions across arm passive movements in P3 strongly supports the relationship between the sense of ownership and the update of spatial localisation of the body. This case shows that the relationship between body ownership and body localisation is bidirectional. Here, we somehow observed the reciprocal effect of the rubber hand illusion, as we found that the localisation of bodily self affects the feeling of body ownership. This influence is so strong that a body part of the patient, when suddenly located in an unexpected spatial position, can be attributed to someone else.

Notably, the update impairment mechanism is potentially valid also for other features of the hand (e.g., size, shape, temperature). For example, patients frequently describe their hand as to be visually-different than the one they see (e.g., smaller/fatter). If the update hypothesis applies to the visual modality too, the patient with "visual" SP should have a prior about the visual features of the hand that is not updated through the senses. When the discrepancy between such a non-updated prior and the seen hand is large enough, the patient rejects the ownership of the seen limb. Further systematic observations are needed to consolidate this theoretical framework evaluating, if it extends to more visually-driven features.

A similar hypothesis has been proposed to explain the behaviour of a patient experiencing a contralesional, supernumerary limb that was

felt 60–90 s following arm movements. This sensation was attributed to a deficit in tracking arm position, that resulted in body misperception (McGonigle et al., 2002). In that patient the lesion, located in the supplementary motor area, would delay the update of motor signals, leading to the sensation that an additional limb was present at the position that the limb occupied before movement. The feeling lasted until the system could re-update the arm position to the newly acquired position (McGonigle et al., 2002). Crucially, patients with SP hold the representation of only one arm per side simultaneously. The sensation of having the arm in a certain position, when it is in a different one, could be similar for SP and supranumerary limb. However, SP patients use the information of the felt arm to exclude that the seen one belongs to them, while supranumerary limb patients do not solve the ambiguity and acknowledge a sense of ownership towards both the seen and the felt one. In other words, by using the distinction between feelings and beliefs of body ownership (de Vignemont, 2011), patients with SP attribute the limb ownership relying on the feeling of ownership while supranumerary limb patients attribute multiple ownership relying independently on their feelings and their beliefs of ownership. It is a common clinical experience that in some instances, when SP patients deny the ownership of their limb contralateral to the lesion under visual control and are forced to indicate their own left arm, they seem to search for a different position than that of the physical limb, as if experienced their own arm somewhere else.

Vision, touch, proprioception and efferent copies of motor plans usually converge to determine where body parts are located (Tsakiris, 2010; Botvinick and Cohen, 1998; Tsakiris et al., 2006), giving a crucial clue for the feeling of ownership and construct a solid coherent belief of ownership toward a body that can be easily, constantly and finely controlled. The study of body ownership in healthy individuals supports this view. When a mismatch between two or more of sensory modalities is artificially introduced, several phenomena of a disturbed body representation emerge also in healthy people, typically together with a misperception of body location. Phenomena like a sense of disownership for one's own body (i.e., the disappearing hand trick illusion (Newport and Gilpin, 2011)), the embodiment of alien body parts (i.e., the rubber hand illusion (Longo et al., 2008; Ehrsson et al., 2004; Botvinick and Cohen, 1998)), or the incorporation of an entire alien body (i.e., the full body illusion (Ehrsson, 2007; Lenggenhager et al., 2007)). In strict analogy with these results, it has been recently reported that patients with a defective sense of ownership are more sensitive to the visual capture component of the Rubber Hand Illusion (RHI) (Martinaud et al., 2017). In the RHI, a multisensory visuo-tactile stimulation is used to induce an illusory sense of ownership toward a fake hand (Botvinick and Cohen, 1998). The visual plausibility of the seen fake hand (i.e., the visual capture component), and the simultaneity of the seen and the felt touch (i.e., the multisensory component) are merged in a single multisensory experience that induces a sense of ownership toward the fake hand (Tsakiris, 2010). The RHI is the most used experimental procedure to study the plasticity of the sense of body ownership in healthy individuals (Tsakiris, 2010; Botvinick and Cohen, 1998), and was introduced in the investigation of disrupted sense of ownership only recently (Jenkinson et al., 2013; van Stralen et al., 2013; Bolognini et al., 2014). The behaviour of P3, who tended to attribute an alien hand to himself, just because it occupied the expected location even in absence of any other sensory information, is coincident with the pathological embodiment (PE) condition (Garbarini et al., 2014). P3, together with the signs of SP, presented with the vivid experience that the real biological limb of another person belongs to himself. Similarly, the increased embodiment of the rubber hand in patients with disturbed sense of ownership (Martinaud et al., 2017) showed that also an artificial limb might be embodied because of its anatomical spatial location. A crucial difference separates PE from the RHI embodiment. While the former is accompanied by a profound belief of ownership, the latter induces only a milder feeling of ownership whereby the fake is felt “as if it was mine” and is not coupled with the

strong belief that “it is actually mine”, as in PE. We did not test P3 with an artificial limb, so that we cannot disambiguate between these two different aspects of abnormal embodiment, an interesting question that may seek for the importance of biological constraints in the pathological ownership experience of the patients.

The idea that the body schema plays a central role for a proper experience of body ownership can be generalised to healthy people, suggesting new experimental possibilities in healthy participants, where the link between sense of ownership and self-location can be tested more formally. For example, one could investigate not only how the sense of ownership affects the localisation of one's own body (e.g., as in the rubber hand illusion), but also how experimentally induced mislocalization of the body may reduce the sense of ownership toward one's body parts. Indeed, although these two aspects are tightly linked, they do not necessarily overlap, as shown by the evidence that illusory ownership and bodily self-location do not always go hand-in-hand (Rohde et al., 2011; Romano et al., 2015a; Abdulkarim and Ehrsson, 2016; Longo et al., 2008). Improving our knowledge about how these aspects connect seems now of utmost importance to extend our understanding of body representation. Indeed P3 shows that SP does not merely emerge following failed self-identification, but it originates from the failure of a dynamic representation of the body in space (Romano et al., 2014). The importance of such a body/space relation in SP is already underlined by the modulation of SP determined by changing the patient's viewpoint (Jenkinson et al., 2013), or spatial frame of reference (Salvato et al., 2016). The centrality of body/space interaction would also be consistent with the fact that SP has never been dissociated from extrapersonal neglect up to now (Romano et al., 2014).

## Funding

Any fund has been for this study. Authors have no conflict of interest to disclose.

## CRedit authorship contribution statement

**Daniele Romano:** Conceptualization, Data curation, Formal analysis, Investigation, Methodology, Writing - original draft. **Angelo Maravita:** Conceptualization, Investigation, Methodology, Supervision, Writing - review & editing.

## Appendix A. Supplementary data

Supplementary data to this article can be found online at <https://doi.org/10.1016/j.neuropsychologia.2019.107119>.

## References

- Abdulkarim, Z., Ehrsson, H.H., 2016. No causal link between changes in hand position sense and feeling of limb ownership in the rubber hand illusion. *Attention, Perception. Psychophysiology* 78, 707–720.
- Albert, M.L., 1973. A simple test of visual neglect. *Neurology* 23, 658–664.
- Baier, B., Karnath, H.-O., 2008. Tight link between our sense of limb ownership and self-awareness of actions. *Stroke* 39, 486–488.
- Bartolomeo, P., Thiebaut De Schotten, M., Doricchi, F., 2007. Left unilateral neglect as a disconnection syndrome. *Cerebr. Cortex* 17, 2479–2490.
- Beato, R., Martins, W., Nicolato, A., Ulhoa, T.H., Oliveira, M.M., Avelar, I.F.F.E., 2010. Transitory somatoparaphrenia associated with a left frontoparietal meningioma. *J. Neurol.* 257, 1208–1210.
- Berlucchi, G., Aglioti, S., 1997. The body in the brain: neural bases of corporeal awareness. *Trends Neurosci.* 20, 560–564.
- Berlucchi, G., Aglioti, S.M., 2010. The body in the brain revisited. *Exp. Brain Res.* 200, 25–35.
- Berti, A., 2013. This limb is mine but I do not want it: from anatomy to body ownership. *Brain* 136, 11–13.
- Berti, a, Bottini, G., Gandola, M., Pia, L., Smania, N., Stracciari, a, et al., 2005. Shared cortical anatomy for motor awareness and motor control. *Science* 309, 488–491.
- Bisiach, E., Geminiani, G., 1991. Anosognosia related to hemiplegia and hemianopia. In: *Awareness of Deficit after Brain Injury: Clinical and Theoretical Issues*. Oxford University Press, Oxford.

- Bisiach, E., Vallar, G., Perani, D., Papagno, C., Berti, a, 1986. Unawareness of disease following lesions of the right hemisphere: anosognosia for hemiplegia and anosognosia for hemianopia. *Neuropsychologia* 24, 471–482.
- Bisiach, E., Rusconi, M.L., Vallar, G., 1991. Remission of somatoparaphrenic delusion through vestibular stimulation. *Neuropsychologia* 29, 1029–1031.
- Bolognini, N., Ronchi, R., Casati, C., Fortis, P., Vallar, G., 2014. Multisensory remission of somatoparaphrenic delusion: my hand is back! *Neurology. Clin. Pract.* 4 (3), 216–225.
- Bottini, G., Bisiach, E., Sterzi, R., Vallar, G., 2002. Feeling touches in someone else's hand. *Neuroreport* 13, 249–252.
- Bottini, G., Sedda, A., Ferre, E.R., Invernizzi, P., Gandola, M., Paulesu, E., 2009a. Productive symptoms in right brain damage. *Curr. Opin. Neurol.* 22, 589–593.
- Botvinick, M., Cohen, J., 1998. Rubber hands 'feel' touch that eyes see. *Nature* 391, 756.
- Carpenter, K., Berti, A., Oxbury, S., Molyneux, a j, Bisiach, E., Oxbury, j m, 1995. Awareness of and memory for arm weakness during intracarotid sodium amyltal testing. *Brain* 118, 243–251.
- Cereda, C., Ghika, J., Maeder, P., Bogousslavsky, J., 2002. Strokes restricted to the insular cortex. *Neurology* 59, 1950–1955.
- Critchley, M., 1953. *The Parietal Lobes*. Williams and Wilkins, Oxford.
- Daprati, E., Sirigu, A., Nico, D., 2010. Body and movement: consciousness in the parietal lobes. *Neuropsychologia* 48, 756–762.
- Doricchi, F., Thiebaut de Schotten, M., Tomaiuolo, F., Bartolomeo, P., 2008. White matter (dis)connections and gray matter (dys)functions in visual neglect: gaining insights into the brain networks of spatial awareness. *Cortex* 44, 983–995.
- D'Imperio, D., Tomelleri, G., Moretto, G., Moro, V., 2017. Modulation of somatoparaphrenia following left-hemisphere damage. *Neurocase* 23, 162–170.
- Ehrsson, H.H., 2007. The experimental induction of out-of-body experiences. *Science* 317, 1048.
- Ehrsson, H.H., Spence, C., Passingham, R.E., 2004. That 's my Hand! Activity in pre-motor cortex reflects feeling of ownership of a limb. *Science* 305, 875–877.
- Feinberg, T.E., 2013. Neuropathologies of the self and the right hemisphere: a window into productive personal pathologies. *Front. Hum. Neurosci.* 7, 472.
- Feinberg, T.E., Venneri, A., 2014. Somatoparaphrenia: evolving theories and concepts. *Cortex* 61, 74–80.
- Feinberg, T.E., Haber, L.D., Leeds, N.E., 1990. Verbal asomatognosia. *Neurology* 40, 1391–1391.
- Feinberg, T.E., Venneri, A., Simone, A.M., Fan, Y., Northoff, G., 2010. The neuroanatomy of asomatognosia and somatoparaphrenia. *J. Neurol. Neurosurg. Psychiatry* 81, 276–281.
- Folstein, M.F., Folstein, S.E., McHugh, P.R., 1975. Mini-mental state: a practical method for grading the cognitive state of patients for the clinician. *J. Psychiatr. Res.* 12, 189–198.
- Fossataro, C., Bruno, V., Gindri, P., Pia, L., Berti, A., Garbarini, F., 2018. Feeling touch on the own hand restores the capacity to visually discriminate it from someone else's hand: pathological embodiment receding in brain-damaged patients. *Cortex* 104, 207–219.
- Fotopoulou, A., Jenkinson, P.M., Tsakiris, M., Haggard, P., Rudd, A., Kopelman, M.D., 2011. Mirror-view reverses somatoparaphrenia: dissociation between first- and third-person perspectives on body ownership. *Neuropsychologia* 49, 3946–3955.
- Friston, K., 2010. The free-energy principle: a unified brain theory? *Nat. Rev. Neurosci.* 11, 127–138.
- Gandola, M., Invernizzi, P., Sedda, A., Ferrè, E.R., Sterzi, R., Sberna, M., et al., 2012. An anatomical account of somatoparaphrenia. *Cortex* 48, 1165–1178.
- Garbarini, F., Pia, L., Piedimonte, A., Rabuffetti, M., Gindri, P., Berti, A., 2013. Embodiment of an alien hand interferes with intact-hand movements. *Curr. Biol.* 23, R57–R58.
- Garbarini, F., Fonia, L., Fossataro, C., Pia, L., Gindri, P., Berti, A., 2014. Embodiment of others' hands elicits arousal responses similar to one's own hands. *Curr. Biol.* 24, R738–R739.
- Garbarini, F., Fossataro, C., Berti, A., Gindri, P., Romano, D., Pia, L., et al., 2015. When your arm becomes mine: pathological embodiment of alien limbs using tools modulates own body representation. *Neuropsychologia* 70, 402–413.
- Gazzaniga, M., 1989. Organization of the human brain. *Science* 245, 947–952.
- Gerstmann, J., 1942. Problem of imperception of disease and of impaired body territories with organic lesions: relation to body scheme and its disorders. *Arch. Neurol. Psychiatr.* 48, 890.
- Geschwind, N., 1965. Disconnection syndromes in animal and man. *Brain* 88, 237–294.
- Halligan, P.W., Marshall, J.C., Wade, D.T., 1993. Three arms: a case study of supernumerary phantom limb after right hemisphere stroke. *J. Neurol. Neurosurg. Psychiatry* 56 (2), 159–166.
- Halloran, P.M., 1946. Delusion of body scheme due to subdural hematoma. *Bull. Los Ang. Neurol. Soc.* 11, 88.
- Head, H., Holmes, G., 1911. Sensory disturbances from cerebral lesions. *Brain* 34, 102–254.
- Heaton, E.B., Navarro, C., Bressman, S., Brust, J.C., 1982. Subcortical neglect. *Neurology* 32, 776–778.
- Heilman, K.M., 1991. Anosognosia: possible neuropsychological mechanisms. In: *Awareness of Deficit after Brain Injury: Clinical and Theoretical Issues*, pp. 53–62.
- Invernizzi, P., Gandola, M., Romano, D., Zapparoli, L., Bottini, G., Paulesu, E., 2013. What is mine? Behavioral and anatomical dissociations between somatoparaphrenia and anosognosia for hemiplegia. *Behav. Neurol.* 26, 139–150.
- Ishida, H., Suzuki, K., Grandi, L.C., 2015. Predictive coding accounts of shared representations in parieto-insular networks. *Neuropsychologia* 70, 442–454.
- Jenkinson, P.M., Haggard, P., Ferreira, N.C., Fotopoulou, A., 2013. Body ownership and attention in the mirror: insights from somatoparaphrenia and the rubber hand illusion. *Neuropsychologia* 51, 1453–1462.
- Jenkinson, P.M., Moro, V., Fotopoulou, A., 2018. Definition: asomatognosia. *Cortex* 101, 300–301.
- Karnath, H.O., Berger, M.F., Küker, W., Rorden, C., 2004. The anatomy of spatial neglect based on voxelwise statistical analysis: a study of 140 patients. *Cerebr. Cortex* 14, 1164–1172.
- Lenggenhager, B., Tadi, T., Metzinger, T., Blanke, O., 2007. Video ergo sum: manipulating bodily self-consciousness. *Science* 317, 1095–1099.
- Levine, D.N., Calvanio, R., Rinn, W.E., 1991. The pathogenesis of anosognosia for hemiplegia. *Neurology* 41, 1770–1781.
- Longo, M.R., Schüür, F., Kammers, M.P.M., Tsakiris, M., Haggard, P., 2008. What is embodiment? A psychometric approach. *Cognition* 107, 978–998.
- Martinaud, O., Besharati, S., Jenkinson, P.M., Fotopoulou, A., 2017. Ownership illusions in patients with body delusions: different neural profiles of visual capture and disownership. *Cortex* 87, 174–185.
- McGonigle, D.J., Hänninen, R., Salenius, S., Hari, R., Frackowiak, R.S.J., Frith, C.D., 2002. Whose arm is it anyway? An fMRI case study of supernumerary phantom limb. *Brain* 125, 1265–1274.
- Meador, K.J., Loring, D.W., Feinberg, T.E., Lee, G.P., Nichols, M.E., 2000. Anosognosia and asomatognosia during intracarotid amobarbital inactivation. *Neurology* 55, 816–820.
- Miura, N., Takeda, A., Terao, S., Tanaka, H., Ishikawa, S., Mitsuma, T., 1996. Somatoparaphrenia caused by the lesion in the dominant cerebral hemisphere—a case report. *No Shinkei* 48, 275–279.
- Mondini, S., Mapelli, D., Vestri, A., Bisiacchi, P.S., 2003. *Esame Neuropsicologico Breve*. Milano.
- Moro, V., Zampini, M., Aglioti, S.M., 2004. Changes in spatial position of hands modify tactile extinction but not disownership of contralesional hand in two right brain-damaged patients. *Neurocase case Stud. Neuropsychol. neuropsychiatry, Behav. Neurol.* 10, 437–443.
- Moro, V., Pernigo, S., Tsakiris, M., Avesani, R., Edelmyst, N.M.J., Jenkinson, P.M., et al., 2016. Motor versus body awareness: voxel-based lesion analysis in anosognosia for hemiplegia and somatoparaphrenia following right hemisphere stroke. *Cortex* 83, 62–77.
- Newport, R., Gilpin, H.R., 2011. Multisensory disintegration and the disappearing hand trick. *Curr. Biol.* 21, R804–R805.
- Nightingale, S., 1982. Somatoparaphrenia: a case report. *Cortex* 18, 463–467.
- Pugnaghi, M., Molinari, M., Panzetti, P., Nichelli, P.F., Zamboni, G., 2011. 'My sister's hand is in my bed': a case of somatoparaphrenia. *Neurol. Sci.* 10–12.
- Rohde, M., Di Luca, M., Ernst, M.O., 2011. The rubber hand illusion: feeling of ownership and proprioceptive drift do not go hand in hand. *PLoS One* 6, e21659.
- Romano, D., Gandola, M., Bottini, G., Maravita, A., 2014. Arousal responses to noxious stimuli in somatoparaphrenia and anosognosia: clues to body awareness. *Brain* 137, 1213–1223.
- Romano, D., Caffa, E., Hernandez-Arieta, A., Brugger, P., Maravita, A., 2015a. The Robot Hand Illusion: inducing proprioceptive drift through visuo-motor congruency. *Neuropsychologia* 70, 414–420.
- Romano, D., Sedda, A., Brugger, P., Bottini, G., 2015b. Body ownership: when feeling and knowing diverge. *Conscious. Cognit.* 34, 140–148.
- Ronchi, R., Rode, G., Cotton, F., Farnè, A., Rossetti, Y., Jacquin-Courtois, S., 2013. Remission of anosognosia for right hemiplegia and neglect after caloric vestibular stimulation. *Restor. Neurol. Neurosci.* 31, 19–24.
- Salvato, G., Gandola, M., Veronelli, L., Agostoni, E.C., Sberna, M., Corbo, M., Bottini, G., et al., 2016. The spatial side of somatoparaphrenia: a case study. *Neurocase* 22 (2), 154–160.
- Schiff, N.D., Pulver, M., 1999. Does vestibular stimulation activate thalamocortical mechanisms that reintegrate impaired cortical regions? *Proc. Biol. Sci.* 266, 421–423.
- Starkstein, S.E., Berthier, M.L., Fedoroff, P., Price, T.R., Robinson, R.G., 1990. Anosognosia and major depression in 2 patients with cerebrovascular lesions. *Neurology* 40, 1380–1380.
- van Stralen, H.E., van Zandvoort, M.J., Kappelle, L.J., Dijkerman, H.C., 2013. The rubber hand illusion in a patient with hand disownership. *Perception* 42 (9), 991–993.
- Tsakiris, M., 2010. My body in the brain: a neurocognitive model of body-ownership. *Neuropsychologia* 48, 703–712.
- Tsakiris, M., Fotopoulou, A., 2008. Is my body the sum of online and offline body-representations? *Conscious. Cognition* 17, 1317–20–3.
- Tsakiris, M., Prabhu, G., Haggard, P., 2006. Having a body versus moving your body: how agency structures body-ownership. *Conscious. Cognit.* 15, 423–432.
- Vallar, G., 1998. Spatial hemineglect in humans. *Trends Cognit. Sci.* 2, 87–97.
- Vallar, G., Coslett, H.B., 2018. *The Parietal Lobe*. Elsevier.
- Vallar, G., Perani, D., 1986. The anatomy of unilateral neglect after right-hemisphere stroke lesions. A clinical/CT-scan correlation study in man. *Neuropsychologia* 24, 609–622.
- Vallar, G., Ronchi, R., 2009. Somatoparaphrenia: a body delusion. A review of the neuropsychological literature. *Exp. Brain Res.* 192, 533–551.
- de Vignemont, F., 2010. Body schema and body image—pros and cons. *Neuropsychologia* 48, 669–680.
- de Vignemont, F., 2011. Embodiment, ownership and disownership. *Conscious. Cognition* 20, 82–93.
- Weinstein, E.A., Kahn, R.L., 1950. The syndrome of anosognosia. *Arch. Neurol. Psychiatr.* 64, 772–791.