



Intracranial Penetrating Trauma Caused by Fishing Sinker

Seckin Aydin

Key words

- Fishing sinker
- Foreign body
- Intracranial penetrating trauma
- Sports-related injury

Abbreviations and Acronyms

- CT:** Computed tomography
GCS: Glasgow Coma Scale
IPT: Intracranial penetrating trauma

Department of Neurosurgery, University of Health Sciences, Okmeydanı Training and Research Hospital, Istanbul, Turkey

To whom correspondence should be addressed:

Seckin Aydin, M.D.

[E-mail: seckin047@hotmail.com]

Citation: *World Neurosurg.* (2019) 129:237-240.

<https://doi.org/10.1016/j.wneu.2019.06.051>

Journal homepage: www.journals.elsevier.com/world-neurosurgery

Available online: www.sciencedirect.com

1878-8750/\$ - see front matter © 2019 Elsevier Inc. All rights reserved.

INTRODUCTION

Intracranial penetrating traumas (IPTs) account for 0.4% of all cranial traumas.^{1,2} Although gunshot wounds are the most common causes of IPTs, traumas induced at low penetrating speeds are rarely encountered and usually result in more restricted damage.³ Here, we report the clinical features and surgical outcomes of a patient with a low-energy IPT caused by an unexpected object.

CASE REPORT

A 37-year-old male presented with an IPT to our emergency department. The patient had a right periorbital ecchymosis, conjunctival chemosis, and subconjunctival hemorrhage with limited movement of the right eye. Although ophthalmologic examination revealed a dilated, fixed right pupil and an optic disc with blurry margins, the globe was normotonic with normal integrity and had not ruptured. The patient was conscious, and the Glasgow Coma Scale (GCS) score was 15. Neurologic examination revealed only right hemiparesis with manual muscle strength grade 2. Unenhanced brain

■ **BACKGROUND:** Intracranial penetrating traumas (IPTs) are rarely encountered in neurosurgery practice. Here, we report the case of a patient with orbital and cranial trauma caused by an unexpected object.

■ **CASE DESCRIPTION:** A 37-year-old male presenting with a right orbital penetrating injury was referred to our emergency department. Neurologic examination of the patient revealed right periorbital ecchymosis, a dilated and fixed right pupil, and right hemiparesis. Cranial computed tomography showed fractures of the right orbital medial wall and the anterior skull base, as well as bifrontal and left parietal intracerebral hemorrhage accompanied by a metallic foreign body artifact. Emergency left frontoparietal decompressive craniectomy was performed, and the foreign body, identified as a fishing sinker, was removed. No additional postoperative complications were observed, and cranioplasty was performed 6 months postoperatively.

■ **CONCLUSIONS:** IPTs have high morbidity and mortality rates. Early surgical intervention is often the first treatment option. Intracranial injury caused by a fishing sinker is an extremely rare low-energy intracranial penetrating trauma, and in the literature, this is the first reported case in which the patient survived.

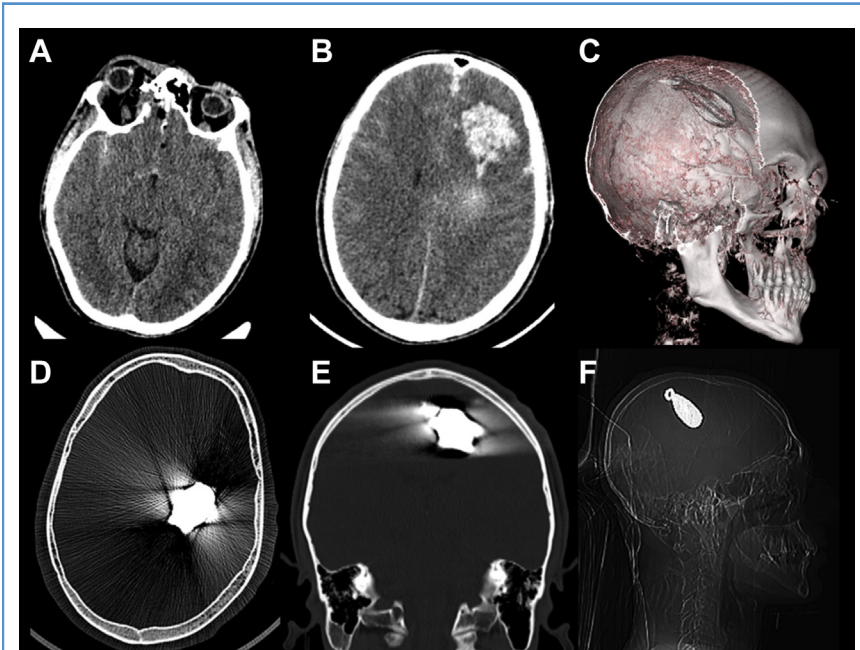


Figure 1. (A) Brain computed tomography (CT) image shows right medial orbital wall bone defect in the axial plane. (B) Brain CT image shows left intracerebral hematoma in the axial plane. (C) Reconstructed brain CT image shows the shape of fishing sinker and initial position. (D) Brain CT image shows metallic artifact of fishing sinker in the axial plane, bone window. (E) Brain CT image shows metallic artifact of fishing sinker in the coronal plane, bone window. (F) Lateral-view roentgenograph shows the initial position of the intracranial fishing sinker.

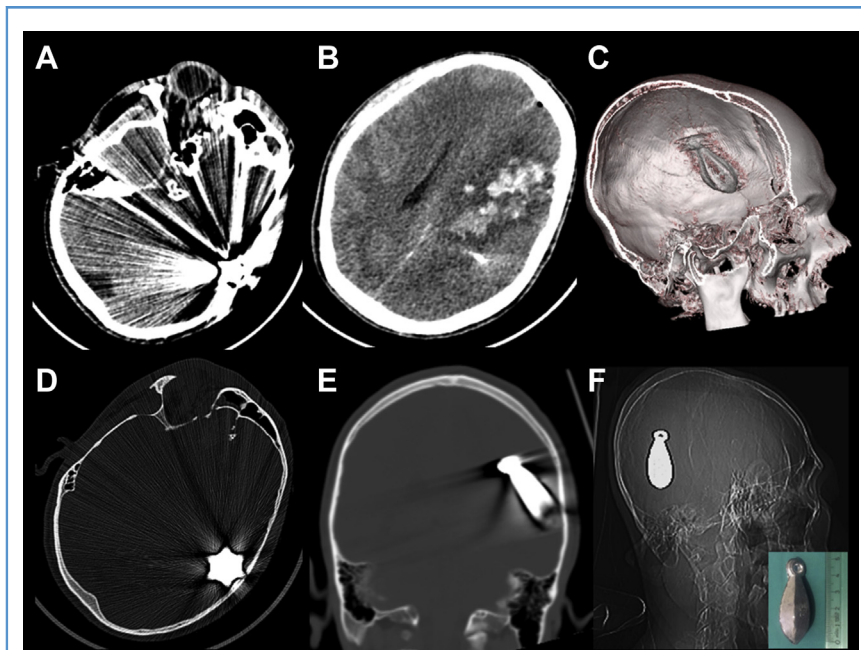


Figure 2. (A) Brain computed tomography (CT) image shows right orbital wall bone defect and metallic artifact of fishing sinker in the axial plane. (B) Brain CT image shows left intracerebral hematoma in the axial plane. (C) Reconstructed brain CT image shows the shape of fishing sinker and second position. (D) Brain CT image shows metallic artifact of fishing sinker in the axial plane, bone window. (E) Brain CT image shows metallic artifact of fishing sinker in the coronal plane, bone window. (F) Lateral-view roentgenograph shows the second position of intracranial fishing sinker and a photograph in the bottom right corner showing the fishing sinker.

computed tomography (CT) showed fractures of the right orbital medial wall and the anterior skull base in addition to bifrontal and left parietal intracerebral

hemorrhage with a hyperdensity artifact due to the presence of a metallic foreign body located deep in the left parietal lobe (Figure 1). During surgical preparations,

the patient's neurologic status suddenly deteriorated with a GCS score of 7 and unenhanced brain CT was repeated. It was observed that the metallic foreign body, identified as a fishing sinker, had shifted downward into the parenchyma under the influence of gravity (Figure 2). The patient was subsequently taken to the operating room, and an emergency left frontoparietal decompressive craniectomy was performed. An intracerebral hematoma was evacuated, and the fishing sinker was removed (Figure 3). The bone flap was inserted into a subcutaneous pocket prepared in the right abdominal wall. In the postoperative period, no additional neurologic and/or cognitive deterioration was observed, and there was no additional complication. After gradual recovery of the patient's neurologic status, the patient was discharged with a GCS score of 15 on the postoperative 14th day. The right hemiparesis of the patient was improved by physical rehabilitation, and at the postoperative 6th month follow-up, at the time of cranioplasty, the right-sided muscle strength grade was 4. Cranioplasty was performed using the patient's own bone flap retrieved from the subcutaneous pocket in the right abdominal wall (Figure 4). The right eye was conservatively treated by the ophthalmology department.

DISCUSSION

Various objects and mechanisms play a role in the etiology of IPTs.^{4,5} IPTs can be divided into 2 types: high energy and low energy. Gunshot wounds, the most common cause of IPTs, are an example of high-energy IPT.⁶ On the other hand, injuries associated with unexpected objects such as fishing sinkers are examples of low-energy IPT, which are comparatively less common.^{7,8}

Among sports-related ocular injuries, fishing-related ones are the second most common and result in a severe loss of visual acuity in approximately 20.83% patients.⁹ However, these traumas are usually limited to the ocular region, and ocular traumas accompanied by an intracranial pathology are rare.¹⁰⁻¹² In addition, fishing-related injuries are reportedly localized to the maxillofacial region and similar to fishing-related

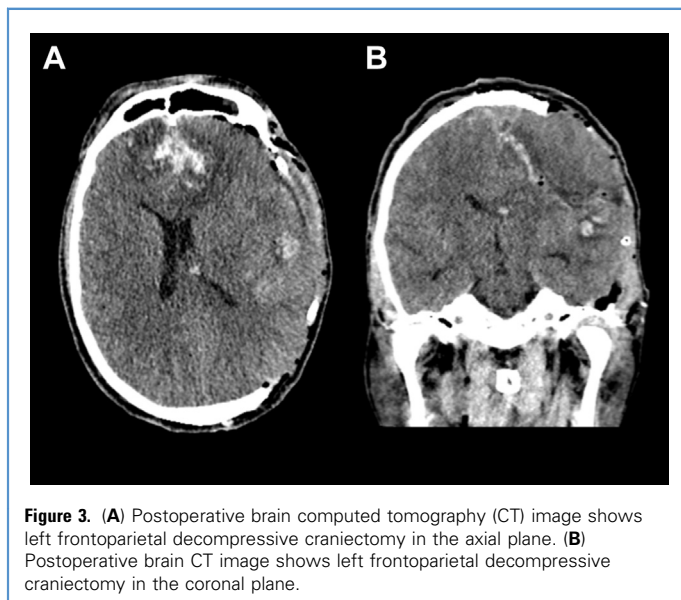


Figure 3. (A) Postoperative brain computed tomography (CT) image shows left frontoparietal decompressive craniectomy in the axial plane. (B) Postoperative brain CT image shows left frontoparietal decompressive craniectomy in the coronal plane.

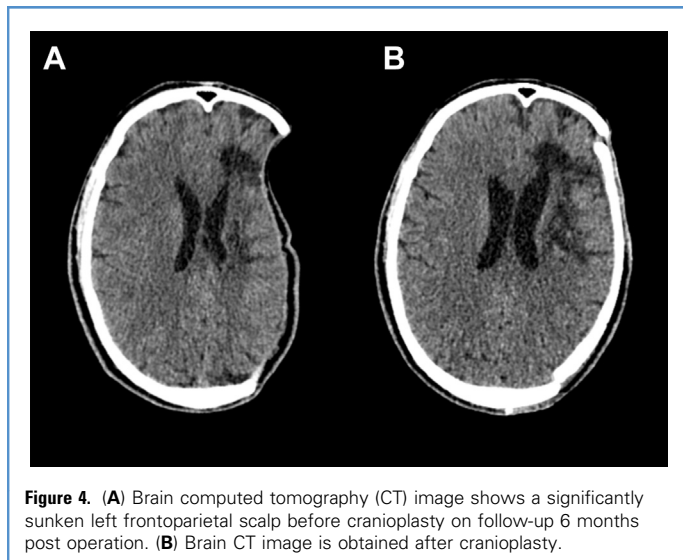


Figure 4. (A) Brain computed tomography (CT) image shows a significantly sunken left frontoparietal scalp before cranioplasty on follow-up 6 months post operation. (B) Brain CT image is obtained after cranioplasty.

ocular injuries rarely extend to the intracranial region.^{13,14}

In previously published literature, only 1 case of a patient who developed intracranial hemorrhage with IPT caused by a fishing sinker has been reported. The patient was evaluated in an emergency department, and the case was graded with a score of 3 according to the Glasgow Coma Scale, warranting no further neurosurgical intervention. Thereafter, the patient was declared brain dead.¹⁵ No further observations could be made in the patient regarding surgical treatment and follow-up. To the best of our knowledge, this is the first reported case of a patient who developed intracranial hemorrhage with IPT caused by a fishing sinker and survived. We believe that this makes the case particularly noteworthy.

The most important reason underlying the patient's survival is that the fishing sinker did not cause any damage to the critical neural and vascular structures in the brain. This was remarkable given that the heavy object freely shifted intracranially under the influence of gravity.

Thus in such cases, early surgical intervention is recommended even if the patient has a poor prognosis.^{16,17} Stone et al¹⁸ suggested operating on patients who have a GCS score of 4–7 points without hypotension, even if their pupils are nonreactive. Also, Kelly et al¹⁹ considered that aggressive treatment should be performed when there is

evidence of motor or brainstem function. Postoperative complications, such as brain edema and herniation risk, were also prevented by administering decompressive craniectomy according to guidelines prepared by the Brain Trauma Foundation.²⁰

In the long term, several cranioplasty techniques can be employed to correct the bone defect following decompressive craniectomy.²¹ For the postoperative cranioplasty in the present case, we used the bone flap, which was previously placed in a subcutaneous pocket in the abdominal wall. Currently, the patient continues to be followed up by our neurosurgery and ophthalmology outpatient clinics.

An interesting observation made in our patient and in the other patient who previously suffered an IPT caused by a fishing sinker was that such a large object did not cause the globe to rupture as it entered the intracranial region from the ocular region. Although this observation supports the classification of such an injury as a low-energy IPT, it also indicates that the globe has high resistance to blunt trauma of this type. Weaver et al²² have previously reported that cylindrical projectiles cause less stress and pressure on the eye than spherical ones. Therefore it may be hypothesized that the sinker, which had a teardrop shape, resulted in a cylindrical projectile that did not cause the globe to rupture.

Intracranial penetrating injuries that may not be detected during gross examination should be considered for patients presenting with head trauma to the emergency department. Accordingly, the necessary radiologic examinations should be conducted and the possible presence of intracranial foreign bodies should be detected. Similarly, intracranial penetrating injuries caused by foreign bodies should also be considered in patients whose neurologic examinations are incompatible with their external findings.

It should be foreseen that the objects entering the intracranial region and freely standing within the parenchyma may shift under the influence of gravity, causing deterioration in the patient's clinical condition. If this occurs, the patient should be promptly directed for surgical intervention.

CONCLUSIONS

In emergency departments, IPTs are often associated with high morbidity and mortality rates. Patients with IPTs rarely present without any damage to critical intracranial structures, and application of appropriate treatment approaches can be lifesaving. In this article, we have reported the case of a patient who developed intracranial hemorrhage with IPT caused by a fishing sinker and have provided details regarding the treatment and subsequent follow-up.

ACKNOWLEDGMENT

The author thanks Mr. Sirzat Bek for his help.

REFERENCES

1. Santiago LA, Oh BC, Dash PK, Holcomb JB, Wade CE. A clinical comparison of penetrating and blunt traumatic brain injuries. *Brain Inj.* 2012; 26:107-125.
2. Liu WH, Chiang YH, Hsieh CT, Sun JM, Hsia CC. Transorbital penetrating brain injury by branchlet: a rare case. *J Emerg Med.* 2011;41:482-485.
3. Chen PC, Tsai SH, Chen YL, Liao WI. Post-traumatic cerebral infarction following low-energy penetrating craniocerebral injury caused by a nail. *J Korean Neurosurg Soc.* 2014;55:293-295.
4. Kazim SF, Shamim MS, Tahir MZ, Enam SA, Waheed S. Management of penetrating brain injury. *J Emerg Trauma Shock.* 2011;4:395-402.
5. Vakil MT, Singh AK. A review of penetrating brain trauma: epidemiology, pathophysiology, imaging

- assessment, complications, and treatment. *Emerg Radiol.* 2017;24:301-309.
6. Solmaz I, Kural C, Temiz C, et al. Traumatic brain injury due to gunshot wounds: a single institution's experience with 442 consecutive patients. *Turk Neurosurg.* 2009;19:216-223.
 7. Agrawal A, Reddy VU, Kumar SS, Hegde KV, Rao GM. Transorbital orbitocranial penetrating injury with an iron rod. *Craniofacial Trauma Reconstr.* 2016;9:145-148.
 8. Ferraz VR, Aguiar GB, Vitorino-Araujo JL, Badke GL, Veiga JC. Management of a low-energy penetrating brain injury caused by a nail. *Case Rep Neurol Med.* 2016;2016:4371367.
 9. Alfaro DV 3rd, Jablon EP, Rodriguez Fontal M, et al. Fishing-related ocular trauma. *Am J Ophthalmol.* 2005;139:488-492.
 10. Malhotra R, Tappin M, Olver JM. Angler's fishing line sinker causing rupture of globe and medial wall fracture. *Eye (Lond).* 1999;13:260-262.
 11. Ding X, Liu Z, Lin Y, Yang Y. Perforating ocular fishhook trauma: a case report. *Clin Exp Optom.* 2018;101:297-298.
 12. Doucet TW, Harper DW, Rogers J. Penetrating orbital foreign body with intracranial involvement. *Ann Ophthalmol.* 1983;15:325-327.
 13. Erisen L, Basut O, Coskun H, Hizalan I. An unusual penetrating facial injury due to a fishing-line sinker. *J Oral Maxillofac Surg.* 2001;59:945-947.
 14. Ribeiro AL, de Vasconcellos HG, Pinheiro Jde J. Unusual fishing harpoon injury of the maxillofacial region in a child. *Oral Maxillofac Surg.* 2009;13:243-246.
 15. Seitelman E, Premo J, Cardoza S, Charbel I, Angus LD. Young man with fishing injury. Intracranial fishing line sinker. *Ann Emerg Med.* 2009;54:854.
 16. Werner JK Jr, Armonda R, Manley GT, Rosenthal G. Management of penetrating brain injury. In: Schmidek HH, Sweet WH, eds. *Operative Neurosurgical Techniques.* 6th ed. New York, NY: Grune & Stratton; 2012:1619-1628.
 17. Bell RS, Mossop CM, Dirks MS, et al. Early decompressive craniectomy for severe penetrating and closed head injury during wartime. *Neurosurg Focus.* 2010;28:E1.
 18. Stone JL, Lichtor T, Fitzgerald LF. Gunshot wounds to the head in civilian practice. *Neurosurgery.* 1995;37:1104-1112.
 19. Kelly DF, Nikas DL, Becker DP. Diagnosis and treatment of moderate and severe head injuries in adults. In: Youmans J, ed. *Neurosurgical Surgery.* 4th ed. Philadelphia, PA: WB Saunders; 1996:1618-1707.
 20. Carney N, Totten AM, O'Reilly C, et al. Guidelines for the management of severe traumatic brain injury, fourth edition. *Neurosurgery.* 2017;80:6-15.
 21. Aydin S, Kucukyuruk B, Abuzayed B, Aydin S, Sanus GZ. Cranioplasty: review of materials and techniques. *J Neurosci Rural Pract.* 2011;2:162-167.
 22. Weaver AA, Kennedy EA, Duma SM, Stitzel JD. Evaluation of different projectiles in matched experimental eye impact simulations. *J Biomech Eng.* 2011;133:031002.

Conflict of interest statement: We confirm that there are no conflicts of interest associated with this publication, and there has been no significant financial support for this work that could have influenced its outcome.

Received 20 April 2019; accepted 6 June 2019

Citation: World Neurosurg. (2019) 129:237-240.

<https://doi.org/10.1016/j.wneu.2019.06.051>

Journal homepage: www.journals.elsevier.com/world-neurosurgery

Available online: www.sciencedirect.com

1878-8750/\$ - see front matter © 2019 Elsevier Inc. All rights reserved.