





# A Rare Case of Prolonged Ictal Aphasia

Roohi Katyal, M.D.<sup>1</sup>; Eduardo De Sousa, M.D.<sup>2</sup>; Fahd Sultan, M.D.<sup>1</sup>

<sup>1</sup>University of Oklahoma Health Sciences Center  
Oklahoma City, Oklahoma

<sup>2</sup>Mercy Neurology Neuroscience Institute  
Oklahoma City, Oklahoma

**ABSTRACT.** *Aphasia is commonly seen in focal brain lesions. Prolonged aphasia from an ictal state is rarely reported. We report the case of a 62-year-old man with focal motor status epilepticus manifested initially as episodic right cheiro-oral clonic movements with preserved awareness and expressive aphasia for 48 hours. EEG showed left frontal and central lateralized periodic discharges (LPDs) without plus features (rhythmicity, overlying fast) and electrographic seizures that correlated with right clonic movements. Treatment with two seizure medications (levetiracetam and lacosamide) resulted in complete electrographic and clinical resolution of his symptoms, including aphasia. In this case, aphasia was determined to be an ictal semiology, as patient had complete resolution of his symptoms supported by a normal EEG after receiving seizure medications. We suggest keeping high suspicion for an ictal process in patients with sudden-onset aphasia supported by EEG findings of LPDs.*

**KEY WORDS.** *Aphasia, ictal, lateralized periodic discharges (LPDs).*

## INTRODUCTION

Aphasia is commonly seen in focal brain lesions such as ischemic and hemorrhagic stroke, primary or metastatic tumors, and traumatic brain injury (Goodglass 1993). Prolonged aphasia from an ictal state is rarely reported (Benatar 2002; Patil and Oware 2012). The diagnosis is based on specific EEG findings, which vary from lateralized periodic discharges (LPDs) to electrographic seizures (Herskovitz and Schiller 2012). Brain imaging may be helpful in finding the underlying cause (Benatar 2002).

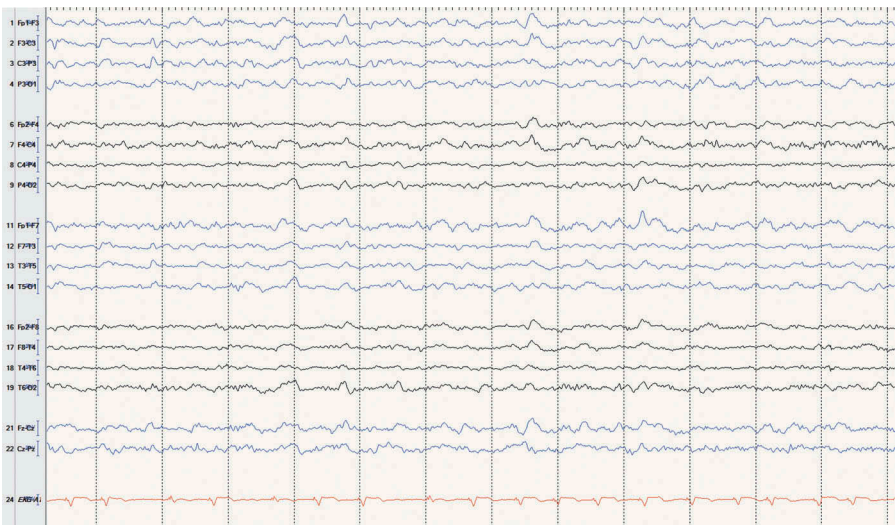
Corresponding Author's E-mail: [roohi-katyal@ouhsc.edu](mailto:roohi-katyal@ouhsc.edu); [roohikatyal02@gmail.com](mailto:roohikatyal02@gmail.com)

Received: February 11, 2019. Accepted for publication: May 7, 2019.

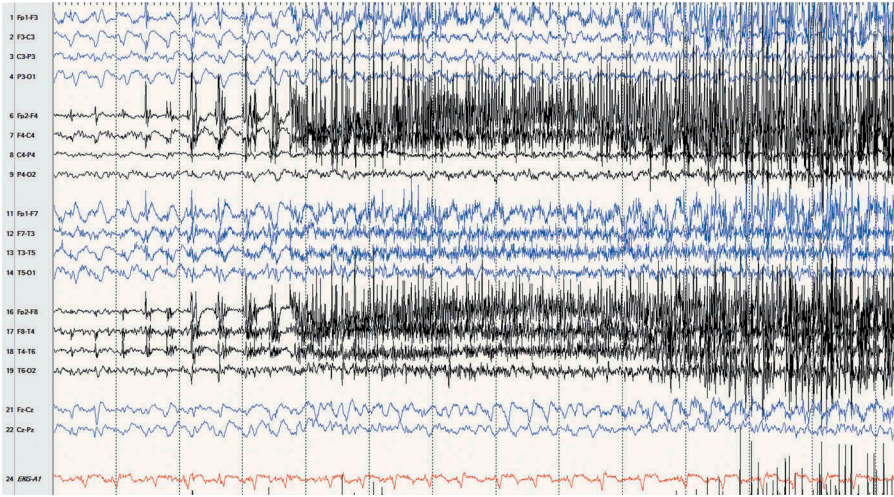
Color versions of one or more of the figures in the article can be found online at [www.tandfonline.com/utnj](http://www.tandfonline.com/utnj).

## CASE REPORT

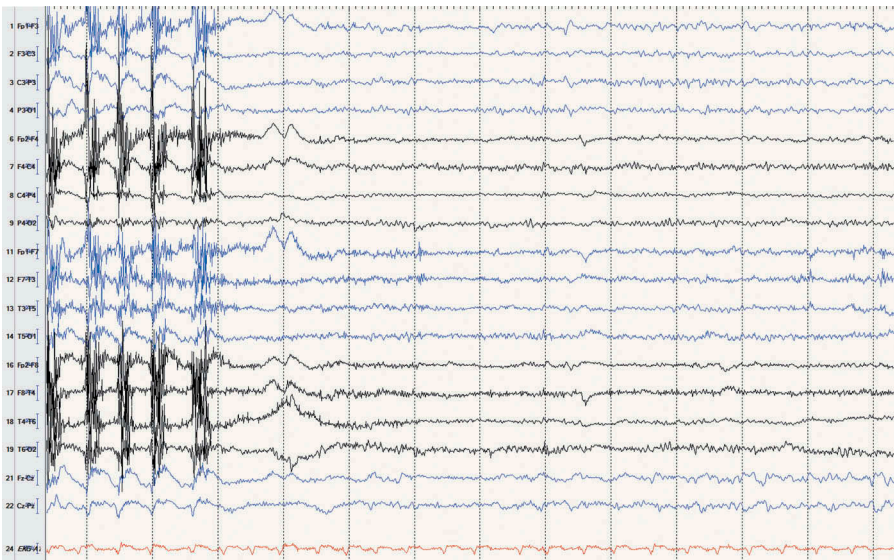
A 62-year-old right-handed man with history of pancreatic cancer with metastasis to liver, sick sinus syndrome status post pacemaker (which was magnetic resonance imaging [MRI] incompatible), and no prior history of seizures was admitted for management of septic shock secondary to urosepsis. Neurology was consulted for a new-onset focal seizure manifested by ~30-second episode of right cheiro-oral (hand and hemimouth) clonic movements along with intermittent expressive aphasia. He was given levetiracetam intravenous load of 20 mg/kg (3000 mg) after the first episode, followed by maintenance 750 mg twice a day (BID). As part of the work-up, a computerized tomography (CT) scan of the head with and without contrast was obtained twice, 2 days apart, both negative for any focal lesion that could explain his seizures. Routine EEG captured two seizures that co-related clinically with right cheiro-oral movements. It showed frequent left frontocentral sharp waves. No LPDs were seen during this recording (Figures 1–5). Due to examination findings of persistent expressive aphasia, a continuous video-EEG was obtained, which was started approximately 1 hour after the completion of routine EEG and showed left frontocentral LPDs. LPDs were seen approximately 10 minutes after being on continuous video-EEG and captured focal motor seizure with clinical right face and arm rhythmic jerking, following which patient was loaded with 10 mg/kg (1500 mg) of levetiracetam intravenously and maintenance dose was increased to 1500 mg BID.



**FIG. 1.** EEG epoch just before the first seizure on routine EEG demonstrating drowsy state and no LPDs. Sensitivity: 7  $\mu$ V/mm. High frequency filter: 70 Hz. Low frequency filter: 1 Hz.

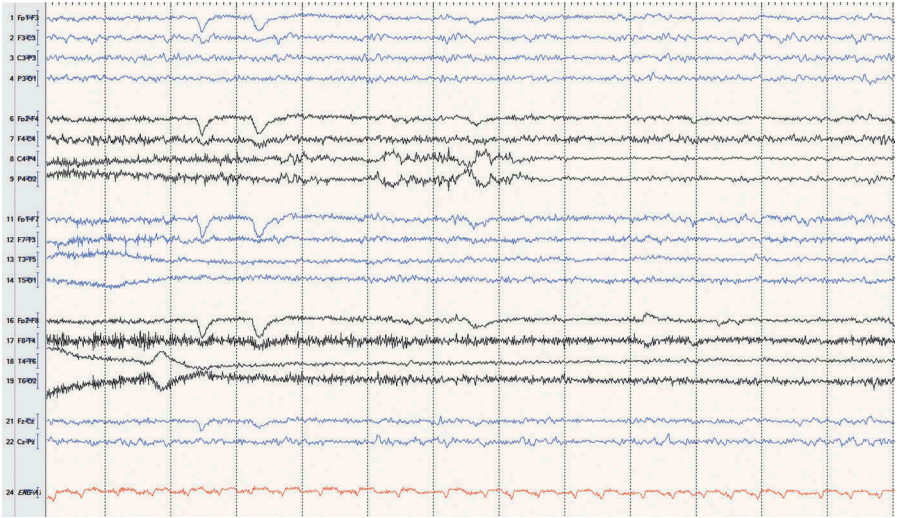


**FIG. 2.** EEG epoch demonstrating focal seizure with onset in left hemisphere and spread to bilateral hemispheres. Sensitivity: 7  $\mu\text{V}/\text{mm}$ . High frequency filter: 70 Hz. Low frequency filter: 1 Hz.

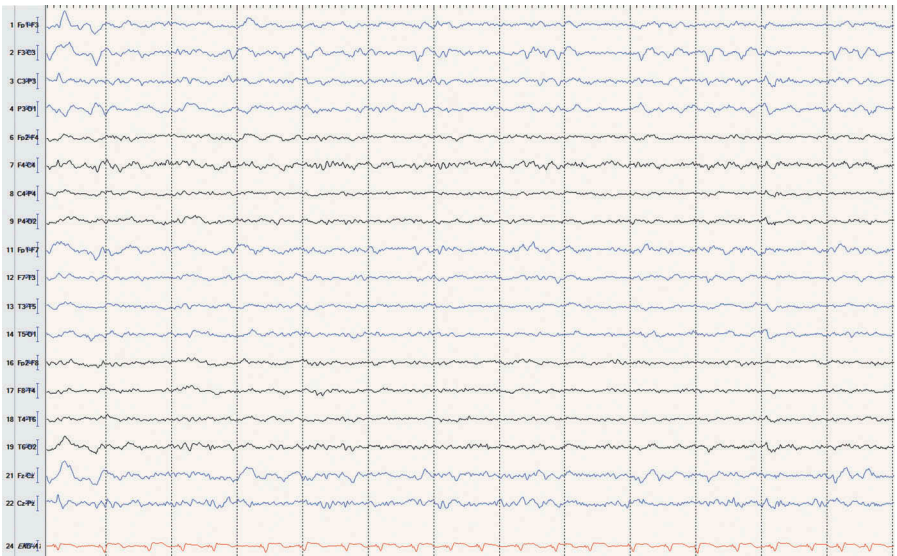


**FIG. 3.** EEG epoch demonstrating ictal offset, followed by symmetric background without periodic discharges. Sensitivity: 7  $\mu\text{V}/\text{mm}$ . High frequency filter: 70 Hz. Low frequency filter: 1 Hz.

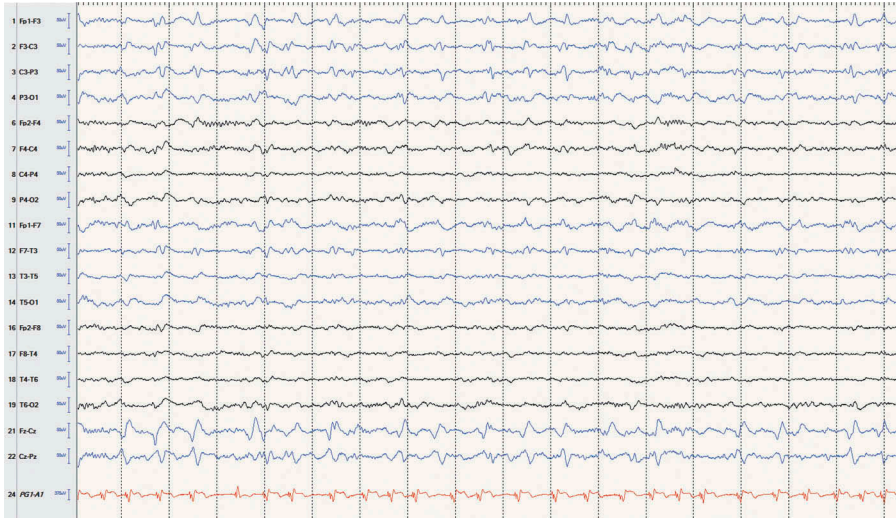




**FIG. 4.** EEG epoch during routine EEG demonstrating awake background without LPDs. Sensitivity: 7  $\mu\text{V}/\text{mm}$ . High frequency filter: 70 Hz. Low frequency filter: 1 Hz.



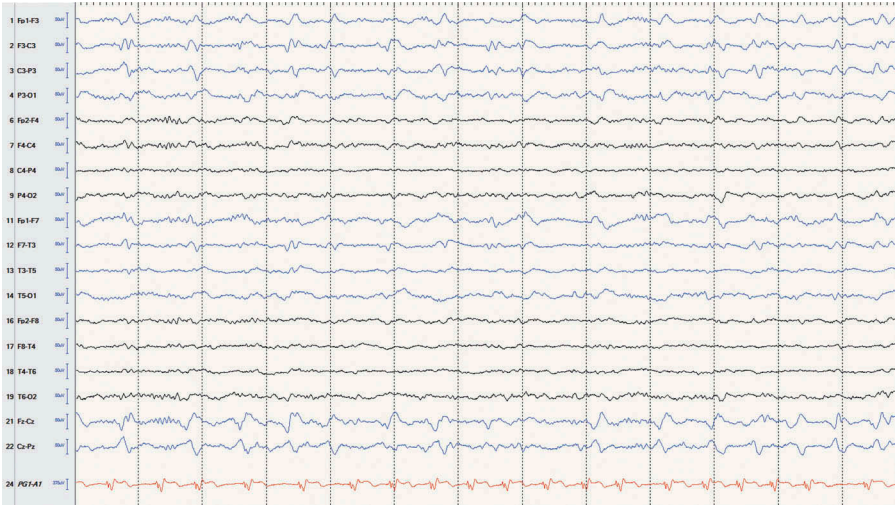
**FIG. 5.** EEG epoch demonstrating left frontocentral sharp waves on routine EEG. Sensitivity: 7  $\mu\text{V}/\text{mm}$ . High frequency filter: 70 Hz. Low frequency filter: 1 Hz.



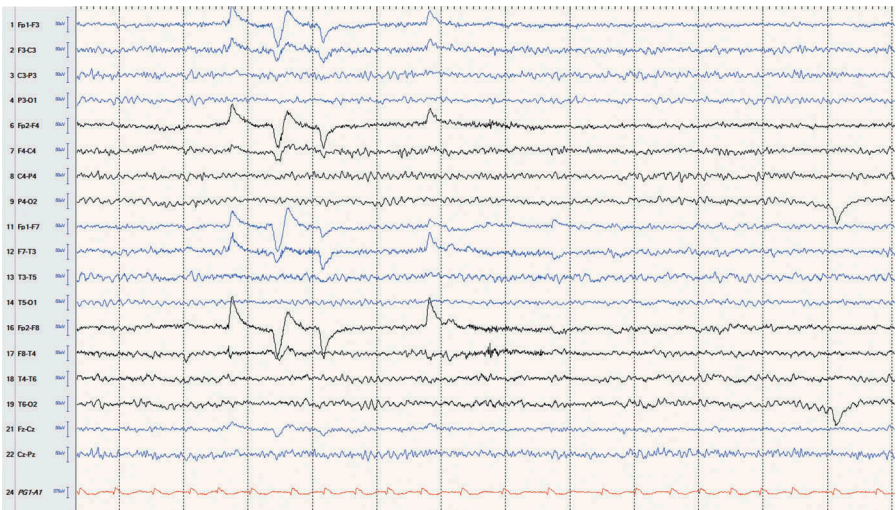
**FIG. 6.** EEG epoch demonstrating left frontocentral lateralized periodic discharges (LPDs) prior to patient developing focal motor status epilepticus. Sensitivity:  $7 \mu\text{V}/\text{mm}$ . High frequency filter: 70 Hz. Low frequency filter: 1 Hz.

The patient initially improved after the levetiracetam reload, became more alert, followed commands on the left upper and lower extremities consistently, and had postictal paresis on the right upper extremity. However, he continued to have expressive aphasia, which was seen on video-EEG as LPDs originating in the left frontocentral region (Figure 6). These were thought to lie on the ictal-interictal continuum given lack of evolution, low frequency, and lack of plus features.

Approximately 20 hours later, he developed depressed awareness along with focal motor status epilepticus. This was treated with intravenous lorazepam ( $4 \text{ mg} \times 2$  doses) and fosphenytoin  $20 \text{ mg}/\text{kg}$  ( $3100 \text{ mg}$ ) intravenously, following which the patient became hypoxic, required intubation, and was transferred to the neurosciences intensive care unit (ICU) where he was started on a second seizure medication, lacosamide,  $200 \text{ mg}$  BID. He remained on continuous video-EEG for another 18 hours, which again demonstrated left frontocentral LPDs without plus features (Figure 7). While in the ICU, lumbar puncture was done, which demonstrated a nonspecific, mildly elevated protein of  $59 \text{ mg}/\text{dL}$  (normal range:  $15\text{--}45 \text{ mg}/\text{dL}$ ). Remaining cerebrospinal fluid (CSF) findings, including CSF cell count, Gram stain and culture, paraneoplastic panel, and flow cytology, were all negative. His examination continued to improve after addition of the second seizure medication. Post extubation on day 6 of being transferred to ICU, the patient was noted to have a normal language examination. EEG was repeated, which was normal (Figure 8).



**FIG. 7.** EEG epoch demonstrating left frontocentral lateralized periodic discharges (LPDs) post intubation and sedation. Sensitivity:  $7 \mu\text{V}/\text{mm}$ . High frequency filter: 70 Hz. Low frequency filter: 1 Hz.



**FIG. 8.** EEG epoch showing normal awake state as seen on the repeat routine EEG. No epileptiform discharges were captured during this recording. Sensitivity:  $7 \mu\text{V}/\text{mm}$ . High frequency filter: 70 Hz. Low frequency filter: 1 Hz.

## DISCUSSION

Speech disturbances due to dominant hemisphere seizures are not a rare occurrence (Serafetinides and Falconer 1963; Gabr et al. 1989). In one study of 35 patients, abnormal speech was seen in 51.4% of patients, either ictally or postictally. Clinically, this can manifest as speech arrest, dysphasia, and dysarthria (Gabr et al. 1989) and can be associated with negative and positive motor symptoms (Benatar 2002). In our case, the patient had intermittent episodes of right cheiro-oral movements associated with ictal aphasia. Exact prevalence of aphasia as an ictal semiology is currently unknown. It is possible that this is due to underreporting of cases, due to lack of formal language testing (inability to name objects, impaired repetition, lack of comprehension, paraphasic errors) in a patient with aphasia associated with motor features (Benatar 2002).

Differential diagnosis of ictal aphasia includes any structural or metabolic damage to the language center, inflammation, migraine, and a postictal state. Sudden-onset aphasia with negative brain imaging with or without other epileptic features should raise concern for an ictal process (Flügel et al. 2015). Duration of ictal aphasia is highly variable and has been reported to range between days (Herskovitz and Schiller 2012) to weeks. Chung et al. (2002) presented a case of progressive ictal aphasia that developed over 5 weeks.

Several studies with cortical stimulation have supported the concept that an increase in brain electrical activity in certain areas can generate language dysfunction. A study done by Lüders et al. (1991) using stimulation of subdural electrodes at undersurface of dominant temporal lobe reported speech arrest or slowing down of speech in 8 out of 22 patients. In another study done by Schaeffer and colleagues in 45 patients (Schaffler et al. 1996), language deficits were identified with electrical stimulation over left lateral cortex.

Diagnosis of ictal aphasia is usually based on clinical presentation along with EEG recording, preferably during the episode and brain imaging (Benatar 2002). Dong et al. (2009) reported detection of hypermetabolism in left frontotemporal area on positron emission tomography (PET) scan in patients with ictal aphasia with EEG findings of left temporal irregular delta activity. A wide range of EEG findings have been reported with ictal aphasia. These range from electrographic seizures to lateralized periodic discharges (LPDs) (Herskovitz and Schiller 2012). In a study evaluating morphological patterns of LPDs, patients with a blunt delta pattern on EEG were significantly less likely to develop seizures on continuous EEG, whereas patients with LPDs with rhythmicity were at significantly higher risk for developing seizures (Newey et al. 2017).

Our case was unique in that ictal aphasia was associated with LPDs without plus features (rhythmicity, overlying fast). However, given the clinical features of the patient in our case and resolution of symptoms and the EEG finding of LPDs with addition of a second seizure medication, we concluded that the patient's aphasia was



an ictal phenomenon seen on EEG as LPDs. Thus, we suggest keeping high suspicion for an ictal process in patients with sudden-onset aphasia supported by EEG findings of LPDs.

## REFERENCES

- Benatar M. 2002. Ictal aphasia. *Epilepsy Behav.* 3(5):413–419.
- Chung PW, Seo DW, Kwon JC, Kim H, Na DL. 2002. Nonconvulsive status epilepticus presenting as a subacute progressive aphasia. *Seizure.* 11(7):449–454.
- Dong C, Sriram S, Delbeke D, Al-Kaylani M, Arain AM, Singh P, McLean MJ, Abou-Khalil B. 2009. Aphasic or amnesic status epilepticus detected on PET but not EEG. *Epilepsia.* 50:251–255.
- Flügel D, Kim OC, Felbecker A, Tettenborn B. 2015. De novo status epilepticus with isolated aphasia. *Epilepsy Behav.* 49:198–202.
- Gabr M, Lüders H, Dinner D, Morris H, Wyllie E. 1989. Speech manifestations in lateralization of temporal lobe seizures. *Ann Neurol.* 25:82–87.
- Goodglass H. 1993. *Understanding aphasia.* San Diego (CA): Academic Press. p. 104.
- Herskovitz M, Schiller Y. 2012. Prolonged ictal aphasia: a diagnosis to consider. *J Clin Neurosci.* 19:1605–1606.
- Lüders H, Lesser RP, Hahn J, Dinner DS, Morris HH, Wyllie E, Godoy J. 1991. Basal temporal language area. *Brain.* 114:743–754.
- Newey CR, Sahota P, Hantus S. 2017 Jul. Electrographic features of lateralized periodic discharges stratify risk in the interictal-ictal continuum. *J Clin Neurophysiol.* 34(4):365–369.
- Patil B, Oware A. 2012. De-novo simple partial status epilepticus presenting as Wernicke's aphasia. *Seizure.* 21:219–222.
- Schaffler L, Lüders HO, Beck GJ. 1996. Quantitative comparison of language deficits produced by extraoperative electrical stimulation of Broca's, Wernicke's, and Basal temporal language areas. *Epilepsia.* 37:463–475.
- Serafetinides EA, Falconer MA. 1963. Speech disturbance in temporal lobe seizures. *Brain.* 86:333–346.