

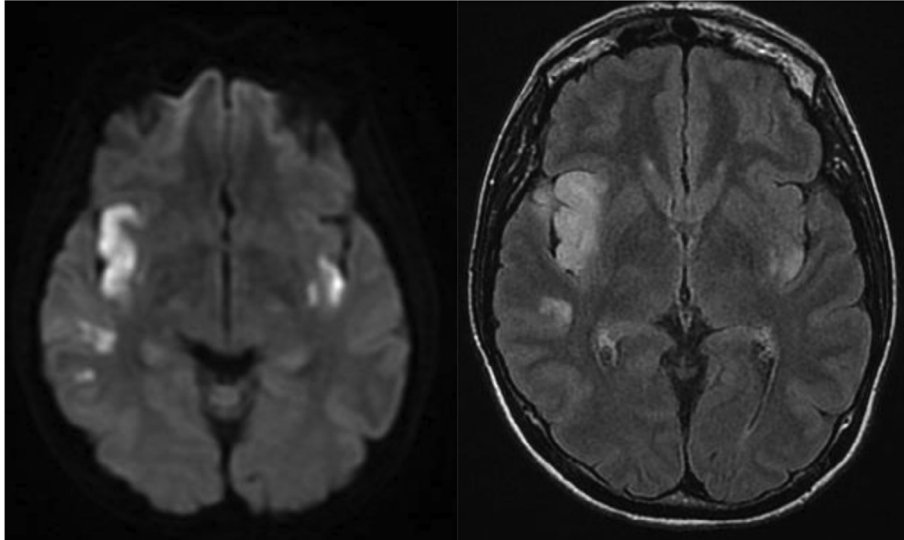Fig. 1. MRI scan; on the right FLAIR sequences showing abnormal hyperintense signaling in the right insular lobe and smaller similar lesions in the right temporal lobe and in the contralateral insular lobe. These alterations are characterized by a marked restriction in the DWI sequences (left), which is consistent with the acute vascular origin.

References

- [1] Luks AM, Swenson ER, Bartsch P. Acute high-altitude sickness. *Eur Respir Rev* 2017;26:160096.
- [2] West JB, Schoebe RB, Milledge JS. *High Altitude Medicine and Physiology*. 4th ed. London: Hodder Arnold; 2007. p. 312.
- [3] Jha SK, Anand AC, Sharma V, et al. Stroke at high altitude: Indian experience. *High Alt Med Biol* 2002;3:21–7.
- [4] Wheatly K, Creed M, Mellor A. Haematological changes at altitude. *J R Army Med Corps* 2011;157:48–52.
- [5] Chan T, Wong WWY, et al. Acute ischaemic stroke during short-term travel to high altitude. *Hong Kong Med J* 2012;18:63–5.
- [6] Murdoch DR. Revisiting the cause of focal neurological deficits and profound dyspnea at high altitude. The potential role of patent foramen ovale. *High Alt Med Biol* 2015;16.
- [7] Helal I, Reed B, et al. Prevalence of cardiovascular events in patients with autosomal dominant polycystic kidney disease. *Am J nephrol* 2010;36:362–70.
- [8] Nagai M, Dote K, et al. The right insular cortex infarction: a critical factor for mortality? *Eur J Neurol* 2017;24:e11.

<https://doi.org/10.1016/j.jocn.2019.05.049>

First case report of spontaneous posterior fossa subdural hemorrhage – A rare cause of neonatal encephalopathy



M.S. Sreedhara^a, Binu Ninan^a, A. Prakash^a, K. Visvanathan^b, Ravi Shekhar^b, R. Usha Devi^{a,*}

^a Department of Neonatology, Sri Ramachandra Institute of Higher Education & Research, Porur, Chennai, India

^b Department of Neurosurgery, Department of Neurosurgery, Sri Ramachandra Institute of Higher Education & Research, Porur, Chennai, India

ARTICLE INFO

Article history:

Received 25 March 2019

Accepted 27 May 2019

Keywords:

Intracranial haemorrhage

Encephalopathy

Seizures

Neonates

Decompression surgery

ABSTRACT

Posterior fossa subdural hemorrhage (PFSDH) in term neonates is rare and unknown in the absence of obvious trauma. Its management is challenging and decided case to case basis. Here we report two cases of posterior fossa subdural hemorrhage in term babies with normal transition at birth and presenting later with neonatal encephalopathy. First baby was born by elective caesarean section and the second baby by assisted vaginal delivery. They presented at 60 h and 48 h respectively. Both babies had similar clinical presentation in the form of poor feeding, shrill cry and posturing. But they had contrasting clinical course with features of brainstem compression in the first baby requiring ventilation. Coagulation workup was normal in the first baby but fibrinogen level was low in the second baby. Magnetic resonance imaging of the first baby showed PFSDH with tonsillar herniation while in the second baby, there was no midline shift or herniation associated with the PFSDH. Management was tailor made to suit the clinical course and imaging findings. Craniotomy and clot evacuation was done in the first case and in the second baby, management was conservative. Neurological examination was normal at discharge. Both are developmentally normal on follow up. There is no evidence of hydrocephalus in both. Management of PFSDH depends on clinical course and MRI findings. Timely intervention leads to good outcome.

© 2019 Elsevier Ltd. All rights reserved.

* Corresponding author.

E-mail address: dr.ushaa@gmail.com (R. Usha Devi).

1. Introduction

Symptomatic posterior fossa subdural hematoma (PFSDH) in term neonates is very rare and is not reported following elective caesarean delivery [1]. Till date, less than 100 cases of symptomatic PFSDH in neonates have been reported in the literature [1–6]. In view of risk of brain stem compression secondary to PFSDH in the confined space, there is management dilemma regarding surgical intervention and its optimal timing due to paucity of evidence. Hence we report two cases with unforeseen diagnosis of PFSDH with contrasting clinical course and management dilemmas.

2. Case report

We report two cases of PFSDH who were term babies born out of non consanguineous marriage. Both babies had a normal transition at birth and uneventful course till they became symptomatic (see Table 1, Figs. 1 and 2).

3. Discussion

Symptomatic posterior fossa subdural hematomas in term neonates are very rare with reported occurrence of about 0.3 per 100,000 live births in western population [2]. Primiparity, breech presentation, difficult delivery, instrumentation, familial bleeding tendency, vitamin K deficiency are the commonly identified risk factors for posterior fossa haemorrhage [1]. Though Blauwblomme et al. reported PFSDH in three cases born through labor naturalis, this is the first case report (case 1) of spontaneous PFSDH in a baby born by elective cesarean delivery before labor onset [3].

Two types of clinical presentation have been described in literature: acute presentation in the first few hours of life with features of brain stem dysfunction due to compression and delayed presentation after few days with signs of hydrocephalus [1,2]. Both babies in our report presented with signs of brain stem compression and did not have hydrocephalus.

Steggerda et al. demonstrated the usefulness of neurosonography through Mastoid fontanelle (NSMF) to detect posterior fossa abnormalities, and this underscores the importance of NSMF in

Table 1
Clinical details, MRI findings, Intervention and outcome of the two neonates with PFSDH.

Clinical features	Case 1	Case 2
Maternal details	G3A2	G2P1L1
Birth weight	2.4 kg	3.2 kg
Mode of delivery	Elective Caesarean (maternal demand)	Assisted vaginal delivery
Perinatal history	Normal transition	Normal transition
Onset of symptoms	60 h	48 h
Presenting features	Lethargy, poor feeding, shrill cry, posturing, Anterior fontanelle (AF) -flat	Poor feeding, shrill cry, posturing, AF- flat
Clinical course	Worsening of neurological status requiring mechanical ventilation, Bulging AF, unequal and sluggish reacting pupils	Sensorium gradually improved
Septic and metabolic screen	Normal	Normal
Bleeding and coagulation screen (Bleeding time, Platelet count, Prothrombin time, d Dimer levels, Activated partial thromboplastin time, Fibrinogen level, clot stability test)	Normal	Low fibrinogen (cryoprecipitate, Fresh frozen plasma transfused)
Magnetic Resonance Imaging	A large acute subdural haemorrhage in the posterior fossa under the tentorium cerebelli with herniation of the cerebellar tonsils (Fig. 1)	Subdural haemorrhage in the posterior fossa extending to bilateral tentorial leaflets and acute parenchymal haemorrhage in right cerebellar hemisphere but no tonsillar herniation (Fig. 2)
Management	Craniotomy & clot evacuation (Fig. 1)	Conservative
Hammersmith assessment at discharge, Head circumference on follow up	Normal, No hydrocephalus	Normal, No hydrocephalus
Coagulation profile on follow up	Normal	Normal
Development assessment using DASII*	At 1 year- normal	At 10 months- normal

* DASII – Development Assessment Scale for Indian Infants.

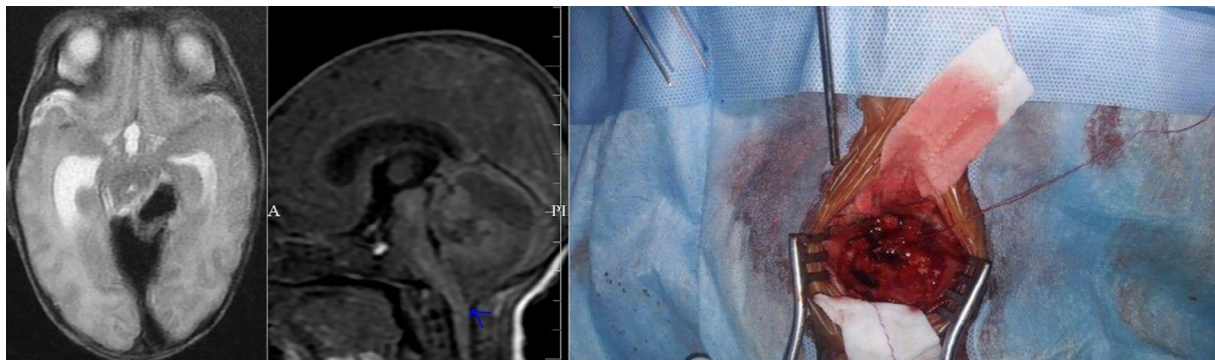


Fig. 1. a) MRI (T2) image showing subdural hemorrhage in the posterior cranial fossa b) Evidence of tonsillar herniation c) Clots visualized on posterior craniotomy.

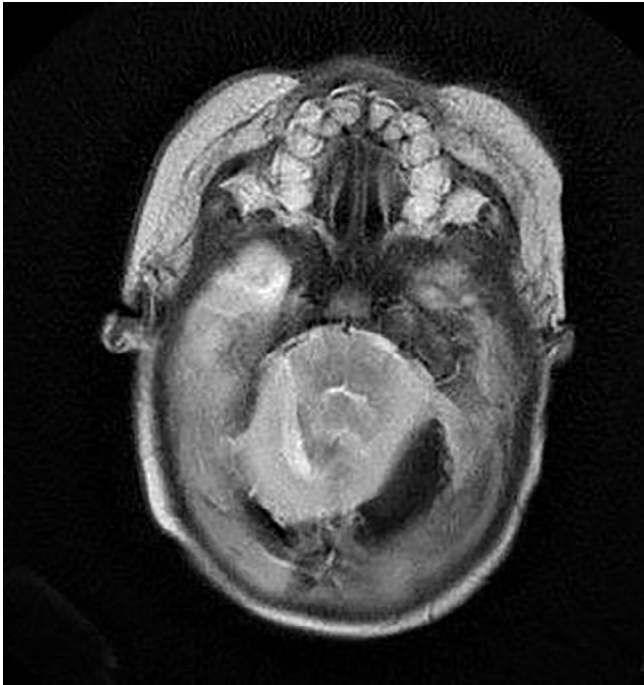


Fig. 2. MRI (GRE) showing posterior fossa subdural haemorrhage with blooming effect.

any baby with encephalopathy [7]. MRI with MR spectroscopy of the brain is the imaging modality of choice to identify etiology in babies with encephalopathy with or without seizures. If intracranial hemorrhage is suspected then Computer Tomography (CT) or MRI with gradient echo (GRE) is a better modality. Hayashi et al., have proposed a management plan according to CT classification of SDH [6]. However, this CT criteria is not followed universally for deciding intervention. Criteria to perform surgery in previously published series were either brainstem dysfunction or obstructive hydrocephalus [1,2,4]. Emergency surgical decompression was done for case 1 since the baby had progressive neurological deterioration and also MRI revealed tonsillar herniation. Whereas, Case 2 had no evidence of raised intracranial pressure clinically and there was no further expansion of bleed radiologically, and baby started improving clinically. Both burr hole surgery, and posterior fossa craniotomy followed by decompression have been the surgical intervention. In our cases, since the epicentre of the bleeding was under the tentorium, evacuation under direct visualization was considered optimal. Surgery, can be life - saving when performed in time.

In both our cases, there was no evidence of hydrocephalus and developmental assessment was normal on follow up. There is

scanty evidence on the long-term outcomes of neonates with PFSDH and the outcome is variable in different case series [1–3,6]. In the case series by Perrin et al. severely affected neonates had evidence of supratentorial parenchymal injuries in conjunction with their PFSDHs, indicative of a greater degree of brain involvement [1]. Our babies had predominantly posterior fossa haemorrhage, however, case 1 had thin supratentorial subdural hemorrhage. Hydrocephalus is a common complication but need for Ventriculoperitoneal shunt is variable ranging from rarely required to 50% [5].

In conclusion, it is important to rule out PFSDH in babies with neonatal encephalopathy even in the absence of obvious trauma for optimal life saving management.

Contributorship statement

Sreedhara, Binu Ninan, Prakash A, Usha Devi R, Visvanathan K, Ravi Shekhar managed the patient.

Sreedhara and Usha Devi R reviewed the literature and drafted the initial version of the manuscript. Binu Ninan, Prakash A and Visvanathan K contributed to literature review and critically revised the manuscript. All the authors contributed to drafting of the manuscript and approved the final version of the manuscript.

Funding sources

None.

Declaration of Competing Interest

None.

References

- [1] Perrin RG, Rutka JT, Drake JM, Meltzer H, Hellman J, Jay V, et al. Management and outcomes of posterior fossa subdural hematomas in neonates. *Neurosurgery* 1997;40:1190–9. discussion 1199–1200.
- [2] Henzi BC, Wagner B, Verma RK, Bigi S. Perinatal infratentorial haemorrhage: a rare but possibly life-threatening condition. *Case Rep* 2017;2017. bcr-2017-221144.
- [3] Blauwblomme T, Garnett M, Vergnaud E, Boddart N, Bourgeois M, Dirocco F, et al. The management of birth-related posterior fossa hematomas in neonates. *Neurosurgery* 2013;72:755–62. discussion 762.
- [4] Menezes AH, Smith DE, Bell WE. Posterior fossa hemorrhage in the term neonate. *Neurosurgery* 1983;13:452–6.
- [5] Hernansanz J, Muñoz F, Rodríguez D, Soler C, Principe C. Subdural hematomas of the posterior fossa in normal-weight newborns. Report of two cases. *J Neurosurg* 1984;61:972–4.
- [6] Hayashi T, Hashimoto T, Fukuda S, Ohshima Y, Moritaka K. Neonatal subdural hematoma secondary to birth injury. Clinical analysis of 48 survivors. *Childs Nerv Syst* 1987;3:23–9.
- [7] Steggerda SJ, de Bruïne FT, Smits-Wintjens VEJ, Verbon P, Walther FJ, van Wezel-Meijler G. Posterior fossa abnormalities in high-risk term infants: comparison of ultrasound and MRI. *Eur Radiol* 2015;25:2575–83.