



Late recovery of responsiveness after intra-thecal baclofen pump implantation and the role of diffuse pain and severe spasticity: a case report

Rita Formisano¹ · Marta Aloisi¹ · Marianna Contrada¹ · Francesca Spanedda¹ · Sara Schiattone¹ · Sylwia Niedbala¹ · Maria Rosaria Cobianchi² · Gianni Colini Baldeschi³ · Maria Gabriella Buzzi¹

Received: 23 April 2019 / Accepted: 25 June 2019
© Springer-Verlag GmbH Austria, part of Springer Nature 2019

Abstract

Patients with a prolonged disorder of consciousness (DoC) may present with severe spasticity and diffuse pain, which might impair motor output, thus preventing any possible behavioral responsiveness. A 26-year-old man affected by frontoparietal hemorrhage was operated by hematoma evacuation and decompressive craniectomy; coma persisted for 1 month; cranioplasty and ventriculo-peritoneal shunting was performed after 4 months. At admission in rehabilitation, he was diagnosed as vegetative state/unresponsive wakefulness syndrome (VS/UWS). The implantation of intrathecal baclofen (ITB) pump (Medtronic SynchroMed™ II), 14 months after, (60 µg/daily), dramatically improved behavioral responsiveness according to Coma Recovery Scale-Revised (CRS-R) from 6 to 12 (1 month after ITB). Nociception Coma Scale-Revised (NCS-R) also changed from 4 to 8 at the same time points. This case report may be an example of covert cognition that should have been diagnosed as a functional locked-in syndrome or motor-cognitive dissociation, rather than as VS/UWS.

Keywords Disorder of consciousness · Spasticity · Intra-thecal baclofen · Pain · Functional locked-in · Coma recovery scale-revised · Nociception coma scale · Behavioral responsiveness

Case report

A 26-year-old young man was affected by frontoparietal hemorrhage due to the rupture of an arteriovenous malformation; neurosurgical interventions consisted of hematoma evacuation and decompressive craniectomy on April 13, 2015; coma persisted for 1 month and cranioplasty and ventriculo-peritoneal shunting (Hakim at 170 mm H₂O rate), because

of secondary hydrocephalus, was performed on August 7, 2015.

The patient was admitted to the Post-Coma Unit of the post-acute Neurorehabilitation Hospital Santa Lucia, in Rome, around 5 months after the acute event and presented with severe spastic quadriplegia and sub-continuous crying, likely because of diffuse and intensive pain. This latter symptomatology and the presence of the ventriculo-peritoneal shunting did not lead the diagnostic support of neuroimaging and neurophysiological advanced techniques because of muscular artifacts.

The diagnosis at admission to our post-acute rehabilitation ward (September 2015) was of vegetative state/unresponsive wakefulness syndrome (VS/UWS) [5], according to the Coma Recovery Scale-Revised [4], with a total score of 6 (CRS-R = 6).

During the rehabilitation, the pharmacological therapy with oral anti-spastic drugs, pain killers, GABA-ergic drugs, and benzodiazepines was of no efficacy, as well as the holistic multi-disciplinary intensive rehabilitation treatment.

The implantation of intrathecal baclofen (ITB) programmable battery-based pump (Medtronic SynchroMed™ II) 14 months after the acute event, even at low rate dosage

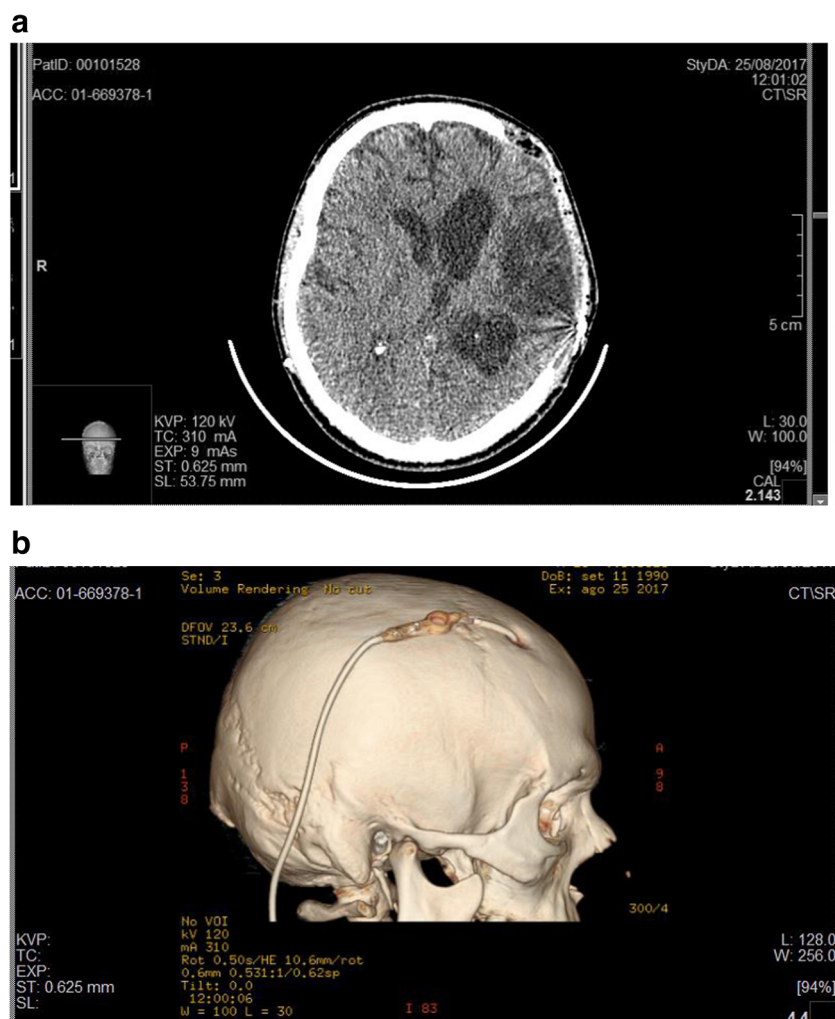
This article is part of the Topical Collection on *Brain trauma*

Electronic supplementary material The online version of this article (<https://doi.org/10.1007/s00701-019-03994-2>) contains supplementary material, which is available to authorized users.

✉ Rita Formisano
r.formisano@hsantalucia.it

- ¹ IRCCS Santa Lucia Foundation, Via Ardeatina 306, 00179 Rome, Italy
- ² Pain Therapy Unit S, Giovanni-Addolorata Hospital, Rome, Italy
- ³ Pain Therapy Unit, Salvator Mundi International Hospital, Rome, Italy

Fig. 1 a, b Brain CT scan
(obtained on August 25, 2017)



(60 µg/daily), dramatically improved the behavioral responsiveness of the patient, which changed according to CRS-R, from 6 to 12, with intentional and purposeful motor responses at the upper and lower left limbs and functional communication recovery by means of eyelids closure and limbs movements, together with a significant reduction of the crying episodes.

Noiception Coma Scale-Revised also revealed a significant improvement from before to after the baclofen pump implantation (NCS-R = 4 → NCS-R = 8).

CT scan at admission (cerebral MRI was incompatible with the sub-continuous muscular spasms and the presence of ventriculo-peritoneal shunting) showed the sequelae of cranioplasty and ventriculo-peritoneal shunting; left fronto-parieto-temporo-lenticular, bilateral frontal, and right cerebral peduncle hypodensities, associated with moderate cortical and subcortical atrophy (Fig. 1a, b).

Discussion

The high misdiagnosis rate up to 40% of the prolonged DoC [10] may be caused by several factors, such as severe motor impairment, often associated with intractable spasticity, not responsive to common pharmacological treatments, as well as intensive and diffuse pain, which may exacerbate the severe spasticity and thus might impair the behavioral responsiveness. Previous case reports underlined the possible responsiveness improvement after ITB pump implantation in patients with DoC [8].

Limitation of the study

Although a late spontaneous recovery, as previously reported [11], cannot be excluded, the recovery of responsiveness and

of functional communication 14 months after the acute event, i.e., besides 1 year in a non-traumatic VS/UWS is only anecdotally reported [12].

Moreover, the presented case did not change along the whole period of holistic intensive neurorehabilitation treatment, lasted 10 months, notwithstanding specific pharmacotherapy (anti-spasticity drugs and pain killers).

Conversely, the improvement of behavioral responsiveness was obtained only a few days after the intrathecal baclofen pump implantation, with a clear cause-effect relationship.

Conclusions

These cases could explain the possible covert residual cognition revealed by means of advanced diagnostic techniques in previous reports [6, 7] and should be diagnosed as functional locked-in syndrome [1–3] or motor-cognitive dissociation [9], rather than VS/UWS with residual islands of consciousness.

Before a definitive diagnosis of chronic VS/UWS, interfering factors such as severe spasticity and diffuse pain, should be taken into account.

The next of kin has consented to the submission of the case report for submission to the journal.

Funding This work has received funding from the European Union's Horizon 2020 research and innovation program under the Marie Skłodowska-Curie grant agreement no. 778234.

Compliance with ethical standards

Conflict of interest The authors declare that they have no conflict of interest.

References

1. Bruno MA, Vanhaudenhuyse A, Thibaut A, Moonen G, Laureys S (2011) From unresponsive wakefulness to minimally conscious PLUS and functional locked-in syndromes: recent advances in

- our understanding of disorders of consciousness. *J Neurol* 258: 1373–1384
2. Formisano R, D'Ippolito M, Catani S (2013) Functional locked-in syndrome as recovery phase of vegetative state. *Brain Inj* 27:1332–1332
3. Formisano R, D'Ippolito M, Risetti M, Riccio A, Caravasso CF, Catani S, Forcina M, Buzzi MG (2011) Vegetative state, minimally conscious state, akinetic mutism and parkinsonism as a continuum of recovery from disorders of consciousness: an exploratory and preliminary study. *Funct Neurol* 26:15
4. Giacino JT, Kalmar K, Whyte J (2004) The JFK Coma Recovery Scale-Revised: measurement characteristics and diagnostic utility. *Arch Phys Med Rehabil* 85:2020–2029
5. Laureys S, Celesia GG, Cohadon F, Lavrijsen J, León-Carrión J, Sannita WG, Sazbon L, Schmutzhard E, von Wild KR, Zeman A, Dolce G (2010) Unresponsive wakefulness syndrome: a new name for the vegetative state or apallic syndrome. *BMC Med* 8:68
6. Monti MM, Vanhaudenhuyse A, Coleman MR, Boly M, Pickard JD, Tshibanda L, Owen AM, Laureys S (2010) Willful modulation of brain activity in disorders of consciousness. *N Engl J Med* 362: 579–589
7. Owen AM, Coleman MR, Boly M, Davis MH, Laureys S, Pickard JD (2006) Detecting awareness in the vegetative state. *Science* 313: 1402–1402
8. Sarà M, Pistoia F, Mura E, Onorati P, Govoni S (2009) Intrathecal baclofen in patients with persistent vegetative state: 2 hypotheses. *Arch Phys Med Rehabil* 90:1245–1249
9. Schiff ND (2015) Cognitive motor dissociation following severe brain injuries. *JAMA Neurol* 72:1413–1415
10. Schnakers C, Vanhaudenhuyse A, Giacino J, Ventura M, Boly M, Majerus S, Moonen G, Laureys S (2009) Diagnostic accuracy of the vegetative and minimally conscious state: clinical consensus versus standardized neurobehavioral assessment. *BMC Neurol* 9:35
11. Estraneo A, Moretta P, Loreto V, Lanzillo B, Santoro L, Trojano L (2010) Late recovery after traumatic, anoxic, or hemorrhagic long-lasting vegetative state. *Neurol* 75:239–245
12. De Tanti A, Saviola D, Basagni B, Cavatorta S, Chiari M, Casalino S, Galvani R (2016) Recovery of consciousness after 7 years in vegetative state of non-traumatic origin: a single case study. *Brain Inj* 30:1029–1034

Publisher's note Springer Nature remains neutral with regard to jurisdictional claims in published maps and institutional affiliations.