



Tools and techniques

Thrombosis of the straight sinus and microbleedings due to deep seated arteriovenous fistula – Hemodynamic changes, cognitive impairment and improvement after microsurgery. A technical report



Nazife Dinc^{a,*}, Won Sae-Yeon^a, Eibach Michael^a, Quick-Weller Johanna^a, Keil Fee^b, Berkefeld Joachim^b, Konczalla Jürgen^a, Marquardt Gerhard^a, Seifert Volker^a

^a Department of Neurosurgery, Goethe University Hospital, Frankfurt, Germany

^b Department of Neuroradiology, Goethe University Hospital, Frankfurt, Germany

ARTICLE INFO

Article history:

Received 16 November 2018

Accepted 5 July 2019

ABSTRACT

Dural arteriovenous fistulas (dAVF) are rare vascular malformations accounting for only 10–15% that may lead to life threatening deficits due to hemodynamic changes in blood supply and pressure conditions.

We present a 64-year old patient who was admitted with disorientation and aphasia.

Following images confirmed an infratentorial dural fistula draining into the straight sinus. Additional findings were progressive thrombosis of the straight sinus, microbleedings and bithalamic edema due changes in hemodynamic conditions and venous congestion. Microsurgery was performed. After treatment improvement in clinical condition was observed and the venous congestion was regressive.

Hemodynamic changes due to infratentorial dAVFs may lead to bleedings in deep regions and worsening of clinical condition fastly. Treatment requires carefully planning and visualization of angioarchitecture. Symptoms and hemodynamic changes are reversible after treatment, which are essential for treatment decisions.

© 2019 Elsevier Ltd. All rights reserved.

1. Introduction

Dural arteriovenous fistulas (dAVF) are rare vascular lesions accounting for 10–15% of all intracranial vascular shunts [1–7]. Tentorial dAVF represent a subgroup of dAVF accounting for 4% and are potentially hazardous acquired lesions [1,7–10]. The etiology is discussed controversial and the association with venous or sinus thrombosis is described in several studies [6,11–14].

We report a case of a straight sinus fistula with arterial blood supply from the left superior cerebellar artery, sinus thrombosis, bithalamic venous congestion and deep microbleedings.

2. Patient and methods

A 64 year old male was presented with disorientation and aphasia. For a short time he showed a mild confusion with memory deficits and speech arrest. An intracerebral hemorrhage was ruled out by a computed tomography. The sonography of the cervical vessels excluded any high grade stenosis and magnet resonance imaging (MRI) and cerebral angiography was planned.

3. Results

3.1. Imaging findings before treatment

The MRI at presentation revealed a fistulous infratentorial arteriovenous malformation from the left superior cerebellar artery with stenosis of the straight sinus. Bithalamic edema were defined as a sign of venous congestion.

The first angiography confirmed the straight sinus fistula (Fig. 1). Significantly delayed antegrade drainage with stenosis just proximal to the confluens sinuum and very low contrasting and reflux into small veins of the thalamus and venous congestion were detected. The dAVF was classified as a Cognard IIb fistula [15,16].

The MRI two months later showed persistent early contrasting of the straight sinus as a sign for arterial flow. The thalamic edema were regressive but bithalamic hyperintense regions due venous congestion on FLAIR and DWI-sequences were still existing. Multiple microbleedings bithalamic and at the posterior part of the splenium were detected on T2w*.

Due to a renewed confusion and worsening of patients clinical condition 9 days later MRI was performed again. An increasing of the bithalamic right-sided edema with progression of venous congestion, now with thrombosis of the posterior part of the straight sinus was detected (Fig. 2).

* Corresponding author at: Dept. of Neurosurgery, Goethe-University Frankfurt, Schleusenweg 2-16, 60528 Frankfurt, Germany.

E-mail address: nazife.dinc@kgu.de (N. Dinc).

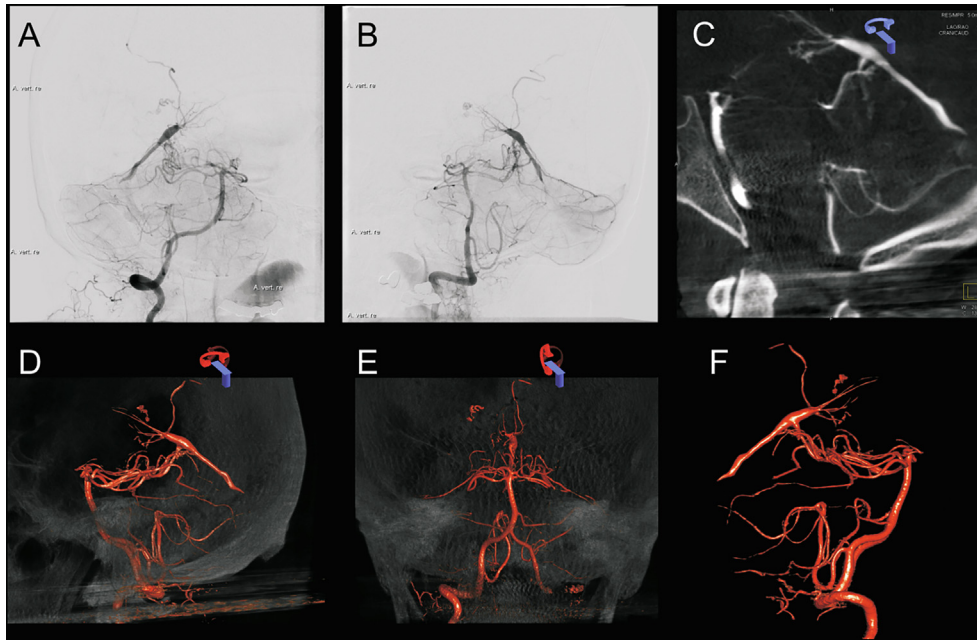


Fig. 1. Angiography series prior treatment A, B: Angiography (C: CT angiography; D-F: 3-dimensional angiography;) reveals infratentorial dAVF with blood supply from the left superior cerebellar artery, draining to the straight sinus.

3.2. Thrombophilia screening

For excluding thrombophilia as a predictive factor for the development of venous clots we performed a coagulation-screening. There were no pathologic findings considering factor V Leiden, factor VIII, protein C and S deficiency and antithrombin deficiency.

3.3. Treatment

The case was discussed in the interdisciplinary vascular board. Due worsening in clinical state and rapid hemodynamic changes within 9 days the decision was to perform microsurgery immediately at the following day.

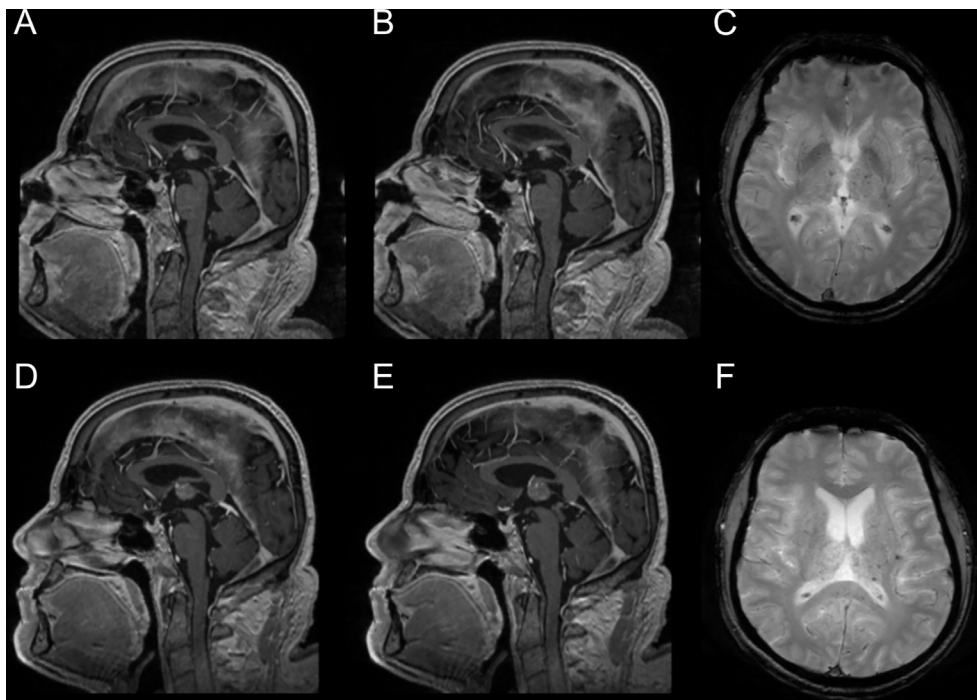


Fig. 2. MRI series prior treatment Preoperative MRI on sagittal T2 showing early contrasting of the straight sinus (A–B) and microbleedings bithalamic and at the corpus callosum in T2^w (C). 9 days later early contrasting of the anterior third part of the straight sinus. The posterior part of the straight sinus is thrombosed (D–E). Microbleedings and bithalamic edema in T2^w (F).

3.4. Surgical procedure

After performing an echocardiography and excluding a patent foramen ovale the patient was placed in the sitting position with gentle neck flexion to maximize gravity-assisted retraction of the cerebellum. Intraoperative electrophysiology with sensory and motor evoked potentials were recorded.

We used a midline linear skin incision. A suboccipital craniotomy was performed for an infratentorial supracerebellar access. The exposure of the transverse sinus was necessary as the inferior edge of the sinus can be gently mobilized superior and allow upward retraction of the transverse sinus. After opening and retracting the dura flaps we divided the arachnoid bands carefully. Fenestration of the cisterna magna released cerebrospinal fluid and allowed brain relaxation. After detaching all arachnoid connections and visualizing the cerebellar surface vascular landmarks were identified. To preserve and protect bridging veins and to evade diminished visibility of the surgical access we performed a right paramedian trajectory. The confluence of the internal cerebral veins and basal vein of Rosenthal were carefully identified and preserved. After sufficient visualization of the cerebellar surface, small arteries were visible along the surface. They run into a larger artery and drained directly into the straight sinus. Then indocyanine green (ICG) angiography was performed and showed the fistula point clearly. The thrombosed part of the straight sinus was visible proximal to the fistula. We coagulated the arterial fistula and clipped it with a straight clip. Renewed ICG angiography confirmed occlusion of the fistula and demonstrated a retrograde perfusion of the straight sinus. After watertight dural closure the bone was replaced and wound closure was performed. The recorded evoked potentials remained normal during the entire procedure. Fig. 3 shows the surgical clip occlusion of the infratentorial dAVF.

3.5. Imaging findings at early follow up and outcome

Postoperatively the first MRI and angiography confirmed the occlusion of the fistula. Bithalamic edema were still visible.

In early MRI follow up 3 months later the bithalamic edematous changes were regressive compared to the preliminary studies. Only residuals in the thalamus on the right side were visible on T2Flair, without infarctions or hemorrhage (Fig. 4). The patient was in a favorable clinical condition and showed no neurological deficits and no confusion.

4. Discussion

The pathophysiology of dAVF remains still unclear and is discussed controversial. A multifactorial development is described like head trauma, craniotomy, meningiomas, infections or thrombophilic pathologies [17–19]. A relation to sinus thrombosis with opening of small physiological arteriovenous pathways from the sinus or abnormal connections during the recanalization process is proposed [20,21]. The formation of a thrombosis at some stages in fistula development, possibly due to stenosis thickening of sinus wall which leads to turbulences with subsequent thrombus formation is described as well [20,22]. Furthermore thrombosis of the sinus could be a trigger for de novo fistulas [11]. The occlusion of a dural sinus or a cerebral vein may cause alterations in hemodynamics, which may contribute to arteriovenous shunts [17].

In adults dAVF typically presents with venous or sinus thrombosis, in children the etiology is usually congenital [23]. The association with thrombophilic polymorphism and dural fistula is described in some studies but the literature therefore is rare and limited to case reports and a small number of studies [5,24,25]. In particular, dAVF may be a considerable cause of vascular cogni-

tive impairment. Venous congestion due to hemodynamic changes with progressive thrombosis and venous hypertension are described as a serious finding and reason for cognitive disorders in high flow dAVF [26]. However, cognitive disorders are reported in previous studies with discrepant frequencies. The rate of mental deterioration in patients with dAVF in the transverse-sigmoid sinus ranges between 12% and 22% [26–28]. In addition to neurodegenerative disorders, prion disease, autoimmune encephalopathies or some infections and neoplasms, dAVF may be a reason for rapid progressive dementia [29]. Seizures, focal cortical deficits, cranial nerve palsies, trigeminal neuralgia, thalamic or cortical dementia, parkinsonism, cerebellar dysfunction, myelopathy, aphasia or dysphasia are related to non-hemorrhagic dAVF [30–35]. In MRI white matter edema in deep cerebellar or cerebral hemispheres is a direct evidence of venous congestion and correlates with neurological deficits [36]. Due to their rapid decline and excellent post-treatment improvement [13,26,28,37], rapid evaluation and treatment of dAVF is required. We describe a case of a patient with a tentorial fistula, with a high arterial flow, draining into the straight sinus with occlusive changes of the straight sinus resulting in sinus thrombosis and venous reflux during the course. The impaired hemodynamic conditions led to venous congestions, bithalamic edema, and microbleedings. The patient experienced a rapidly progressive confusion, similar to thalamic dementia with memory deficits and mild aphasia within a few days prior to treatment. After interdisciplinary case discussion, microsurgery was performed. Beside the dilemma of medical anticoagulative treatment of the sinus thrombosis despite the microbleedings, the surgical management is more challenging too, due to the deep location and vast anastomotic network. Fig. 4 illustrates the extent of venous congestion and its regression after treatment. The association of a thrombophilic condition of hypercoagulopathy in the pathogenesis of dAVF were published already [17,38–40]. In our report there were no findings considering thrombophilic risk factors.

In their reports Pu et al and Morparia et al described a similar case of a patient with a parkinsonism due to tentorial dAVF and acute thrombosis of the straight sinus and lenticular nuclei congestion. The clinical symptoms and hemodynamic MRI findings with venous congestion were reversible after treatment [12,41]. Our report also showed a clinical improvement and regression of the venous congestion after microsurgical clipping of the fistula. Already in earlier studies the significant impact of thrombophlebitis pattern due to dAVFs with venous congestion as a prognostic indicator for treatment decisions was pointed out [42].

The most frequent localization of dAVF is the transverse sinus (50%), followed by the cavernous sinus (16%). These dAVF rarely cause intracranial hemorrhage. Less common are dAVF of the tentorium (4–12%), but harboring a hemorrhage risk of 58% [15,43]. Treatment decision depends on angioarchitectural features, location and clinical presentation. Endovascular embolization, microsurgical interruption or Gamma Knife surgery or the combination of these treatment methods are common options. Endovascular treatment has become a first-line treatment for dAVFs during the past 2 decades and includes transarterial embolization, transvenous embolization or a combination of both, using embolic agents (polyvinyl alcohol particles, n-butyl-2-cyanoacrylate, Onyx, Coils) [16,33]. The recurrence rate for a single intraarterial occlusion may be 50% including a high bleeding risk. The success rate can be improved by a combined arterial and venous occlusion. However, the transvenous procedure is more risky, as serious obstruction of venous drainage may occur or in the event of incomplete embolization, cortical reflux may be exacerbated [43]. Endovascular treatment is also an effective procedure in cases of anterior cranial fossa dAVFs. The fistula point can be completely obliterated with low risk and good results [44]. In dAVF of the tentorium with

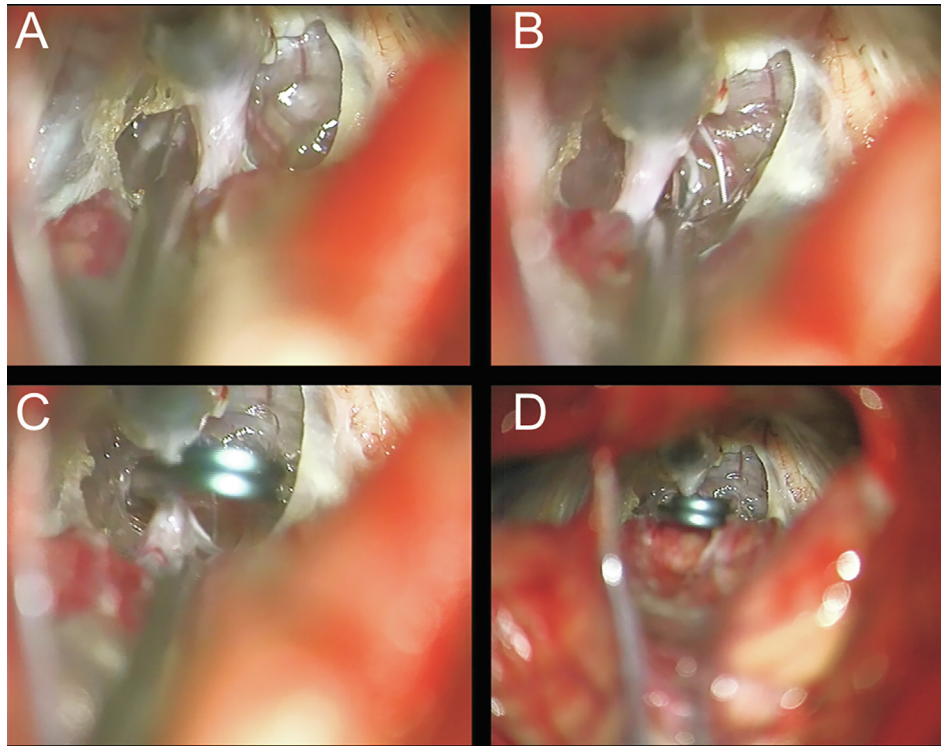


Fig. 3. Intraoperative images pre- (A, B) and postclipping (C, D) of infratentorial dAVF.

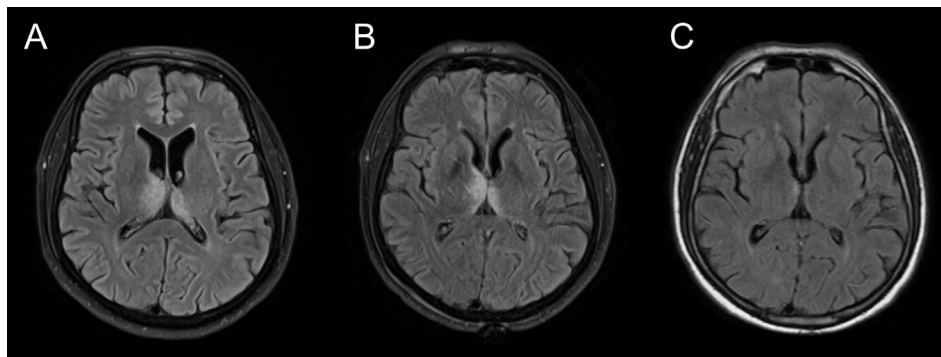


Fig. 4. MRI series preoperative and in early follow up MRI follow up reveals the changes in hemodynamic conditions. Venous congestion with hyperintense regions bithalamic in FLAIR preoperative (A), in early postoperative MRI follow up (B) and regression 3 months after discharge (C).

feeding arteries from the vertebral artery or internal carotid artery, a complete or permanent occlusion may be rarely possible due to recanalization of small arterial feeders. Therefore some authors argue for primary surgical care [43,45]. Gamma Knife surgery is recommended for lesions without cortical venous reflux and with low risk of hemorrhage. The main problem remains the period of 1 to 2 years until a fistula closure can be achieved. Therefore Gamma Knife surgery in hemorrhagic dAVF is indicated only in exceptional cases.

In our case, surgery was preferred for the occlusion of the infratentorial dAVF. The access to this deep-seated fistula and post-treatment results including fistula closure and cognitive function were excellent.

Cognitive impairment due to venous hypertension and venous congestion is an underrecognized symptom and literature

therefore is limited to case reports. The aim of our report is to emphasize hemodynamic features of a rare subtype of dAVF with its presenting symptoms, treatability and rapid radiographic resolution and neurological improvement after treatment.

5. Conclusion

Management of tentorial dAVFs is challenging and requires carefully planning, especially the association with sinus thrombosis may lead to neurological deficits due to venous congestions in deep brain regions and harbor a high risk of intracerebral hemorrhage. These findings and the knowledge about the reversibility of the symptoms with a favorable outcome after treatment are essential impact factors for treatment decisions.

Ethical approval

The study was approved by the ethics standard of our institution and was reviewed and approved by the local ethics committee. Patient consent was obtained.

Conflict of interest

All authors certify that they have NO affiliations with or involvement in any organization or entity with any financial interest (such as honoraria; educational grants; participation in speakers' bureaus; membership, employment, consultancies, stock ownership, or other equity interest; and expert testimony or patent-licensing arrangements), or non-financial interest (such as personal or professional relationships, affiliations, knowledge or beliefs) in the subject matter or materials discussed in this manuscript.

Funding

No funding was received for this research.

Acknowledgment

The authors thank Marina Heibel, Department of Neurosurgery for her excellent technical support.

References

- [1] Byrne JV, Garcia M. Tentorial dural fistulas: Endovascular management and description of the medial dural-tentorial branch of the superior cerebellar artery. *Am J Neuroradiol* 2013;34:1798–804.
- [2] Kajita Y, Miyachi S, Wakabayashi T, Inao S, Yoshida J. A dural arteriovenous fistula of the tentorium successfully treated by intravascular embolization. *Surg Neurol* 1999;52:294–8.
- [3] Chen L, Mao Y, Zhou LF. Local chronic hypoperfusion secondary to sinus high pressure seems to be mainly responsible for the formation of intracranial dural arteriovenous fistula. *Neurosurgery* 2009;64:973–83.
- [4] Tomak PR et al. Evolution of the management of tentorial dural arteriovenous malformations. *Neurosurgery* 2003;52, 750–60, discussion 760–2.
- [5] Kortman HG et al. Treatment of cranial dural arteriovenous fistulas with exclusive cortical venous drainage: a single-center cohort of 35 patients. *Interv Neuroradiol* 2017;23:661–5.
- [6] Hiramatsu M et al. Epidemiology of dural arteriovenous fistula in Japan: analysis of Japanese registry of Neuroendovascular therapy (JR-NET2). *Neurol Med Chir (Tokyo)* 2014;54:63–71.
- [7] Bhogal P et al. Normal pial-dural arterial connections. *Interv Neuroradiol* 2015;21:750–8.
- [8] Kortman HG et al. Tentorial dural arteriovenous fistulas: a single-center cohort of 12 patients. *J Cerebrovasc Endovasc Neurosurg* 2017;19:284–90.
- [9] Daniels DJ, Vellimana AK, Zipfel GJ, Lanzino G. Intracranial hemorrhage from dural arteriovenous fistulas: clinical features and outcome. *Neurosurg Focus* 2013;34:E15.
- [10] Lawton MT, Sanchez-Mejia RO, Pham D, Tan J, Halbach VV. Tentorial dural arteriovenous fistulae: operative strategies and microsurgical results for six types. *Neurosurgery* 2008;62, 110–24; discussion 124–5.
- [11] Fujii H, Nagano Y, Hosomi N, Matsumoto M. Dural arteriovenous fistula presenting with progressive dementia and parkinsonism. *BMJ Case Rep* 2014. <https://doi.org/10.1136/bcr-2014-203921>.
- [12] Morparia N, Miller G, Rabinstein A, Lanzino G, Kumar N. Cognitive decline and hypersomnolence: thalamic manifestations of a tentorial dural arteriovenous fistula (dAVF). *Neurocrit Care* 2012;17:429–33.
- [13] Van Dijk JMC, TerBrugge KG, Willinsky RA, Wallace MC. Clinical course of cranial dural arteriovenous fistulas with long-term persistent cortical venous reflux. *Stroke* 2002;33:1233–6.
- [14] Ishii K et al. High-risk dural arteriovenous fistulae of the transverse and sigmoid sinuses. *AJNR Am J Neuroradiol* 1987;8:1113–20.
- [15] Cognard C et al. Cerebral dural arteriovenous fistulas: clinical and angiographic correlation with a revised classification of venous drainage. *Radiology* 1995;194:671–80.
- [16] Oh JT et al. Intracranial dural arteriovenous fistulas: clinical characteristics and management based on location and hemodynamics. *J Cerebrovasc Endovasc Neurosurg* 2012;14:192–202.
- [17] LaHue SC et al. Frequency and characteristics associated with inherited thrombophilia in patients with intracranial dural arteriovenous fistula. *J Neurosurg* 2018;1–5. <https://doi.org/10.3171/2017.10.JNS171987>.
- [18] Chaudhary MY et al. Dural arteriovenous malformation of the major venous sinuses: an acquired lesion. *AJNR Am J Neuroradiol* 1982;3:13–9.
- [19] Houser OW, Campbell JK, Campbell RJ, Sundt TM. Arteriovenous malformation affecting the transverse dural venous sinus—an acquired lesion. *Mayo Clin Proc* 1979;54:651–61.
- [20] Sun L-L et al. Dural arteriovenous fistula disguised as cerebral venous sinus thrombosis. *J Zhejiang Univ Sci B (Biomed Biotechnol)* 2017;18:733–6.
- [21] Kojima T et al. The relationship between venous hypertension and expression of vascular endothelial growth factor: hemodynamic and immunohistochemical examinations in a rat venous hypertension model. *Surg Neurol* 2007;68:277–84.
- [22] Shimizu S, Sato S, Iida H, Mitomi T, Fujii K. Sinus thrombosis probably resulting from a dural arteriovenous fistula development in the superior sagittal sinus. *Acta Neurochir (Wien)* 2003;145:719–20, discussion 720–1.
- [23] Hettis SW et al. Pediatric intracranial dural arteriovenous fistulas: age-related differences in clinical features, angioarchitecture, and treatment outcomes. *J Neurosurg Pediatr* 2016;18:602–10.
- [24] Gerlach R et al. Increased incidence of thrombophilic abnormalities in patients with cranial dural arteriovenous fistulae. *Neurol Res* 2003;25:745–8.
- [25] Safavi-abbasi S et al. Thrombophilia due to factor V and factor II mutations and formation of a dural arteriovenous fistula: case report and review of a rare entity. *Skull Base* 2007;1:135–43.
- [26] Pasi M et al. Rapidly progressive cognitive impairment in a patient with high flow dural arteriovenous fistulas, cerebral sinus thrombosis and protein S deficiency. *J Clin Neurosci* 2014;21:1654–6.
- [27] Obrador S, Soto M, Silvela J. Clinical syndromes of arteriovenous malformations of the transverse sigmoid sinus. *J Neurol Neurosurg Psychiatry* 1975;38:436–51.
- [28] Kai Y et al. Reversibility of cognitive disorder after treatment of dural arteriovenous fistulae. *Neuroradiology* 2009;51:731–9.
- [29] Geschwind MD. Rapidly progressive dementia. *Contin Lifelong Learn Neurol* 2016;22:510–37.
- [30] Reynolds MR, Lanzino G, Zipfel GJ. Intracranial dural arteriovenous fistulae. *Stroke* 2017;48:1424–31.
- [31] Lasjaunias P et al. Neurological manifestations of intracranial dural arteriovenous malformations. *J Neurosurg* 1986;64:724–30.
- [32] Cognard C et al. Dural arteriovenous fistulas as a cause of intracranial hypertension due to impairment of cranial venous outflow. *J Neurol Neurosurg Psychiatry* 1998;65:308–16.
- [33] Gandhi D et al. Intracranial dural arteriovenous fistulas: classification, imaging findings, and treatment. *AJNR Am J Neuroradiol* 2012;33:1007–13.
- [34] Borden JA, Wu JK, Shucart WA. A proposed classification for spinal and cranial dural arteriovenous fistulous malformations and implications for treatment. *J Neurosurg* 1995;82:166–79.
- [35] Holekamp TF et al. Dural arteriovenous fistula-induced thalamic dementia: report of 4 cases. *J Neurosurg* 2016;124:1752–65.
- [36] Willinsky R, Terbrugge K, Montaner W, Mikulis D, Wallace MC. Venous congestion: an MR finding in dural arteriovenous malformations with cortical venous drainage. *AJNR Am J Neuroradiol* 1994;15:1501–7.
- [37] Henderson JB, Zarghouni M, Hise JH, Opatowsky MJ, Layton KF. Dementia caused by dural arteriovenous fistulas reversed following endovascular therapy. *Proc (Bayl Univ Med Cent)* 2012;25:338–40.
- [38] Gerlach R et al. Thrombophilic risk factors in patients with cranial and spinal dural arteriovenous fistulae. *Neurosurgery* 2008;63:693–8.
- [39] Izumi T et al. Thrombophilic abnormalities among patients with cranial dural arteriovenous fistulas. *Neurosurgery* 2007;61:262–8, discussion 268–9.
- [40] Jellema K et al. Spinal dural arteriovenous fistulas are not associated with prothrombotic factors. *Stroke* 2004;35:2069–71.
- [41] Pu J, Si X, Ye R, Zhang B. Straight sinus dural arteriovenous fistula presenting with reversible parkinsonism. *Med (United States)* 2017;96.
- [42] Willinsky RA, Goyal M, Terbrugge K, Montaner W. Tortuous, engorged pial veins in intracranial dural arteriovenous fistulas: Correlations with presentation, location, and MR findings in 122 patients. *Am J Neuroradiol* 1999;20:1031–6.
- [43] Dietrich U, Wanke I, Asgari S, Forsting M, Oettel F. Durafisteln mit intrakranieller blutung: Diagnostische und therapeutische aspekten. *Zentralbl Neurochir* 2003;64:12–8.
- [44] Xu K, Ji T, Li C, Yu J. Current status of endovascular treatment for dural arteriovenous fistulae in the anterior cranial fossa: a systematic literature review. *Int J Med Sci* 2019;16:203–11.
- [45] De Jesús O, Rosado JE. Tentorial dural arteriovenous fistula obliterated using the petrosal approach. *Surg Neurol* 1999;51:164–7.