

# The use of middle latency response in the diagnosis of cortical deafness

JEANNE S. VEDDER, MD, DAVID M. BARRS, MD, and ROBERT C. FIFER, PhD,  
San Antonio, Texas, Aurora, Colorado, and Champaign, Illinois

**B**ilateral cortical lesions resulting in true deafness were first reported approximately 100 years ago.<sup>1-3</sup> A detailed map of the auditory cortex, however, was derived only within the past 50 years, primarily from investigation in the cat and subhuman primate.<sup>4</sup> The few human studies have shown the primary auditory cortex to be located around the posterior two-thirds of the sylvian fissure (Fig. 1), especially in the anterior and posterior transverse temporal gyri—or Heschl's gyri—on the superior portion of the temporal lobe.<sup>4</sup> Each organ of Corti

has extensive bilateral projections to the primary auditory cortex,<sup>5</sup> although experiments by Celesia<sup>4</sup> have shown larger contralateral than ipsilateral response to auditory stimulation.

This bilateral distribution of ascending auditory pathways makes deafness secondary to a single cortical lesion highly unlikely.<sup>6-10</sup> Before the advent of brainstem evoked responses and computed tomographic (CT) or magnetic resonance imaging (MRI) of the brain, diagnosis of cortical deafness was made only through exhaustive neurologic, speech, hearing, and psychiatric evaluation.<sup>6</sup> The purpose of this article is to present a patient with cortical deafness and illustrate the use of auditory middle latency responses as an aid to diagnosis.

## CASE REPORT

In 1980, a 43-year-old man experienced a cerebrovascular accident (CVA) that involved the right frontal, temporal, and parietal areas of the cortex and a portion of the brainstem, with resultant dense left hemiparesis. The patient also experienced a total loss of hearing in the left ear that was believed to be of either brainstem or end-organ origin. The right tem-

From the Otolaryngology Service, Wilford Hall USAF Medical Center, Lackland AFB (Dr. Vedder), the Otolaryngology Service, Fitzsimons Army Medical Center (Dr. Barrs), and the Carle Clinic (Dr. Fifer).

The opinions expressed in this article do not necessarily represent the views of the Department of the Army or the Department of the Air Force.

Presented at the Annual Meeting of the American Academy of Otolaryngology-Head and Neck Surgery, Atlanta, Ga., Oct. 20-24, 1985.

Submitted for publication May 18, 1987; accepted Dec. 16, 1987.

No reprints available.

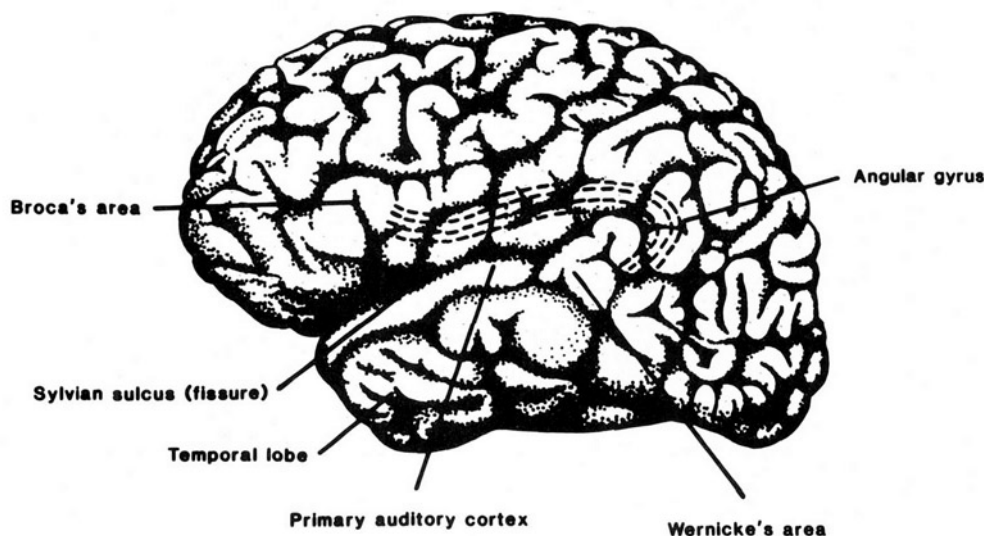


Fig. 1. Lateral surface of brain shows primary and Wernicke's associative auditory centers.

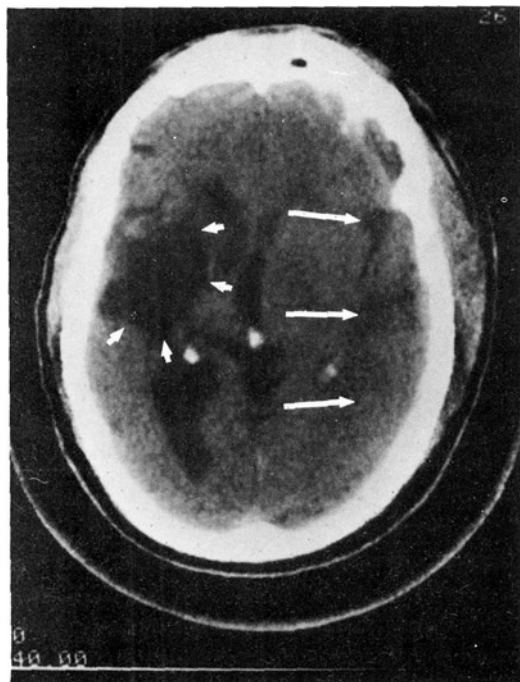


Fig. 2. CT scan demonstrates 1980 right frontal temporal and parietal CVA (short arrows) and 1984 left temporal and parietal CVA (long arrows).

poral lobe lesion would not have been expected to cause the left total hearing loss because of the bilateral nature of the ascending auditory pathways mentioned previously.<sup>6-10</sup>

In 1984, he manifested acute onset of right-sided hemiparesis. An enhanced CT scan demonstrated the old right cerebral infarct and a new infarct in the left posterior temporal and inferior parietal cortex and subcortical white matter (Fig. 2). Angiography revealed a left carotid artery occlusion for which a temporal artery to middle cerebral artery bypass was performed. Two days after this surgery, the patient experienced intermittent hearing loss that progressed to complete unresponsiveness to speech. Physical examination at this time revealed normal tympanic membranes and external auditory canals. The patient was unresponsive to speech and Weber testing with a 512 Hertz (Hz) tuning fork. His reading and writing ability was intact. His own speech was fluent, although mildly dysarthric. The neurologic examination revealed primarily the residual of his first CVA: mild left central facial paresis, spastic left hemiparesis, and decreased left-sided sensation.

Standard audiometry confirmed the total hearing loss in the left ear (Fig. 3). In the right ear, the patient had speech awareness at 30 decibels (dB), but no speech discrimination. In conversation, he reported he knew when sound was speech, but could not understand the words. Auditory brainstem (ABR), middle latency (MLR), and late potential responses were recorded by

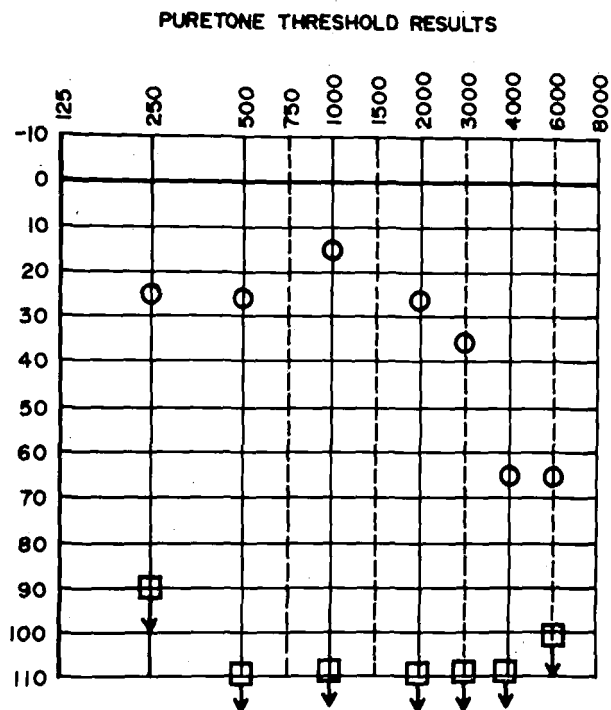


Fig. 3. Audiogram, 1984 CVA.

use of broadband clicks, presented initially at 90 dB through TDH-39 earphones. Multiple runs with 2048 clicks were accomplished in an attempt to demonstrate reproducible waveforms. Averaging was accomplished on a Nicolet CA-1000 (Nicolet Corp., Madison, Wisc.) with band pass filters at 150 to 3000 Hz. The left ear could not be tested for any evoked response secondary to the severe hearing loss. The ABR with right ear stimulation was essentially normal for ipsilateral and contralateral recording (Fig. 4). The right MLR showed an abnormal ipsilateral recording, with small amplitude and unusual morphology of waves (Fig. 5). Waveforms were absent on contralateral right MLR recording. No repeatable ipsilateral or contralateral late potentials could be obtained with left ear stimulation.

## DISCUSSION

Cortical deafness is a marked impairment in hearing sensitivity despite an apparently intact peripheral and brainstem auditory pathway.<sup>7</sup> Unilateral temporal lobe lesions in the primary auditory cortex cause only subtle auditory deficits.<sup>6-10</sup> Cortical deafness is almost always the result of extensive bilateral temporal lobe lesions, although a unilateral white-matter lesion of the posterior temporal lobe, which disconnects the primary auditory

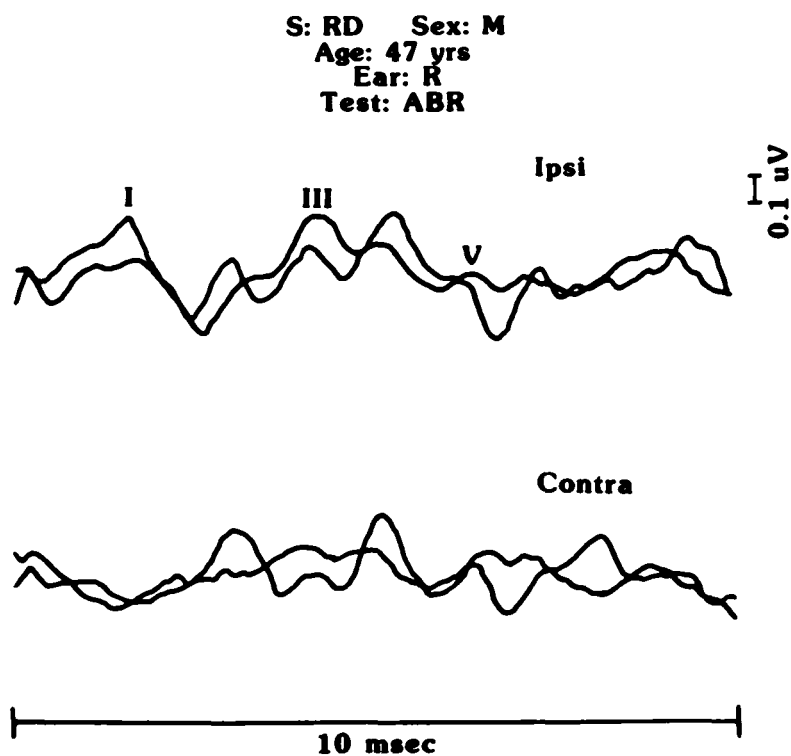


Fig. 4. Right ear ABR, performed after 1984 CVA.

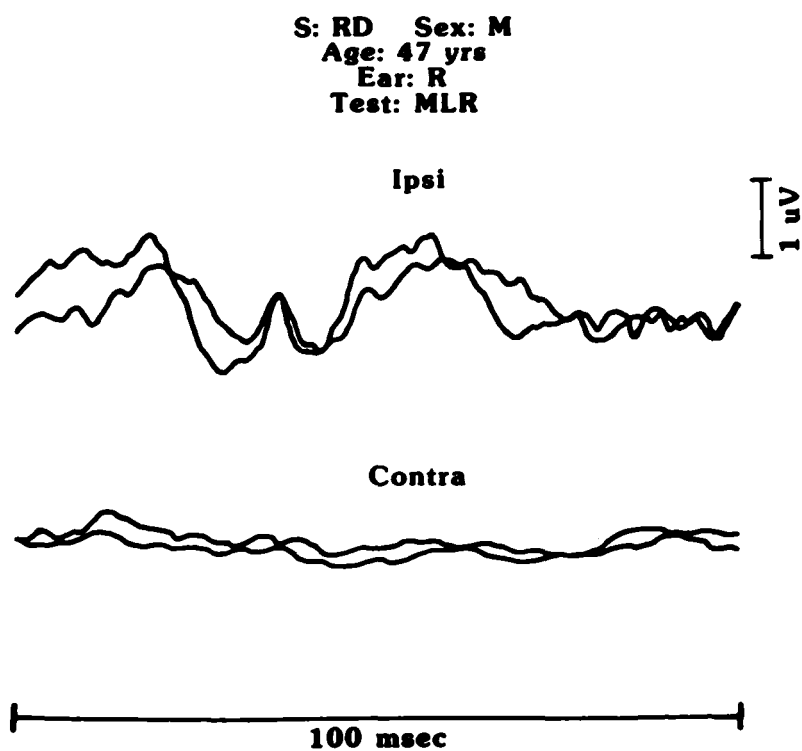


Fig. 5. Right ear MLR, performed after 1984 CVA.

center from Wernicke's associative center and interrupts callosal fibers to the opposite auditory cortex, can theoretically cause the same deficit.<sup>7,8</sup> Cortical deafness can be divided into three separate entities: *central deafness*, *auditory agnosia*, and *pure-word deafness*.<sup>8,9</sup>

In *central deafness*, the patient is totally deaf as a result of bilateral destruction of the primary auditory cortex. Some functioning auditory cortex remains in *auditory agnosia* and the patient has some residual hearing, but cannot discriminate or name nonspeech sounds. The patient with *pure-word deafness* cannot discriminate speech even though the words spoken can be heard. In reality, the three entities are usually not so distinct in an individual patient.<sup>7-10</sup>

Although similar, cortical deafness can be distinguished from aphasia. *Aphasia* is defined as an acquired disorder of a previously intact language function secondary to brain damage.<sup>11</sup> An example of expressive aphasia is Broca's aphasia, in which the patient can understand speech but is unable to speak coherently because of damage in Broca's motor association area of the inferior frontal cortex (Fig. 1). The receptive aphasia closest to pure-word deafness is Wernicke's aphasia, caused by destruction of the auditory associative cortex adjacent to the primary auditory cortex (Fig. 1). Since it is the associative, or "decoding" center, that is destroyed, the patient with Wernicke's aphasia also has difficulty with reading in addition to loss of speech discrimination. The content of speech is usually meaningless, even though the fluency or motor function is intact. In pure-word deafness, the defect is an isolated inability to comprehend spoken language, whereas reading and speech function are performed normally.<sup>11</sup> The pathologic defect in pure-word deafness, whether a bilateral temporal lobe lesion or a deep unilateral lesion in the dominant posterior temporal lobe, spares Wernicke's associative area. It is possible, then, to differentiate the aphasias from cortical deafness caused by damage to the primary auditory cortex.

The diagnosis of cortical deafness has been facilitated by demonstration of (1) the anatomic defect on CT or MRI scans, and (2) the functional defect with auditory evoked responses. The short latency auditory evoked potentials cover the first ten milliseconds (ms) after auditory stimulation and are familiar to the clinician as the typical ABR used for acoustic neuroma and threshold screening. The MLR begins at 10 ms and extends to fifty to eighty ms.<sup>12-14</sup> The most robust MLR wave, *Pa*, occurs at approximately 30 ms.<sup>13</sup> Late potentials may continue to 500 milliseconds.<sup>12-14</sup>

The ABR measures the integrity of ascending auditory pathways through the upper brainstem. For the

MLR to be useful in the diagnosis of cerebral lesions, basic audiometry and ABR must be normal. The MLR generator, while less extensively studied, has been generally accepted to be located in the area of the primary auditory cortex.<sup>4,7,12-14</sup> This finding is not universally held, as Parving<sup>12</sup> presented a patient with bilateral temporal lobe lesions who had normal MLR recordings. Most physicians believe, however, that lesions in the primary auditory cortex cause a decrease in amplitude or distortion of MLR waves over the involved hemisphere.<sup>14</sup> In patients with normal ABR, the finding of an abnormal MLR is evidence of damage to the auditory cortex.<sup>4,7,13,14</sup>

The patient presented in this report was a difficult diagnostic challenge because he had no speech discrimination in the face of nearly normal pure-tone audiometry. The MLR was helpful in pinpointing this patient's lesion to the auditory cortex. Based on the CT findings and the functional testing with ABR and MLR, it could be determined the discrimination loss was cortical deafness caused by the CVA that occurred in 1984. It was impossible, of course, to tell if the resulting pure-word deafness was caused by the combination of the bilateral auditory temporal lobe lesions or a deep unilateral auditory cortex lesion on the left side. In the rare patient with cortical deafness, the CT or MRI can demonstrate anatomic defects, and the MLR can give functional information about the primary auditory cortex.

## REFERENCES

1. Wernicke C, Friedländer C. Ein Fall von Taubheit in Folge von doppelseitiger Laesion des Schlafelappens. *Fortschr Med* 1883; 1:177-85.
2. Bastian HC. Some problems in connexion with aphasia and other speech defects. *Lancet* 1897;1:1131-7.
3. Mott FW. Bilateral lesion of the auditory cortical center; complete deafness and aphasia. *Brit Med Journ* 1907;2:310-5.
4. Ceesia GG. Organization of the auditory cortical areas of man. *Brain* 1976;99:403-14.
5. Schuknecht HF. *Pathology of the ear*. 1st ed. Cambridge, Mass.: Harvard University Press, 1974:64-72.
6. Jerger J, Weikers NJ, Sharbrough FW III, Jerger S. Bilateral lesions of the temporal lobe—a case study. *Acta Otolaryngol (Stockh)* 1969;(Suppl 258).
7. Ozdamar O, Kraus N, Curry F. Auditory brain stem and middle latency responses in a patient with cortical deafness. *Electroencephalogr Clin Neurophysiol* 1982;53:224-30.
8. Leicester J. Central deafness and subcortical motor aphasia. *Brain and Language* 1980;10:224-42.
9. Earnest MP, Monroe MA, Yarnell PR. Cortical deafness: demonstration of the pathologic anatomy by CT scan. *Neurology* 1977;27:1172-5.
10. Graham J, Greenwood R, Lecky B. Cortical deafness—a case report and review of the literature. *J Neurol Sci* 1980;48:35-49.
11. Benson DF, Geschwind N. The aphasias and related distur-

- bances. In: Baker AB, Baker LH, eds. *Clinical neurology*. 11th ed, Vol. 1. Philadelphia: Harper and Row, 1986:1-18.
12. Parving A, Salomon G, Elberling C, Larsen B, Lassen NA. Middle components of the auditory evoked response in bilateral temporal lobe lesions. *Scand Audiol* 1980;9:161-7.
13. Musiek FE, Geurkink NA, Weider DJ, Donnelly K. Past, present, and future applications of the auditory middle latency response. *Laryngoscope* 1984;94:1545-53.
14. Kraus N, Ozdamar O, Hier D, Stein L. Auditory middle latency responses (MLRs) in patients with cortical lesions. *Electroencephalogr Clin Neurophysiol* 1982;54:275-87.

**AVAILABLE NOW!** The FIVE-YEAR (1981-1985) CUMULATIVE INDEX TO OTOLARYNGOLOGY—HEAD AND NECK SURGERY can be purchased from the Publisher for \$36.00. This comprehensive, 84-page reference guide is a current presentation of all topics included in the Journal from January 1981 through December 1985 (volumes 89-93)—the past 5 volumes. It incorporates complete references to over 570 original articles, abstracts, case reports, letters, editorials, and CME articles. It features 1,473 Subject Headings, under which there are 3,284 references. Each subject entry lists the complete article title, author(s), volume, page, and year of publication. In addition, it includes 2,188 Author Entries, which list contributors, along with their respective titles, author-to-author referral, volume, page, and publication date.

To purchase, call or write: The C.V. Mosby Company, 11830 Westline Industrial Dr., St. Louis, Missouri 63146, or telephone FREE 1-800-325-4177, extension 531, Journal Fulfillment (in Missouri call collect at 314-872-8370, extension 531, Journal Fulfillment). Please reference book code number 2606-4 when placing your order. PREPAYMENT REQUIRED. Make checks payable to The C.V. Mosby Company; (all payments must be in U.S. funds drawn on a U.S. bank). Price: \$36.00 in the U.S., \$38.50 international (price includes mailing charges).