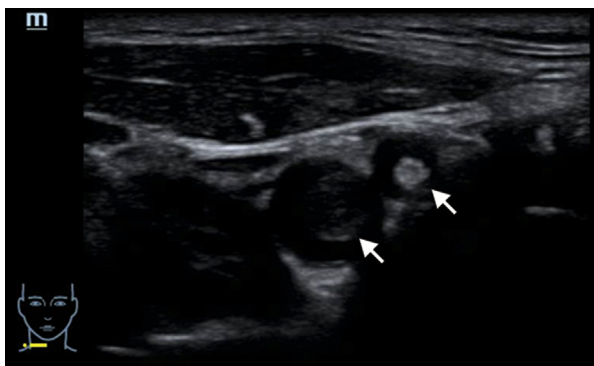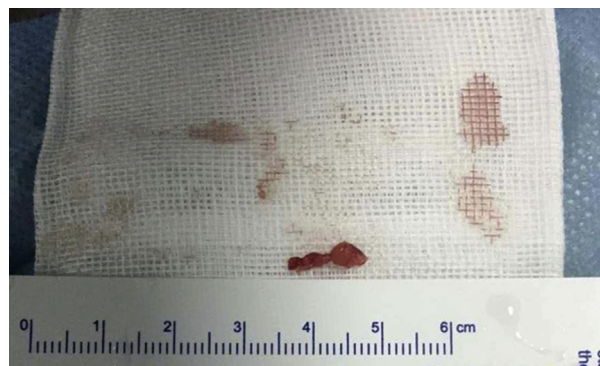
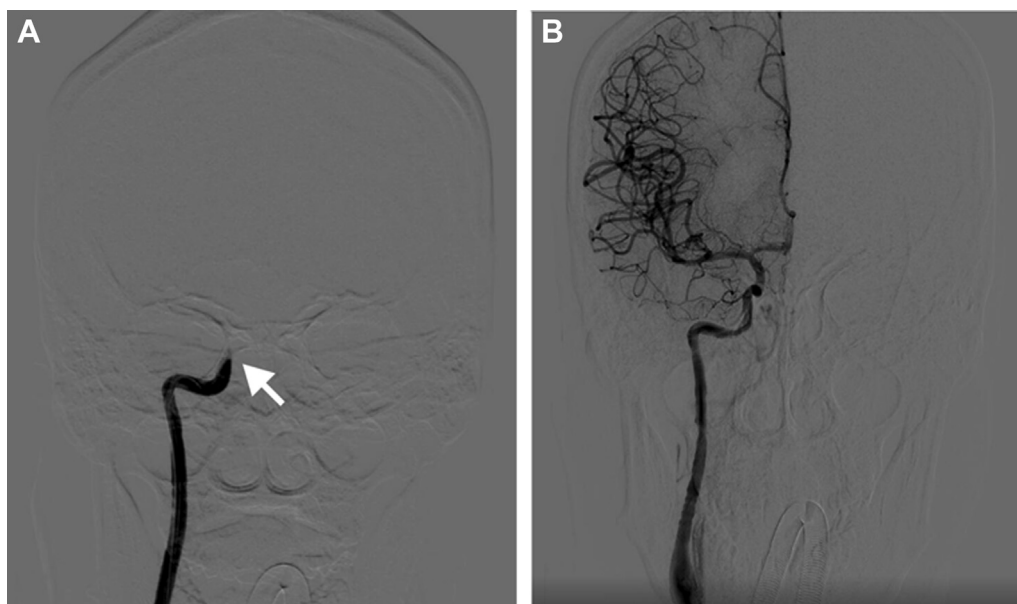




**Figure 1.** Ultrasonography of the carotid vessels, showing solid echoes in the internal (left arrow) and external (right arrow) carotid arteries.



**Figure 3.** The largest fat embolus.



**Figure 2.** A, Preoperative cerebral digital subtraction angiography showing the occluded right internal carotid artery (arrow). B, Postoperative digital subtraction angiography showing the restored forward flow of the right internal carotid artery and the middle and anterior cerebral arteries.

[Ann Emerg Med. 2019;74:305.]

A 30-year-old woman was transported to the emergency department with sudden new-onset seizures and collapse shortly after 5 mL of autologous fat granules was injected into the right side of her forehead during plastic surgery at a private clinic. Her Glasgow Coma Scale score was 7, blood pressure 122/68 mm Hg, pulse rate 68 beats/min, and respiration 18 breaths/min. The emergency physician intubated the patient and obtained ultrasonography of the carotid vessels (Figure 1). Cerebral digital subtraction angiography confirmed the diagnosis (Figure 2).

*For the diagnosis and teaching points, see page 309.*

*To view the entire collection of Images in Emergency Medicine, visit [www.annemergmed.com](http://www.annemergmed.com)*

I choked back tears. *What did I just do?*

My legs regained enough strength to stand, and I looked into the patient's eyes as mine filled up. I held her head and leaned down. "I'm so sorry. I wish you didn't have to experience that, because I have, and it sucks. I hope you can forgive me." I exited the room as the first drop of saline was about to run down my face.

I headed for my desk to start orders.

*...or regroup.*

"Excuse me. My husband would like a pillow." A random lady was standing in front of me.

*Smile.* "Sure. We'll get one."

The room was dark. The glow of the monitors illuminated my patient's face. ICU visits are uncommon for me, but I needed this one.

I leaned on the doorframe and listened to the ventilator's steady cadence. I replayed the events from 2 days prior.

I wanted to apologize. I wanted to hear she didn't remember anything. I needed her forgiveness.

Beep... Beep... Beep... Heart rate 62.

---

*Author affiliations:* United States Air Force, Hurlburt Field, FL.

*Military disclaimer:* The views expressed in this article are those of the author and do not reflect the official policy or position of the Department of the Air Force, Department of Defense, or the US government.

---

## REFERENCE

1. Lyon RF. Take my breath away. *Ann Emerg Med.* 2017;69:253-254.

## IMAGES IN EMERGENCY MEDICINE

(continued from p. 305)

### DIAGNOSIS:

*Cerebral fat embolism.* Ultrasonography showed solid echogenic material in the right internal and external carotid arteries, whereas digital subtraction angiography confirmed that the right internal carotid artery was occluded in the C2 segment (Figure 2A and Video E1 [available online at <http://www.annemergmed.com>]). After arterial embolectomy, postoperative digital subtraction angiography demonstrated restoration of forward flow of the right internal carotid artery and middle and anterior cerebral arteries (Figure 2B and Video E2 [available online at <http://www.annemergmed.com>]). Several fat particles were removed, the largest being  $10 \times 4 \times 3$  mm<sup>3</sup> (Figure 3). The patient died after 20 days because of complications of bilateral massive cerebral infarction.

Symptomatic cerebral fat embolism is a rare and potentially fatal complication arising after trauma or aesthetic surgery.<sup>1-3</sup> Typical signs include deteriorating mental status and progressive respiratory insufficiency within 24 to 48 hours.<sup>4</sup> In our patient's case, the fat granules moved from the superficial temporal artery to the ipsilateral internal carotid artery through the external carotid artery and caused the stroke.

---

*Author affiliations:* From the Department of Emergency Medicine, The First Affiliated Hospital, School of Medicine, Zhejiang University, Hangzhou, People's Republic of China.

---

### REFERENCES

1. Dunkel J, Roth C, Erbguth F, et al. Cerebral fat embolism: clinical presentation, diagnostic steps and long-term follow-up. *Eur Neurol.* 2017;78:181-187.
2. Huo X, Liu R, Wang Y, et al. Cerebral fat embolism as complication of facial fat graft: retrospective analysis of clinical characteristics, treatment, and prognosis. *World Neurosurg.* 2018;120:249-255.
3. Pan JW, He HW, Feng L, et al. Curative embolization of supratentorial arteriovenous malformation by an initial single session: a statistical study on the potential and angiographic predictors. *J Cerebrovasc Dis.* 2018;1:18-26.
4. Godoy DA, Di Napoli M, Rabinstein AA. Cerebral fat embolism: recognition, complications, and prognosis. *Neurocrit Care.* 2018;29:358-365.