

Multiple cerebral sinus venous thrombosis and venous infarct: rare complication of tuberculous meningitis in a child

Indar Kumar Sharawat,¹ Deepanjan Bhattacharya,¹ Lokesh Saini,¹ Paramjeet Singh²

¹Pediatrics, Post Graduate Institute of Medical Education and Research, Chandigarh, India
²Radiodiagnosis and Imaging, Post Graduate Institute of Medical Education and Research, Chandigarh, India

Correspondence to
Dr Lokesh Saini,
drlokeshsaini@gmail.com

Accepted 8 July 2019

DESCRIPTION

A 10-year-old boy presented with fever for the past 1 month. The fever was low grade, intermittent and more in evening and night. It was associated with low-grade neck pain and intermittent bifrontal headache. He had three episodes of generalised tonic-clonic seizures, each lasting for 5 min in last 1 week. The child had excessive sleepiness, decreased interaction and feeding following seizures. There was no history of prolonged cough, haematemesis, apparent cranial neuropathy and bowel or bladder involvement. His grandmother was diagnosed as a case of sputum positive pulmonary tuberculosis (TB) and was on therapy for the past 2 months.

On examination, he had stable vitals, Glasgow coma scale of 13, signs of meningeal irritation (neck rigidity and Brudzinski's sign) and right hemiparesis. Fundus examination did not show choroid tubercles and papilledema. A clinical possibility of tuberculous meningitis (TBM) was considered.

Cerebrospinal fluid (CSF) examination revealed normal opening pressure, lymphocytic pleocytosis (74 WBC/ μ L), hypoglycorrhachia (CSF sugar: 62 mg/dL; blood sugar: 146 mg/dL), elevated protein (220 mg/dL) and elevated adenosine deaminase levels (45 U/L). Gram stain was negative, and culture was sterile for bacterial pathogens. No acid-fast bacilli could be detected and Gene Xpert was positive for *Mycobacterium tuberculosis*. Chest radiography was unremarkable and the tuberculin skin test was negative. HIV serology was non-reactive. Neuroimaging was suggestive of acute haemorrhagic infarcts in right globus pallidus and multiple cerebral sinus venous thrombosis (CSVT) (figures 1 and 2). Procoagulant workup was negative, and the child was started on enoxaparin and anti-tubercular therapy with steroids and physiotherapy. At 4 months of follow-up, the child had mild residual right hemiparesis and was able to walk unsupported without much difficulty. Rest of the neurological examination was normal. Repeat MR venography showed partial recanalisation of venous sinuses and enoxaparin was continued for 6 months.

Central nervous system (CNS) TB is the most devastating form of TB and accounts for approximately 1% of all cases of TB. CNS TB has variable manifestations and may manifest as meningitis, meningoencephalitis, tubercular abscess, tuberculoma or vasculitis. Ischaemic strokes are found in 13%–57% of cases of TBM, occurring mainly in the 'tuberculous zone' involving caudate nucleus,

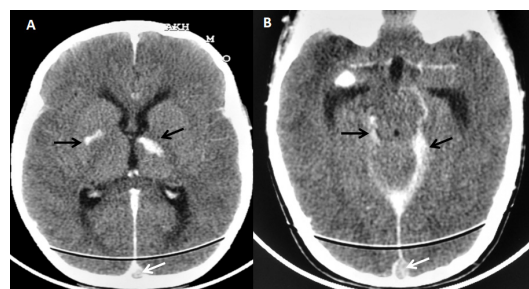


Figure 1 Contrast-enhanced CT of the brain. Axial sections (A, B) showing hyperdensities in right globus pallidus and left thalamus suggestive of acute haemorrhagic infarct (black arrow) (A) and basal exudates (black arrow) (B). There was a filling defect in superior sagittal sinus suggestive of thrombosis (A and B, white arrow).

anterior thalamus, anterior limb and genu of the internal capsule.¹ Around 75% of infarcts occur in the 'tuberculous zone' supplied by the thalamoperforating and medial lenticulostriate arteries.

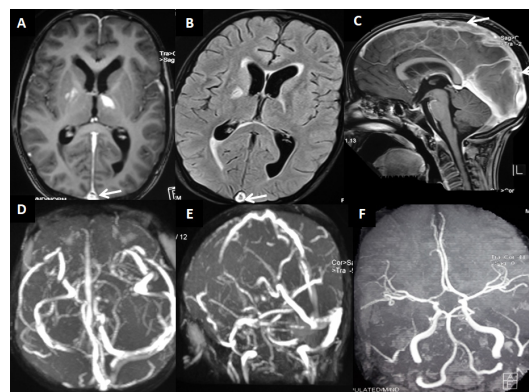
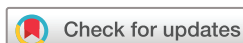

Figure 2 MRI of the brain axial (T1-weighted (A) and Fluid Attenuated Inversion Recovery (FLAIR) (B)) sections showing mild ventriculomegaly, hyperintensities in right globus pallidus, putamen and left anterolateral thalamus, suggestive of the acute haemorrhagic infarct. Superior sagittal sinus was hyperintense along with central hypointensity (A and B, white arrow), suggestive of acute partial thrombosis. Contrast-enhanced T1-weighted sagittal (C) sequences showing a filling defect in the posterior half of superior sagittal sinus (arrow). MR venography showing filling defects in the posterior half of superior sagittal sinus, left transverse sinus and sigmoid sinus (D and E). MR angiography of intracranial arteries was normal (F).



© BMJ Publishing Group Limited 2019. No commercial re-use. See rights and permissions. Published by BMJ.

To cite: Sharawat IK, Bhattacharya D, Saini L, et al. *BMJ Case Rep* 2019;**12**:e231419. doi:10.1136/bcr-2019-231419

Images in...

The cause has been attributed to the involvement of the smaller calibre branches of medial striate, thalamotuberal and thalamostriate perforators by the exudates. Despite the high prevalence of CNS TB in India, cerebral venous infarcts and venous thrombosis are reported quite rarely. The proposed underlying mechanisms are venous stasis, inflammation-induced endothelial injury, procoagulant release and enhanced platelet aggregation.²

Cerebral venous sinus thrombosis has also been described in TBM; however, venous infarction is extremely rare. Endothelial injury increased platelet aggregation and abnormal flow have been proposed in the pathogenesis. Acid-fast bacilli mount a robust immune response in CNS and release various inflammatory chemokines and cytokines, such as CCL2, CCL5, CXCL10, tumor necrosis factor- α , interleukin (IL)-6 and IL-1 β .

Learning points

- ▶ Central nervous system tuberculosis (CNS TB) has varied presentations as meningitis, meningoencephalitis, tubercular abscess and tuberculoma. It can affect the vasculature as well.
- ▶ Cerebral venous sinus thromboses and resultant venous infarct is a rare complication of CNS TB.
- ▶ Thrombosis is usually secondary to endothelial injury by the infection, and increased platelet aggregation, although concurrent procoagulant state must always be ruled out.
- ▶ It is important to differentiate in between an arterial and a venous stroke in the cases of tuberculous meningitis (TBM) as the management of these stroke syndromes will be quite different.
- ▶ In the case of vasculitis or arterial involvement, vessel wall MRI shows circumferential multifocal vessel wall thickening and enhancement and may be useful for the diagnosis of TBM-related vascular complication and monitoring of the treatment.

These inflammatory cytokines have an additive effect on platelet aggregation, procoagulant activity and endothelial cell damage. CSVT usually presents with headache, altered sensorium and other features of raised intracranial pressure and it is difficult to identify in the presence of TBM.² It is important to differentiate in between an arterial and a venous stroke in the cases of TBM as the management of these stroke syndromes will be quite different. In the case of vasculitis or arterial involvement, vessel wall MRI (VWM) shows circumferential multifocal vessel wall thickening and enhancement. VWM may be useful for the diagnosis of TBM-related vascular complication and monitoring of the treatment. CSVT in children is treated by anticoagulation with heparin (conventional or low molecular weight) or oral warfarin for 3 months.³ Infarcts in TBM are usually considered secondary to arteriopathy; however venous infarcts, though rare, should be kept in the differentials.

Contributors IKs: patient management, literature review and initial draft of manuscript preparation. DB: patient management, literature review and initial draft of manuscript preparation. LS: literature review and critical review of manuscript for important intellectual content. He will act as a guarantor of the manuscript. PS: analysis of radiology, critical review of manuscript for important intellectual content and final approval of the version to be published.

Funding The authors have not declared a specific grant for this research from any funding agency in the public, commercial or not-for-profit sectors.

Competing interests None declared.

Patient consent for publication Parental/guardian consent obtained.

Provenance and peer review Not commissioned; externally peer reviewed.

REFERENCES

- 1 Mahadevan A. The enigma of tuberculous vasculopathy - Is it time to review our dogmas? *Neurol India* 2016;64:864–7.
- 2 Verma R, Lalla R, Patil TB, et al. A rare presentation of cerebral venous sinus thrombosis associated with tubercular meningitis. *BMJ Case Rep* 2013;2013:bcr2013009892.
- 3 Kumar RM, Saini L, Kaushik JS, et al. A Combination of Moyamoya Pattern and Cerebral Venous Sinus Thrombosis: A Case of Tubercular Vasculopathy. *J Trop Pediatr* 2015;61:393–6.

Copyright 2019 BMJ Publishing Group. All rights reserved. For permission to reuse any of this content visit <https://www.bmj.com/company/products-services/rights-and-licensing/permissions/>
BMJ Case Report Fellows may re-use this article for personal use and teaching without any further permission.

Become a Fellow of BMJ Case Reports today and you can:

- ▶ Submit as many cases as you like
- ▶ Enjoy fast sympathetic peer review and rapid publication of accepted articles
- ▶ Access all the published articles
- ▶ Re-use any of the published material for personal use and teaching without further permission

Customer Service

If you have any further queries about your subscription, please contact our customer services team on +44 (0) 207111 1105 or via email at support@bmj.com.

Visit casereports.bmj.com for more articles like this and to become a Fellow