

Case Report

Fulminant cerebral venous thrombosis associated with the m.3243A>G MELAS mutation: A new guise for an old disease

Marc Nikolaus^a, Anna Tietze^d, Leonille Schweizer^e, Angela M. Kaindl^{a,b,c},
Werner Stenzel^e, Markus Schuelke^{a,f}, Ellen Knierim^{a,b,f,*}

^a Charité–Universitätsmedizin Berlin, Corporate Member of Freie Universität Berlin, Humboldt-Universität zu Berlin, and Berlin Institute of Health (BIH), Department of Neuropediatrics, Berlin, Germany

^b Charité–Universitätsmedizin Berlin, Corporate Member of Freie Universität Berlin, Humboldt-Universität zu Berlin, and Berlin Institute of Health (BIH), Sozialpädiatrisches Zentrum, Berlin, Germany

^c Charité–Universitätsmedizin Berlin, Corporate Member of Freie Universität Berlin, Humboldt-Universität zu Berlin, and Berlin Institute of Health (BIH), Institute for Cell and Neurobiology, Berlin, Germany

^d Charité–Universitätsmedizin Berlin, Corporate Member of Freie Universität Berlin, Humboldt-Universität zu Berlin, and Berlin Institute of Health (BIH), Department of Neuroradiology, Berlin, Germany

^e Charité–Universitätsmedizin Berlin, Corporate Member of Freie Universität Berlin, Humboldt-Universität zu Berlin, and Berlin Institute of Health (BIH), Department of Neuropathology, Berlin, Germany

^f Charité–Universitätsmedizin Berlin, Corporate Member of Freie Universität Berlin, Humboldt-Universität zu Berlin, and Berlin Institute of Health (BIH), NeuroCure Clinical Research Center, Berlin, Germany

Received 11 March 2019; received in revised form 5 June 2019; accepted 4 July 2019

Abstract

MELAS-syndrome (mitochondrial myopathy, encephalomyopathy, lactic acidosis, and stroke-like episodes) is a multisystem disorder with various presentations. Common clinical manifestations include stroke-like episodes, encephalopathy with seizures, muscle weakness, recurrent headaches and vomiting, hearing impairment, and short stature. Uncommon clinical presentations like cerebral venous thrombosis, which is almost unprecedented for MELAS-syndrome, impede correct diagnosis. We describe a novel presentation of MELAS-syndrome with severe cerebral venous thrombosis (CVT) and inflammation with a vasculopathy that affects the venous system as well. This case does not only extend the clinical spectrum of a multifaceted disease, but offers new clues for the pathomechanism of MELAS-syndrome.

© 2019 The Japanese Society of Child Neurology. Published by Elsevier B.V. All rights reserved.

Keywords: MELAS-syndrome; Cerebral venous thrombosis; Autoimmunity; Mitochondrial angiopathy; Endothelial dysfunction

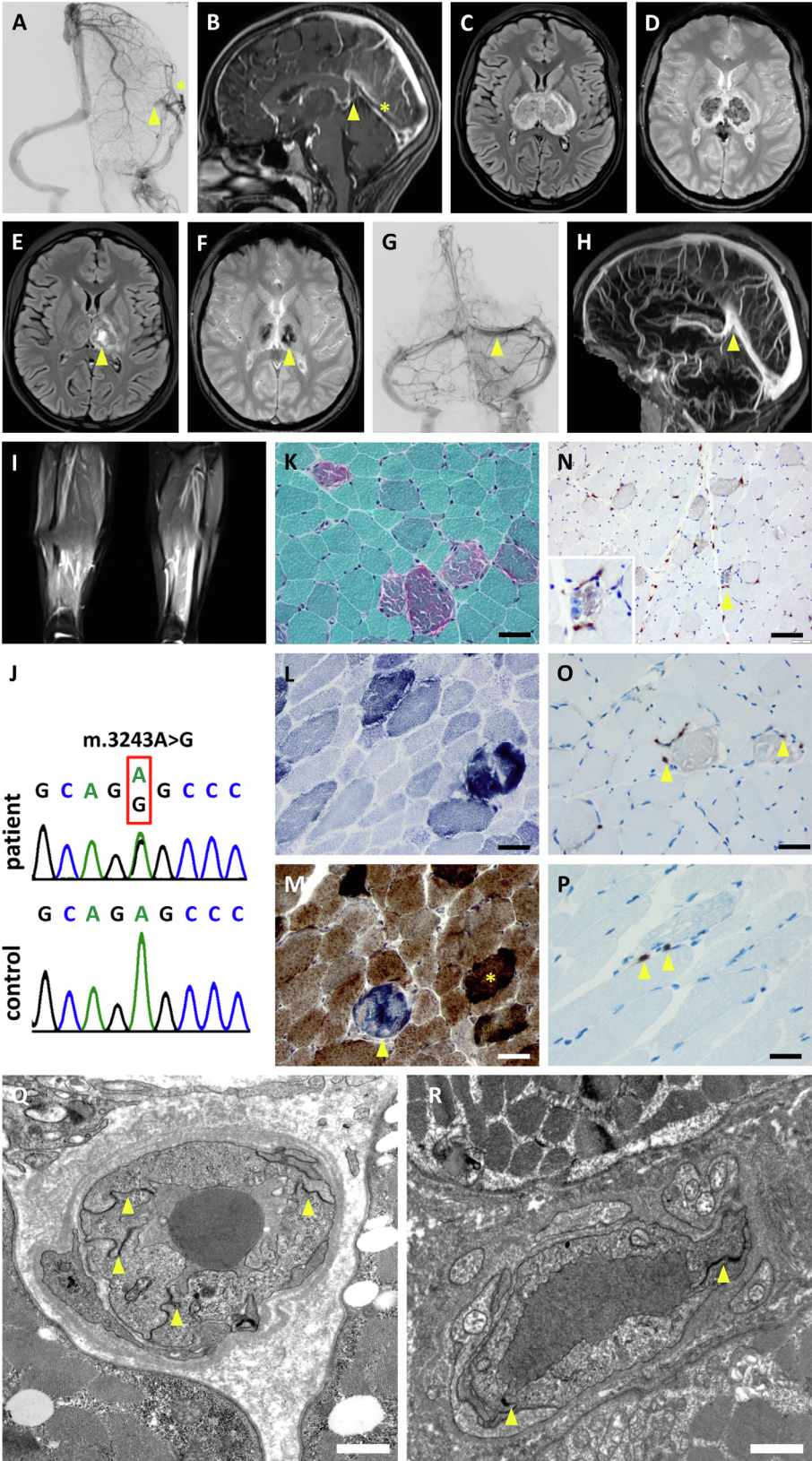
1. Case report

This study has been approved by the appropriate ethics committee and has been performed in accordance

with the ethical standards laid down in the 1964 Declaration of Helsinki. The Informed Consent was taken from the guardian. A 16-year-old girl of short stature presented with headache, vomiting, drowsiness, and elevated D-dimers. Soon she developed a right-sided hemiparesis and a palsy of the right facial nerve. Neuroimaging detected thalamic edema and thrombosis of the left dural venous sinus including the vein of Galen

* Corresponding author at: Department of Neuropediatrics, Charité–Universitätsmedizin Berlin, Augustenburger Platz 1, 13353 Berlin, Germany. Phone: 0049 30 450566112.

E-mail address: ellen.knierimcharite.de (E. Knierim).



(Fig. 1A,B). Despite immediate anticoagulation, her mental state deteriorated rapidly. The unfavorable course with thalamic infarctions (Fig. 1C,D) the following day required interventional thrombectomy that restored perfusion in the sinus and partially in the vein of Galen (Fig. 1E–H). She recovered within one week without persisting signs of neurological deficits. Her medical history revealed oral contraception, her clinical history was not remarkable. Her family history revealed diabetes mellitus of her grandmother on the maternal side as well as intolerance to physical stress. Work-up for thrombophilia, infectious and neoplastic diseases was unremarkable. Inflammatory markers, factor VIII, and von-Willebrand-antigen (vWF-Ag 186%; normal 50–160%) were elevated. A mild serum lactate elevation [31 mg/dl; normal <20] was not followed-up initially. The following year she had two episodes of headache, visual impairment, and gait disturbance. Neuroimaging did not reveal any new pathology. In both instances serum lactate levels rose above 50 mg/dl. Two months later she presented with edema of face and both legs associated with muscle pain and weakness. Cardiomyopathy and thrombosis were ruled out. Factor VIII and vWF-Ag were still elevated, anti-CENPB and anti-PM-Scl75 were highly positive; T₂-hyperintensities on muscle magnetic resonance imaging (MRI) and elevated serum CPK levels [338 U/l; normal <120] suggested myositis (Fig. 1I). Immunosuppression with IV methyl-prednisolone (1 mg/kg/d) had to be discontinued after 5 days due to clinical deterioration and rising lactate levels [107 mg/dl]. This clinical course led us to suspect a mitochondrial disease. In the muscle we found numerous ragged-red fibers (RRFs, Fig. 1K–M) and elevated major histocompatibility complex I expression as well as inflammatory T-cell and macrophage infiltration around the RRFs as signs of inflammation (Fig. 1N–P). Genetic testing identified the “classic” m.3243A>G mtDNA-mutation with 50% heteroplasmy in muscle (Fig. 1J) and secured the diagnosis of MELAS-syndrome 14 months after first admission. Since then, episodes of severe headache and lactic

acidosis were treated efficiently with IV L-arginine (500 mg/kg BW).

Although well-defined at the molecular and phenotypic level, varying clinical presentations and its rarity make MELAS-syndrome difficult to diagnose. In hindsight, the clinical course of our patient appears typical [1]. However, the correct diagnosis was delayed, due to a severe cerebral venous thrombosis (CVT), almost unprecedented for MELAS-syndrome [2]. The often multifactorial etiology of CVT involves infections, thrombophilia, anemia, malignancy, and autoimmune disorders [3]. Contraceptives are an additional risk factor, albeit unlikely to cause such extensive CVT. Potential links between MELAS-syndrome and thrombosis might be (i) *endothelial dysfunction* and *venous angiopathy* or (ii) *autoimmunity* and *inflammation*. (i) MELAS pathogenesis is based on a deficiency of oxidative phosphorylation with decreased ATP-production and subsequent dysfunction of nitric oxide supply resulting in mitochondrial proliferation within the endothelium, wall thickening, endothelial dysfunction, and finally impaired microvascular perfusion. This might lower serum arginine concentrations leading to impaired nitric oxide dependent vasodilatation. Such angiopathy with endothelial dysfunction, vasodilatory deficit, and impaired microvascular perfusion is considered a potential trigger for the stroke-like episodes, but is a predominantly arterial phenomenon [1,4]. Our patient shows a numerical increase and thickening of venular endothelial cells (Fig. 1Q,R) pointing towards endothelial dysfunction and venous angiopathy. This notion is corroborated by the persisting elevation of vWF-Ag, another biomarker of endothelial activation and damage [5]. (ii) Elevated major histocompatibility complex I expression and inflammatory T-cell and macrophage infiltration around the RRFs have not been reported in MELAS-syndrome [6]. Conversely, however, secondary mitochondrial dysfunction is a feature of various chronic inflammatory disorders including autoimmune and neurodegenerative diseases [7]. Autoimmunity and inflammation with their noxious impact on endothelial

Fig. 1. Imaging and histological studies of the patient. (A) Digital subtraction angiography shows blockage of the blood flow through the transverse sinus (*arrowhead*) and formation of cortical collaterals (*asterisk*). (B) MR-venography depicts the blockage of the vein of Galen (*arrowhead*) and the rectus sinus (*asterisk*). (C) T₂w* and (D) FLAIR imaging shows hemorrhagic infarction and edema of both thalami one day after admission. (E,F) Residual defects in the left thalamus (*arrowheads*) after one year. (G,H) Interventional transvenous thrombectomy was performed by aspiration *via* a microcatheter (Sofia 5F) and capture with a stent retriever (Trevor XP 4/20). (G,H) Both veins were re-canalized after thrombectomy (*arrowheads*). (I) T₂-weighted muscle MRI of the lower thighs shows edema and perifascial fluid in all muscle compartments. (J) Sanger sequencing traces of the “classic” m.3243A>G MELAS mutation in muscle DNA with ~50% heteroplasmy. Muscle histology from the quadriceps muscle (K–P) showing RRFs in the Gömöri trichrome- (K), ragged blue fibers in the SDH- (L) and COX-positive ragged brown fibers in the COX-SDH-staining (M). (N) Anti-CD68 staining reveals infiltration by macrophages (*arrowhead*) that cluster around the RRFs (magnified inset). (O) Anti-CD45 staining reveals infiltration by leukocytes around the RRFs (*arrowheads*). (P) Anti-CD8 staining depicts two CD8+ T-cells next to a RRF (*arrowheads*). Size bars: 40 µm (for K–O), 100 µm (for P). Electron microscopic images of a muscle venule of the patient (Q) and a normal control (R). In the patient the endothelium is thickened and the number of endothelial cells is increased to four (*arrowheads* depict tight junctions) as compared to two endothelial cells per circumference in the control sample. Size bars: 1 µm (for Q, R). (For interpretation of the references to colour in this figure legend, the reader is referred to the web version of this article.)

function might be either the direct consequence of the MELAS-mutation or sequelae of vascular and muscle cell damage brought about by mitochondrial dysfunction. In both scenarios it could have aggravated endothelial dysfunction leading to edema and thrombosis.

In conclusion, we describe a novel presentation of MELAS-syndrome with severe CVT and inflammation with a vasculopathy that affects the venous system as well. This case not only extends the clinical spectrum of a multifaceted disease, but offers new clues for the pathomechanism of MELAS-syndrome.

2. Authors' contributions

MN: patient care, data acquisition, analysis and interpretation of data, drafted first version of the manuscript. **AT:** Analysis and interpretation of imaging data. **LS** and **WS:** Analysis and interpretation of histological data. **AMK:** critical revision of manuscript for intellectual content, supervision **MS:** acquisition, analysis and interpretation of sequencing data, critical revision of manuscript for intellectual content, supervision; **EK:** patients care, study design, critical revision of manuscript for intellectual content, supervision

Author disclosures

The authors report no disclosures. No honorarium, grant, or other form of payment was given to anyone to produce the manuscript.

Appendix A. Supplementary data

Supplementary data to this article can be found online at <https://doi.org/10.1016/j.braindev.2019.07.002>.

References

- [1] El-Hattab AW, Adesina AM, Jones J, Scaglia F. MELAS syndrome: clinical manifestations, pathogenesis, and treatment options. *Mol Genet Metab* 2015;116:4–12.
- [2] Lindberg C, Moslemi AR, Oldfors A. MELAS syndrome in a patient with a point mutation in MTTS1. *Acta Neurol Scand* 2008;117:128–32.
- [3] Dlamini N, Billingham L, Kirkham FJ. Cerebral venous sinus (sinovenous) thrombosis in children. *Neurosurg Clin N Am* 2010;21:511–27.
- [4] Koga Y, Akita Y, Junko N, Yatsuga S, Povalko N, Fukiyama R, et al. Endothelial dysfunction in MELAS improved by l-arginine supplementation. *Neurology* 2006;66:1766–9.
- [5] Vischer UM. von Willebrand factor, endothelial dysfunction, and cardiovascular disease. *J Thromb Haemost* 2006;4:1186–93.
- [6] Mancuso M, Orsucci D, Ienco EC, Ricci G, Ali G, Servadio A, et al. An “inflammatory” mitochondrial myopathy. A case report. *Neuromuscul Disord* 2013;23:907–10.
- [7] Escames G, López LC, García JA, García-Corzo L, Ortiz F, Acuña-Castroviejo D. Mitochondrial DNA and inflammatory diseases. *Hum Genet* 2012;131:161–73.