

A Case of Chronic Subdural Hematoma with Anxiety States and Concomitant Regression-Like Symptoms

Takeshi Sato, M.D. and Masashi Takeichi, M.D.

Department of Psychiatry, Saga Medical School, Saga

Abstract: The authors described an epileptic suffering from head trauma in whom anxiety states and concomitant regression-like symptoms masked the diagnosis of chronic subdural hematoma. Along with the occurrence of chronic subdural hematoma, psychic symptoms were manifested including the anxiety and regression of personality. However, after the chronic subdural hematoma was neurosurgically evacuated, these psychic symptoms gradually disappeared.

In the study of organic and symptomatic psychosis, Mackenzie and Popkin (1983) have proposed the concept of an organic anxiety syndrome on the ground that DSM-III provides no organic equivalent for anxiety disorders. Therefore, we presented a case of chronic subdural hematoma in which the direct effect on CNS of this pathological condition was considered to bring about the above-mentioned anxiety disorders with regression-like symptoms.

Key Words: *epileptic, head trauma, chronic subdural hematoma, anxiety states, regression*

Jpn J Psychiatr Neurol 41: 663-667, 1987

INTRODUCTION

The most characteristic symptoms of chronic subdural hematoma (CSDH) are intermittent headaches, slight or severe impairment of intellectual faculties and hemiparesis.⁵ However, it is difficult to diagnose CSDH in the first stage because the neurological signs are still obscure and sometimes absent. One thus needs to pay attention to the psychiatric symptoms and assess them judiciously.

According to Black,² significant psychiatric symptoms of subdural hematoma (SDH) are delirium in the old and coma in the young patient. In addition, Alarcon, Thweatt¹ and Wood⁷ report several cases of severe depression with conversion-like symptoms and catatonia.

Today, with respect to the classification and diagnosis of mental disorders in DSM-III, the multiaxial classification system has gradually been adopted in everyday clinical works. However, this manual has not offered any organic equivalent for anxiety disorders so that Mackenzie and Popkin (1983)⁴ have proposed the concept of an organic anxiety syndrome.

Recently the authors encountered a case of epilepsy with borderline intellectual func-

Received for publication April 3, 1987.

Mailing address: Takeshi Sato, M.D. and Masashi Takeichi, M.D., Department of Psychiatry, Saga Medical School, Oaza-Nabeshima-Sanbonsugi, Nabeshima-cho, Saga 840-01, Japan.

tioning and complaints of persistent headaches. The patient had no neurological abnormalities in spite of a history of head trauma and was eventually diagnosed to be CSDH accompanied by anxiety states with regression-like symptoms which manifested itself at a later time. Thus in this paper we described this case because it corroborates the concept of an organic anxiety syndrome according to Mackenzie and Popkin.

CASE REPORT

A 37-year-old unmarried epileptic woman was admitted to the psychiatric ward in Saga Medical School Hospital for evaluation because of a headache which lasted for about two days following a head trauma.

At age 11 she suffered a high fever from tuberculous meningitis and her illness was very severe to the extent that broken inguinal lymph nodes were observed. Thereafter, she suffered from convulsive seizures on a number of occasions with a loss of consciousness in spite of the appropriate treatment for tuberculous meningitis. With subsequent medication the frequency of her seizures was reduced to about five times a year. She attended a women's junior college and graduated from it without any trouble. At age 26 she joined a religious organization and discontinued medication under its influence. Subsequently, seizures began to occur more frequently and more severely than before. Since age 35 she has been undergoing treatment in the psychiatric outpatient department of Saga Medical School Hospital, but her seizures have not been controlled adequately with anticonvulsant therapy. The recent frequency of convulsions was once or twice a day. She had not yet experienced severe head trauma.

The episode was as follows: When she was about to go to a garden alone, she fell on a concrete floor because of a sudden convulsive seizure. She struck her head and was momentarily unconscious. On waking, she began to complain of a headache. She was

then taken by ambulance to a local emergency hospital, where she was examined and the laceration of the head closed. A further evaluation revealed no evidence of significant abnormal neurological signs and skull fracture.

Although she received appropriate treatment, she was later taken to the emergency ward in Saga Medical School Hospital because she still complained of a persisting headache and feeling of dizziness and anxiety. A complete neurological evaluation in the emergency ward revealed the following: Roentgenogram of the skull showed evidence of a linear fracture in the right occipital bone. A computerized tomography scan of the brain (CT brain scan) (Fig. 1) was performed, and it revealed a slight dilatation of the left lateral ventricle and Sylvius's fossa, abnormal calcification on the left temporal lobe and atrophy of the left hemisphere. Her condition was very probably the result of tuberculous meningitis at age 11. There was no evidence of a shift of the midline in the CT brain scan. The electroencephalogram did not show any changes of difference in the electrical activity of both hemispheres. It was considered that the patient's problems were primarily functional. Consequently, psychiatric consultation was requested because she complained of headaches and refused to go home.

She was admitted to the psychiatric ward for severe symptoms of anxiety. A mental status examination revealed that she was alert, oriented to time, place and person, attentive over a long period of time, and remembered recent events. There was no disturbance of consciousness. While being interviewed, she often complained of headaches, frowned sometimes and appeared very sad. A neurological examination revealed that her sensory system was normal and deep tendon reflexes were symmetrical. There was no Babinski's sign. There was no rigidity nor tremor in the extremities. Her muscular strength did not diminish. However, ataxic gait, which was observed before the accident,

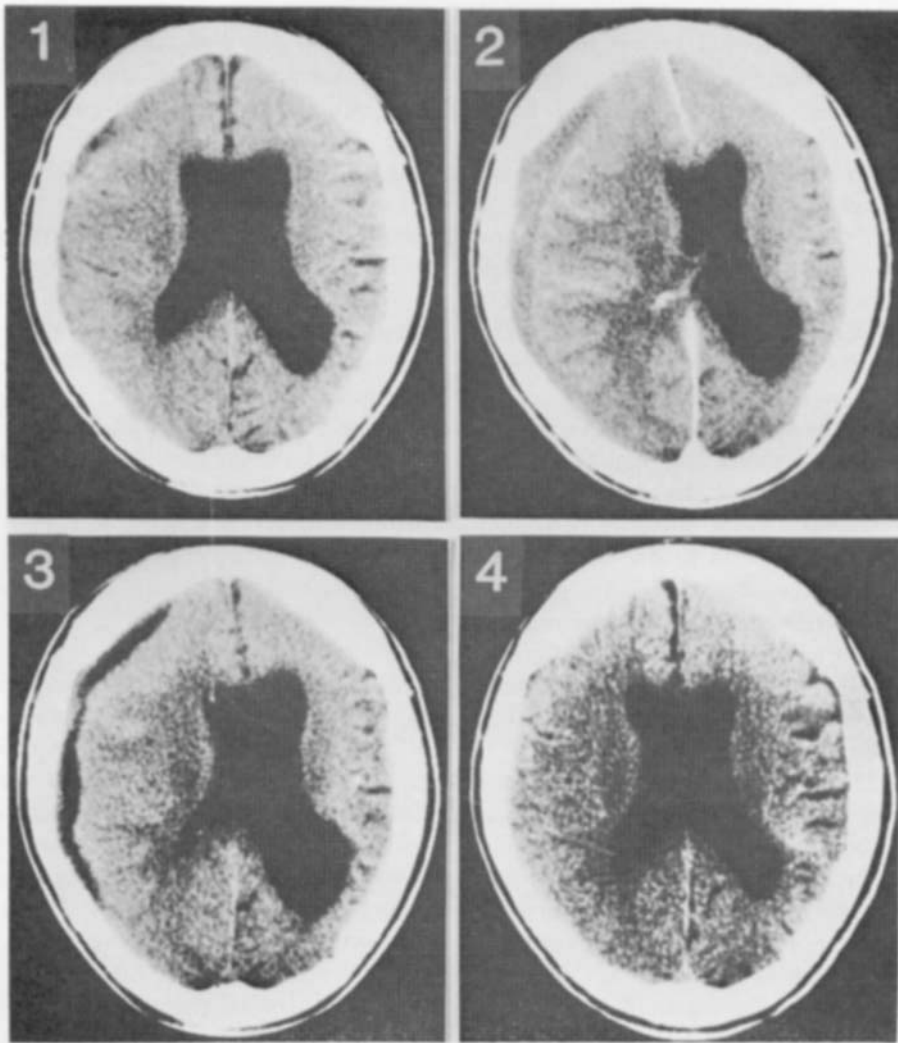


Fig. 1: On admission. Fig. 2: On the 19th day after admission. Fig. 3: On the 15th day after the operation. Fig. 4: On the 40th day after the operation.

may be due to a side effect of the long administration of diphenylhydantoin. Nuchal stiffness and Kernig's sign were absent. There was no feature of a choked disc. The result of laboratory studies (including electrolytes, BUN, creatine, glucose, liver function) was normal, but pancytopenia, which is a side effect of antiepileptic drugs, was found.

Her feeling of nausea on admission gradu-

ally disappeared. Frequently, she had a vague headache that seemed to be persistent, but there were no neurological changes.

On the 19th day after admission she became restless, irritable and often called for medical assistance. She said, "I want to take a bath with you" or "I want you to stay in the hospital and sleep with me because I cannot sleep alone. I often awake in a state of recollecting the head trauma." Further-

more, she complained that she felt detached and did not want to participate in recreational activities. She manifested a demanding attitude, unreasonable expressions of helplessness, and an inability to look after herself. She seemed to have regressed to a more infantile level of functioning.

On the 20th day after admission she complained of pains in several places, such as in the cheek, the back of the head, the left arm, both legs, etc., but the physical examination disclosed no structural abnormalities. We were at a loss what to do for her because sometimes there was no end to her complaints of pains. She manifested behaviors so agitated and desperate that she would lay hands on the medical personnel when we did not give in to her request.

On the 22nd day after admission she was prescribed aspirin because she demanded a pain-killing drug to relieve her suffering. Later she said with a smile that the pain had been relieved. Her behavior then became markedly childish.

On the 23rd day after admission she complained as usual of somatic discomfort. However, she forgot her afflictions while she was absorbed in a game of "Oslo." Meanwhile, she was restlessly hanging around the nurse's station manifesting high-anxiety states, and telling everyone of her past illnesses as soon as she got hold of them in the hall.

On the 25th day after admission she seldom complained of headaches, but wearied us with complaints of colitic disorders.

In the middle of the night on the 26th day after admission she complained of insomnia at the nurse's station but fell asleep with a prescription of 5 mg of diazepam.

Between the 19th and 26th days of admission, we could no longer detect the symptoms of low attention span, disorientation, and the mistaken identities which suggested to us the clouding of consciousness so that no electroencephalogram was made.

On the 27th day after admission a CT brain scan was carried out (Fig. 2). This

revealed a sickle-shaped low density area which extended from the right frontal lobe to the temporal lobe and a midline which had significantly shifted from right to left. The diagnosis of CSDH was then established. An emergency operation was performed to evacuate the hematoma. Therefore, the electroencephalogram could not be further carried out at this point.

As CSDH disappeared, she recovered her personality and intellect, and her regression gradually disappeared. A CT brain scan was performed on the 15th and 40th days after the operation (Figs. 3 and 4). Using the Kohs-block-design test she exhibited an intelligence quotient (IQ) of 69 immediately before discovering CSDH, but an IQ of 79 six months after being discharged.

DISCUSSION

SDH is more common among epileptics, alcoholics, paretics and the senile who are all more prone to a head trauma. With regard to psychiatric symptoms of SDH, Cameron³ reported that 92 percent of those with SDH fell into three groups of symptomatology; hemiparesis, personality or intellectual changes, and raised intracranial pressure. Personality and intellectual changes are a more common feature than that of raised intracranial pressure. Recently, DSM-III, which is used in everyday clinical work, defined organic brain syndrome for delirium, amnesic, organic delusional, organic hallucinosis, organic affective and organic personality syndrome. Tsuboi and his associates⁶ reported that the primary preoperative psychiatric symptom is that of a disorder of intellectual capacity including memory and orientation disturbances, classifiable as the amnesic syndrome and dementia, respectively.

The initial diagnosis of this case was made on the basis of observed anxiety states and by the exclusion of other diseases. We thought that the trauma to her head created a degree of stress which was so psychologi-

cally severe that it produced a state of anxiety with regression in both her behavior and attitude. Moreover, she was a very unhappy person, who had a chronic illness and a borderline intellectual level of functioning.

In this case, an etiological relationship between CSDH and anxiety could be established since the anxiety states gradually disappeared after CSDH was neurosurgically evacuated.

However, DSM-III provides no organic equivalent for anxiety disorders. In anxiety disorders, no specific organic factor can be demonstrated. Therefore, Mackenzie and Popkin⁴ have proposed the diagnostic criteria for an organic anxiety syndrome because recurrences of persistent anxiety or panic attacks are caused by a specific organic factor.

We have presented a case of CSDH with anxiety and concomitant regression-like symptoms. We hope that this case will stimulate psychiatric physicians to pay closer attention to psychiatric symptoms that suggest an organic basis.

REFERENCES

1. Alarcon, R.D. and Thweatt, R.W.: A case of subdural hematoma mimicking severe depression with conversion-like symptoms. *Am J Psychiatry* **140**: 1360-1361, 1983.
2. Black, D.W.: Mental changes resulting from subdural hematoma. *Br J Psychiatry* **145**: 200-203, 1984.
3. Cameron, M.M.: Chronic subdural hematoma: a review of 114 cases. *J Neurol Neurosurg Psychiatry* **41**: 834-839, 1978.
4. Mackenzie, T.B. and Popkin, M.K.: Organic anxiety syndrome. *Am J Psychiatry* **140**: 342-344, 1983.
5. Merrit, H.H.: A textbook of neurology (6ed). Lea and Febinger, Philadelphia, pp. 334-342, 1979.
6. Tsuboi, K., Maki, Y., Nose, T. and Matsuki, T.: Psychiatric symptoms of patient with chronic subdural hematoma. *Neurological Surgery Jpn* **12**: 275-279, 1984 (in Japanese).
7. Woods, S.W.: Catatonia in a patient with subdural hematoma. *Am J Psychiatry* **137**: 983-984, 1980.