

Pure Cortical Stroke Causing Hemichorea-Hemiballismus

Sara Strauss, DO, Daniel Rafie, MD, Anitha Nimma, MD,
Raquel Romero, MD, and Philip A. Hanna, MD

Background: Movement disorders including hemichorea-hemiballismus as the initial presentation of an acute ischemic stroke are uncommon. Structures outside of the deep subcortical areas such as the subthalamic nucleus or basal ganglia are rarely involved. **Case Report:** We report a case of a 72-year-old man with vascular risk factors who presented with acute onset right-sided hemichorea-hemiballismus. Metabolic-, infectious-, and toxic-related conditions were ruled out, his EEG was without epileptiform changes. An MRI confirmed an acute ischemic stroke in the parieto-occipital region without any subcortical structures involved. Atrial Fibrillation was later discovered during his hospitalization and was treated appropriately. **Conclusions:** Although rare, strokes outside of the subthalamic nucleus can result in hemichorea-hemiballismus.

Key Words: Stroke—movement disorder—hemichorea—hemiballismus

Published by Elsevier Inc.

Introduction

Movement disorders including hemichorea-hemiballismus as the initial presentation of an acute ischemic stroke are uncommon. In a large hospital-based registry of 5009 acute stroke patients, the incidence was reported to be 0.54%.¹ The etiologic lesion is classically subcortical, with or without involvement of the subthalamic nucleus. Alarcon et al. showed that the probability of developing a poststroke involuntary movement disorder was 3 times higher when the vascular lesion was deep in location vis-a-vis surface infarcts.² We report a case of a 72-year-old male clinically presenting with acute right-sided hemichorea-hemiballismus resultant of an acute parieto-occipital lobe infarct, without involvement of the deeper structures.

From the Hackensack Meridian Health JFK Medical Center, Neurology Department, Edison, New Jersey.

Received April 25, 2019; revision received July 1, 2019; accepted July 6, 2019.

There were no sponsorships or financial support for the study.

Address correspondence to Sara Strauss, DO, 65 James Street, Edison, NJ, 08820. E-mails: sara.strauss@hackensackmeridian.org, strauss07@gmail.com.

1052-3057/\$ - see front matter

Published by Elsevier Inc.

<https://doi.org/10.1016/j.jstrokecerebrovasdis.2019.07.003>

Case Report

A 72-year-old male with a past medical history of hypertension, diabetes, and COPD, was transferred from an outside hospital for evaluation of abnormal movements of the right upper extremity. He was noted to have involuntary, nonrhythmic, flailing, uncontrollable movements of the right upper extremity. Noncontrast CT scan of the head was without acute findings. Metabolic, infectious, and toxic encephalopathy was ruled out. He was treated with Keppra 1 g BID for possible seizures without improvement of his symptoms. The patient was subsequently transferred to our hospital for further care.

Upon evaluation he had persistent right-sided hemichorea-hemiballistic movements as described above. The movements were absent during sleep. An EEG was negative for epileptiform changes. An MRI of the brain without contrast demonstrated patchy areas of restricted diffusion consistent with acute infarcts in the left parieto-occipital region (Fig 1). MRA of the head and neck ruled out stenosis or occlusions. Aspirin 81 mg daily and a high dose statin were initiated for secondary stroke prevention. Laboratory investigations including HIV, ANA, lupus anticoagulants, ASO antibodies, RPR, and ceruloplasmin levels were within normal limits. The patient's hemiballismus improved with initiation of Clonazepam. Keppra was subsequently discontinued. His hospital course was

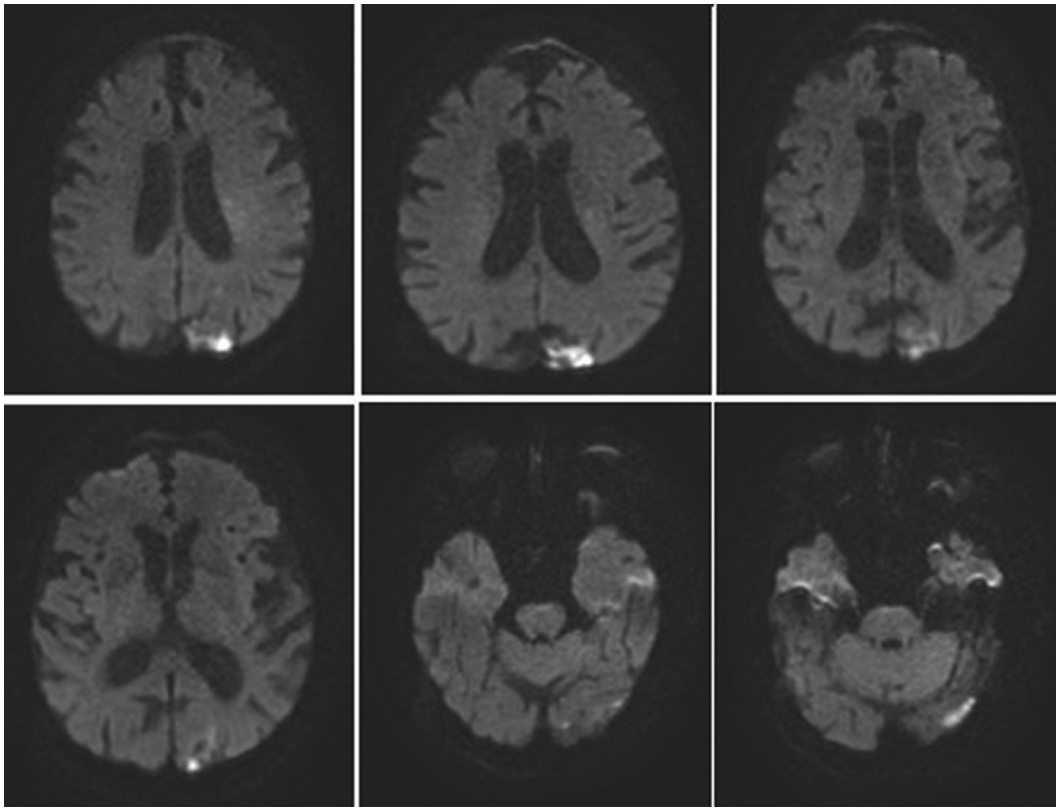


Figure 1. Diffusion-weighted MRI brain.

complicated by pneumonia and MRSA bacteremia with septic shock, which correlated with an acute worsening of his hemiballismus associated with increased amplitude and frequency. A repeat EEG returned negative for seizure activity. Paroxysmal atrial fibrillation was noted during his ICU stay which was treated appropriately. Mild improvement with residual hemiballismus was noted. He was discharged on clonazepam with planned outpatient follow-up.

Discussion

Subcortical ischemic strokes are most commonly reported to cause hemichorea-hemiballismus.¹⁻³ Infarcts classically involve the contralateral subthalamic nucleus. Pure cortical strokes causing hemichorea-hemiballismus are rare and infrequently reported. The prognosis is however better in patients with cortical strokes, as the rate of disappearance of hemichorea is significantly higher than in those with subthalamic lesions.¹ The proposed pathophysiologic mechanism of our patient's movement disorder is suspected to be from interruptions of the intercortical and/or cortical-ganglionic connections. A study using lesion

network mapping techniques showed that although lesions identified in cases of hemichorea-hemiballismus were heterogeneous in location, a shared network was present.⁴ The patient's hospitalization was complicated by sepsis with multiple metabolic derangements which likely exacerbated his involuntary movements. Our case highlights that lesions outside of the subthalamic nucleus can result in hemichorea-hemiballismus.

References

1. Chung SJ, Joo-Hyuk Im, Lee Myoung C, et al. Hemichorea after stroke: clinical-radiological correlation. *J Neurol* 2004;251:725-729.
2. Alarcon F, Zijlmans JCM, Duenas G, et al. Post-stroke movement disorders: reports of 56 patients. *J Neurol Neurosurg Psychiatry* 2004;75:1568-1574.
3. Ghika-Schmid F, Ghika J, Regli F, et al. Hyperkinetic movement disorders during and after acute stroke: the Lausanne Stroke Registry. *J Neurol Sci* 1997;146: 109-116.
4. Laganier Simon, Boes Aaron D, Fox Michael D. Network localization of hemichorea-hemiballismus. *Neurology* 2016;86(23):2187-2195.