



Delusional parasitosis as presenting symptom of occipital lobe cerebrovascular accident☆

Nathan L. Haas, MD^{a,*}, Adam Nicholson, MD^b, Mary R.C. Haas, MD^a

^a Department of Emergency Medicine, University of Michigan, Ann Arbor, MI, USA

^b Department of Emergency Medicine, University of Wisconsin, Madison, WI, USA

ARTICLE INFO

Article history:

Received 17 July 2019

Accepted 24 July 2019

Available online xxxx

Keywords:

Delusional parasitosis

Cerebrovascular accident

Psychosis

Delusions

ABSTRACT

Delusional parasitosis manifests as a fixed, false belief that an individual is infested by living organisms. Primary delusional parasitosis is a psychiatric disorder with the delusion as an isolated manifestation, whereas secondary delusional parasitosis is a delusion occurring secondary to a psychiatric disorder, substance use, or medical illness. A 62-year-old woman with no psychiatric history presented to the Emergency Department with two to three months of “whole body itching” and seeing small insects crawling on her skin and in her hair. Exam of her skin and scalp was notable for no appreciable lesions, rashes, excoriations, or insects. Her neurologic exam was notable for full visual fields, and no localizing deficits. A non-contrast head CT demonstrated a nonspecific heterogeneous low-attenuation lesion within the medial right occipital lobe, and a follow up MRI confirmed a right posterior cerebral artery distribution subacute infarction. She was admitted for two days, and ultimately was discharged on aspirin and atorvastatin for secondary prevention. An emergency physician should remain vigilant in his/her assessment of patients with seemingly psychiatric symptoms, in particular elderly patients with no known psychiatric illnesses. Neuroimaging should be amongst studies considered in the evaluation of elderly patients presenting with new onset psychiatric complaints.

© 2019 Elsevier Inc. All rights reserved.

1. Introduction

Delusional parasitosis (also commonly referred to as delusional infestation) is a psychiatric disorder in which a patient has a fixed, false belief that his body has been infested with some form of foreign body. Patients may believe they are infested with bacteria, fungi, parasites, insects, worms, inanimate objects, fibers, or hair. Patients with delusional parasitosis generally present with symptoms that include burning, itching, crawling, biting, and stinging [1,2]. A large proportion of patients with delusional parasitosis are not seen by psychiatric professionals due to the patient's belief that he has a primarily medical condition [1-3].

Delusional parasitosis can be classified as either primary or secondary. Primary delusional parasitosis is a primarily psychiatric disease in which a patient has the delusion that his body has been infested. Secondary delusional parasitosis is caused by an underlying medical condition, is a symptom rather than disease, and can be caused by many disease states. Delusional parasitosis has a bimodal age distribution,

with peaks in young adulthood and greater than 50 years of age, and has a slight female predominance. While the exact prevalence of this disease is unknown, it is believed to be relatively uncommon [1,3].

The pathophysiology of delusional parasitosis is poorly understood with multiple hypothesized theories, including an excess of extracellular dopamine within the striatum [4]. We describe a case of a female patient who presented with delusional parasitosis and was found to have subacute ischemia in the right posterior cerebral artery distribution.

2. Case report

A 62-year-old woman with a past medical history of chronic obstructive pulmonary disease, peripheral arterial disease, and no psychiatric history presented to the Emergency Department with two to three months of “whole body itching.” She described seeing small insects crawling on her skin and in her hair, and had taken several photographs of what she described as small insects, though on review of the images no insects were seen by the Emergency Physician. She had previously been treated with courses of permethrin and ivermectin for presumed scabies and cephalexin for presumed cellulitis without improvement. On further questioning, she later endorsed a vague visual disturbance out of her left eye for two weeks that she

☆ This research did not receive any specific grants or funding from agencies in the public, commercial, or not-for-profit sectors.

* Corresponding author at: University of Michigan, Taubman Center B1354, 1500 E Medical Center Dr, SPC 5303, Ann Arbor 48109-5305, MI, USA.

E-mail address: haasn@med.umich.edu (N.L. Haas).

could not characterize further. She denied further neurologic, physical, or psychiatric complaints.

On arrival to the ED, vital signs were temperature 37.1 °C, heart rate 85 beats per minute, blood pressure 140/63 mmHg, 17 respirations per minute, and oxygen saturation 96% on room air. Exam of her skin and scalp was notable for no appreciable lesions, rashes, excoriations, or insects. Her neurologic exam was notable for full visual fields, and no localizing deficits.

A non-contrast head CT demonstrated a nonspecific heterogeneous low-attenuation lesion within the medial right occipital lobe (Fig. 1). A follow up MRI demonstrated a right posterior cerebral artery distribution subacute infarction corresponding to the CT abnormality, with multiple foci of restricted diffusion predominantly in the right occipital lobe (Fig. 2). She was evaluated by neurology, admitted for two days, and ultimately discharged on aspirin and atorvastatin for secondary prevention.

3. Discussion

We present a case of delusional parasitosis as the presenting symptom of an occipital lobe cerebrovascular accident in a 62-year-old woman. To our knowledge, this is the first case report of delusional parasitosis secondary to a cerebrovascular accident in the emergency medicine literature.

The mechanism by which stroke leads to psychiatric symptoms has been hypothesized to be related to disruption of neurotransmitter systems or structural damage to neuronal pathways [5]. Delusions arising from primary central nervous system lesions may be the result of the lesion disrupting limbic-cortical associations with an abnormal response interacting with intact cortex [6].

The symptoms of delusional parasitosis have been reported to last from two months to 20 years [7]. Management of delusional parasitosis requires first determining whether the delusion is a primary delusional infestation (a psychiatric disorder with the delusion as an

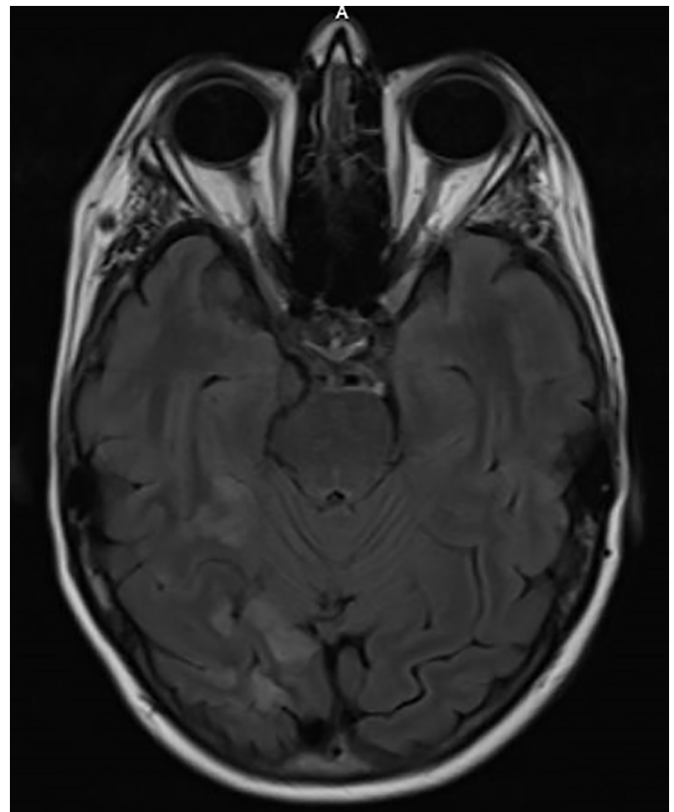


Fig. 2. MRI brain with and without contrast demonstrating multiple foci of restricted diffusion predominantly in the right occipital lobe, consistent with right posterior cerebral artery distribution subacute infarct.

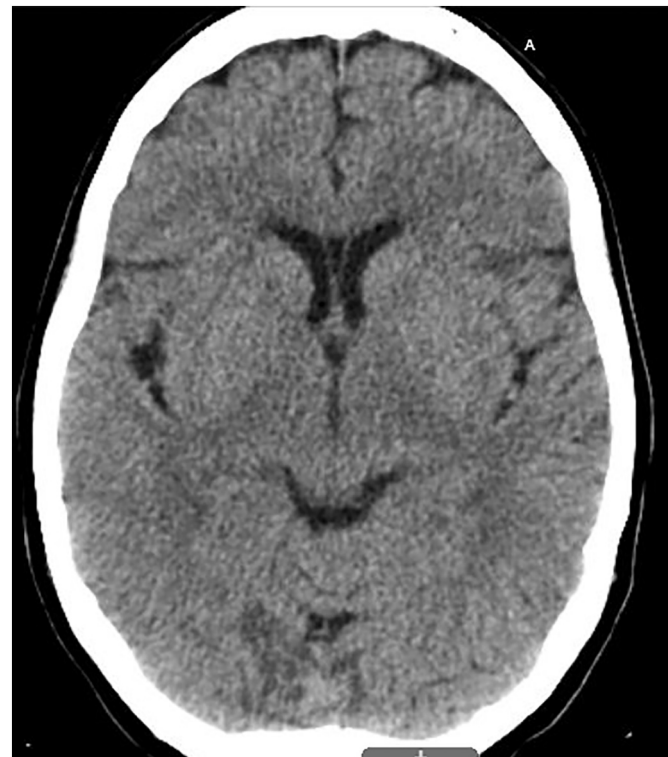

Fig. 1. Non-contrast head CT demonstrating nonspecific heterogeneous low-attenuation lesion within the medial right occipital lobe.

isolated manifestation) or a secondary delusional infestation (a delusion occurring secondary to a psychiatric disorder, substance use, or medical illness, as in this patient). Primary delusional parasitosis is often managed with an antipsychotic, whereas secondary delusional parasitosis is best managed by addressing the underlying cause.

For patients presenting to the emergency department with delusions or other psychiatric symptoms, both organic and non-organic causes of symptoms should be considered. Underlying medical (non-psychiatric) causes of delusions include infectious, toxicologic, traumatic, endocrinologic, neoplastic, structural, ischemic, and metabolic etiologies. The emergency physician should consider a psychiatric cause of delusions as a diagnosis of exclusion, made only after medical causes have been ruled out. An emergency physician should remain vigilant in his/her assessment of patients with seemingly psychiatric symptoms, in particular elderly patients with no known psychiatric illnesses. Neuroimaging (such as head computed tomography) should be considered for patients presenting with delusional parasitosis prior to assuming a psychiatric etiology, particularly in elderly patients or those with stroke risk factors.

References

- [1] Kohorst JJ, Bailey CH, Andersen LK, Pittelkow MR, Davis MDP. Prevalence of delusional infestation—a population-based study. *JAMA Dermatol.* 2018 May 1; 154(5): 615–617. doi:<https://doi.org/10.1001/jamadermatol.2018.0004>. PubMed PMID: 29617524; PubMed Central PMCID: [PMC6128498].
- [2] Suh MD, Keystone MD. In: Hermann MD, Ofori MD, editors. Delusional infestation: Epidemiology, clinical presentation, assessment and diagnosis. UpToDate; 2018 Retrieved July 3rd 2019 from <https://www.uptodate.com/contents/delusional-infestation-epidemiology-clinical-presentation-assessment-and-diagnosis>.
- [3] Heller MM, Wong JW, Lee ES, Ladizinski B, Grau M, Howard JL, et al. Delusional infestations: clinical presentation, diagnosis and treatment. *Int J Dermatol* 2013;52(7):775–83. <https://doi.org/10.1111/ijd.12067> Jul. [Review. PubMed PMID: 23789596].

- [4] Huber M, Kirchler E, Karner M, Pycha R. Delusional parasitosis and the dopamine transporter. A new insight of etiology? *Med Hypotheses* 2007;68(6):1351–8. <https://doi.org/10.1016/j.mehy.2006.07.061> [Epub 2006 Nov 28. PubMed PMID: 17134847].
- [5] Nagaratnam N, O'Neile L. Delusional parasitosis following occipito-temporal cerebral infarction. *Gen Hosp Psychiatry*. 2000 Mar-Apr; 22(2): 129–32. PubMed PMID: [10896495].
- [6] Cummings JL. Organic delusions: phenomenology, anatomical correlations, and review. *Br J Psychiatry* 1985;146:184–97 Feb. [Review. PubMed PMID: 3156653].
- [7] Munro A. Monosymptomatic hypochondriacal psychosis. *Br J Psychiatry Suppl* 1988 Jul;2:37–40 [Review. PubMed PMID: 3072051].