

Prolonged anterograde amnesia and disorientation after anterior communicating artery aneurysm coil embolisation

Zein Al-Atrache,¹ Brett Friedler,² Hamza A Shaikh,¹ Tapan Kavi³

¹Neurosurgery, Cooper University Hospital, Camden, New Jersey, USA

²College of Osteopathic Medicine, Rocky Vista University, Parker, Colorado, USA

³Neurology and Neurosurgery, Cooper University Hospital, Camden, New Jersey, USA

Correspondence to
Dr Zein Al-Atrache,
zeinal@pcom.edu

Accepted 12 July 2019

DESCRIPTION

A 64-year-old man with a previous medical history of hypertension and non-specific focal seizures was admitted for treatment of recurrent anterior communicating artery aneurysm (ACoA). He had previous treatment of the ACoA twice but the aneurysm recanalised again and had grown in size from 1.8 cm in greatest dimension to 2.6 cm and associated with 6 x 7 mm of residual filling (figure 1). He was retreated with stent-assisted coil embolisation.

The day after endovascular intervention, he was disoriented to time and situation, confused and inattentive. He was also agitated with pressured speech, unable to recognise his wife, exhibited intermittent expressive aphasia and poor short-term recall after 5 min. His inpatient medication was not contributory to his new-onset altered mental status, as he remained on his home medication of levetiracetam (750 mg two times per day), metoprolol (50 mg two times per day), methadone (50 mg daily) and topical testosterone gel. Despite undergoing treatment for a urinary tract infection, poor mentation persisted, prompting brain MRI that revealed diffusion-restricted, punctate acute ischaemic foci in the fornix and the left frontal and bilateral parietal lobes (figure 2). Psychological evaluation 7 days into his hospital stay revealed a Montreal Cognitive Assessment score of 16/30 and severe anterograde amnesia with visual memory more preserved than verbal memory. His neurological exam otherwise remained benign. He was ultimately discharged shortly thereafter with minimal improvement.

Outpatient neuropsychiatric evaluation 1 month following endovascular revision revealed abnormalities with complex attention, executive function, and most significantly, anterograde amnesia. Subjectively, the patient described frequent memory loss of conversations, with visitors to his house, or where he had been recently. He completed an outpatient traumatic brain injury clinic cognitive

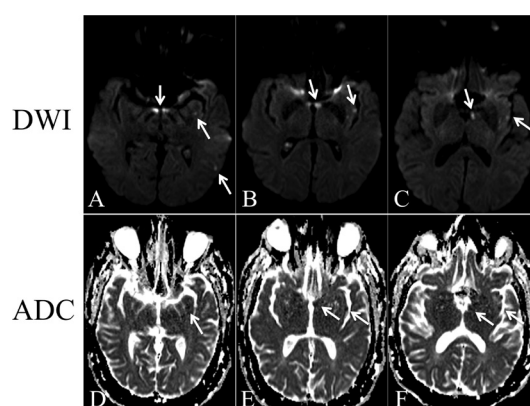
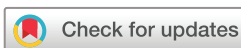

Figure 2 Diffusion-weighted (DWI) (A–C) and their corresponding adjusted diffusion coefficient (ADC) (D–F) MRI-weighted imaging representing acute diffusion restriction of ischaemic foci in left forniceal and left frontotemporal areas post stent-assisted coiling. White concave arrows in both DWI and ADC panels indicate enhanced diffusion restriction, and therefore areas of acute stroke in the fornix.

behavioural therapy programme without the need for antipsychotic medication and demonstrated recovery of symptoms over the next few months with almost complete resolution after 9 months.

Amnesia after ACoA coiling is rarely described in prior literature.¹ The fornix is supplied by medial central arteries that usually arise from the proximal anterior cerebral artery, but may also originate from the ACoA.² The subcallosal artery, a major perforator branch off the posterior aspect of the ACoA, is the sole source of perfusion to the anterior columns of the fornix bilaterally.³ The risk of forniceal stroke



© BMJ Publishing Group Limited 2019. No commercial re-use. See rights and permissions. Published by BMJ.

To cite: Al-Atrache Z, Friedler B, Shaikh HA, et al. *BMJ Case Rep* 2019;12:e230543. doi:10.1136/bcr-2019-230543

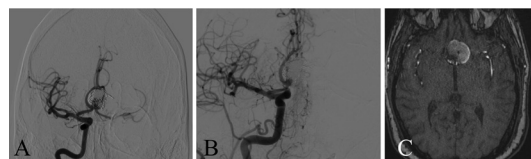


Figure 1 Cerebral angiogram anterior–posterior view (A) and lateral view (B) and T1 postcontrast MRI (C) demonstrating residual filling of ACoA prior to endovascular reintervention. ACoA, anterior communicating artery aneurysm.

Learning points

- Forniceal stroke may result from subcallosal artery occlusion during anterior communicating aneurysm repair, resulting in severe persistent anterograde amnesia in patients undergoing this procedure.
- Anterograde amnesia resolution may take months; however, patients should be encouraged to participate in cognitive behavioural therapy programmes and to create a structured living environment to facilitate recovery.

must be weighed against the potential benefits conferred by endovascular obliteration of wide-necked ACoA.

Occlusion or damage to these perforators leading to infarction of fornix and amnesia can occur after seemingly uneventful endovascular treatment of ACoA.³ Injury to mammillary bodies, hippocampus and thalamic nuclei can also lead to amnesia; however, injury to these structures was not seen in our patient. Hence, fornix infarct was the most likely cause of amnesia in our patient.

It is important to recognise forniceal infarction following ACoA coiling as a cause of amnesia postoperatively, as it can be misdiagnosed as delirium or acute stress reaction and lead to inappropriate medication administration. It is also important to counsel patients on reversibility and excellent prognosis with this complication, although the course may be prolonged.

Contributors TK conceived and directed the construction of this case report. HAS conducted the intervention and obtained the intraoperative images. TK and HAS

interpreted the images and maintained direct patient care. ZA-A and BF designed and drafted the manuscript and figures. All authors discussed and edited the final and revised versions of the manuscript.

Funding The authors have not declared a specific grant for this research from any funding agency in the public, commercial or not-for-profit sectors.

Competing interests None declared.

Patient consent for publication Obtained.

Provenance and peer review Not commissioned; externally peer reviewed.

REFERENCES

- 1 Kamble RB, Sheshadri V, Jayaraman A, *et al*. Rare complication of anterior communicating artery aneurysm coiling: Transient retrograde amnesia. *Neuroradiol J* 2015;28:325–8.
- 2 Salvalaggio A, Cagnin A, Nardetto L, *et al*. Acute amnesic syndrome in isolated bilateral fornix stroke. *Eur J Neurol* 2018;25:787–9.
- 3 Moussouttas M, Giacino J, Papamitsakis N. Amnesic syndrome of the subcallosal artery: a novel infarct syndrome. *Cerebrovasc Dis* 2005;19:410–4.

Copyright 2019 BMJ Publishing Group. All rights reserved. For permission to reuse any of this content visit <https://www.bmj.com/company/products-services/rights-and-licensing/permissions/> BMJ Case Report Fellows may re-use this article for personal use and teaching without any further permission.

Become a Fellow of BMJ Case Reports today and you can:

- ▶ Submit as many cases as you like
- ▶ Enjoy fast sympathetic peer review and rapid publication of accepted articles
- ▶ Access all the published articles
- ▶ Re-use any of the published material for personal use and teaching without further permission

Customer Service

If you have any further queries about your subscription, please contact our customer services team on +44 (0) 207111 1105 or via email at support@bmj.com.

Visit casereports.bmj.com for more articles like this and to become a Fellow