

Intracerebral Hemorrhage Complicating Intravenous Tissue Plasminogen Activator Treatment

Scott E. Carlson, MD; Michael S. Aldrich, MD; Harry S. Greenberg, MD; Eric J. Topol, MD

● Tissue plasminogen activator's thrombolytic action is relatively specific for fibrin; however, systemic bleeding can occur in patients, especially when heparin is simultaneously administered. We describe two cases of intracerebral hemorrhage from a cohort of 450 patients (0.44%) treated at one institution with tissue plasminogen activator and heparin for acute myocardial infarction. A pooled worldwide review of 5258 cases from several clinical protocols for treatment of acute myocardial infarction, using tissue plasminogen activator from one source, revealed a similar overall incidence of 0.68%. The incidence of intracerebral hemorrhage may be reduced by lowering the total dose of tissue plasminogen activator or by reducing the infusion rate and duration. The incidence of central nervous system hemorrhage with tissue plasminogen activator is within the range reported with streptokinase, but because equal coronary artery thrombolytic doses are not known, no definitive comparison is possible.

(*Arch Neurol* 1988;45:1070-1073)

Thrombolytic treatment within the first few hours of acute myocardial infarction has been used with increased frequency since initial studies with streptokinase and urokinase.¹

The major limitation of streptokinase and urokinase is that they activate both fibrin-bound plasminogen and circulating plasminogen and thereby produce a systemic fibrinolytic state.^{1,2} While thrombolysis of coronary artery clots is often successful, bleeding complications severe enough to require transfusion have occurred in up to 9% of patients treated with streptokinase or urokinase, and central nervous system hemorrhage in up to 1.6% of patients.^{3,4}

Tissue plasminogen activator is a clot-selective activator which should, in theory, have fewer bleeding complications than nonspecific thrombolytic agents. Several randomized trials comparing intravenous tissue plasminogen activator and intravenous streptokinase have shown a higher frequency of coronary artery patency with tissue plasminogen activator than with streptokinase,^{2,3,5-7} and although hemorrhagic events appear to be less frequent with tissue plasminogen activator than streptokinase,² the difference in the incidence of bleeding may be due, at least in part, to differing degrees of fibrinolysis at the doses used. In patients receiving tissue plasminogen activator alone, oozing around the catheter site has been the most common bleeding complication, occurring in 26% to 45% of patients treated.^{3,8,9}

Neurologic complications during catheterization in patients treated with tissue plasminogen activator include transient ischemic attack and ischemic stroke.^{2,3} In one study,⁸ brief mention was made of intracranial hemorrhage but to date there are no detailed reports of intracranial hemorrhages complicating tissue plasminogen activator use. In this article, we

describe two cases of intracerebral hemorrhage occurring during tissue plasminogen activator use for acute myocardial infarction.

PATIENTS AND METHODS

The two patients we describe are part of a cohort of 450 patients entered thus far at the University of Michigan (Ann Arbor) as part of the multicenter Thrombolysis in Acute Myocardial Infarction (TAMI) Study. Criteria for inclusion in this study have been published elsewhere.^{9,10} Patients were excluded from the cohort if they had any of the following: cardiogenic shock, previous coronary artery bypass surgery, prior transmural infarct in the same myocardial territory, bleeding diathesis, head trauma or stroke in the previous three months, or major surgery in the past two weeks. Exclusion criteria also included the use of warfarin sodium (coumadin), but did not include use of antiplatelet agents or other medications.

The tissue plasminogen activator used was a single-chain preparation (G₁₁₀₃₅, Genentech, South San Francisco).^{11,12} The initial intravenous dose of tissue plasminogen activator was 1.0 mg/kg over the first hour with 10% given as a bolus. An additional 0.5 mg/kg infusion was administered over the next four hours to a total maximum dose of 135 to 150 mg, depending on the specific protocol. Case 1 was part of the TAMI I Study, a randomized protocol comparing patients treated with tissue plasminogen activator followed by angioplasty and those receiving only tissue plasminogen activator and cardiac catheterization.⁹ Case 2 was part of the TAMI III protocol comparing patients receiving tissue plasminogen activator and early heparinization, and those receiving tissue plasminogen activator alone for 90 minutes, followed by later postcatheterization heparinization.¹³ A 5000-U heparin bolus was given to all patients immediately following cardiac catheterization, followed by a 500-U/h infusion.

These two patients were selected for evaluation because of the development of a

Accepted for publication April 17, 1988.

From the Department of Neurology (Drs Carlson, Aldrich, and Greenberg), and Division of Cardiology, Department of Internal Medicine (Dr Topol), University of Michigan Medical Center, Ann Arbor.

Presented in part at the 40th annual meeting of the American Academy of Neurology, Cerebrovascular Disease Scientific Section, Cincinnati, April 19, 1988.

Reprint requests to Department of Neurology, 1920/0316 Taubman Center, 1500 E Medical Dr, Ann Arbor, MI 48109-0316 (Dr Aldrich).

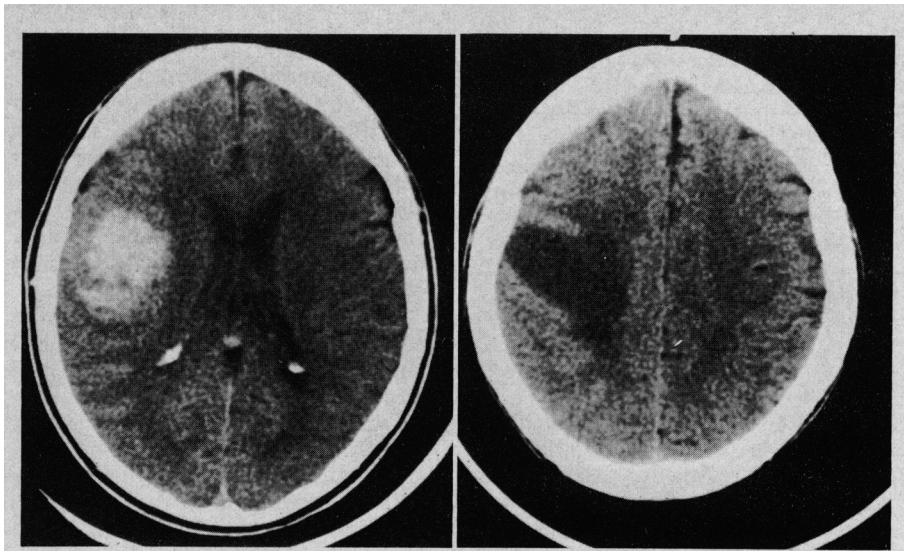


Fig 1.—Left, Noncontrasted computed tomographic scan of brain done after neurologic presentation following intravenous tissue plasminogen activator treatment showing an acute lobar intracerebral hemorrhage in right subcortical frontoparietal region. Right, Noncontrasted follow-up computed tomographic scan of brain showing resolution of hemorrhage 2½ weeks later.

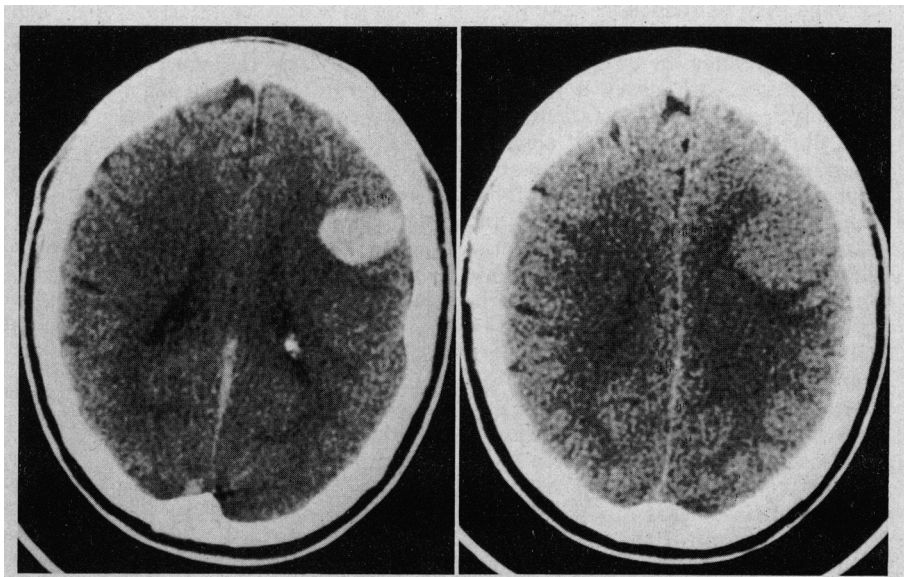


Fig 2.—Left, Noncontrasted computed tomographic scan of brain done after neurologic presentation following intravenous tissue plasminogen activator treatment showing an acute intracerebral hemorrhage in left frontal region. Right, Noncontrasted follow-up computed tomographic scan of brain showing resolution of hemorrhage ten days later.

neurologic deficit within hours of receiving intravenous tissue plasminogen activator therapy. Pretreatment computed tomographic (CT) scans of the head and random posttreatment scans were not performed as part of the TAMI protocols. Computed tomographic scans of the head in the two patients described were performed on a scanner (GE9800) without intravenous contrast. Fibrinogen and fibrinogen degradation product measurements were performed using the methods of Clauss¹⁴ and Mersky et al,¹⁵ respectively. Blood used for analysis was collected into tubes containing protease inhibitor (Trasyol) to prevent in vitro activation of tissue plasminogen activator.

REPORT OF CASES

CASE 1.—A 63-year-old woman with a 20-year history of intermittent angina, controlled hypertension, and smoking was admitted with substernal chest pain and electrocardiographic changes consistent with an acute posterior wall myocardial infarction. Initial blood pressure was 188/108 mm Hg. Physical examination was otherwise unremarkable. Lidocaine and morphine sulfate were administered intravenously without relief. After consenting to enter the TAMI I protocol, she was randomized to receive tissue plasminogen activator without angioplasty. She received an 8-mg bolus of tissue plasminogen

activator followed by an infusion of 68 mg/h for one hour and by a 15-mg/h infusion thereafter to a total dose of 150 mg. Cardiac catheterization revealed abnormalities of all three major vessels and occlusion of the distal circumflex artery. Blood pressure immediately after the procedure was 150/78 mm Hg. A heparin bolus of 5000 U was given immediately after cardiac catheterization followed by infusion of 500 U/h. Two hours after catheterization she developed sudden left face and arm weakness with minimal associated sensory changes. Laboratory analysis at the time of clinical deterioration revealed a partial thromboplastin time of 100 s; prothrombin time, 15.7 s; fibrin split products, 256 µg/mL (normal, 0 to 7 µg/mL); fibrinogen, 0.77 g/L (normal, 2.0 to 3.5 g/L); and platelet count, 264 × 10⁹/L. Computed tomographic brain scan showed a right hemisphere lobar hemorrhage (Fig 1, left). Protamine, fresh frozen plasma, cryoprecipitate, and aminocaproic acid were administered. Twelve hours later, fibrinogen, prothrombin time, and partial prothrombin time were normal. A follow-up CT scan of the head 2½ weeks later showed resolution of the intracerebral hemorrhage (Fig 1, right). She was discharged to a rehabilitation unit with moderate left hemiparesis and hemineglect.

CASE 2.—A 59-year-old man without prior cardiac, hypertensive, or cerebrovascular disease was admitted with substernal chest pain and electrocardiographic changes consistent with inferior wall myocardial infarction. Initial blood pressure was 180/112 mm Hg. Results of physical examination were otherwise normal. He was treated with nitroglycerin, lidocaine, and morphine sulfate. After informed consent he entered the TAMI III protocol and was randomized to receive tissue plasminogen activator and postcatheterization heparin. He received a 9-mg bolus of tissue plasminogen activator over five minutes followed by infusion of 81 mg over the next hour. Cardiac catheterization revealed 80% to 90% stenosis of the right coronary artery. A 5000-U bolus of heparin was administered intravenously after catheterization followed by a 500-U/h infusion. Forty-five minutes after catheterization, he developed sudden severe expressive aphasia with mild right facial and hand weakness. Blood pressure was 138/94 mm Hg. Laboratory analysis revealed a partial thromboplastin time of 65 s; prothrombin time, 16.7 s; fibrin split products, 512 µg/mL; fibrinogen, 0.77 g/L; and platelet count, 145 × 10⁹/L. Heparin was discontinued, and 3 U of fresh frozen plasma were given. A CT scan of the brain revealed a subcortical hemorrhage in the left frontal hemisphere (Fig 2, left). Over the next two weeks his weakness resolved and his ability to speak simple words and syllables returned. A second CT scan ten days later showed resolution of the clot (Fig 2, right).

COMMENT

Two patients suffered acute lobar hemorrhages within four hours of

Incidence of Intracranial Hemorrhage in Over 5000 Patients Receiving Intravenous Tissue Plasminogen Activator (Activase)			
No. of Patients	Dose, mg	No. of Intracranial Hemorrhages	Incidence, %
175	Up to 80	1	0.6
3361	80-120	14	0.4
1722	120-180	21	1.2
Total	5258	36*	0.68†

*Three events occurred more than 48 hours after intravenous tissue plasminogen activator treatment.

†Incidence of hemorrhage occurring less than 48 hours after intravenous tissue plasminogen activator treatment was .63%

beginning tissue plasminogen activator therapy and within two hours of completing cardiac catheterization and beginning heparin therapy. To our knowledge these are the first two reports of central nervous system hemorrhages occurring within four hours of intravenous tissue plasminogen activator treatment. A posterior fossa hemorrhage occurring 48 hours after tissue plasminogen activator infusion and emergency coronary artery bypass graft has been reported, but the 48-hour interval between tissue plasminogen activator therapy and the interposition of open heart surgery make it uncertain whether the hemorrhage was secondary to fibrinolytic therapy.¹⁰ Five cases of intracerebral hemorrhage that occurred from five to 72 hours after initiation of tissue plasminogen activator treatment have been reported as part of the TAMI II Pilot Study.¹⁶

These two cases represent a 0.44% incidence of intracerebral hemorrhage in the 450 patients who have received intravenous tissue plasminogen activator therapy at the University of Michigan. An incidence of hemorrhage of 0.44% in patients treated with tissue plasminogen activator and heparin is similar to the reported incidence of intracerebral hemorrhage of 0.0% to 1.6% in patients with acute myocardial infarction treated with streptokinase intravenously and heparin or antiplatelet agents.^{4,17}

Our data represent the experience of one institution and may not represent the true, overall incidence of intracerebral hemorrhage. Other reports describe an incidence of intracerebral hemorrhage in the 48 hours after infusion of tissue plasminogen activator of 0.3% (three of 998 patients).¹⁸ Pooled data from over 5000 patients treated with tissue plasminogen activator, including all United States trials through May 31, 1987 (TAMI, 2000 patients through April 29, 1987) and five large European trials (over 1500 patients) show a combined incidence of intracerebral hem-

orrhage of 0.68% (Table).¹⁹ Although these trials used varying study designs, dose regimens, and selection criteria, the data from these studies suggest an increased incidence of hemorrhage with higher doses of tissue plasminogen activator. Recent TAMI protocols have lowered the recommended maximum dose of tissue plasminogen activator.²⁰ At these lower doses, the overall incidence of hemorrhage may be reduced.

Although the cause of the intracerebral hemorrhage in our patients is unknown, in both cases a systemic fibrinolytic state existed (abnormally low fibrinogen levels and elevated fibrin split products), and this state probably contributed to the lobar hemorrhages. Clinical experience and in vivo studies²¹ have shown that the likelihood of producing a systemic fibrinolytic state increases with higher doses (Table), long infusion times, and higher infusion rates. Pooled data from three studies of the European Cooperative Study Group indicated that bleeding complications were 2.4 times more frequent if fibrin split product levels exceeded 85 mg/L at the end of tissue plasminogen activator infusion than if the levels stayed below 22 mg/L.²² Multicenter United States data of patients receiving 150 mg of tissue plasminogen activator over 6 to 8 hours have shown that nadir fibrinogen levels are inversely proportional to bleeding incidence.²³ These data suggest an association between systemic fibrinolysis and bleeding complications.

Spontaneous intracerebral hemorrhages are also described in hypofibrinogenic or dysfibrinogenic states,²⁴ including disseminated intravascular coagulopathy.²⁵ Whether a predisposing vascular abnormality is required for hemorrhage to occur during systemic fibrinolysis, or whether fibrinolysis disrupts normally occurring microhemostasis within the cerebral vasculature is not known. The value of tissue plasminogen activator is based on the enzyme's high affinity for the

fibrin-plasminogen complex which should make the enzyme's action clot selective and prevent a systemic fibrinolytic state.^{18,21,26} However, the clot selectivity is incomplete and systemic activation of plasminogen can occur.^{21,27} If a fibrinolytic state occurs, the potential advantage of this drug over other thrombolytic agents may be eliminated.

We cannot exclude heparin as a contributing factor in our patients since the hemorrhages occurred 45 minutes and two hours, respectively, following the initiation of heparin infusion. At the time of hemorrhage, the partial prothrombin time was elevated in case 1, and therapeutic, 2.0 to 2.5 times control, in case 2. Although both cases had elevated blood pressure on presentation, lobar cerebral hemorrhages are not typical of hypertensive hemorrhages.^{28,29} There was no evidence of other possible causes of lobar hemorrhages such as amyloid, arteriovenous malformation, and metastatic tumor.³⁰ Cerebrovascular complications following acute myocardial infarction are usually embolic infarctions and not lobar hemorrhages.^{29,31,32}

We cannot definitely rule out the remote possibility that intracerebral hemorrhages were already present when fibrinolytic therapy was initiated, since pretreatment CT scans were not done. Large intracerebral and subarachnoid hemorrhages can cause secondary myocardial damage and cardiac arrhythmias in animal models and in patients.³³ However, our patients would have had to have asymptomatic, small intracerebral hemorrhages at presentation, and resultant myocardial injury would be unlikely from such a small lesion.

Despite the retrospective nature of our article, several conclusions can be drawn. Serious central nervous system hemorrhagic complications may occur with tissue plasminogen activator treatment, which appear to have an overall incidence of between 0.3% and 1.2%. Although this incidence is similar to that previously reported with intravenous streptokinase,^{4,17} a direct assessment of risk of intracerebral hemorrhage with these two thrombolytic agents cannot be made because equal fibrinolytic doses are not known. Such comparisons would also involve the incidences from patients in several different protocols.

While accepted risks for intracerebral hemorrhage such as hypertension, age, diabetes, recent stroke, brain tumor, recent head injury, or

recent craniotomy are important considerations in patient selection for thrombolytic therapy, an additional concern is the potential development of a systemic fibrinolytic state. The optimum intravenous dosage to achieve effective coronary recanalization and prevent rethrombosis, yet minimize the risk of a systemic thrombolytic state, has not yet been defined. It appears that the lowest dose required for intracoronary clot lysis, given for the shortest period of

time, may result in a lower incidence of central nervous system hemorrhagic complications. A complete review of all hemorrhages following tissue plasminogen activator use may provide further information concerning the risk of central nervous system hemorrhage during tissue plasminogen activator thrombolysis.

Tissue plasminogen activator (Activase) has recently been accepted by the Food and Drug Administration for general use in the management of

acute myocardial infarction. The recommended dose is 100 mg (60 mg in the first hour with 6 to 10 mg as a bolus, 20 mg over the second hour, and 20 mg over the third hour), or 1.25 mg/kg over three hours. Our patients received either more total tissue plasminogen activator or received a similar total dose over a shorter interval. The long-term incidence of intracerebral hemorrhage at the currently recommended dose is not known.

References

1. Sharma G, Cella G, Parisi A, et al: Thrombolytic therapy. *N Engl J Med* 1982;306:1268-1276.
2. Verstraete M, Bory M, Collen D, et al: Randomized trial of intravenous recombinant tissue-type plasminogen activator versus intravenous streptokinase in acute myocardial infarction. *Lancet* 1985;1:842-847.
3. Sloan M: Thrombolysis and stroke, past and future. *Arch Neurol* 1987;44:748-768.
4. Aldrich MS, Sherman SA, Greenberg HS: Cerebrovascular complications of streptokinase infusion. *JAMA* 1985;253:1777-1779.
5. Van de Werf F, Ludbrook PA, Bergmann SR, et al: Coronary thrombolysis with tissue-type plasminogen activator in patients with evolving myocardial infarction. *N Engl J Med* 1984;310:609-613.
6. Health and Public Policy Committee: Thrombolysis for evolving myocardial infarctions. *Ann Intern Med* 1985;103:463-469.
7. Thrombolysis in Acute Myocardial Infarction Study Group: Thrombolysis in myocardial infarction (TAMI) trial: Phase I findings. *N Engl J Med* 1985;312:932-936.
8. Topol EJ, Morris DC, Smalling RW, et al: A multicenter, randomized, placebo-controlled trial of a new form of intravenous recombinant tissue-type plasminogen activator (Activase) in acute myocardial infarction. *J Am Coll Cardiol* 1987;9:1205-1213.
9. Topol EJ, Califf RM, George BS, et al: A randomized trial of immediate versus delayed elective angioplasty after intravenous tissue plasminogen activator in acute myocardial infarction. *N Engl J Med* 1987;317:581-588.
10. Topol EJ, O'Neill WW, Langburd AB, et al: A randomized, placebo-controlled trial of intravenous recombinant tissue-type plasminogen activator and emergency coronary angioplasty in patients with acute myocardial infarction. *Circulation* 1987;75:420-428.
11. Garabedian HD, Gold HK, Leinbach RC, et al: Comparative properties of two clinical preparations of recombinant human tissue-type plasminogen activator in patients with acute myocardial infarction. *J Am Coll Cardiol* 1987;9:599-607.
12. Topol EJ, Morris DC, Smalling RW, et al: A multicenter, randomized, placebo-controlled trial of a new form of intravenous recombinant tissue type plasminogen activator (Activase) in acute myocardial infarction. *J Am Coll Cardiol* 1987;9:1205-1213.
13. Topol EJ, George BS, Kereiakos DJ, et al: A multicenter, randomized, controlled trial of intravenous tissue plasminogen activator and early intravenous heparin in acute myocardial infarction. *J Am Coll Cardiol* 1988;11(suppl):230A.
14. Clauss A: Gorinnungsphysiologische Schnellmethode zur Bestimmung des Fibrinogens. *Acta Haematol* 1957;17:237.
15. Mersky C, Lalezari P, Johnson AJ: A rapid simple, sensitive method for measuring fibrinolytic split products in human serum. *Proc Soc Exp Biol Med* 1969;13:871.
16. Passamani E, Morrison H, Herman M, et al: The thrombolysis in myocardial infarction (Thrombolysis in Acute Myocardial Infarction) Phase II Pilot Study: Tissue plasminogen activator followed by percutaneous transluminal coronary angioplasty. *J Am Coll Cardiol* 1987;10:51B-64B.
17. DelZoppo G, Zeumer H, Harker L: Thrombolytic therapy in stroke: Possibilities and hazards. *Stroke* 1986;17:595-607.
18. Grossbard EB: Genentech experience with rt-PA (Activase). *J Am Coll Cardiol* 1987;9:467.
19. Minutes of the Food and Drug Administration Cardiorenal Advisory Committee meeting. Bethesda, Md, May 29, 1987.
20. Thrombolysis in Acute Myocardial Infarction Operations Committee: Announcements of protocol change in thrombolysis in myocardial infarction trial. *J Am Coll Cardiol* 1987;9:467.
21. Topol EJ, Bell WR, Weisfeldt ML: Coronary thrombolysis with recombinant tissue-type plasminogen activator. *Ann Intern Med* 1985;103:837-843.
22. Alfred ER, Arnold MD, Brower RW, et al: Systemic fibrinogenolysis after recombinant human tissue-type plasminogen activator for myocardial infarction: Influence in coronary patency and bleeding. *J Am Coll Cardiol* 1988;11:107A.
23. Califf RM, Stump D, Thorton D, et al: Hemorrhagic complications after tissue plasminogen activator (t-PA) therapy for acute myocardial infarction. *Circulation* 1987;76(suppl):IV-1.
24. Marder VJ: The functional defects of hereditary dysfibrinogenia. *Thromb Haemost* 1976;36:1.
25. Schwartzman RJ, Hull JB: Neurologic complications of disseminated intravascular coagulation. *Neurology* 1982;32:791.
26. Bergmann SR, Fox KAA, Ter-Pogossian MM, et al: Clot-selective coronary thrombolysis with tissue plasminogen activator. *Science* 1983;220:1181-1183.
27. Collen D, Topol EJ, Tiefsbrunn AJ, et al: Coronary thrombolysis with recombinant human tissue-type plasminogen activator: A prospective, randomized, placebo-controlled trial. *Circulation* 1984;70:1012-1017.
28. McCormick WF, Rosenfield DB: Massive brain hemorrhage: A review of 144 cases and an examination of their cause. *Stroke* 1973;4:946-955.
29. Ropper AH, Davis KR: Lobar cerebral hemorrhages: Acute clinical syndromes in 26 cases. *Ann Neurol* 1979;8:141-147.
30. Kase CS, Williams JP, Wyatt DA, et al: Lobar intracerebral hematomas: Clinical and CT analysis of 22 cases. *Neurology* 1982;32:1146.
31. Kase C, Mohr JP: General features of intracerebral hemorrhage, in Barnett HJM, Mohr JP, Stein BM (eds): *Stroke: Pathophysiology, Diagnosis and Management*. New York, Churchill Livingstone Inc, 1986, chap 27.
32. Hart E: Brain hemorrhage in cardiac disease, acute myocardial infarction, in Furlan AJ (ed): *The Heart and Stroke*. New York, Springer-Verlag NY Inc, 1987, chap 7, pp 121-122.
33. Weidler DJ: Myocardial damage and cardiac arrhythmias after intracranial hemorrhage: A critical review. *Stroke* 1974;5:759-764.