




# Thalassemia and Moyamoya syndrome: unfurling an intriguing association

Shambaditya Das<sup>1</sup> · Souvik Dubey<sup>2</sup> · Mrinal Acharya<sup>3</sup> · Subhankar Chatterjee<sup>4</sup> · Durjoy Lahiri<sup>2</sup> · Goutam Das<sup>2</sup> · Biman Kanti Ray<sup>2</sup> · Markus Kraemer<sup>5,6</sup> 

Received: 13 May 2019 / Revised: 4 August 2019 / Accepted: 5 August 2019  
© Springer-Verlag GmbH Germany, part of Springer Nature 2019

## Abstract

**Introduction** Moyamoya angiopathy (MMA) is a rare cerebrovascular disease with progressive bilateral narrowing of intracranial parts of the internal carotid artery and proximal parts of the anterior and middle cerebral artery resulting in recurrent hemodynamic ischemic attacks, strokes and hemorrhages. If associated with other diseases, it is called Moyamoya syndrome (MMS). Until now, MMS has rarely been described with thalassemia.

**Methods** Of the 75 cases of MMA collected in our Indian center in the last 3 years, 4 new patients with the rare cooccurrence of thalassemia and MMS were found. Thalassemia cases were confirmed by hemoglobin electrophoresis and MMA was diagnosed on the basis of MR angiography. Other known secondary causes of MMA were ruled out by relevant investigations. Thirteen previously reported cases of thalassemia and MMA were retrieved by literature search in PubMed and Google Scholar using the keywords “Moyamoya” AND “thalassemia”. Subsequently all the data were analyzed and compared by using descriptive statistics.

**Results** Analysis of our 4 cases and those 13 found in the literature showed early childhood diagnosis of thalassemia and in most cases later manifestation of MMS in the age of  $14.5 \pm 10.72$  years (mean  $\pm$  SD) in our cases and with  $10.97 \pm 6.47$  years in previous cases. While 9 out of the former 13 and 3 of our 4 cases showed obvious infarcts in brain imaging, 1 case with HbE- $\beta$ -thalassemia presented with intracerebral hemorrhage. Hemiplegia/hemiparesis was present among all of our 4 cases, while it was present in 69.23% cases of the previous 13 reports. Neither transfusion dependence nor the history of splenectomy was found to be associated with MMA development.

**Conclusion** These four new cases of MMS in thalassemia enlarged our knowledge about MMS in patients with thalassemia. MMS is a relevant complication in patients with thalassemia and early detection is essential to avoid disability.

**Keywords** Moyamoya syndrome · Thalassemia · Association

✉ Markus Kraemer  
markus.kraemer@krupp-krankenhaus.de

<sup>1</sup> Department of General Medicine, IPGMER and SSKM Hospital, Kolkata, India

<sup>2</sup> Department of Neuromedicine, Bangur Institute of Neurosciences, IPGMER and SSKM Hospital, Kolkata, India

<sup>3</sup> Department of Neurology, Malda Medical College and Hospital, Malda, India

<sup>4</sup> Department of General Medicine, Rajendra Institute of Medical Sciences, Ranchi, India

<sup>5</sup> Department of Neurology, Alfried Krupp Von Bohlen Und Halbach Hospital, Alfried-Krupp-Str. 21, 45117 Essen, Germany

<sup>6</sup> Department of Neurology, Medical Faculty, Heinrich-Heine University Düsseldorf, Düsseldorf, Germany

## Introduction

Moyamoya angiopathy (MMA) is an intracranial angiopathy of unknown etiology, which is characterized by bilateral progressive steno-occlusive changes of the intracranial portion of the internal carotid arteries (ICA) and proximal portions of the anterior cerebral artery (ACA) and/or middle cerebral artery (MCA). The compensatory development of a collateral network of vessels resembles a “puff of smoke” (“moyamoya” in Japanese) at the base of the brain [1]. Although bilateral involvement is typical of MMA, angiographically proven unilateral steno-occlusion of terminal ICA has also been included under the umbrella term MMA [2]. Posterior cerebral arterial (PCA) or vertebra-basilar involvement has increasingly been recognized [3]. In contrast to idiopathic,

mainly genetic triggered forms (formerly known as Moyamoya disease, MMD), Moyamoya syndrome (MMS) refers to MMA associated with other recognized diseases, such as meningitis in childhood, neurofibromatosis type-II, Down syndrome, cranial irradiation and different types of anemias, particularly hemoglobinopathies [2]. Although sickle cell disease is a well-described risk factor for MMS [4], there are only few cases of MMS associated with thalassemia [5–17] and other rarer variants of hemoglobinopathies [18, 19]. Here, we report four cases of MMA with  $\beta$ -thalassemia, provide comparative analysis of these findings with previous reports and discuss biologically plausible associations of these two entities.

## Materials and methods

In the period of 3 years (2017–19), totally 75 angiographically proven MMA cases had been diagnosed at our center (Bangur Institute of Neurosciences, IPGIMER and SSKM Hospital, Kolkata, India). While 61 of them were MMD, 14 were MMS. Out of those 14 MMS cases, 4 were found to be thalassemic (proven by hemoglobin electrophoresis). Three of them were previously diagnosed with thalassemia and one was simultaneously diagnosed with HbE trait. Each case was evaluated by detailed history taking, neurological examination and review of additional symptoms. All patients underwent magnetic resonance imaging (MRI) of the brain, followed by MR angiography (MRA). To exclude other causes of stroke, routine blood investigations (complete hemogram, electrolytes, renal and liver function tests, viral serology, random blood sugar, routine urine, lipid profile, coagulation profile), vasculitis screening (anti-nuclear antibody profile, cytoplasmic anti-neutrophil cytoplasmic antibody, perinuclear anti-neutrophil cytoplasmic antibody, anti-phospholipid antibodies, rheumatoid factor, anti-cyclic citrullinated peptide, angiotensin-converting enzyme), thrombophilia workup (serum homocysteine, vitamin B<sub>12</sub>, folate, protein C, protein S, anti-thrombin III, factor V Leiden, prothrombin gene mutation, fibrinogen, hemoglobin electrophoresis) were done. Moreover, diagnostic workup included tests to rule out cardioembolism or arteriosclerosis (electrocardiography, 2D-echocardiography and bilateral carotid arterial Doppler).

Literature search was performed in PubMed using the keywords “Moyamoya” AND “Thalassemia”, which yielded 21 results. After screening these 21 references, ten cases which described the association of MMS and thalassemia were selected [5–12, 14, 16]. Considering the rarity of diagnosis and paucity of cases reported in literature, we further extended the literature search in Google Scholar with the same keywords. This revealed three more cases published

in non-PubMed indexed journals [13, 15, 17]. So, finally 13 published cases were included in this literature analysis.

Our’s and the previously reported cases were analyzed in terms of gender distribution, type of  $\beta$ -thalassemia, age of diagnosis of thalassemia, age of onset of neurological problems (including seizures), history of any neuropsychiatric or cognitive impairment, age at which diagnosis of MMS was established, status of spleen, treatment received for thalassemia (including transfusion dependency), relevant family history, neurological presentation, mode of treatment and long-term neurological sequelae. Findings were summarized in descriptive statistics. Due to the small number of cases, no statistical comparisons were done. All patients gave their permission for publication. They underwent no study-specific procedures, so no permission from the ethical committee was necessary.

## Case presentations

### Case-1

A 13-year-old male patient, suffering from transfusion-dependent  $\beta$ -thalassemia major, experienced a sudden onset of right-sided hemiparesis with loss of consciousness and an episode of focal seizure with secondary generalization. There was no conventional risk factor for vascular diseases. There was no prior history of focal neurological deficit (FND), seizures, cognitive or psychiatric manifestations. Family history was also non-contributory. Neurologic examination revealed right-sided diminished muscle power more in the lower limb with spasticity, brisk deep tendon reflexes (DTR) and extensor plantar response. Review of other systems (ROS) showed mild pallor and hepatosplenomegaly. MRI of the brain revealed infarct in the left centrum semi-ovale, adjoining the corpus callosum and the left frontal lobe. MRA depicted bilateral terminal ICA narrowing with narrowing of the right M1 segment of MCA with collaterals suggestive of MMA. All routine blood investigations were within normal limits, except hemoglobin 7.8 g% and peripheral blood smear showing microcytic hypochromic anemia. Hemoglobin electrophoresis allowed diagnosing  $\beta$ -thalassemia major. Additional workup (described above) revealed no other abnormalities. The patient was managed conservatively (with antiplatelets, statin, mannitol and physiotherapy) with uneventful clinical recovery.

### Case-2

A 9-year-old female, known to have transfusion dependent  $\beta$ -thalassemia major, presented with sudden onset of left-sided complete hemiparesis. There was no conventional risk factor for atherosclerotic vasculopathy. There was no

prior history of FND, seizures, psychiatric manifestations or cognitive impairment. There was no relevant family history. Neurologic examination revealed diminished muscle power (more in lower limbs) with spasticity, brisk DTR and extensor plantar response as well as upper motor neuron (UMN) type of facial palsy on the left side. The girl presented with mild pallor, icterus and hepatosplenomegaly. Acute infarction in the right fronto-temporo-parieto-occipital region and right basal ganglia was found in MRI. MRA showed bilateral, but left accentuated MMS showing plenty of left-sided collateral formation (Fig. 1a). Routine blood investigation revealed hemoglobin of 7.4 g%, microcytic hypochromic anemia and total serum bilirubin 3 mg% (conjugated—2.1 mg%). Further workup was unyielding. The patient was managed conservatively (with antiplatelets, statin, mannitol and physiotherapy) with uneventful clinical recovery.

### Case-3

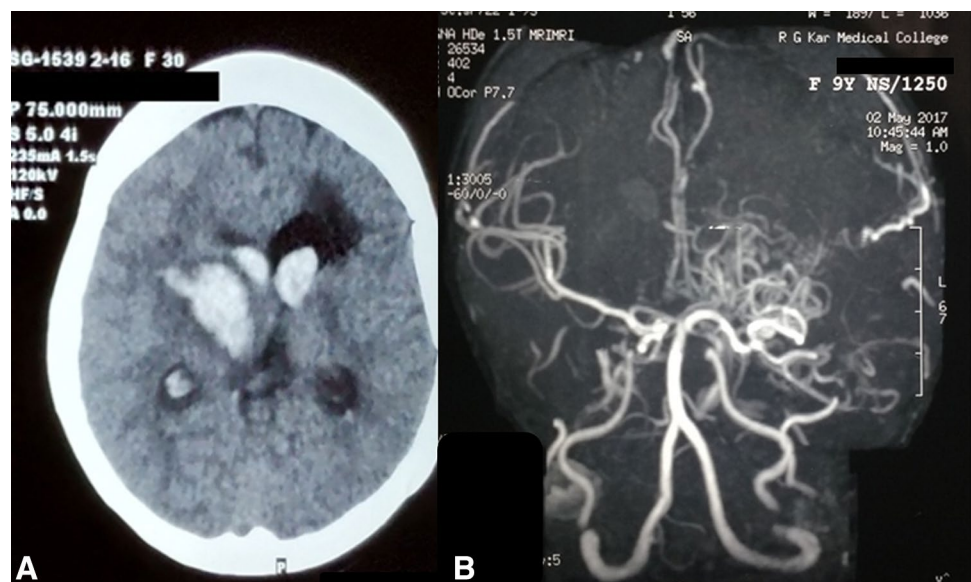
A 30-year-old female patient, a known case of Hb E  $\beta$ -Thalassemia, presented with sudden onset of loss of consciousness. On regaining consciousness, she developed left-sided hemiparesis and choreatic movements of the left extremities. She was transfusion dependent since the age of 6 years, requiring transfusion once or twice per month. At the age of 21 years, she underwent splenectomy. Thereafter, she had only three episodes of blood transfusion in the last 9 years, the last being 5 years previously. There was no conventional risk factor for vascular diseases. There was no prior history of FND, seizures, cognitive or psychiatric disturbances. There was no relevant family history. Physical examination uncovered just mild pallor. Neurologic examination revealed mild left-sided spastic

paresis with UMN-type facial palsy. Computer tomography of the brain depicted intracerebral bleeding with intraventricular extension (Fig. 1b). Bilateral narrowing of the supraclinoid ICA, bilateral ACA, MCA and PCA with Moyamoya collateralization was evident in MRA. Routine blood investigation revealed hemoglobin of 8.4 g% and total serum bilirubin 2.83 mg%. Other workup was unremarkable. The patient was managed conservatively (with trihexyphenidyl and clonazepam for dystonia, tetra-benazine for chorea, mannitol as anti-edema measure, and physiotherapy). Her weakness improved with no residual hemiparesis, while choreodystonic movements persisted, albeit its severity decreased.

### Case-4

A 6-year-old female presented with history of recurrent transient left hemiparesis with left focal motor seizure with onset 8 months previously. There was no conventional risk factor for vascular diseases. There was no prior history of FND, seizures, psychiatric or cognitive impairment. Family history was also non-contributory. Examination revealed mild pallor with residual paresis of the left side of the body with spasticity. MRI of the brain showed areas of subacute and chronic infarct involving the frontoparietal cortical and subcortical regions. MRA depicted narrowing of bilateral supraclinoid ICA, MCA and ACA along with collaterals. Hemoglobin was 9.2 g% and peripheral smear showed normocytic normochromic anemia. HbE trait was found in hemoglobin electrophoresis. This was incidentally diagnosed, without prior transfusion history. Further workup was normal. The patient was managed conservatively (with antiplatelets, statin and physiotherapy) with uneventful recovery.

**Fig. 1** **a** Computer tomography of the brain of a 30-year-old patient with right-sided basal ganglia hemorrhage with edema accompanied by intra-ventricular extension. **b** Magnetic resonance angiography of a 9-year-old patient with bilateral but left accentuated MMS showing plenty of left-sided collateral formation



## Results

### Analysis of our cases

Our case series had female predominance (male:female—1:3), two were  $\beta$ -thalassemia major and one was a HbE-  $\beta$ -thalassemia patient and the other had HbE-trait. The age at which they were diagnosed with thalassemia was  $5 \pm 1.41$  years (mean  $\pm$  SD), while the mean age at which they were diagnosed with MMS was  $14.5 \pm 10.72$  years (mean  $\pm$  SD). However, in one of our cases thalassemia was diagnosed as a part of the workup after diagnosis of MMS. All four of them presented with hemiparesis, two had focal seizures with secondary generalization and one had involuntary movements. Three of the four had not undergone splenectomy and two were transfusion dependent at the time of the event. While three of them had infarct on brain imaging, one with HbE- $\beta$ -thalassemia presented with intracerebral hemorrhage. All our cases, though counseled for revascularization surgery, were managed conservatively and have been clinically stable over a minimum of 6 months period (Tables 1 and 2).

### Analysis of previous cases

Among the 13 cases reported till now of thalassemia associated with MMS, 5 cases were of  $\beta$ -thalassemia intermedia [6, 9, 10, 13, 14], 3 had HbE- $\beta$ -thalassemia [8, 15, 17] and 2 of them had  $\beta$ -thalassemia major [5, 12], while a single cases of  $\beta$ -thalassemia with HPFH [16], Hb Fairfax [7] and sickle  $\beta$  + -thalassemia [11] have been reported earlier. They were almost equally distributed among males and females (M:F—1:1.16). The diagnosis of thalassemia (mean age- $2.87 \pm 2.02$  years) was made earlier than MMS in most of the cases except two, one in which MMS was diagnosed earlier to the hemoglobinopathy [12] and another where both diagnoses were established simultaneously [16]. The mean age of diagnosis of MMS was  $10.97 \pm 6.47$  year with the youngest diagnosis at 13 months and oldest at 25 years. The predominant symptom was hemiparesis or hemiplegia (9 out of 13 i.e., 69.23%). One case was neurologically asymptomatic. 41.67% of patients had no prior history of neurological complaints before they presented with acute-onset focal neurological deficit which led to the diagnosis of MMS. 50% of patients had earlier onset of neurological symptoms before they were finally diagnosed to be suffering from MMS. The age of appearance of the first neurological symptoms also preceded the age at diagnosis of MMS by a duration of  $35.57 \pm 35.47$  months (mean  $\pm$  SD). Splenectomy was seen only in two out of the ten patients in which

the status of the spleen was reported [6, 9]. Out of the 12 cases describing the transfusion status, 6 were transfusion independent [6, 8, 9, 11, 12, 14] at the time of acute neurological event of MMS. Nine out of the 13 cases had ischemic presentation on MRI. Out of ten cases mentioning management strategy, nine were managed conservatively [6–8, 10, 12–14, 16, 17], while only 1 underwent revascularization surgery [11]. Nine references reported follow-up, six were found to be clinically improved [6, 8, 10, 12, 13, 16], two described radiological progression of the disease [7, 17] and the surgically managed one showed impaired cognitive skills [11].

## Discussion

In general, patients with MMS are at a high risk of suffering hemodynamic transient ischemic attacks and stroke as well as embolic stroke. Emboli are thought to form locally in the intracranial stenosis and are hypothesized to become symptomatic due to reduced washout of emboli in the hemodynamically compromised state [20, 21]. Hypercoagulability, followed by thromboembolic events, is a widely recognized complication of thalassemia [22–24]. Risk factors include family history of thrombotic event, previous splenectomy, profound anemia, age above 35 years and a serum ferritin level  $\geq 1000$  mg/l, [25–27]. On the other hand, positive history of transfusion and a hemoglobin level  $\geq 9$  g/dl were found to be protective against thrombosis [28]. Hypercoagulability in chronic hemolytic anemia is multifactorial and includes the following: (1) circulating oxidative stress-dependent damaged red cell membrane increasingly exposing negatively charged phosphatidylserine, more so in the transfusion-independent patients [29]; (2) endothelial cell damage and activation by the oxidative stress due to hemolysis and iron overload [30, 31]; (3) higher plasma levels of markers of coagulation and of fibrinolysis activation [32]; (4) increased platelet numbers and aggregation [33, 34]; (5) deficiency of natural anticoagulants, such as protein C and protein S and increased levels of thrombin–antithrombin III complex [35].

Among hematological disorders, MMS has been more commonly associated with sickle cell anemia, but has also been reported with other disorders such as beta thalassemia, Fanconi's anemia [36], hereditary spherocytosis [37], iron deficiency anemia [38], Diamond–Blackfan anemia [39], paroxysmal nocturnal hemoglobinuria [40] and few rare hemoglobinopathies [18, 19]. It could be hypothesized that pathophysiologically obstructed flow in the vasa vasorum by non-deformable red cells, especially sickle cells, contributes to ischemia of vessel walls and subsequent intimal proliferation of the internal carotid artery and thus occlusion. The decreased blood flow caused by

**Table 1** Summary of our cases

Sl. No	Sex	Thalassemia syndrome	History of splenectomy	Age at the diagnosis of thalassemia	Previous history of neurological and neuropsychiatric manifestations	Age at the onset of neurological problems	Age at the diagnosis of MMS	Neurologically relevant family history	Neurological presentation	Type of stroke (infarct/hemorrhage)	Management	Treatment received for thalassemia and transfusion dependence	Follow-up
1	Male	$\beta$ -Thal major	No	3 years	Nil	13 years	13 years	Nil	Loss of consciousness, hemiparesis and seizure	Infarct	Conservative	Transfusion dependent	Improving, residual paresis present
2	Female	$\beta$ -Thal major	No	5 years	Nil	9 years	9 years	Nil	Hemiparesis	Infarct	Conservative	Transfusion dependent	Improving, residual paresis present
3	Female	HbE/ $\beta$ -Thal	Yes	6 years	Nil	30 years	30 years	Nil	Loss of consciousness, hemiparesis and choreodystonia	Hemorrhage	Conservative	Not transfusion dependent	Improving. Choreo-dystonia decreased in severity, but persisting
4	Female	HbE trait	No	6 years	Nil	6 years	6 years	Nil	Hemiparesis and seizure	Infarct	Conservative	Not transfusion dependent	Improving, residual paresis present



**Table 2** Summary of previously reported cases

Authors [reference]	Sex	Thalassemia syndrome	History of splenectomy	Age at the diagnosis of thalassemia	Previous history of neurological and neuropsychiatric manifestations	Age at the onset of neurological problems	Age at the diagnosis of MMS	Neurologically relevant family history	Neurological presentation	Type of stroke (infarct/hemorrhage)	Management	Treatment received for thalassemia and transfusion dependence	Follow-up
Mukherjee et al. [5]	Female	$\beta$ -Thal major	No	3.5 years	Nil	3.5 years	5.5 years	Nil	Right followed by left hemiparesis	N/A	N/A	N/A	N/A
Sanefuji et al. [6]	Female	$\beta$ -Thal intermedia	Yes (at 12 years)	6 years	Nil	14 years	14 years	Nil	Recurrent transient right hemiparesis and left paresis	Neither infarct, nor hemorrhage	Conservative	Not transfusion dependent	Free from neurological deficit. No radiological progression of disease
Marden et al. [7]	Female	Hb Fairfax/ $\beta$ -Thal	No	4 months	Cerebral infarct	19 months	9 years	Nil	Mild cognitive impairment and left spastic hemiparesis	Infarct	Conservative	Transfusion dependent	Radiological progression seen on MRA
Parker et al. [8]	Male	HbE/ $\beta$ -Thal	No	15 months	Nil	–	13 years	Nil	No neurological deficit, rather had growth hormone deficiency	Ischemic changes	Conservative	Hydroxyurea, sodium phenylbutyrate; Not transfusion dependent	No evidence of neurological deficit after 18 months of follow-up
Goksel et al. [9]	Male	$\beta$ -Thal intermedia	Yes (at 17 years)	1 year	Nil	5 years	19 years	Nil	Left hemiparesis with bilateral UMN signs	Infarct	N/A	Not transfusion dependent	N/A

**Table 2** (continued)

Authors [reference]	Sex	Thalassemia syndrome	History of splenectomy	Age at the diagnosis of thalassemia	Previous history of neurological and neuropsychiatric manifestations	Age at the onset of neurological problems	Age at the diagnosis of MMS	Neurologically relevant family history	Neurological presentation	Type of stroke (infarct/hemorrhage)	Management	Treatment received for thalassemia and transfusion dependence	Follow-up
Oberoi et al. [10]	Male	$\beta$ -Thal intermedia	No	21 months	Nil	5 years	5 years	Nil	Right hemiparesis	Infarct	Conservative	Hydroxyurea, folate supplementation Transfusion dependent	Improved neurodeficit
Ray et al. [11]	Male	Sickle/ $\beta$ -Thal	No	N/A	Nil	8 years	8 years	Nil	Altered mental status with focal neurological deficits	Infarct	Revascularisation surgery	Not transfusion dependent	Impaired cognitive skills
Inati et al. [12]	Female	$\beta$ -Thal major	No	13 months	Nil	3 months	13 months	Nil	Left tonic posturing seizures followed by right hemiparesis	Infarct	Conservative	Iron supplementation; Not transfusion dependent	Complete resolution of neurological deficits
Nadkarni et al. [13]	Male	$\beta$ -Thal intermedia	No	3 years	Nil	9.5 years	10 years	Nil	Right sided hemiparesis with dysphasia	Infarct	Conservative	Transfusion dependent	Complete resolution of neurological deficits
Beltagi et al. [14]	Female	$\beta$ -Thal intermedia	No	18 months	Focal seizures	14 years	16 years	Nil except consanguineous marriage of parents	Recurrent headache and focal seizures	Neither infarct nor hemorrhage	Conservative	Folate supplementation; Not transfusion dependent	N/A
Sarkar et al. [15]	Male	HbE/ $\beta$ -Thal	No	5 years	Syncope	10 years	11 years	Nil	Right followed by left hemiplegia	Infarct	N/A	Transfusion dependent	N/A

Table 2 (continued)

Authors [reference]	Sex	Thalassemia syndrome	History of splenectomy	Age at the diagnosis of thalassemia	Previous history of neurological and neuropsychiatric manifestations	Age at the onset of neurological problems	Age at the diagnosis of MMS	Neurologically relevant family history	Neurological presentation	Type of stroke (infarct/hemorrhage)	Management	Treatment received for thalassemia and transfusion dependence	Follow-up
Gupta et al. [16]	Male	$\beta$ -Thal/HPFH	No	6 years	Nil	6 years	6 years	Nil	Left hemiplegia	Infarct	Conservative	Transfusion dependent	Improved neurological deficits
Doctor et al. [17]	Female	HbE/ $\beta$ -Thal	No	4 years	Nil	25 years	25 years	Nil	Chorea/tosis	Neither infarct nor hemorrhage	Conservative	Hydroxyurea; transfusion dependent	Radiological progression seen on MRA

anemia, together with less deformable blood cells, may also cause progressive endothelial proliferation and subsequent vascular occlusion [41]. Another pathophysiological hypothesis of cooccurrence could be seen in two or more synergistic genetic triggers. Just recently, it has been demonstrated in MMS associated with neurofibromatosis that the combination of two generic factors might contribute to the development of vasculopathy [42]. Also in European MMA, a synergistic gene constellation has been discussed [43]. In Asia, MMA is highly associated with the RNF213 gene variant p.R4810K; however, not all carriers of this variant will develop MMA, so a multigenetic cause is highly probable. However, until now no genetic links between these two entities has been described, despite well-known genetic factors in thalassemia. Nitric oxide has emerged as a missing link in the pathogenesis of MMA in thalassemia. As in sickle cell anemia [44, 45], NO deficiency might be the key reason for generating oxidative stress, proinflammatory and prothrombotic cascades and adverse vascular events among thalassemia patients [46, 47]. Data from three unrelated family studies have revealed that homozygous mutations in GUCY1A3 (which encodes the  $\alpha 1$  subunit of soluble guanylate cyclase, the major receptor for NO) result in MMA [48]. This further strengthens the association between altered NO signaling and MMA.

Reviewing existing literature, some similarities and differences could be found. The age at first neurological symptom was not discordant with the age at diagnosis of MMS in our case series, contrary to the previous findings where appearance of neurological symptoms preceded MMS diagnosis by many years. Splenectomy, thought to be a risk factor for development of thromboembolic manifestation [49] owing to thrombocytosis and hyperlipidemia, was seen only in two out of the ten patients that described the status of spleen in previous literature, [6, 9] suggesting that it might not be a very important determinant for the development of MMS in the background of thalassemia. Three of the four in our cases had not undergone splenectomy, again undermining its risk potential. In both our cases and previously reported cases, 50% of patients with thalassemia were transfusion independent at the time of acute neurological event. This indicates that mere transfusion dependency may have a lesser role in preventing the development of MMS in the background of thalassemia, unlike in other types of hemoglobinopathies [50, 51], rather keeping the hemoglobin above a desired level so as to prevent chronic hypoxia is more important. While all the prior reported cases had ischemic presentation in the MRI of the brain, one of our cases with HbE- $\beta$ -thalassemia presented with intracerebral hemorrhage at 30 years of age. This could be due to the older age of presentation where intracerebral hemorrhage is a common presenting feature in MMS due to fragile collaterals and microaneurysms [52].



## Conclusion

Transfusion dependency in  $\beta$ -thalassemia major might not be able to prevent the progression of MMS. There is usually a prolonged time gap between the diagnosis of thalassemia and recognition of MMS, which hypothetically could be explained by a long time of good hemodynamic compensation as well as with high rate of misdiagnoses and false diagnoses. A higher index of suspicion and screening might be helpful for early detection of MMS and lead to better prognosis. It is important that neurological deficit in the background of hemoglobinopathy should be worked up carefully differentiating between a thromboembolic event due to chronic hypercoagulable state and a potential MMS. As the later is a progressive disease, early surgical intervention with direct or indirect revascularisation might have great impact on prognosis of the patient [53, 54].

## Compliance with ethical standards

**Conflicts of interest** There is no conflict of interest.

**Ethical approval** All patients gave their permission for publication. They underwent no study-specific procedures, so no permission from the ethical committee was necessary.

## References

1. Scott RM, Smith ER (2009) Moyamoya disease and moyamoya syndrome. *N Engl J Med* 360:1226–1237
2. Fujimura M, Tominaga T (2015) Diagnosis of moyamoya disease: international standard and regional differences. *Neurol Med Chir (Tokyo)* 55:189–193
3. Zhao M, Zhang D, Wang S, Zhang Y, Wang R, Deng X et al (2018) Posterior circulation involvement in pediatric and adult patients with moyamoya disease: a single center experience in 574 patients. *Acta Neurol Belg* 118:227–233
4. Dobson SR, Holden KR, Nietert PJ, Cure JK, Laver JH, Disco D et al (2002) Moyamoya syndrome in childhood sickle cell disease: a predictive factor for recurrent cerebrovascular events. *Blood* 99:3144–3150
5. Mukherjee A (1995) Moyamoya disease and beta-thalassemia. *J Assoc Physicians India* 43:710–711
6. Sanefuji M, Ohga S, Kira R, Yoshiura T, Torisu H, Hara T (2006) Moyamoya syndrome in a splenectomized patient with beta-thalassemia intermedia. *J Child Neurol* 21:75–77
7. Marden FA, Putman CM, Grant JM, Greenberg J (2008) Moyamoya disease associated with hemoglobin Fairfax and beta-thalassemia. *Pediatr Neurol* 38:130–132
8. Parker TM, Ward LM, Johnston DL, Ventureya E, Klaassen RJ (2009) A case of Moyamoya syndrome and hemoglobin E/beta-thalassemia. *Pediatr Blood Cancer* 52:422–424
9. Göksel BK, Ozdogu H, Yildirim T, Oğuzkurt L, Asma S (2010) Beta-thalassemia intermedia associated with moyamoya syndrome. *J Clin Neurosci* 17:919–920
10. Oberoi S, Bansal D, Singh P, Marwaha RK (2010) Stroke in a young boy with  $\beta$ -thalassemia intermedia secondary to moyamoya syndrome. *J Pediatr Hematol Oncol* 32:568–570
11. Ray A, Rodriguez N (2011) Cerebral infarction in the setting of moyamoya in a pediatric patient with sickle  $\beta$ -thalassemia. *Pediatr Hematol Oncol* 28:535–537
12. Inati A, Tourjuman O, Bizri D, Dhayni R, Abbas HA, Tfaily H et al (2013) A rare case of Moyamoya syndrome in a  $\beta$ -thalassemia major patient. *Blood Cells Mol Dis* 51:149–150
13. Nadkarni J, Pal P, Dwivedi R, Singh A (2014) Vasculopathy in beta thalassemia intermedia: a rare case report. *Sch J App Med Sci* 2(1C):345–347
14. El Beltagi AH, El-Sheikh A, El-Saif R, Norbash A (2014) Ivy sign in mildly symptomatic  $\beta$ -thalassemia intermedia, with development of moyamoya disease. *Neuroradiol J* 27:23–28
15. Sarkar KN, Deoghuria D, Sarkar M, Sarkar S (2016) Moyamoya syndrome in a HbE beta thalassemic child presenting with hemiplegia in rural West Bengal. *IOSR J Med Dent Sci* 15:113–118
16. Gupta A, Mathur P, Sharma M, Parmar V (2017) A rare case of compound heterozygous B-thalassemia and hereditary persistence of fetal hemoglobin with Moya-Moya disease. *J Pediatr Crit Care*. <https://doi.org/10.21304/2017.0403.00208>
17. Doctor PN, Choudhary A, Verma M, Merchant RH (2018) Moyamoya syndrome in hemoglobin E-beta thalassemia: A rare presentation and association. *J Postgrad Med* 64:240–242
18. Brockmann K, Stolpe S, Fels C, Khan N, Kulozik AE, Pekrun A (2018) Moyamoya syndrome associated with hemolytic anemia due to Hb Alesha. *J Pediatr Hematol Oncol* 27:436–440
19. Haque A, Quint DJ, Castle VP, Leber SM (2015) Another rare unstable hemoglobinopathy: hemoglobin Casper/Southampton associated with Moyamoya disease. *Cerebrovasc Dis Extra* 5:52–54
20. Shulman JG, Snider S, Vaitkevicius H, Babikian VL, Patel NJ (2017) Direct visualization of arterial emboli in Moyamoya syndrome. *Front Neurol* 8:425
21. Kraemer M, Berlit P, Diesner F, Khan N (2012) What is the expert's option on antiplatelet therapy in moyamoya disease? Results of a worldwide Survey. *Eur J Neurol* 19:163–167
22. Franchini M, Manucci PM (2012) Hypercoagulability in congenital haemolytic anaemias. *Blood Transfus* 10:423–427
23. Cappellini MD, Poggiali E, Taher AT, Musallam KM (2012) Hypercoagulability in  $\beta$ -thalassemia: a status quo. *Expert Rev Hematol* 5:505–511
24. Cappellini MD, Musallam KM, Poggiali E, Taher AT (2012) Hypercoagulability in non-transfusion-dependent thalassemia. *Blood Rev* 26(Suppl 1):S20–S23
25. Taher AT, Otrrock ZK, Uthman I, Cappellini MD (2008) Thalassemia and hypercoagulability. *Blood Rev* 22:283–292
26. Taher AT, Musallam KM, Karimi M, El-Beshlawy A, Belhouli K, Daar S et al (2010) Splenectomy and thrombosis: the case of thalassemia intermedia. *J Thromb Haemost* 8:2152–2158
27. Eldor A, Rachmilewitz EA (2002) The hypercoagulable state in thalassemia. *Blood* 99:36–43
28. Taher AT, Musallam KM, Karimi M, El-Beshlawy A, Belhouli K, Daar S et al (2010) Overview on practices in thalassemia intermedia management aiming for lowering complication rates across a region of endemicity: the OPTIMAL CARE study. *Blood* 115:1886–1892
29. Borenstain-Ben Yashar V, Barenholz Y, Hy-Am E, Rachmilewitz EA, Eldor A (1993) Phosphatidylserine in the outer leaflet of red blood cells from beta-thalassemia patients may explain the chronic hypercoagulable state and thrombotic episodes. *Am J Hematol* 44:63–65
30. Ruf A, Pick M, Deutsch V, Patscheke H, Goldfarb A, Rachmilewitz EA et al (1997) In-vivo platelet activation correlates with red

- cell anionic phospholipid exposure in patients with beta-thalassemia major. *Br J Haematol* 98:51–56
31. Mannucci PM (2010) Red cells playing as activated platelets in thalassemia intermedia. *J Thromb Haemost* 8:2149–2151
  32. Cappellini MD, Robbiolo L, Bottasso BM, Coppola R, Fiorelli G, Mannucci AP (2000) Venous thromboembolism and hypercoagulability in splenectomized patients with thalassaemia intermedia. *Br J Haematol* 111:467–473
  33. Goldschmidt N, Spectre G, Brill A, Zelig O, Goldfarb A, Rachmilewitz E et al (2008) Increased platelet adhesion under flow conditions is induced by both thalassemic platelets and red blood cells. *Thromb Haemost* 100:864–870
  34. Del Principe D, Menichelli A, Di Giulio S, De Matteis W, Cianciulli P, Papa G (1993) PADGEM/GMP-140 expression on platelet membranes from homozygous beta thalassaemic patients. *Br J Haematol* 84:111–117
  35. Tripatara A, Jetsrisuparb A, Teeratakulpisarn J, Kuaha K (2007) Hemostatic alterations in splenectomized and non-splenectomized patients with beta-thalassemia/hemoglobin E disease. *Thromb Res* 120:805–810
  36. Al-Hawsawi ZM, Al-Zaid MA, Barnawi AI, Yassine SM (2015) Fanconi anemia associated with moyamoya disease in Saudi Arabia. *Saudi Med J* 36:233–235
  37. Gait-Carr E, Connolly DJ, King D (2017) Moyamoya syndrome associated with hereditary spherocytosis: an emerging clinical entity. *J Pediatr Hematol Oncol* 39:233–234
  38. Meena SS, Ramkumar TV, Sharma S, Aneja S, Kumar A (2012) Moyamoya syndrome associated with severe iron deficiency anemia in a young child. *Pediatr Hematol Oncol* 29:368–371
  39. Butrum MW, Williams LS, Golomb MR (2003) A child with Diamond-Blackfan anemia, methylenetetrahydrofolate reductase mutation, and perinatal stroke. *J Child Neurol* 18:800–802
  40. Cheng ZJ, Shen YY, Warsame IM, Dai TM, Tu JL (2018) Moyamoya syndrome caused by paroxysmal nocturnal hemoglobinuria. *Chin Med J (Engl)* 131:2874–2876
  41. Bersano A, Guey S, Bedini G, Nava S, Hervé D, Vajkoczy P, European Moyamoya Disease Initiative et al (2016) Research progresses in understanding the pathophysiology of Moyamoya disease. *Cerebrovasc Dis* 41:105–118
  42. Santoro C, Giugliano T, Kraemer M, Torella A, Schwitalla JC, Cirillo M et al (2018) Whole exome sequencing identifies MRV11 as a susceptibility gene for moyamoya syndrome in neurofibromatosis type 1. *PLoS ONE* 13:e0200446
  43. Grangeon L, Guey S, Schwitalla JC, Bergametti F, Arnould M, Corpechot M (2019) Clinical and molecular features of five European multigenerational families with Moyamoya angiopathy. *Stroke* 50:789–796
  44. Akinsheye I, Klings ES (2010) Sick cell anemia and vascular dysfunction: the nitric oxide connection. *J Cell Physiol* 224:620–625
  45. Wood KC, Granger DN (2007) Sick cell disease: role of reactive oxygen and nitrogen metabolites. *Clin Exp Pharmacol Physiol* 34:926–932
  46. Hirsch RE, Sibmooh N, Fucharoen S, Friedman JM (2017) HbE/ $\beta$ -thalassemia and oxidative stress: the key to pathophysiological mechanisms and novel therapeutics. *Antioxid Redox Signal* 26:794–813
  47. Chamchoi A, Srihirun S, Paiboonsukwong K, Sriwantana T, Sathavorasmi P, Pattanapanyasat K et al (2018) Decreased nitrite reductase activity of deoxyhemoglobin correlates with platelet activation in hemoglobin E/ $\beta$ -thalassemia subjects. *PLoS ONE* 13:e0203955
  48. Hervé D, Philippi A, Belbouab R, Zerah M, Chabrier S, Colardieu-Frachon S et al (2014) Loss of  $\alpha$ 1 $\beta$ 1 soluble guanylate cyclase, the major nitric oxide receptor, leads to moyamoya and achalasia. *Am J Hum Genet* 94:385–394
  49. Crary SE, Buchanan GR (2009) Vascular complications after splenectomy for hematologic disorders. *Blood* 114:2861–2868
  50. Bader-Meunier B, Verlhac S, Elmaleh-Bergès M, Ithier G, Sellami F, Faïd S et al (2009) Effect of transfusion therapy on cerebral vasculopathy in children with sickle-cell anemia. *Haematologica* 94:123–126
  51. Schlens AM, Antonucci MU, Cafiero R, Burkett NS, Kanter J (2015) Moyamoya disease predicts progression of cerebral vasculopathy in patients with sickle cell disease despite chronic transfusion therapy. *Blood* 126:2071
  52. Kim JS (2016) Moyamoya disease: epidemiology, clinical features, and diagnosis. *J Stroke* 18:2–11
  53. Matsushige T, Kraemer M, Sato T, Berlitz P, Forsting M, Ladd ME et al (2018) Visualization and classification of deeply seated collateral networks in Moyamoya angiopathy with 7T MRI. *Am J Neuroradiol* 39:1248–1254
  54. Kraemer M, Karakaya R, Matsushige T, Graf J, Albrecht P, Hartung HP et al (2018) Efficacy of STA-MCA bypass surgery in moyamoya angiopathy: long-term follow-up of the Caucasian Krupp Hospital cohort with 81 procedures. *J Neurol* 265:2425–2433