

## A Case of Transcranial Direct-Current Stimulation for Childhood Stroke Hemiparesis: A Brief Report

P Ciechanski, HL Carlson, M Herrero, C Lane, FP MacMaster & A Kirton

To cite this article: P Ciechanski, HL Carlson, M Herrero, C Lane, FP MacMaster & A Kirton (2019): A Case of Transcranial Direct-Current Stimulation for Childhood Stroke Hemiparesis: A Brief Report, *Developmental Neurorehabilitation*, DOI: [10.1080/17518423.2019.1655678](https://doi.org/10.1080/17518423.2019.1655678)

To link to this article: <https://doi.org/10.1080/17518423.2019.1655678>



Published online: 19 Aug 2019.



Submit your article to this journal [↗](#)



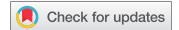Article views: 16



View related articles [↗](#)



View Crossmark data [↗](#)



# A Case of Transcranial Direct-Current Stimulation for Childhood Stroke Hemiparesis: A Brief Report

P Ciechanski<sup>a</sup>, HL Carlson<sup>b</sup>, M Herrero<sup>c</sup>, C Lane<sup>c</sup>, FP MacMaster<sup>d</sup>, and A Kirton<sup>a</sup>

<sup>a</sup>University of Calgary, Calgary, Alberta, Canada; <sup>b</sup>Alberta Children's Hospital Research Institute, University of Calgary, Calgary, Alberta, Canada; <sup>c</sup>Alberta Children's Hospital, Calgary, Alberta, Canada; <sup>d</sup>Mathison Centre for Mental Health Research & Education, University of Calgary, Calgary, Alberta, Canada

## ABSTRACT

**Purpose:** Survivors of childhood stroke incur lifelong physical disability. Treatment options are limited, however, models of motor reorganization after stroke are revealing cortical targets for neuromodulation. Transcranial direct-current stimulation (tDCS) enhances motor learning and may improve motor recovery in adult stroke, but remains uninvestigated in childhood-onset stroke. Here we documented the feasibility and safety of tDCS in an adolescent with chronic stroke-induced hemiparesis.

**Materials and methods:** Over 10 days, the participant underwent occupational therapy paired with contralesional, primary motor cortex-targeting, cathodal tDCS. Clinical motor outcomes, and safety and tolerability measures were completed.

**Results:** tDCS was well-tolerated with no adverse events. Motor outcomes did not regress post-intervention, with clinically significant changes still evident at 6 months.

**Conclusions:** Application of controlled trials of non-invasive neuromodulation are safe and tolerability in childhood-onset stroke.

## ARTICLE HISTORY

Received January 27, 2019

Revised Vxx xxx xxxx

Accepted August 10, 2019

## KEYWORDS

Non-invasive brain stimulation; tDCS; rehabilitation; stroke; pediatrics

## Introduction

Childhood stroke often causes disability that lasts decades.<sup>1</sup> Most survivors will suffer neurological disability, and motor disorders are most common.<sup>2</sup> Effective therapeutic options for these disorders are currently limited.<sup>3</sup> Advanced neuroimaging and brain mappings are defining neural reorganization following stroke, which may inform novel therapeutic targets.<sup>4</sup> Similar models are now being defined following stroke early in life.<sup>5</sup>

Neuromodulation with non-invasive brain stimulation may modulate cortical targets to enhance stroke recovery. Transcranial direct-current stimulation (tDCS) is a form of non-invasive brain stimulation increasingly applied in stroke rehabilitation. By passing weak electrical currents through surface electrodes positioned on the scalp, cortical regions can be shifted toward relative states of increased or decreased cortical excitability.<sup>6</sup> Anodal tDCS is suggested to produce relative regional hyperexcitability, whereas cathodal tDCS may reduce target excitability, although exceptions are increasingly recognized.<sup>7</sup> Changes in cortical excitability associated with tDCS appear to respect the principles of long-term potentiation and depression.<sup>8</sup>

Anodal tDCS over the primary motor cortex (M1) enhances motor learning in the contralateral hand, and cathodal tDCS over the M1 may also improve motor learning in the ipsilateral hand in adults.<sup>9,10</sup> Applying these principles to target the proposed imbalance of interhemispheric inhibition in adult stroke,<sup>11</sup> multiple adult trials of both lesioned anodal

and contralesional cathodal tDCS have suggested efficacy.<sup>12</sup> Experience with tDCS in children has been minimal to date.<sup>13</sup> We recently demonstrated that both anodal and cathodal M1 tDCS is safe, tolerable, and can enhance motor learning in school-aged children.<sup>14</sup> Taken together, this existing evidence supports the exploration of tDCS neuromodulation in children with stroke-induced hemiparesis.

Here we report the safety, tolerability and clinical effects of an open-label trial of daily contralesional tDCS during an intensive 2-week motor rehabilitation trial in an adolescent with severe hemiparesis secondary to childhood stroke.

## Materials and Methods

### Participant

A 17-year-old female incurred an arterial ischemic stroke secondary to acute diabetic ketoacidosis at 6 years of age. She had been right-handed. Acute neuroimaging diagnosed a left middle cerebral artery occlusion and complete infarction of the middle cerebral artery territory including the motor cortex and basal ganglia. At 11 years post-injury, she suffered from severe, disabling hemiparesis in the upper extremity. Distal power averaged 3 out of 5 with 4 out of 5 more proximally, with minimal coordinated hand and wrist movements, mild spasticity, and good range of motion. She had exhausted all available therapeutic options. She was functioning well in high school without cognitive or language deficits or other major comorbidities.

### Intervention: Therapy and tDCS

The participant was recruited to an open-label tDCS trial in parallel with an ongoing perinatal stroke rehabilitation clinical trial.<sup>15</sup> Over 10 consecutive weekdays, the participant received 60 min of daily intensive rehabilitation therapy targeting upper extremity function. This included 20 min of 1:1 occupational therapy that was individualized and goal-directed with evidence-based gross and fine motor skill training. This intensive therapy and the remaining full day therapy program adhered to TiDIER criteria.<sup>15</sup>

Cathodal tDCS was delivered during the first 20 min of each 60-min intensive therapy session (1:1 session with MScOT). Two 35 cm<sup>2</sup> saline-soaked sponge-electrodes were attached to a 1 × 1 DC Stimulator (Neuroconn; Ilmenau, Germany). The cathode was centered over the contralesional M1 hotspot, with location confirmed by transcranial magnetic stimulation and individualized MR-guided neuronavigation (Brainsight2, Rogue Research Inc.; Montreal). The anode was placed over the ipsilesional supraorbital region. Stimulation current was ramped to 1.5 mA over 45 s, held for 20 min, and ramped-down over 45 s. A TMS tolerability and side-effects questionnaire was modified for tDCS-specific adverse effects and administered weekly with reporting of any side-effects and comparing the stimulation to seven common childhood experiences.<sup>16</sup>

One week prior to the intervention baseline clinical outcomes were obtained, and repeated 1 week, 2 months and 6-months post-intervention.

### Clinical Outcomes: Motor Measures

The primary motor measure was the Jebsen Taylor Hand Function Test (JTT), an objective measure of hand function.<sup>17</sup> The measure consists of seven subtests that involve practical motor tasks including: writing (JTT1), flipping cards (JTT2), placing objects in a can (JTT3), stacking checkers (JTT4), picking up beans with a spoon, and lifting light and heavy cans. Due

to the severity of hemiparesis, the latter three tests were not performed. Scoring for ‘placing objects in a can’ was modified due to paresis severity, by dividing it three sections: (1) placing paperclips, (2) placing bottle caps, and (3) placing pennies into a can, allowing 40 s for each task (120 s total).

Additional validated clinical motor measures included the Assisting Hand Assessment (AHA)<sup>18</sup>, grip strength, Box & Block Test,<sup>19</sup> Melbourne Assessment of Unilateral Upper Limb Function (MAUULF),<sup>20</sup> and the Canadian Occupational Performance Measure (COPM).<sup>21</sup> Tests that measured unaffected hand function served as a safety measure to exclude any theoretical risk of decreased contralateral, unaffected hand function associated with contralesional cathodal tDCS.

## Results and Discussion

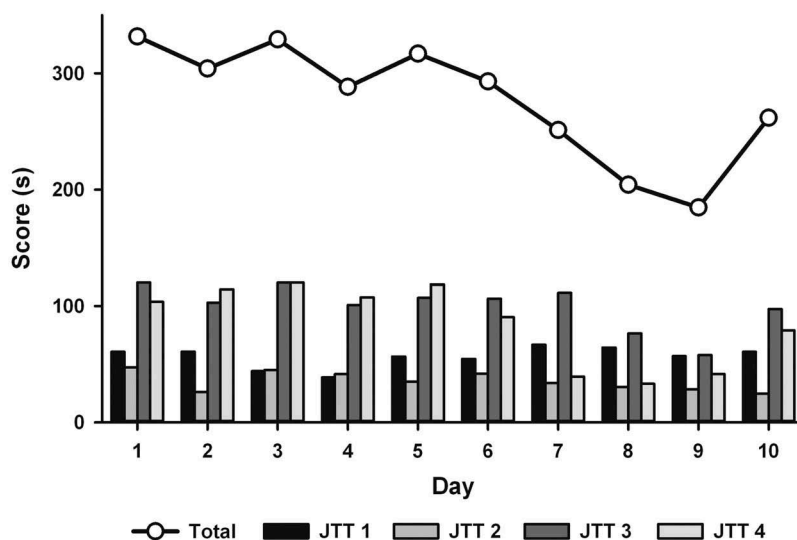
### tDCS Safety and Tolerability

All tDCS sessions were well tolerated. Typical tDCS sensations reported were mild tingling and itching during the ramp-up phase, typically subsiding within 3 min. The participant did not report additional side effects including headaches, neck pain, nausea, or light-headedness. Using a tolerability scale, the participant ranked tDCS as 2/8, comparable to watching TV.

Unaffected hand function did not decrease throughout the trial period. A 20-pound increase in grip strength was observed in the unaffected hand at 6 months. When the Box and Blocks test was performed with the unaffected hand, we observed a steady improvement throughout the trial (59 vs 68 at 1 week vs 6 months post-intervention). These scores are within 2 standard deviations of norm values seen for this age group (74.3 ± 9.1; range of 54–91).<sup>22</sup>

### Primary Motor Outcome: JTT

Daily JTT performance is summarized in Figure 1. At baseline, the time to complete the JTT using the paretic hand was



**Figure 1.** Jebsen–Taylor Hand Function Test (JTT). Scores of individual subtests are displayed as shaded-bars, with the total score (sum of subtest scores) reported as a black line. Minor improvements were noted between days 1 and 5, with large improvements were evident in the second week of treatment.

331 s. Minor fluctuations in total score were seen through the first week, with large improvements observed in the second week. Best performance was observed on Day 9, where 185 s represented a 44% improvement from baseline. Best performances for individual subtests compared to baseline were: JTT1 38.6vs60.7s; JTT2 24.7vs47.2s; JTT3 57.8vs120s; JTT4 33.1vs103.7s.

### Secondary Motor Outcomes

Motor outcomes are summarized in Table 1. AHA logit score significantly increased ( $\geq 5$  points) from 29 at baseline to 40 at 1-week post-intervention, 35 at 2 months and 33 at 6 months. COPM scores for both performance and satisfaction significantly increased ( $\geq 2$  points). The greatest improvements were seen in mean goal performance which increased from 2/10 at baseline to 8/10 post-intervention. Improvements were often maintained at 6 months. Paretic handgrip strength was stable. MAUULF score improvements were seen at all post-intervention evaluations, with maximum scores at 2 months. Improvements were seen in accuracy and fluency measures. Box and blocks test was performed at all time-points post-intervention, but not baseline due to patient fatigue.

### Discussion

This is the first published case of tDCS in childhood-onset stroke. Here we demonstrate preliminary evidence supporting feasibility and safety of tDCS-paired stroke rehabilitation in adolescents. Preliminary findings suggest that cathodal tDCS combined with occupational therapy is safe, tolerable, and does not decrease motor function.

The safety and tolerability of tDCS are well defined in adults, however, lacks the same degree of investigation in pediatrics. Our findings suggest that cathodal tDCS applied over the contralesional M1 is feasible, safe, and tolerable in adolescents suffering from stroke. Although commonly applied in adult stroke, evidence from healthy adults has been variable for cathodal tDCS where even possible disruption of motor learning has been described.<sup>23</sup> There is, therefore, an essential need for safety data in pediatric populations. Our findings suggest no decrease in affected or unaffected

hand function, consistent across a wide range of motor measures. Recently, we demonstrated that both contralateral anodal and ipsilateral cathodal tDCS can enhance motor learning in healthy school-aged children.<sup>14</sup> Tolerability of tDCS in pediatric disease populations is also increasingly defined. Gillick et al.<sup>24</sup> reported a 10-year-old child with hemiparesis that could not complete a trial due to discomfort of tDCS. In contrast, we documented that stimulation up to 2 mA was tolerable in 24 healthy children ages 7–18 years though younger children were more likely to rank itching as “moderate or severe” compared to adolescents.<sup>14</sup> Recently, we also demonstrated favorable safety and tolerability of 1 mA cathodal stimulation in 24 children with hemiparetic cerebral palsy following perinatal stroke.<sup>25</sup>

These variable observations may relate to several factors including differing strength of induced-electric fields and off-target stimulation. Computational current modeling can predict electric field strength and distribution in patients of different ages and conditions. For example, younger subjects likely experience differences in current intensity and distribution compared to adults.<sup>26</sup> Cortical strokes introduce additional variability such as the high conductivity of cerebrospinal fluid that fills the lesioned area and may shunt current to regions distant from the electrodes resulting in less predictable stimulation patterns.<sup>27</sup> Such computational current modeling methods should be considered to understand and ultimately optimize electrode position and current strength in both pediatric and stroke populations.

The primary objective of this case study was to demonstrate early feasibility of tDCS-paired rehabilitation in children with hemiparesis following childhood-onset stroke. The opportunity to participate in a parallel trial meant there was no option for a cross over, sham-controlled single subject trial, though this may be challenging with tDCS as subjects may need to be naïve for true blinding.<sup>28</sup> This lack of control conditions further limits any conclusions that can be drawn on the effects of tDCS and measured changes may have solely been due to the intensive occupational therapy; it is important to recognize that despite previous therapy the patient appeared to have plateaued in terms of recovery of motor outcomes, prior to the trial.

In conclusion, we provide preliminary experience of safety and feasibility of tDCS interventions combined with

**Table 1.** Summary of motor measures.

|                         | Pre-tDCS | Post-tDCS | 2MO Follow-Up | 6MO Follow-up |
|-------------------------|----------|-----------|---------------|---------------|
| AHA (logit-based score) | 29       | 40        | 35            | 33            |
| Box & block test        |          |           |               |               |
| - Unaffected hand       | -        | 59        | 62            | 68            |
| - Paretic hand          | 0        | 0         | 0             | 0             |
| Grip strength           |          |           |               |               |
| - Unaffected hand       | 58.3lbs  | 66.7lbs   | 75lbs         | 78.3lbs       |
| - Paretic hand          | 10.6lbs  | 10.6lbs   | 10.6lbs       | 10lbs         |
| Melbourne assessment    |          |           |               |               |
| - Range of motion       | 48%      | 48%       | 37%           | 37%           |
| - Accuracy              | 48%      | 52%       | 68%           | 64%           |
| - Fluency               | 62%      | 67%       | 76%           | 76%           |
| - Dexterity             | 0%       | 0%        | 0%            | 0%            |
| COPM                    |          |           |               |               |
| - Goal #1 performance   | 2/10     | 8/10      | 9/10          | 9/10          |
| - Goal #1 satisfaction  | 7/10     | 7/10      | 8/10          | 9/10          |
| - Goal #2 performance   | 1/10     | 6.5/10    | 4/10          | 6/10          |
| - Goal #2 satisfaction  | 2/10     | 7/10      | 5/10          | 7/10          |

Abbreviations: AHA, Assisting Hand Assessment; COPM, Canadian Occupational Performance Measure

comprehensive motor assessments in chronic hemiparesis secondary to childhood stroke. This should help advance larger studies. The benefits to young persons with disability and their families of just having the opportunity to try new therapeutic interventions should also not be underestimated.

## Declaration of Interest Statement

The authors report no conflict of interest.

## Funding

Financial support for the research was provided by the Alberta Children's Hospital Foundation [10155487].

## References

- Kirton A, DeVeber G. Paediatric stroke: pressing issues and promising directions. *Lancet Neurol.* 2015;14(1):92–102. doi:10.1016/S1474-4422(14)70227-3.
- deVeber G, MacGregor D, Curtis R, Mayank S. Neurologic outcome in survivors of childhood arterial ischemic stroke and sinovenous thrombosis. *J Child Neurol.* 2000;15(0883–0738):316–24. doi:10.1177/088307380001500508.
- Hebert D, Lindsay MP, McIntyre A, Kirton A, Rumney PG, Bagg S, Bayley M, Dowlatshahi D, Dukelow S, Garnhum M, et al. Canadian stroke best practice recommendations: stroke rehabilitation practice guidelines, update 2015. *Int J Stroke.* 2016;11(4):459–84. doi:10.1177/1747493016643553.
- Hsu WY, Cheng CH, Liao KK, Lee IH, Lin YY. Effects of repetitive transcranial magnetic stimulation on motor functions in patients with stroke: a meta-analysis. *Stroke.* 2012;43(7):1849–57. doi:10.1161/STROKEAHA.111.649756.
- Kirton A. Modeling developmental plasticity after perinatal stroke: defining central therapeutic targets in cerebral palsy. *Pediatr Neurol.* 2013;48(2):81–94. doi:10.1016/j.pediatrneurol.2012.08.001.
- Nitsche MA, Paulus W. Excitability changes induced in the human motor cortex by weak transcranial direct current stimulation. *J Physiol.* 2000;527:633–39.
- Moliadze V, Schmanke T, Andreas S, Lyzhko E, Freitag CM, Siniatchkin M. Stimulation intensities of transcranial direct current stimulation have to be adjusted in children and adolescents. *Clin Neurophysiol.* 2015;126(7):1392–99. doi:10.1016/j.clinph.2014.10.142.
- Stagg CJ, Nitsche MA. Physiological basis of transcranial direct current stimulation. *The Neuroscientist.* 2011;17(1):37–53. doi:10.1177/1073858410386614.
- Reis J, Schambra HM, Cohen LG, Buch ER, Fritsch B, Zarahn E, Celnik PA, Krakauer JW. Noninvasive cortical stimulation enhances motor skill acquisition over multiple days through an effect on consolidation. *Proc Natl Acad Sci USA.* 2009;106(5):1590–95. doi:10.1073/pnas.0805413106.
- Prichard G, Weiller C, Fritsch B, Reis J. Effects of different electrical brain stimulation protocols on subcomponents of motor skill learning. *Brain Stimul.* 2014;7(4):532–40. doi:10.1016/j.brs.2014.04.005.
- Murase N, Duque J, Mazzocchio R, Cohen LG. Influence of interhemispheric interactions on motor function in chronic stroke. *Ann Neurol.* 2004;55:400–09.
- Fregni F, Pascual-Leone A. Technology insight: noninvasive brain stimulation in neurology—perspectives on the therapeutic potential of rTMS and tDCS. *Nat Clin Pract Neurol.* 2007;3:383–93.
- Rajapakse T, Kirton A. Non-invasive brain stimulation in children: applications and future directions. *Transl Neurosci.* 2013;4:2. doi:10.2478/s13380-013-0116-3.
- Ciechanski P, Kirton A. Transcranial direct-current stimulation can enhance motor learning in children. *Cereb Cortex.* 2017;27(5):2758–67. doi:10.1093/cercor/bhw114.
- Kirton A, Anderson J. Brain stimulation and constraint for hemiparesis after perinatal stroke: The PLASTIC CHAMPS trial. *Eur J Paediatr Neurol.* 2015;19(S1):S10. doi:10.1016/S1090-3798(15)30030-1.
- Garvey MA, Kaczynski KJ, Becker DA, Bartko JJ. Subjective reactions of children to single-pulse transcranial magnetic stimulation. *J Child Neurol.* 2001;16:891–94. doi:10.1177/088307380101601205.
- Jebsen RH, Taylor N, Trieschmann RB, Trotter MJ, Howard LA. An objective and standardized test of hand function. *Arch Phys Med Rehabil.* 1969;50:311–19.
- Krumlinde-Sundholm L, Holmfur M, Kottorp A, Eliasson AC. The Assisting Hand Assessment: current evidence of validity, reliability, and responsiveness to change. *Dev Med Child Neurol.* 2007;49(4):259–64. doi:10.1111/j.1469-8749.2007.00259.x.
- Mulcahey MJ, Kozin S, Merenda L, Gaughan J, Tian F, Gogola G, James MA, Ni P. Evaluation of the box and blocks test, stereognosis and item banks of activity and upper extremity function in youths with brachial plexus birth palsy. *J Pediatr Orthop.* 2012;32(Suppl 2):S114–122. doi:10.1097/BPO.0b013e3182595423.
- Bourke-Taylor H. Melbourne assessment of unilateral upper limb function: construct validity and correlation with the pediatric evaluation of disability inventory. *Dev Med Child Neurol.* 2003;45(2):92–96. doi:10.1111/j.1469-8749.2003.tb00911.x.
- Carswell A, McColl MA, Baptiste S, Law M, Polatajko H, Pollock N. The Canadian occupational performance measure: a research and clinical literature review. *Can J Occup Ther.* 2004;71(4):210–22. doi:10.1177/000841740407100406.
- Mathiowetz V, Federman S, Wiemer D. Box and block test of manual dexterity: norms for 6–19 year olds. *Can J Occup Ther.* 1985;52(5):241–45. doi:10.1177/000841748505200505.
- Stagg CJ, Jayaram G, Pastor D, Kincses ZT, Matthews PM, Johansen-Berg H. Polarity and timing-dependent effects of transcranial direct current stimulation in explicit motor learning. *Neuropsychologia.* 2011;49(5):800–04. doi:10.1016/j.neuropsychologia.2011.02.009.
- Gillick BT, Feyma T, Menk J, Krach LE, Usset M, Vaith A, Wood TJ, Worthington R. Safety and feasibility of transcranial direct current stimulation in pediatric hemiparesis: a randomized controlled pilot study. *Phys Ther.* 2014;95(3):337–49.
- Kirton A, Ciechanski P, Zewdie E, Andersen J, Nettel-Aguirre A, Carlson H, Carsolio L, Herrero M, Quigley J, Mineyko A, et al. Transcranial direct current stimulation for children with perinatal stroke and hemiparesis. *Neurology.* 2017;88(3):259–67. doi:10.1212/WNL.0000000000003518.
- Ciechanski P, Carlson HL, Yu SS, Kirton A. Modeling transcranial direct-current stimulation-induced electric fields in children and adults. *Front Hum Neurosci.* 2018;12:268. doi:10.3389/fnhum.2018.00352.
- Datta A, Baker JM, Bikson M, Fridriksson J. Individualized model predicts brain current flow during transcranial direct-current stimulation treatment in responsive stroke patient. *Brain Stimul.* 2011;4(3):169–74. doi:10.1016/j.brs.2010.11.001.
- Ambrus GG, Al-Moyed H, Chaieb L, Sarp L, Antal A, Paulus W. The fade-in – Short stimulation – Fade out approach to sham tDCS – Reliable at 1 mA for naïve and experienced subjects, but not investigators. *Brain Stimul.* 2012;5(4):499–504. doi:10.1016/j.brs.2011.12.001.