

Moyamoya disease with epileptic nystagmus: A case report

Chie Nakayama^a, Takeshi Mikami^{a,*}, Ryo Ukai^a, Ryohei Chiba^a, Rei Enatsu^a, Hime Suzuki^a, Toru Hirano^b, Nobuhiro Mikuni^a

^a Department of Neurosurgery, Sapporo Medical University, Sapporo, Japan

^b Division of Radiology, Sapporo Medical University Hospital, Sapporo, Japan



ARTICLE INFO

Article history:

Received 25 June 2019

Accepted 7 August 2019

Keywords:

Moyamoya disease

Seizure

Epileptic nystagmus

Ischemic attack

ABSTRACT

Epileptic nystagmus is a quick, repetitive, jerky movement of the eyeball caused by seizure activity, which is unaccompanied by other ictal phenomena. We report a case of moyamoya disease with epileptic nystagmus. A 23-year-old woman presented with a headache and transient hemiparesis on her left side. Magnetic resonance imaging showed no ischemic or hemorrhagic stroke lesions. Digital subtraction angiography confirmed stenosis of the terminal portion of the right internal carotid artery and the formation of moyamoya vessels on the right side. ¹²³I-N-isopropyl-iodoamphetamine (¹²³I-IMP) single photon emission computed tomography (SPECT) showed decreased uptake in the right basal ganglia, frontal, and parietal regions. After electroencephalography (EEG) and a hyperventilation test were performed, nystagmus appeared and was accompanied with a declining level of consciousness. Ictal EEG during an attack showed no epileptiform discharge. Moreover, the patient sometimes experienced simultaneous upper limb-shaking and gelastic attacks. After superficial temporal artery to middle cerebral artery bypass surgery was performed on the right side, symptom frequency and duration gradually decreased. Decreased ¹²³I-IMP SPECT blood flow in the right frontal region is considered a mechanism that causes the onset of epileptic nystagmus. It is presumed that the attack was caused by an ischemic abnormality in the saccade region of the frontal eye field. Moreover, revascularization can effectively treat the symptoms of moyamoya disease.

© 2019 Elsevier Ltd. All rights reserved.

1. Introduction

Moyamoya disease is a chronic and occlusive cerebrovascular disease, which has an unknown etiology and is characterized by bilateral steno-occlusive changes at the terminal portion of the internal carotid artery (ICA) and an abnormal vascular network at the base of the brain [1]. The initial representative symptoms are infarction and transient ischemic attack (TIA), which result from ischemia, and hemorrhage or headache, which results from the expansion of collateral vessels distal to the stenotic lesion. Epilepsy is the third most common manifestation in moyamoya disease [2], and approximately 10–30% of moyamoya disease patients present with seizures [3]. Recurrent seizure attacks in moyamoya disease should be regarded as symptomatic localization-related epilepsy caused by a stroke after ischemic or hemorrhagic attacks [4]. Risk factors for epilepsy in moyamoya disease are considered to be modified Rankin scale scores, early seizures, and diffuse brain atrophy [3]. The clinical features of epilepsy in patients with moyamoya disease have rarely been discussed in detail.

Here, we report a case of moyamoya disease with epileptic nystagmus. Epileptic nystagmus is a quick, repetitive, jerky movement of the eyeball caused by seizure activity, which is unaccompanied by other ictal phenomena [5]. Its etiological factors include trauma, cerebral vascular diseases, tumors, and anoxia. To our knowledge, this is the first report of moyamoya disease with epileptic nystagmus. Moreover, the epileptic nystagmus disappeared after revascularization surgery in this case, which we report along with the relevant literature.

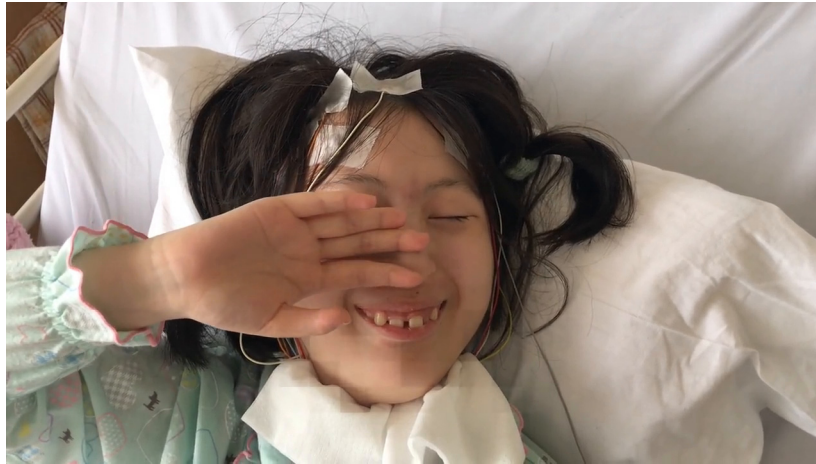2. Case report

A 23-year-old woman presented with a headache and transient hemiparesis on her left side. She had a chromosomal abnormality (46, XX, –9+der(9)t(6;9)pat), presented with congenital hypotonia, and showed mental and motor retardation. Her father was also diagnosed with moyamoya disease. Magnetic resonance imaging (MRI) showed the ivy sign on the fluid attenuated inversion recovery (FLAIR) sequence in the right hemisphere, though there was no ischemic or hemorrhagic stroke lesion (Fig. 1A). Digital subtraction angiography and magnetic resonance angiography confirmed the stenosis of the terminal portion of the right ICA and the formation of moyamoya vessels on the right side, and the patient was diagnosed with moyamoya disease with Suzuki's angiographic staging of grade III (Fig. 1B–D). Resting state ¹²³I-N-isopropyl-iodoamphetamine (¹²³I-IMP) single photon emission computed tomography (SPECT) for cerebral blood flow showed decreased uptake in the right basal ganglia, frontal, and parietal regions (Fig. 1E). Computed tomography (CT) perfusion showed decreased cerebral blood flow (CBF) and delayed mean transit time (MTT) in the same regions (Fig. 1F).

On the seventh day of hospitalization, the patient underwent electroencephalography (EEG), and after hyperventilation test, she complained of a poor physical condition, and nystagmus appeared that was accompanied by a declining level of consciousness. Ictal EEG during an attack showed only a prominent muscle artifact caused by eye movements due to nystagmus, and no epileptiform discharge was observed. During the seizures, her eyes had a horizontal left-beating nystagmus in which her eyes did not cross the midline of the orbit during the slow phase. From that day onwards, similar seizures appeared frequently. Most of the nystagmus involved eye movement, which occurred horizontally and to the left. The patient sometimes reacted to a call and sometimes had impaired consciousness (Video 1). The duration of the seizures

* Corresponding author at: Department of Neurosurgery, Sapporo Medical University, South 1 West 16, Chuo-ku, Sapporo 060-8543, Japan.

E-mail address: tmikami@sapmed.ac.jp (T. Mikami).



Video 1.

ranged from 3 to 30 min. Moreover, she sometimes suffered an upper limb-shaking and a gelastic attack simultaneously. It was impossible to confirm whether this gelastic attack onset was associated with a feeling of mirth because of the patient's decreased awareness. This attack often occurred after hyperventilation due to crying or discomfort. After the appearance of the attack, we began administering antiepileptic drugs (Levetiracetam 1000 mg). The course of the appearance of epileptic nystagmus in the patient is shown in Fig. 2. On the fourteenth day after admission, superficial temporal artery to middle cerebral artery bypass surgery was performed on the right side. After the operation, symptom frequency gradually decreased and almost disappeared after approximately two months.

3. Discussion

From a neurophysiological view point, the mechanisms of epileptic nystagmus are classified into two patterns: saccadic eye movements and smooth pursuit eye movements [5]. Fig. 3 shows the origins of these two patterns. First, the regions causing saccadic movements include the frontal eye field near the precentral sulcus, the supplementary eye field in the superior frontal region near the sulcus, the dorsolateral prefrontal cortex, the parietal eye field in the anterior part of the angular sulcus, and the posterior parietal cortex [6–8]. Epileptic nystagmus originating in cortical regions causing saccadic movements produce the fast phase of the nystagmus beating opposite the side of the epileptic focus without cross-

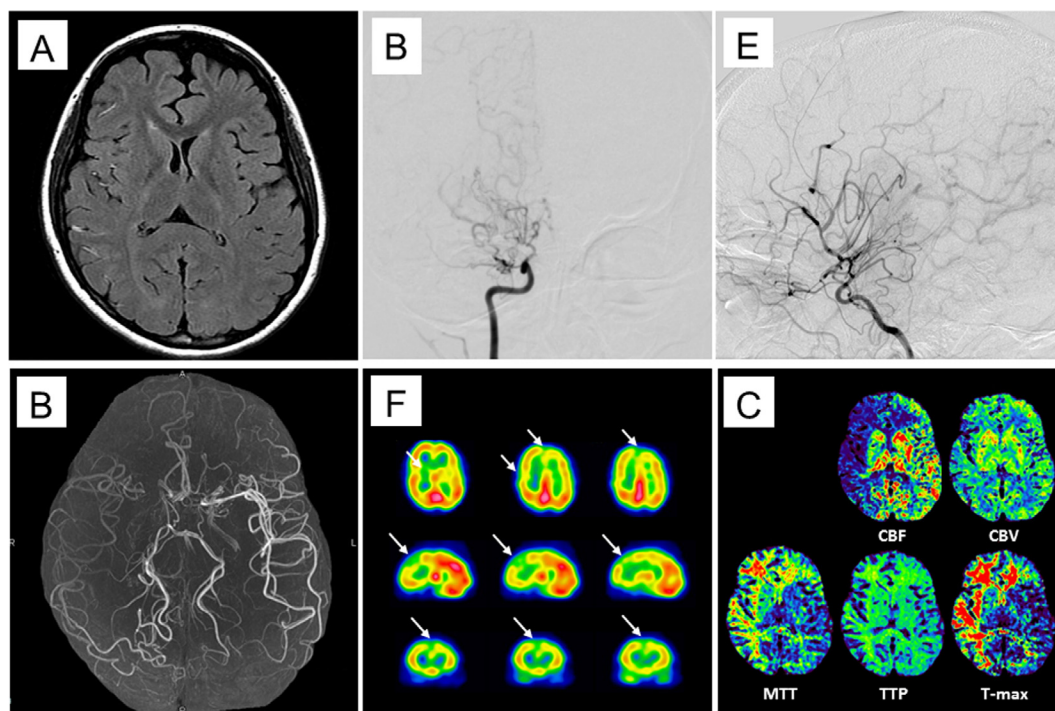


Fig. 1. FLAIR imaging showed the ivy sign in the right hemisphere without a stroke lesion (A). AP view (B) and lateral view (C) of digital subtraction angiography showed the stenosis of the terminal portion of the right ICA and moyamoya vessels around the circle of Willis on the right side. The stenosis of the terminal portion of the right ICA was observed on magnetic resonance angiography (D). Intercal ^{123}I -IMP SPECT showed decreased uptake in the right basal ganglia, frontal, and parietal regions (E). CT perfusion showed decreased CBF, delayed MTT, and prolonged T-max in the same regions. Changes in CBV and TTP in the right hemisphere were limited (F).

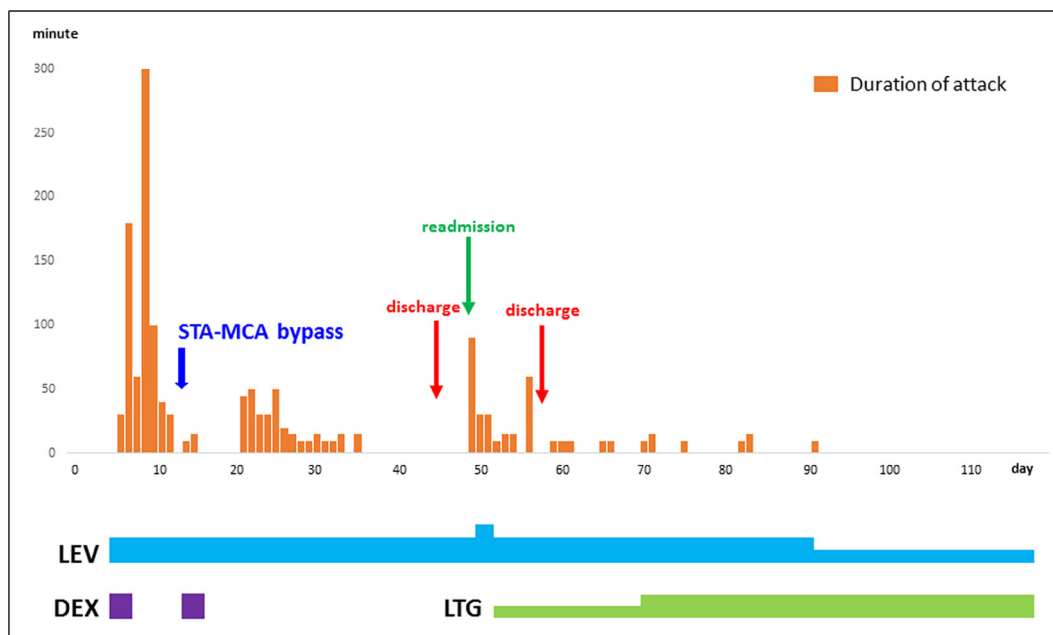


Fig. 2. The clinical course of the patient presenting with epileptic nystagmus. The total duration of epileptic nystagmus is plotted, and the treatment modality is mentioned in the figure. STA-MCA bypass: superficial temporal artery to middle cerebral artery bypass, LEV: Levetiracetam, LTG: Lamotrigine.

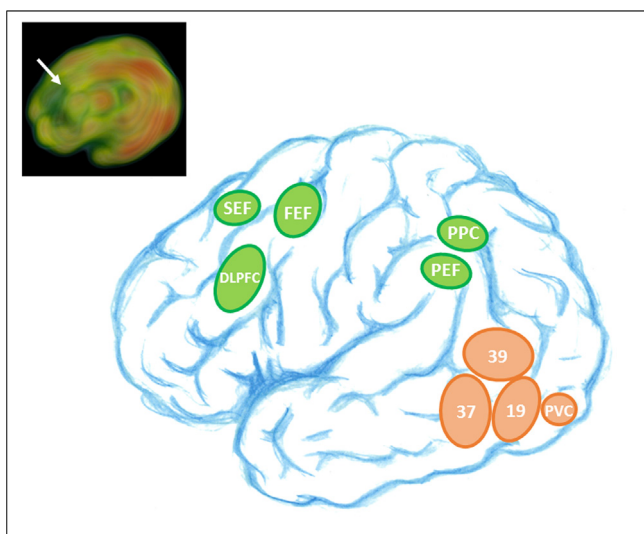


Fig. 3. Schematic drawings of the human saccade regions that should be an origin of epileptic nystagmus. Green shows the regions causing saccadic movements, and orange shows the regions causing smooth pursuit eye movements. Upper left small window shows the sagittal view of the volume data of the right hemisphere on ^{123}I -IMP SPECT, and white arrow shows the decreased uptake in the right frontal lobe. FEF: frontal eye field, SEF: supplementary eye field, DLPFC: dorsolateral prefrontal cortex, PEF: parietal eye field, PPC: posterior parietal cortex, PVC: primary visual cortex, 37/19/39: Brodmann areas 37/19/39.

ing the midline during the slow phase. Second, the regions causing smooth pursuit eye movement include Brodmann areas 37/19/39 and the primary visual cortex [7]. Epileptic nystagmus originating in a cortical area involved in smooth pursuit eye movements shows a slow ipsiversive eye movement that crosses the midline [5,7]. The symptoms in our case were similar to saccadic eye movements. Although MRI showed no infarction, SPECT and perfusion CT showed decreased blood flow in the right frontal region, which is presumed that a functional abnormality caused by ischemia

occurred in the saccade region, and this might have induced epileptic nystagmus.

Together with nystagmus, some cases have been associated with other symptoms: episodic gaze deviation, visual hallucinations, cortical blindness, vertigo, and impaired consciousness [5,7,9–11]. In our case, dizziness, impaired consciousness, limb-shaking, and gelastic seizure accompanied epileptic nystagmus. Limb-shaking is considered to be one of the movement disorders due to vascular etiology, and presumed to be caused by impaired perfusion of the frontal lobe [12]. Gelastic seizures occur most commonly in epilepsy arising from hypothalamic hamartoma, and have subsequently been described in frontal or temporal lobe epilepsies [13]. We previously reported a case of moyamoya disease with gelastic seizure that should be occurred due to frontal lobe ischemia [14]. Ohara et al. reported a case of epileptic nystagmus accompanying gelastic seizure, and the attack was considered to originate in the frontal lobe [15]. The gelastic attack in our case is also presumed to be an abnormality of the frontal lobe because SPECT showed decreased blood flow in the right frontal region. Gelastic attack due to frontal lobe epilepsy occurs without feelings of mirth, and is most likely originated in the anterior cingulate and superior frontal gyrus [16]. These regions are close to the frontal eye field (FEF) and hence, ischemia may spread to the anterior cingulate or superior frontal gyrus that is associated with gelastic seizures.

4. Conclusion

Epileptic nystagmus may develop due to hypoperfusion of the frontal lobes in moyamoya disease. Although it is difficult to judge whether it is a symptom of epileptic seizures or ischemic attack, revascularization can effectively control epileptic nystagmus.

Acknowledgments

None.

References

- [1] Suzuki J, Takaku A. Cerebrovascular, “moyamoya” disease. Disease showing abnormal net-like vessels in base of brain. *Arch Neurol* 1969;20:288–99.
- [2] Scott RM, Smith ER. Moyamoya disease and moyamoya syndrome. *N Engl J Med* 2009;360:1226–37.
- [3] Mikami T, Ochi S, Houkin K, Akiyama Y, Wanibuchi M, Mikuni N. Predictive Factors for Epilepsy in Moyamoya Disease. *Journal of Stroke and Cerebrovascular Diseases*. 2015;24:17–23.
- [4] Manceau E, Giroud M, Dumas R. Moyamoya disease in children. A review of the clinical and radiological features and current treatment. *Childs Nerv Syst* 1997;13:595–600.
- [5] Ma Y, Wang J, Li D, Lang S. Two types of isolated epileptic nystagmus: case report. *Int J Clin Exp Med* 2015;8:13500–7.
- [6] Pierrot-Deseilligny C, Milea D, Muri RM. Eye movement control by the cerebral cortex. *Curr Opin Neurol* 2004;17:17–25.
- [7] Weber YG, Roesche J, Lerche H. Epileptic nystagmus: two case reports, clinical and pathophysiological review of the literature. *J Neurol* 2006;253:767–71.
- [8] Valsecchi M, Gegenfurtner KR, Schutz AC. Saccadic and smooth-pursuit eye movements during reading of drifting texts. *J. Vision* 2013;13:8–.
- [9] Bekdik P, Sener U, Asan IF, Ozcelik M, Zorlu Y. Epileptic nystagmus. *Epileptic Disord. Int Epilepsy J. Videotape* 2006;8:305–8.
- [10] Schulz R, Tomka-Hoffmeister M, Woermann FG, Hoppe M, Schittkowski MP, Ebner A, et al. Epileptic monocular nystagmus and ictal diplopia as cortical and subcortical dysfunction. *Epilepsy Behav Case Rep* 2013;1:89–91.
- [11] Lee SU, Suh HI, Choi JY, Huh K, Kim HJ, Kim JS. Epileptic nystagmus: A case report and systematic review. *Epilepsy Behav Case Rep*. 2014;2:156–60.
- [12] Kim HY, Chung CS, Lee J, Han DH, Lee KH. Hyperventilation-induced limb shaking TIA in Moyamoya disease. *Neurology* 2003;60:137–9.
- [13] Kovac S, Diehl B, Wehner T, Fois C, Toms N, Walker MC, et al. Gelastic seizures: incidence, clinical and EEG features in adult patients undergoing video-EEG telemetry. *Epilepsia* 2015;56:e1–5.
- [14] Suzuki H, Mikami T, Enatsu R, Kanno A, Takahashi Y, Mikuni N. Gelastic attack in a child with moyamoya disease. *Neurology* 2018;91:141–2.
- [15] Ohara K, Morita Y, Takauchi S, Takeda T, Hayashi S. Multicystic encephalopathy with frontal lobe-originated gelastic seizure, ipsilateral oculogyric crisis, and horizontal epileptic nystagmus: an autopsy case. *Clin Neurol* 1996;36:962–7.
- [16] Fernandez-Baca Vaca G, Luders HO, Basha MM, Miller JP. Mirth and laughter elicited during brain stimulation. *Epileptic Disord Int Epilepsy J Videotape* 2011;13:435–40.

<https://doi.org/10.1016/j.jocn.2019.08.069>

Secondary hypokalemic paralysis with bulbar weakness and reversible electrophysiologic abnormalities: A case report and systematic review



Katrina Hannah D. Ignacio*, Marjorie Anne C. Bagnas, Adrian I. Espiritu, Jose Paciano Baltazar T. Reyes

Department of Neurosciences, College of Medicine and Philippine General Hospital, University of the Philippines – Manila, Taft Avenue, Ermita, Manila 1000, Philippines

ARTICLE INFO

Article history:

Received 25 June 2019

Accepted 7 August 2019

Keywords:

Hypokalemic periodic paralysis

Bulbar symptoms

Reversible electrophysiologic changes

Nerve conduction studies

ABSTRACT

Hypokalemic periodic paralysis secondary to distal renal tubular acidosis presenting with prominent bulbar symptoms is extremely rare. The exact pathophysiology by which hypokalemia causes weakness is yet to be elucidated though muscle and nerve membrane hyperpolarization have been hypothesized. The pathophysiology of bulbar involvement in this condition is even more unclear. We report a case presenting as acute flaccid quadriplegia with prominent bulbar symptoms that reversed once potassium levels returned to normal. Serial nerve conduction studies were performed at various potassium levels revealing electrophysiologic abnormalities that corrected with potassium repletion. A systematic review of the literature was also conducted focusing on bulbar symptoms and electrophysiologic findings in hypokalemic periodic paralysis. Nerve conduction abnormalities in this condition are seldom documented, but reports have shown reduced amplitudes of compound motor action potentials and abnormal F-waves during acute attacks of hypokalemic paralysis.

© 2019 Elsevier Ltd. All rights reserved.

1. Introduction

Hypokalemic periodic paralysis (HPP) is a rare condition caused by low serum potassium levels (<3.6 mmol/L) [1]. Distinct from primary hereditary HPP, secondary HPP arises from endocrine, renal, and iatrogenic etiologies [1–4]. Weakness typically begins in the proximal limb musculature and spreads distally without involving the respiratory and cranial nerve musculature [2,5].

To our knowledge, the incidence of bulbar symptoms in hypokalemia is unknown. Similarly, very few reports have documented electrophysiologic changes during attacks of weakness in HPP [6,7]. Herein, we describe an atypical case of secondary HPP from distal renal tubular acidosis (DRTA) which presented with prominent bulbar symptoms. Serial nerve conduction studies (NCS) demonstrated reversible electrophysiologic changes. A systematic review was also conducted focusing on bulbar symptoms and electrophysiologic findings in HPP.

2. Case description

A 50-year-old male with no co-morbidities presented at the emergency department with a 3-day history of first onset, acute, generalized, flaccid paralysis with dysphonia, dysphagia, and dysarthria. This was not preceded by infection, heavy exercise, or carbohydrate loading. Family history was non-contributory. The patient was awake and oriented with severely weak guttural, lingual and gag reflex. Muscle stretch reflexes were diminished on all extremities while sensory testing was normal.

Serum electrolytes done in another institution were normal, hence, a stat nerve conduction study (NCS) was performed. Compound muscle action potential (CMAP) amplitudes were reduced with slowing of distal latencies and conduction velocities. F-waves were prolonged on the tibial nerves and absent on the median and ulnar nerves. Sensory nerve conduction studies were normal. Guillain Barre Syndrome was considered and plasma exchange contemplated due to unavailability of intravenous immunoglobulin. However, repeat serum electrolytes at our institution showed severe hypokalemia (1.7 mmol/L). Oral and intravenous potassium correction caused significant improvement in

* Corresponding author.

E-mail address: kdignacio@up.edu.ph (K.H.D. Ignacio).