

Case report

Confusion, dissociation and bizarre behaviour as the onset of an early Susac syndrome

Marta Pérez-Lombardo,¹ Íñigo Alberdi-Páramo,¹ Belén Ramos-Barragán,² Diana Gimeno-Álvarez¹

¹Instituto de Psiquiatría y Salud Mental, Hospital Universitario Clínico San Carlos, Madrid, Spain

²Hospital Universitario Virgen del Rocío, Sevilla, Spain

Correspondence to

Marta Pérez-Lombardo, martaperezlombardo@gmail.com

Accepted 13 August 2019

SUMMARY

A 47-year-old woman presented an episode of confusion and disorientation. According to remarkable psychiatric records, she had been treated for major depression and obsessive-compulsive disorder; however, no other relevant background was known. After preliminary examinations, blood analysis and neurological tests were unspecific and inconclusive. Therefore, the case was treated as a possible psychiatric episode related to her previous psychiatric disorders. However, due to the atypical presentation of the case, a cerebral MRI was performed, which demonstrated multiple central lesions of the corpus callosum ('snowball lesions'), as well as several supratentorial white matter lesions. As a result of the follow-up of the case, sensorineural hearing loss and branch retinal artery were detected, which concluded in the classic triad and the confirmation of the diagnosis of a Susac syndrome.

BACKGROUND

Susac syndrome is an autoimmune-mediated microangiopathy which affects the vessels of the brain, retina and inner ear.¹ The classic triad consists of encephalopathy, branch retinal artery occlusion and sensorineural hearing loss, although it might not be present at the beginning of the illness.²

Encephalopathy has a myriad of presentations: confusion, cerebellar dysfunction, cognitive impairment and neuropsychiatric symptoms.³ In fact, in recent cases, the diagnosis is made when vision and hearing loss is documented.⁴ The purpose of this case is to outline that Susac syndrome may have various early-onset symptoms; therefore, the disease can be diagnosed earlier and treated more aggressively before it causes severe damage to the patient.

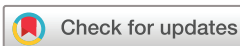CASE PRESENTATION

A 47-year-old woman presented an episode of confusion associated with spatial and temporary disorientation in the morning. The patient said that she had difficulties focusing on simple tasks such as housework over the last 2 months. She also described episodes of dizziness, normally associated with high levels of anxiety related to daily life situations, which concluded to insomnia. As a result of her anxiety, her family doctor prescribed betahistine and lorazepam 1mg/day for 1 week before the episode, both taken at night, improving her insomnia. She also verbalised spontaneous hemicrania oppressive headaches, but no

photophobia, phonophobia or symptoms associated with the parasympathetic nervous system (profuse sweating, dizziness, slow pulse, nausea or vomiting). The patient also described additional symptoms such as dizziness and instability similar to vertigo symptoms. Furthermore, her partner said that she was having temporary disorientation episodes and that she was not able to remember important events of her life, such as the death of her father 5 years ago.

According to the patient's psychiatric personal history, she was diagnosed with obsessive-compulsive disorder 20 years ago and after a 3-year treatment has been in remission. The patient also suffered from major depression, which was first related to an abortion and followed by several relapses all related to stressful life events in the following years. Apart from her depression, the patient had no other significant medical or family history.

Observations from the first neurological examination concluded that the patient presented partial space disorientation (correct city but not the right hospital) and total temporary disorientation (incorrect date, including the year). Although attention was preserved (she named all the 12 months backwards correctly), calculation was only possible subtracting 4 from 100, not 7 from 100. In addition, her memory was altered, obtaining a digit span task within six and two recalls (forward and backward), a score of 0 out of 8 on the Memory Impairment Screen and a normal clock-drawing test without visuospatial dysfunction reported. Language was fluent and spontaneous without aphasic elements, and nomination of objects and name registration were preserved. The patient correctly obeyed axial and appendicular orders. However, phonemic and semantic fluencies were altered, with a frequency of only four words per minute. During examination she tended to manipulate objects with no purpose. Cranial nerves were not altered. A limb examination showed normal tone and power. Hyper-reflexia was noted on stretch reflex tests. Sensory tests showed altered proprioception with failures in more than 50% of the distal interphalangeal determination movement of the four limbs. No further abnormalities on sensory tests were found and coordination was not altered. Cerebellar signs were not observed. Gait was described as little walk steps, not being able to explore the tandem gait due to the instability perceived by the patient. Video head impulse test was negative.



© BMJ Publishing Group Limited 2019. No commercial re-use. See rights and permissions. Published by BMJ.

To cite: Pérez-Lombardo M, Alberdi-Páramo Í, Ramos-Barragán B, et al. *BMJ Case Rep* 2019;**12**:e229422. doi:10.1136/bcr-2019-229422

Psychopathological examination showed remarkable inhibition during the interview. For example, no proper eye contact was made with the interviewer. Language was spontaneous and fluent, and the patient had coherent and grammatically correct structured speech, with no semantic or syntactic errors. The thinking process was unaltered, although ruminative thoughts classified as obsessive kind were present, with no behavioural consequences in daily life described by her or her partner. No psychotic symptoms (delusion or altered perceptions) were reported at first examination, and the patient said her mood was low. A diminution of expressions of emotions was observed, not categorised as alexithymia as concerns about her problems were verbalised by the patient. Anxiety was verbalised but not shown at this time. Insomnia and low appetite were also reported. Insight was conserved, as she recognised all limitations caused by her mental status.

The cognitive impairment was not congruent with the possibility of describing anxiety symptoms as the principal cause of the disease. Therefore, the patient was hospitalised to make further examinations.

INVESTIGATIONS

Brain CT was normal. An MRI of the brain showed T2 hyperintense multifocal supratentorial white matter lesions located in the periventricular, subcortical and juxtacortical areas. The cerebellum, basal ganglia, median cerebellar peduncles and corpus callosum were also affected (figure 1A–C). Routine laboratory analysis, thyroid stimulating hormone, ACE, antinuclear antibody, antiendothelial cell antibodies, lupus anticoagulant, protein electrophoresis, anti-NMO antibodies titre, and testing for HIV, hepatitis B and C, Epstein-Barr, toxoplasmosis, herpes zoster, herpes simplex, cytomegalovirus, *Borrelia burgdorferi* and measles virus were all negative. Oligoclonal bands in the cerebrospinal fluid (CSF) were absent. CSF showed an isolated elevation of protein (147), with normal levels of glucose, and no white or red blood cells present. Electroencephalography was unspecific. Tests for autoimmune encephalitis were not carried out due to limitations in hospital resources.

Retinal fluorescein angiography was normal at this time, showing a vasculitis focus on the right eye 1 month later. Tone audiometry revealed right light sensorineural hearing loss, getting worse one month later as it became mild to moderate.

DIFFERENTIAL DIAGNOSIS

The initial differential diagnosis took place in a wider field than usual: neurological versus psychiatric disorder. As mentioned above, cognitive impairment was not congruent with a mood disorder, and psychotic symptoms were not present at the

time of the first interview. On the third day of hospitalisation, the patient presented disorientated behaviour: she looked for her personal things at the same place several times, could not give concrete answers to the questions asked, and presented loss of anal sphincter during one of the neurological examinations. Nevertheless, the MRI showed white matter lesions, and according to the inconclusive and unspecific psychiatric symptoms primary psychiatric disorders were excluded.

Afterwards, the differential diagnosis was focused on inflammatory, degenerative, tumorous, infectious, vascular, toxic-metabolic and autoimmune causes. Given the negative results obtained from the investigations carried out and the answer to corticosteroids registered, an autoimmune cause was the first diagnosis proposed.

TREATMENT

The patient was first treated with intravenous methylprednisolone and intravenous immunoglobulin (IVIG), with good initial response. Azathioprine (50 mg/day) was added for maintenance. Oral prednisone (40 mg/day) was prescribed with gradual dose reduction for the outpatient follow-up.

OUTCOME AND FOLLOW-UP

One month later, after her first treatment, the patient suffered a relapse which was caused by insufficient doses of oral prednisone after leaving the hospital. The patient presented language alterations and cognitive impairment, similar to the first episode. Therefore, she was treated with methylprednisolone once more and covered with higher doses of prednisone (60 mg/day) until azathioprine reached therapeutic doses 3 months later. A new MRI was done, which showed radiological improvement of the corpus callosum lesions and the left cerebellar lesion (figure 2A,B), without new lesions and no contrast enhancement.

Two days after leaving the hospital for the second treatment, the patient was hospitalised once again for emesis and behavioural alterations (psychomotor inhibition and oppositionist attitude). However, this time, the brain MRI showed new subcortical and pons (mostly in the pons and medulla oblongata junction) T2 hyperintense lesions (figure 2C). In addition, millimetric leptomeningeal lesions showed up with contrast enhancement, along with deterioration of hearing capacity in the right ear (figure 3) and retinal branch ischaemia on the left eye. The patient was again treated with IVIG, and two treatment cycles with cyclophosphamide (15 mg/kg) were added to the initial treatment, resulting in good initial response and tolerance.

In conclusion, the patient experienced recovery from the neurological symptoms, as well as an improvement in neuropsychiatric symptoms; no further psychotic or dissociative episodes

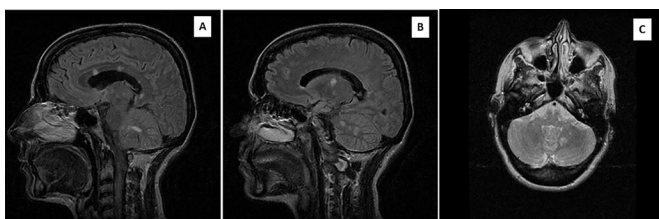

Figure 1 Fluid-attenuated inversion recovery (FLAIR) MRI at presentation. (A) FLAIR sagittal MRI showing white matter lesions in the corpus callosum (snowball lesions) and cerebellum lesion. (B) FLAIR sagittal MRI which shows the extension of the cerebellum lesion and the affection of the basal ganglia. (C) FLAIR axial MRI with a new view of the cerebellum lesion.

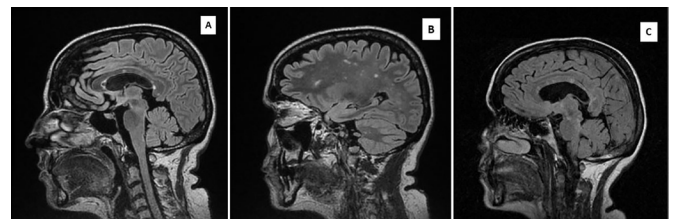

Figure 2 Fluid-attenuated inversion recovery sagittal MRI 1 month later at second (A,B) and third (C) hospitalisations. (A) The remaining lesions still including the characteristic lesions of the corpus callosum, although to a lesser extent than those shown on the first MRI. (B) Diffuse subcortical white and grey matter lesions. (C) New subcortical and pons and medulla oblongata junction T2 hyperintense lesions.

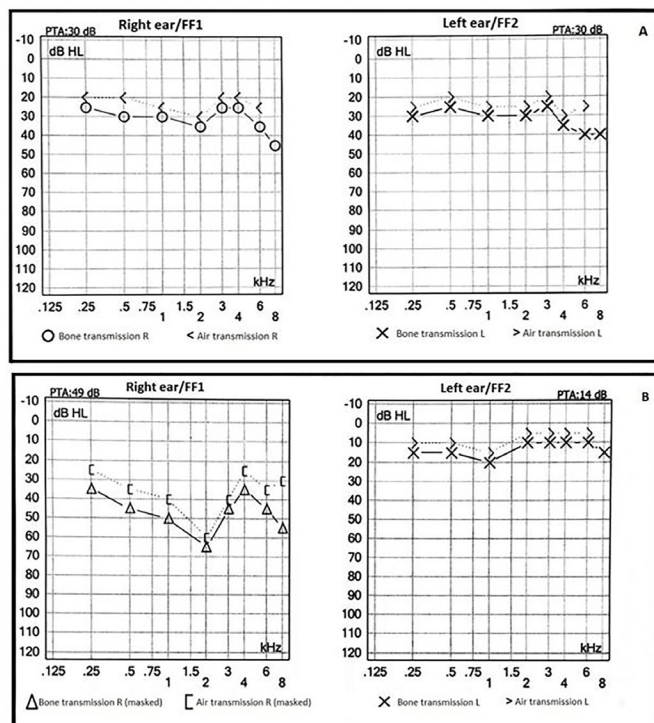


Figure 3 Tone audiometry. The horizontal axis shows the frequency in kilohertz, while the vertical axis shows the decibel level at which the frequency is perceived. (A) Tone audiometry at presentation. No damage was found. (B) Tone audiometry at relapse 1 month later. It shows sensorineural hearing loss in the right ear, with 40% drop in the middle and low frequencies. FF1, Free Field 1 and FF2, Free Field 2 (right and left ear); PTA, Pure Tone Average.

were reported and her memory was recovered. The patient is currently on treatment with azathioprine.

DISCUSSION

Susac syndrome is a rare disease which has probably been misdiagnosed numerous times, although the reported cases over the past 10 years have helped create awareness of the disease and the neuropsychiatric symptoms that may be observed. Gender is a relevant characteristic in this syndrome, as it affects women between 20 and 40 years old, with a male to female ratio of 1:3.5.¹ The development of the illness depends on gender, with a better prognosis among men.²

In 2013, Dörr *et al*² published a review of all Susac cases reported until December 2012. Only 13% of the patients had the typical clinical triad at disease onset. Normally, after 21 weeks, the triad was complete. Some primary symptoms are headaches, cognitive impairment (usually with loss of memory, concentration and executive functions), confusion (normally with disorientation), emotional disturbance and behavioural changes.² In our case, the triad only took 4 weeks to be reported, and the symptoms at onset consisted of headache, confusion and also dissociation. The patient had almost no memory of her three stays in the hospital. In fact, she could not remember any confusion state, bizarre behaviour or even how she arrived at the hospital.

It is essential to understand the neuropsychiatric outcome of the disease because, in the case presented, symptoms and side effects became extremely aggressive for the patient. Even though there was slow tapering of corticosteroids after the acute episode, a relapse was reported. Therefore, an absence of a complete triad

at onset should not be a reason to reject the diagnosis. Moreover, typical snowball lesions in the corpus callosum should be considered a main sign for the diagnosis, as it is normally present with the first symptoms of the disease. We suggest that the presence of this kind of lesions (in the absence of acute disseminated encephalomyelitis or multiple sclerosis lesions) could be considered as a diagnostic sign given the two other symptoms of the triad.

According to the proposed criteria for diagnosis by Kleffner *et al*,⁴ initially our patient could only be defined as a *probable Susac syndrome*. Specifically in this case, brain involvement consisted on typical findings on cranial MRI and cognitive impairment, headache and behavioural changes. Vestibulocochlear involvement included mild hearing loss supported by audiogram and peripheral vertigo symptoms. One month later, the triad was complete, with damage shown on spectral domain optical coherence tomography, funduscopy and in the tone audiometry, which eventually defined our case as *definite diagnosis of Susac syndrome*.

The definition of the severity of symptoms is related to the implication on the central nervous system during the initial peak of the disease and course of illness. This case is considered 'severe' according to the definition of Rennebohm *et al*.⁵ The patient presented a moderate encephalopathy and a moderate-severe cognitive and language dysfunction, and the follow-up MRI showed new ischaemic lesions. Moreover, the response to immunosuppressive treatment was initially positive, but it was not followed by a sustained trend of adequate improvement.

The mechanisms involved in the development of the disease are still unclear. However, it is thought to be an autoimmune process, which would explain the good and long-term response to immunosuppressive therapy. Recent findings focus future research on the blood-brain barrier as an important agent in the immune cell penetration and the reactivation of the immune system. The study of disease-specific antigens, T cell involvement, as well as the brain endothelial cell and components of the neurovascular junction in different central nervous system inflammatory diseases would lead to a better understanding of the inflammatory process occurring in Susac syndrome.⁶

According to this evidence, first-line treatments are focused on the immune system: high doses of corticosteroids, IVIG, cyclophosphamide or azathioprine in the acute period, and a slow tapering of corticosteroids as maintenance.² Although target treatment must be considered according to the main organic threat, all cases must be first treated with corticosteroids. If symptoms are not just mild, treatment with IVIG, cyclophosphamide, mycophenolate mofetil or tacrolimus should be considered gradually, according to the severity of symptoms.⁵ In the case presented, our patient was first treated with corticosteroids and recovery was complete, showing no more cognitive impairment. However, relapse occurred after only 3 weeks of complete recovery.

Although the presented case was treated correctly and early on, sometimes this uncommon disease makes diagnosis or treatment difficult to identify. Our team presented a defined Susac syndrome with an unspecific onset but an aggressive outcome. It was necessary to increase the treatment, as it was not enough with the first line used. It was noted through the study that it is important to consider this disease as a possible cause of neuropsychiatric symptoms, as well as the necessity of an aggressive treatment according to its severity. Therefore, misdiagnosis of Susac syndrome will be reduced and prognosis will be better. Further studies are required to get an earlier diagnosis, to optimise treatment options, and to provide both patients and professionals an improved understanding of this rare disease.

Learning points

- ▶ Susac syndrome is a rare disease with a diagnosis that has increased in the past years.
- ▶ The early outcome of this disease is normally unspecific, with a wide range of neuropsychiatric symptoms.
- ▶ Suspicion of Susac syndrome when the classic triad is not complete ensures a faster diagnosis and an earlier treatment.
- ▶ The distinctive snowball lesions in the corpus callosum should be considered as almost pathognomonic, as their presence and typical localisation are normally directly related with Susac syndrome.
- ▶ Immunosuppressive therapy is the least recommended in the guidelines, although further studies are required to decrease the high risk of relapse in these patients.

Contributors MP-L: study concept and design, drafting of the manuscript, data collection and interpretation. IA-P: critical revision of the manuscript, analysis and interpretation of data. BR-B: critical revision and design of the manuscript,

interpretation of data. DG-A: supervisor of the study, collection and interpretation of data, critical revision of the manuscript. All authors provided final approval of the version to be published and are guarantors.

Funding The authors have not declared a specific grant for this research from any funding agency in the public, commercial or not-for-profit sectors.

Competing interests None declared.

Patient consent for publication Obtained.

Provenance and peer review Not commissioned; externally peer reviewed.

REFERENCES

- 1 Greco A, De Virgilio A, Gallo A, *et al.* Susac's syndrome — Pathogenesis, clinical variants and treatment approaches. *Autoimmun Rev* 2014;13:814–21.
- 2 Dörr J, Krautwald S, Wildemann B, *et al.* Characteristics of Susac syndrome: a review of all reported cases. *Nat Rev Neurol* 2013;9:307–16.
- 3 Ben David C, Sharif K, Watad A, *et al.* Susac syndrome: a rare cause of a confusional state. *Isr Med Assoc J* 2017;19:651–3.
- 4 Kleffner I, Dörr J, Ringelstein M, *et al.* Diagnostic criteria for Susac syndrome. *J Neurol Neurosurg Psychiatry* 2016;87:1287–95.
- 5 Rennebohm RM, Asdaghi N, Srivastava S, *et al.* Guidelines for treatment of Susac syndrome – An update. *Int J Stroke* 2018:1–11.
- 6 Lindner M, Klotz L, Wiendl H. Mechanisms underlying lesion development and lesion distribution in CNS autoimmunity. *J Neurochem* 2018;146:122–32.

Copyright 2019 BMJ Publishing Group. All rights reserved. For permission to reuse any of this content visit <https://www.bmj.com/company/products-services/rights-and-licensing/permissions/> BMJ Case Report Fellows may re-use this article for personal use and teaching without any further permission.

Become a Fellow of BMJ Case Reports today and you can:

- ▶ Submit as many cases as you like
- ▶ Enjoy fast sympathetic peer review and rapid publication of accepted articles
- ▶ Access all the published articles
- ▶ Re-use any of the published material for personal use and teaching without further permission

Customer Service

If you have any further queries about your subscription, please contact our customer services team on +44 (0) 207111 1105 or via email at support@bmj.com.

Visit casereports.bmj.com for more articles like this and to become a Fellow