

[CASE REPORT]

A Successful Treatment Strategy for Paradoxical Cerebral Embolism Accompanied by Entrapped Thrombus in Patent Foramen Ovale

Takuto Ishida^{1,2}, Kazuki Miyazaki¹, Hiroshi Shimizu¹, Keita Shibahashi¹, Hidenori Hoda¹,
Ryo Itagaki², Kazuhiro Sugiyama¹, Takahiro Tanabe¹ and Yuichi Hamabe¹

Abstract:

A 73-year-old man was transferred to our hospital with dyspnea and left hemiplegia. The diagnosis of pulmonary embolism, entrapped thrombus in patent foramen ovale (PFO), and internal carotid artery occlusion was made by imaging studies. We decided to perform endovascular treatment without the administration of tissue plasminogen activator (tPA) for cerebral embolism because of concern about further embolism caused by fragmented thrombi. After endovascular treatment, he successfully underwent surgical embolectomy for entrapped thrombus in PFO. Endovascular treatment without tPA administration and subsequent surgical embolectomy seems to be a viable treatment strategy for patients with occlusion of the large cerebral artery accompanied by entrapped thrombus in PFO.

Key words: cerebral embolism, endovascular treatment, impending paradoxical embolism, patent foramen ovale, tissue plasminogen activator

(Intern Med 59: 211-214, 2020)

(DOI: 10.2169/internalmedicine.3642-19)

Introduction

Patent foramen ovale (PFO) is a common congenital cardiac defect that frequently persists into adulthood (1). Pulmonary embolism (PE) induces pulmonary hypertension, which changes the shunt flow via the PFO from left-to-right to right-to-left, thereby increasing the risk of paradoxical embolism (2). Entrapped thrombus in PFO, also called impending paradoxical embolism, is an imminent fatal condition that can result in further embolism. In previous reports, cerebral embolism was described as the most common paradoxical embolism among patients with this condition (3, 4).

However, while thrombolysis with tissue plasminogen activator (tPA) is a standard treatment for cerebral embolism (5), there are concerns that thrombolysis for patients with impending paradoxical embolism may induce further embolism by fragmented thrombi. Endovascular treatment is a viable option for patients who are not eligible for tPA (5),

so this treatment seems to be a reasonable therapeutic option for patients with cerebral embolism accompanied by impending paradoxical embolism. However, to our knowledge, there have been no case reports describing patients with cerebral embolism and impending paradoxical embolism who underwent endovascular treatment.

We herein report a 73-year-old patient with cerebral embolism, PE, and entrapped thrombus in PFO who successfully underwent endovascular treatment without the administration of tPA for cerebral embolism and subsequent surgery for impending paradoxical embolism.

Case Report

A 73-year-old man was transferred to our emergency medical center with dyspnea and left hemiplegia. His medical history was unremarkable other than hypertension. Upon arrival at the hospital, his vital signs were as follows: Glasgow Coma Scale E3V4M6, temperature 36.1°C, pulse rate

¹Tertiary Emergency Medical Center, Tokyo Metropolitan Bokutoh Hospital, Japan and ²Department of Cardiovascular Surgery, Tokyo Metropolitan Bokutoh Hospital, Japan

Received: July 11, 2019; Accepted: July 22, 2019; Advance Publication by J-STAGE: September 3, 2019

Correspondence to Dr. Takuto Ishida, t_ishi_2750@yahoo.co.jp

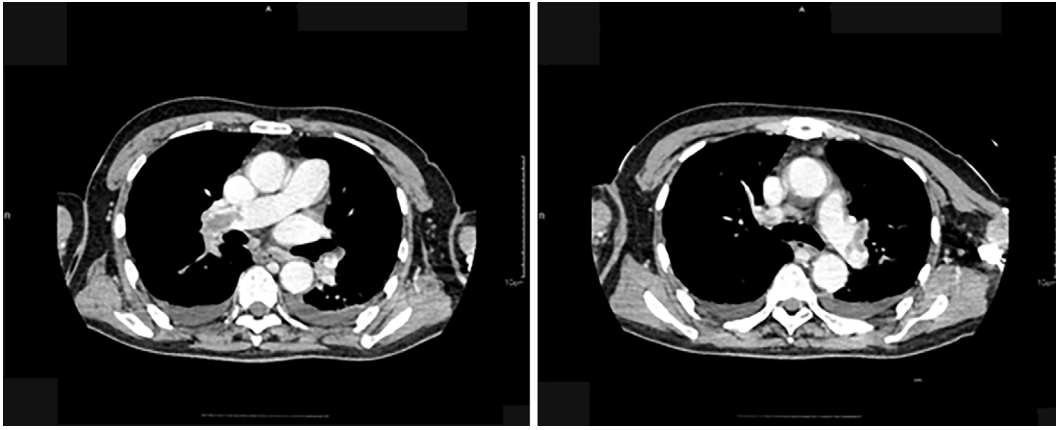


Figure 1. Contrast-enhanced CT showing bilateral pulmonary embolism.

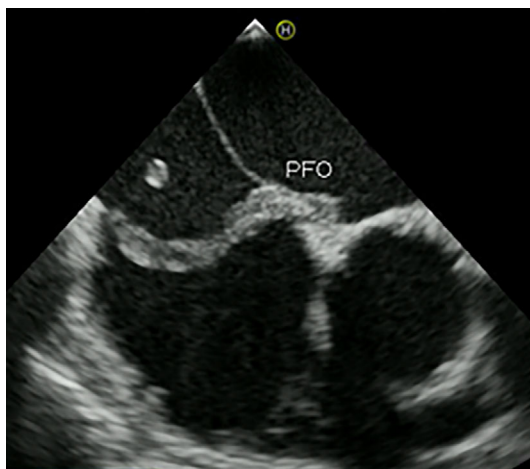


Figure 2. Transesophageal echocardiography showing a mobile thrombus entrapped in PFO. PFO: patent foramen ovale

121 beats/min, blood pressure 130/94 mmHg, respiratory rate 20 breaths/min, and oxygen saturation 98% on O₂ 10 L via mask. His neurologic examination showed left hemiplegia. His National Institutes of Health Stroke Scale (NIHSS) score on arrival was 19 points. The initial laboratory test findings were unremarkable other than an elevated D-dimer level of 28.8 µg/mL, BNP level of 383.4 pg/mL, and troponin I level of 38.1 pg/mL. An electrocardiogram showed T wave inversion in leads V1-3 and atrial fibrillation with rapid ventricular response. Transthoracic echocardiography showed right ventricular dilation and floating objects in both the left and right atria. Computed tomography (CT) of the head did not show any evidence of early infarction. Contrast-enhanced CT showed bilateral PE (Fig. 1), bilateral popliteal vein thrombosis, and splenic infarction.

Given the high clinical suspicion of impending paradoxical embolism, he was intubated and underwent emergency transesophageal echocardiography, which revealed a large entrapped thrombus with mobility in the PFO (Fig. 2). Magnetic resonance angiography (MRA) showed occlusion of the right internal carotid artery (Fig. 3A), while diffusion-weighted magnetic resonance imaging (MRI) findings were

unremarkable other than a high signal intensity at the right basal ganglia and temporal lobe (Fig. 3B).

There were strong concerns that further embolization could be fatal, so we prioritized performing emergency surgery. After careful discussion among a team of an emergency physician, neurosurgeon, cardiac surgeon, and cardiologist, we decided to perform endovascular treatment without the administration of tPA for cerebral embolism because of the strong concerns about inducing further embolism by fragmented thrombi. Mechanical embolectomy was successfully performed using a Solitaire[®] stent retriever (Medtronic Japan, Tokyo, Japan), with a Thrombolysis in Cerebral Infarction score (TICI) of 3 (Fig. 4). The symptom-to-recanalization time was 270 minutes. CT of the head after endovascular treatment was unremarkable other than a localized low-density area in the temporal lobe. After successful endovascular treatment, he underwent surgical treatment consisting of excision of the entrapped embolus, pulmonary embolectomy, and closure of the PFO. A 13-cm fresh thrombus was removed from the PFO (Fig. 5).

Anticoagulation therapy of unfractionated heparin was administered starting on day 2 after surgery. He was able to obey commands on day 2 as well, although his left extremity were paralyzed; follow-up CT of the head on day 3 was unremarkable other than a low-density area at the right basal ganglia and temporal lobe. The diagnosis of antithrombin 3 deficiency was confirmed by a subsequent laboratory examination. He suffered from lung abscess following pulmonary infarction; which required long-term antibiotics treatment. He was transferred to another hospital for further rehabilitation on day 136. His NIHSS score on discharge was 11 points.

Discussion

To our knowledge, this is the first case report of a patient with cerebral embolism accompanied by impending paradoxical embolism who successfully underwent endovascular treatment without the administration of tPA and subsequent surgical embolectomy.

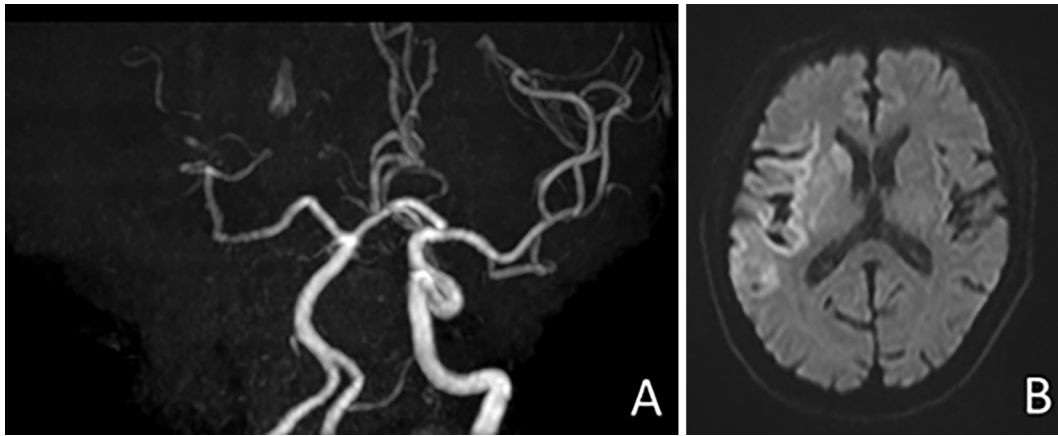


Figure 3. (A) MRA showing occlusion of the right internal carotid artery. (B) Diffusion-weighted MRI showing a high signal intensity at the right basal ganglia and temporal lobe.

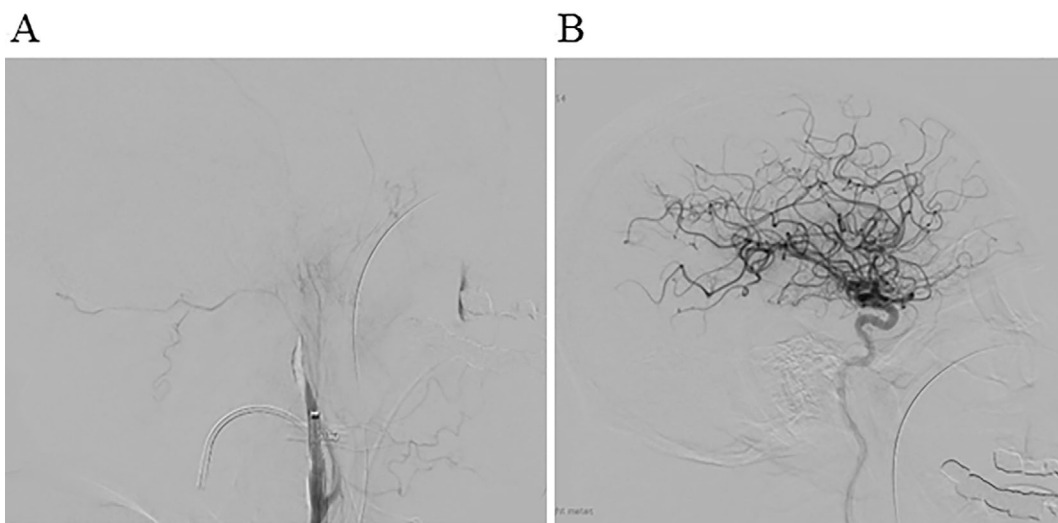


Figure 4. (A) Angiography showing occlusion of the internal carotid artery. (B) Angiography showing Thrombolysis in Cerebral Infarction score 3 characteristics after endovascular treatment.

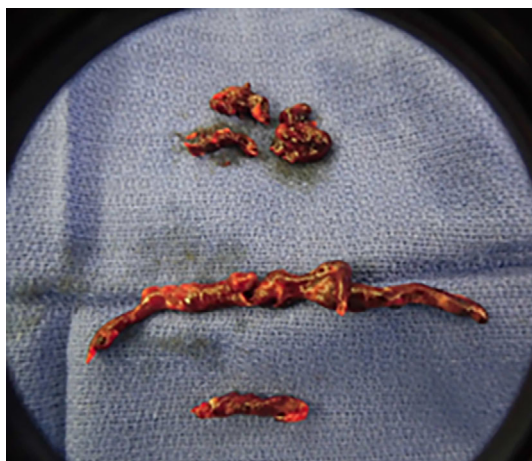

Figure 5. A 13-cm-long thrombus removed from the PFO and thrombi removed from the pulmonary artery. PFO: patent foramen ovale

Recent reports have emphasized the clinical importance of PFO among patients with PE. The prevalence of a PFO among patients with PE is reportedly 30-50%, and the presence of PFO is associated with an increased risk of cerebral embolism and death (6-8). Entrapped thrombus in the PFO, which is direct evidence of paradoxical embolism, can present with various clinical features, from low-risk PE without arterial embolism to cardiac arrest with various arterial embolisms.

There is still no consensus regarding the ideal treatment for impending paradoxical embolism because of the rarity of this entity and its wide variety of clinical features. However, many physicians tend to choose surgery as the first-line treatment, since patients with impending paradoxical embolism who are treated with tPA reportedly have a higher risk of mortality and systemic embolism during treatment than those who undergo surgical embolectomy (4, 9). In fact, the mortality rates of patients administered tPA and those who underwent surgery were reportedly 35.7% and 6.3%, respectively (4).

Among the patients with impending paradoxical embolism, the management for those accompanied by occlusion of large cerebral artery is particularly challenging. Reperfusion therapy for these patients is mandatory since completed large cerebral infarction is generally considered as contraindication to not only open heart surgery but also anticoagulant therapy (5). Although tPA is reportedly more effective for paradoxical embolism than embolism from the left atrium (10), the administration of tPA not only carries a significant risk of further embolism and death (4, 9) but also hampers emergency surgery. Considering both the need for reperfusion therapy and risk of tPA, endovascular treatment without the administration of tPA seems to be a viable treatment strategy for patients with proximal vessel occlusion accompanied by an impending paradoxical embolism. Our patient was able to undergo surgical embolectomy and subsequent anticoagulation therapy without further embolism or hemorrhagic transformation after successful endovascular treatment without the administration of tPA.

In conclusion, among patients with impending paradoxical embolism, the management of those accompanied by the occlusion of a large cerebral artery is especially challenging. Endovascular treatment without the administration of tPA and subsequent surgical embolectomy seems to be a viable treatment strategy for this imminently fatal condition.

Written informed consent was obtained from the patient for publication of this case report and any accompanying images. A copy of the written consent is available for review by the Series Editor of this journal.

The authors state that they have no Conflict of Interest (COI).

References

1. Hagen PT, Scholz DG, Edwards WD. Incidence and size of patent foramen ovale during the first 10 decades of life: an autopsy study of 965 normal hearts. *Mayo Clin Proc* **59**: 17-20, 1984.
2. Windecker S, Stortecky S, Meier B. Paradoxical embolism. *J Am Coll Cardiol* **64**: 403-415, 2014.
3. Iwanaga T, Iguchi Y, Shibazaki K, et al. Paradoxical brain embolism in acute stroke. *J Neuro Sci* **254**: 102-104, 2007.
4. Seo WW, Kim SE, Park MS, et al. Systematic review of treatment for trapped thrombus in patent foramen ovale. *Korean Circ J* **47**: 776-785, 2017.
5. Powers WJ, Rabinstein AA, Ackerson T, et al. 2018 guidelines of patients with acute ischemic stroke: a guideline for healthcare professionals from the American Heart Association/American Stroke Association. *Stroke* **49**: e46-e110, 2018.
6. Konstantinides S, Geibel A, Kasper W, et al. Patent foramen ovale is an important predictor of adverse outcome in patients with major pulmonary embolism. *Circulation* **97**: 1946-1951, 1998.
7. Doen D, Castellani M, Chiche O, et al. Patent foramen ovale and stroke in intermediate-risk pulmonary embolism. *Chest* **146**: 967-973, 2014.
8. Vindis D, Hutrya M, Sanak D, et al. Patent foramen ovale and the risk of cerebral infarcts in acute pulmonary embolism-A prospective observational study. *J Stroke Cerebrovasc Dis* **27**: 357-364, 2018.
9. Meyers PO, Bounameaux H, Panos A, et al. Impending paradoxical embolism. *Chest* **137**: 164-170, 2010.
10. Kimura K, Iguchi Y, Shibazaki K, et al. The presence of a right-to-left shunt is associated with dramatic improvement after thrombolytic therapy in patients with acute ischemic stroke. *Stroke* **40**: 303-305, 2009.

The Internal Medicine is an Open Access journal distributed under the Creative Commons Attribution-NonCommercial-NoDerivatives 4.0 International License. To view the details of this license, please visit (<https://creativecommons.org/licenses/by-nc-nd/4.0/>).