

Charcot and Cholesterin

Olivier Walusinski

Family Physician, Private Practice, Brou, France

Keywords

Atherosclerosis · Cerebral infarction · Cerebrovascular disorder · Charcot · Hemiplegia · History of neurology · Intracerebral hemorrhage · Ischemic stroke · Stroke causes · Stroke mechanism

Abstract

We offer here an observation written in 1866 by Jean-Martin Charcot, accompanied by drawings made during the autopsy of a patient who died of “*cerebral softening*.” Focusing mainly on French medical progress at the time, our survey of the state of knowledge of cerebrovascular pathology indicates that Charcot completely explained the pathophysiology of cerebral infarction, describing the ulceration of an atheromatous plaque at the intima of an artery, on which a clot aggregates, blocks the vessel, or releases embolus downstream, causing cerebral ischemia and parenchymal lesions. Using the term “*cholestérine*” (cholesterin), the name of cholesterol at the time, he identified the biological nature of atheromatous plaques, and made detailed drawings. This observation, included in the famous thesis of Ivan Poumeau, indicates that Charcot did not neglect cerebrovascular pathology, ischemic in this case, but also pathology caused by hemorrhaging, as in the thesis of Charles Bouchard. This interest, which we see clearly during his first decade at Hôpital de la Salpêtrière, gradually turned toward other neurological pathologies that ensured his fame as a founder of neurology more enduringly and overshadowed the conceptual advances he made in the vascular domain.

© 2019 S. Karger AG, Basel

The legitimate and lasting fame achieved by Jean-Martin Charcot (1825–1893) is mainly explained by his contributions to the understanding of nervous system diseases. However, because of his training and his choice to spend his entire career at what was originally a nursing home as well as an asylum, the Hospice de la Vieillesse Femmes de La Salpêtrière, we should also consider him a geriatrician and an internist. His doctoral thesis in medicine on gout and rheumatism gives us further reason to do so [1]. Based on the example of a single observation, recorded in 1866, we hope to show that his clinical perspicacity also helped elucidate pathophysiological and anatomopathological data pertaining to cardiovascular pathology.

Summarized Observation

Marie-Françoise Chifflet, a 95-year-old widow born in Chartres, Bouju by her married name, and a “*day-labourer*,” entered La Salpêtrière at dawn on 10 April 1866 and died that evening: “*On this night of 10 April 1866, we found her on the floor where she had pulled the covers. Her legs were crossed and agitated. Currently, her face and especially her eyes are turned to the right. There is sagging at the left commissure of her lips and slight unilateral puffing of her left cheek on expiration. Stiffness of neck and limbs. She sticks out her tongue on command, which tends slightly toward the left. Speech is slurred. She is still fully conscious. She can use her right arm. Her left arm is strongly half-flexed, with the forearm slightly pro-*

ANNÉE 1866 - N° 608		BULLETIN STATISTIQUE.		MÉDECINE.	
Salle <i>S Paul</i>		N° du Lit: <i>12</i>		Service de M. le Docteur <i>Charcot</i>	
Nom et prénoms du Malade: <i>Chifflet Marie Françoise Genevieve</i>					
Sexe: <i>f</i>	Age: <i>93 ans</i>	Etat civil: <i>V. Douje</i>	Profession: <i>Journaliste</i>		
Lieu de naissance: <i>Chambres Eure-St. Loir</i>		Domicile: <i>admis</i>		Arrond: <i></i>	
Date de l'Entrée: <i>10 avril 66</i>		Date de la Sortie: <i>10 Avril 66</i>		Date du Décès: <i>9 heures du soir</i>	
VACCINÉ.		REVACCINÉ.		NON VACCINÉ.	
		AVEC succès.		SANS succès.	
VARIOLÉ.					
Diagnostic.	Nom de la Maladie.....				
	Aiguë.....				
	Chronique.....				
	Siège.....				
	Variétés.....				
Date du début de la Maladie.....		<i>Est sujette aux étourdissements, était en chirurgie 24 à 19 jours</i>			
Période ou degré au moment de l'entrée.....					
Maladies intercurrentes.....		<i>marchait, n'était pas paralysée n'avait pas de déformation osseuse. Parfait bien.</i>			
Complications.....					
État à la sortie.	Guérison.....				
	Amélioration.....				
	État stationnaire.....				
	Aggravation.....				
MORT.	De la Maladie constatée à l'entrée.....				
	De la Complication.....				
Autopsie cadavérique faite ou non faite.....		<i>La communication l'artère gauche est affaiblie, ferme un peu.</i>			
Observations particulières.	<i>La tige de la cote gauche. Raideur. Du cou et des membres.</i>				
	<i>La langue est tirée quand on la commande elle se dirige un peu à gauche, la parole est aisée, elle se cache sa connaissance.</i>				

Fig. 1. Observation of Marie-Françoise Chifflet (Bibliothèque Charcot ICM La Salpêtrière).

nated, the hand slightly flexed, the fingers extended, and the thumb held to the palm. Both hands are purplish. Her left hand is algid; the right hand is less cold. She does not move her left leg. She can feel on the right, cries out if pinched, and moves her right limbs. On the left, she seems to feel a little, but does not cry out and does not try to protect herself with her right limbs. She also does not move her left limbs. Her lower left limb is rigidly extended in the hip and knee. Her foot is not rigid. The reflex movements of her left leg are preserved. Pinching her left arm slightly exaggerates its contraction. Chatters continuously. Temperature 37 2/5, rigid artery, weak pulse. Weak but normal heart sounds. Equal pupils. Ossified ventral aorta. Bloodletting from the right temporal artery. The clot examined does not have granular bodies.

Died on 10 April 1866 at 8:30 pm. At 10 pm the limbs on both sides were flaccid, no rigor mortis. The parts contracted in the morning were relaxed. The left lower limb (paralysed) was significantly warmer than the right" (Fig. 1).

The autopsy was performed on 12 April 1866: Small fatty heart, no valvular lesion. Thoracic aorta: atheromatous gruel in the vessel. Abdominal aorta filled with atheromatous gruel; it was literally above the bifurcation. The aorta could be felt as a hard cord through the abdominal wall. The femoral arteries, enveloped in bony rings from 1 point to another [...]. In the brachiocephalic trunk, a puriform cyst released its content in the vessel after cutting and decreased significantly in diameter. The common carotid artery had no lesions. At the division of this artery, very pronounced atheromatous damage with formation of a thick plaque, containing soft atheromatous material, salient on the inside or at least a rough membrane. This plaque was ulcerated in the internal carotid at its origin and the ulceration was covered by a discoloured, grainy clot that almost completely blocked the artery.

The common carotid artery on the opposite (left) side also presented a thick atheromatous plaque at the bifurcation, but there was no ulceration or clot. There was only narrowing at the origin of the internal carotid. The arteries of the brain were highly atheromatous. On the right, at the points most narrowed by the atheroma, they presented little discoloured clots that were not, or only slightly adherent and that were particularly prevalent in the divisions of the middle cerebral artery. These arteries were completely blocked by clots and were filled with recently coagulated blood downstream. Nothing similar on the opposite side [...]. At these points, which were very limited, the surface of the gyrus was slightly yellow. On some, there were even small yellow vessels that spread through the tissue of the gyrus. Under the microscope, these vessels were capillaries of which the walls and muscular envelope appeared only slightly damaged, but they were surrounded by a thick layer of fatty granulations. All around these capillaries, the tissue of the gyrus contained numerous fatty granulations and grainy bodies.

Independently of these small points of old softening, certain gyri of the right hemisphere were purplish at the surface only, without diffuence of the tissue, without adherence to the dura mater, and with a few small disseminated points of capillary apoplexy. Under the microscope, the vessels were full of blood. Some appeared slightly atheromatous. The tissue presented some fatty molecular granulations that collected in clumps, espe-

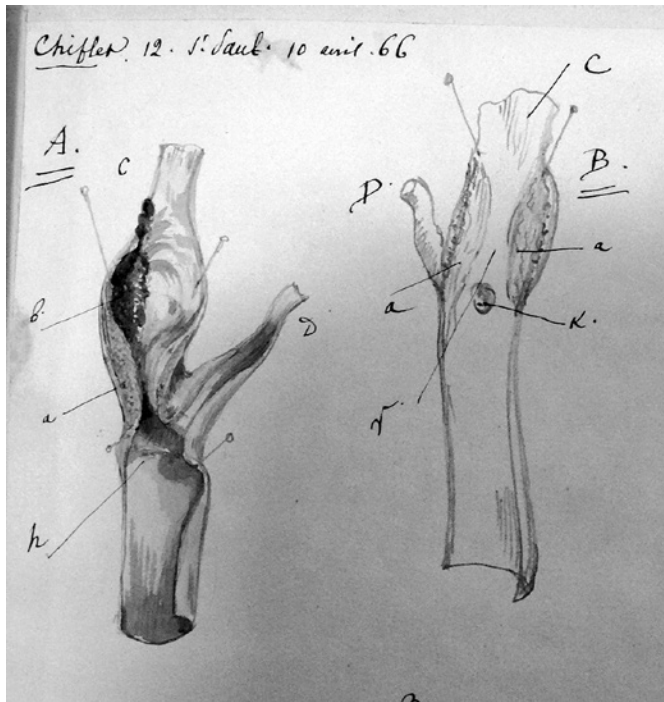


Fig. 2. Drawing A by Charcot, adherent clot on the atheromatous plaque of the right carotid artery. (Bibliothèque Charcot ICM La Salpêtrière).

cially around myelocytes, which were normal. These clumps resembled granular bodies surrounded on one side by a myelocyte. The nerve cells were very granular. Under the centre of the thalamus was a small, pea-sized volume of capillary apoplexy, with slight diffluence of the tissue (pinkish-white softening). Under the microscope, numerous extravasations of blood, dissecting aneurisms in capillaries, slight atheromatous appearance of a few vessels, sparse fatty molecular granulations, and a small number of clumps resembling little granular bodies. No haemorrhaging in the ventricles or softening at their surface [...].

Conclusion: In this case, we were unable to understand the cause of the contraction, but for the softening, there were 3 causes.

- (1) brachiocephalic artery cyst
- (2) narrowing of the internal carotid
- (3) atheroma in the cerebral arteries

“The softening over the gyri and in the thalamus, toward the gyri in places, was pale yellow and old. These atheromatous granular bodies were found in the blood of the femoral arteries. In the cerebral artery clot, treated with acetic acid, there were cholesterin crystals” (Fig. 2, 3).

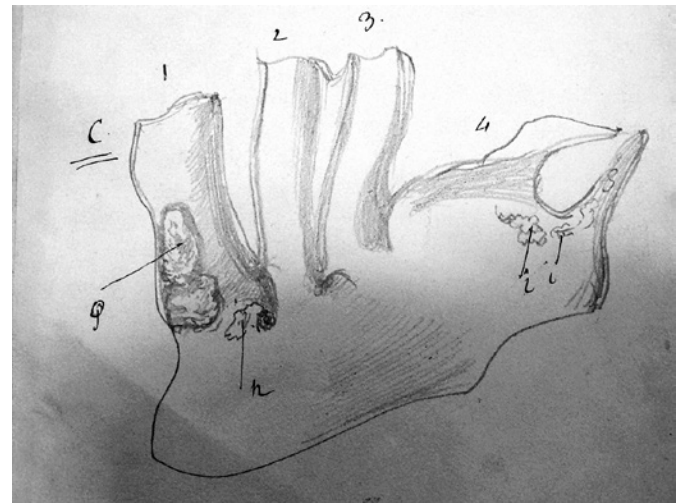


Fig. 3. Aortic arch, brachiocephalic vein, carotid artery, and subclavian vein. Two fibrinous cysts that significantly narrowed the diameter of the brachiocephalic vein; atheromatous-calcareous plaques. (Bibliothèque Charcot ICM La Salpêtrière).

What Is Cholesterin?

Charcot accurately described and drew bilateral atheromatous plaques, indicating ulceration in the right plaque, where there was adhesion of a clot: “This plaque was ulcerated in the internal carotid at its origin and the ulceration was covered by a discoloured, grainy clot that nearly completely blocked the artery.” He did not neglect to specify the location at the bifurcation of the common carotid artery into the internal and external carotids. Was this the only cause of the infarction, or did this thrombus detach and travel toward the middle cerebral artery, as this comment suggests: “These clots were particularly prevalent in the divisions of the middle cerebral artery. These arteries were completely blocked by clots.” The internal carotid artery was not totally occluded; it was “almost completely blocked.” Charcot did not discuss embolism’s role in the accident, though he was thoroughly familiar with this mechanism. Was this omission due to the fact that embolism from artery to artery was still unknown and for him, emboli only traveled from a cardiac chamber to a cerebral artery? In his conclusion, he analyzed the chemical nature of the embolized clot and identified it as “cholestérine” (cholesterin). What was he referring to?

François-Paul Poulletier de la Salle (1719–1788) [2], a forgotten pioneer of animal chemistry in Lyon, showed in 1758 that bile in cattle is an “alkaline saline” substance similar to soap [3]. Pierre-Joseph Macquer (1718–1784) presented these results in his *Dictionnaire de Chimie* in

1778 in the article on “animal gall” [4]: “These (gall) stones contain enough oil to be flammable; but in humans they also contain a singular substance [...]. This substance is a kind of salt discovered by the learned author of the French version of the London Pharmacopoeia [5] (Poullietier de la Salle). The spirit of wine is the specific dissolvent of this saline material. The author I have cited dissolved human gall stones in the spirit of wine, first noticing that this dissolvent became slightly coloured. After a while, he saw that it was filled with fine, very shiny particles moving throughout the liquor. This material was collected and underwent various tests, which determined it to be an oily salt that resembled what is known as “flowers of Benjoin,” not by its odour, but by several other properties.” Later on, Félix Vicq d’Azyr (1748–1794) [6] and Antoine-François de Fourcroy (1755–1809) [7] gave Poullietier de la Salle credit for his discovery in their teaching, calling it “adipocire,” because this term can refer to spermaceti which the substance resembled. In fact, Poullietier de la Salle’s knowledge of this substance was incomplete and uncertain. It was Macquer, then the pharmacist Louis Cadet de Gassicourt (1731–1799) in 1767, who came close to the physicochemical properties of cholesterol, based on gall stones, and compared them with the properties of boric acid (sedative salt) and benzoic acid (“sel de Benjoin”). But the real demonstration that animal fat is composed of specific fatty acids was the work of Eugène Chevreul (1786–1889). He called them margaric, stearic, oleic, and butyric acids, terms still in use today, then demonstrated that they combine with a component he named anhydrous glycerine. This organic chemistry pioneer abandoned the inaccurate term of “adipocire” and coined, in 1816, the word “cholestérine” (from the ancient Greek for “bile” and “solid”), showing that this animal fat, present in gall stones, is composed of glycerol esters [8, 9]. Jean-Louis Lassaigne (1800–1859), a student of Louis-Nicolas Vauquelin (1763–1829), seems to have been the forerunner of a large cohort of discoverers of cholesterol in various organs of the body. Lassaigne isolated it in the brain of a horse [10]. Jean-Pierre Couerbe (1807–1867) considered cholesterol one of the physiological substances of the brain in 1834 [11]. In 1833, Henri-Félix Boudet (1806–1878) showed the presence of cholesterol in the serum of circulating blood [12]. In 1844, Alfred Becquerel (1814–1866) and Alexandre Rodier (1812–?) established the quantitative values in humans [13]. Marcellin Berthelot (1827–1907) renamed “cholestérine” as “cholestérol” in 1860 to indicate that the molecule functions as an alcohol [14]. This is why Charcot used “cholestérine,” at that time the most common term [15].

The Concept of Arterial Atheromas Appeared in the 19th Century

Jean-Frédéric Lobstein (1777–1835), who held the first Chair of Pathological Anatomy in the world, created in Strasbourg in 1819, used the word “artériosclérose” in 1829 to refer to the hardening of the arterial wall [16]. In 1841, the German Julius Vogel (1814–1880) identified the presence of cholesterol in an arterial atheromatous plaque. His colleague, Hermann Lebert (1813–1878), ensured the dissemination of this finding in his book *Physiologie pathologique* published in Paris in 1845: “These ‘bony’ plaques, which are rarely found in the substance of the heart but often in the arteries, almost always contain cholesterol crystals” [17]. He added in the 1857 edition: “An atheroma is a form of damage specifically related to nutrition [...]. It is favoured by the specific properties of arterial blood and can be combined with direct deposits from the blood, when there is an interruption or irregularity in the cretaceous or osteoid plaques which result from the atheroma.” Around the same time, Rudolf Virchow (1821–1902), writing for anatomopathologists, presented the physicochemical characteristics of cholesterol, and the necessary technical means for identifying it in tissues observed microscopically [18]. In 1858, the following year, he proposed a pathophysiology in which the atheroma is a localized, fatty degeneration; that is, a deposit of cholesterol, secondary to an inflammation of the wall. He hypothesized a hemodynamic cause: localized blood stasis [19].

It is very likely that Charcot was aware of this recent work when he drew the carotid atheromatous plaque of Madame Bouju-Chifflet. However, the *American Journal of Medical Sciences* was not part of Charcot’s library, today held by La Salpêtrière, and it is thus uncertain whether Charcot knew of the discoveries of Austin Flint, Jr. (1836–1915) in New York, in 1862, on the physiology and metabolism of cholesterol [20]. Paul Le Gendre (1854–1936) mentioned them in the famous Charcot-Bouchard-Brissaud *Traité de Médecine*, published much later, in 1891: “A. Flint, showing that the blood in cerebral veins contains more cholesterol than in the arteries, proved that this body is a waste product of the nervous tissues.”

Charcot and Vascular Pathology

Several influences led Charcot to take an interest in vascular pathology. During his residency under Eugène Edmé Cazalis (1808–1882) at La Salpêtrière in 1852, he

observed frequent cases of chronic gangrene in the lower limbs [21]. He was also struck by the number of patients at La Salpêtrière suffering from hemiplegia [22]. Learning of the work published in 1847 by Virchow on thromboembolism [23], he was able to validate it through his own clinical and anatomopathological observations [24]. A century earlier, in 1744, Gerard van Swieten (1700–1772), the founder of the Viennese School of Medicine, may have foreseen the cardioembolic mechanism in comments he made on the work of Hermann Boerhaave (1668–1738): “it has been established by many observations that the polyps occasionally attach themselves as excrescences to the *columnae carnea* of the heart, and perhaps the separate from it and are propelled, along with the blood, into pulmonary artery or aorta, and its branches were they thrown into carotid or vertebral arteries, could disturb, or if they completely blocked all approach of arterial blood to the brain, utterly abolish the functions of the brain” [25]. Charlemagne-Joseph Legroux (1798–1861) explicitly formulated the embolic theory in his 1827 thesis, presided over by the surgeon Guillaume Dupuytren (1777–1835) [26], but he did not achieve the same posthumous fame as Virchow for this pathophysiological demonstration.

Premises

Following a presentation to the Société de Biologie (Paris Society of Biology) in 1859, Charcot published, first in a journal of veterinary medicine, the observation that was the basis for his description of arterial claudication: “This presentation should be taken in relation to cases of intermittent claudication due to arterial occlusion, well known today in horse pathology. A. Goubaux and H. Bouley, who have done important work on this subject, have brought such cases to the attention of the Society on several occasions” [27] (Fig. 4). Armand Goubaux [28] (1820–1890), who became Director of the Maisons-Alfort national veterinary school, described “paralysis in the horse caused by occlusion of the posterior aorta” in 1846. Henri Bouley the Younger (1814–1885) was the first to draw attention to this form of claudication in the horse in 1830 [29]. After the clinical description of claudication in a patient during physical exertion, occurring almost 3 decades after a war injury, Charcot discovered a bullet during autopsy that was blocking the common iliac artery, reproducing in a nearly experimental way what veterinarians had observed in the horse. On the pathophysiological mechanism of ischemia, a word that Charcot did not use,

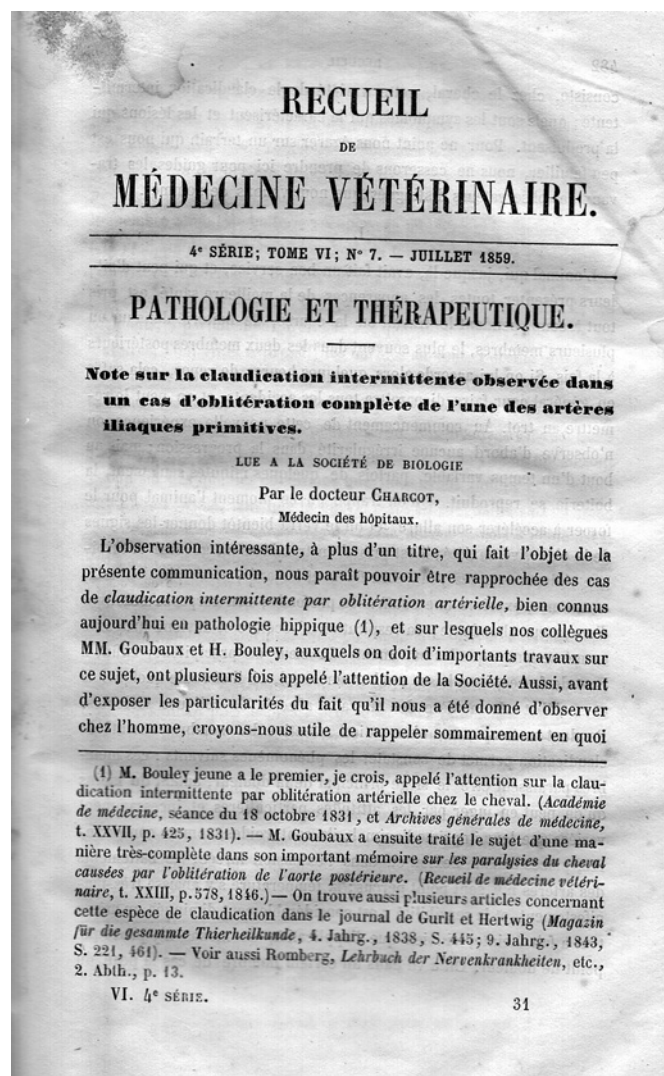


Fig. 4. Charcot’s seminal publication in *Recueil de Médecine vétérinaire*, 1859 (Collection OW).

he wrote: “We see how physiology may give us, to a certain extent, the key to the main phenomena observed during claudication.” Knowing that arterial narrowing caused temporary or permanent ischemia, he was able to broaden this explanation to various arterial territories and relate narrowing of the arterial lumen to atheromas.

When Charcot made his presentation to the Société de Biologie in 1859, he was still only a Central Office physician, not yet assigned to a specific hospital department and virtually unknown. Seven years later, during his first lesson on geriatric diseases, entitled “*Caractères généraux de la pathologie sénile*” (General characteristics of senile pathology, first published as a booklet in 1866, then as a bound book in 1867), he presented the clinical picture for

atheromas: “From the perspective of histological development, arterial atheromas tend to be significantly distinct from the usual forms of senile atrophy, which appear to result from a purely passive process. On the contrary, an arterial atheroma appears, in the first phase of its progression, to involve more or less active proliferation of the normal internal membrane components of the arteries. At some point, fatty degeneration occurs in these newly formed components, but this is a consecutive phenomenon. The resulting granulations accumulate in the deepest parts of the internal membrane, which begin to deteriorate. They then distend the most superficial layer, which remains intact for a long time. This is how these collections of fat and cholesterol crystals form. We refer to them as atheromatous abscesses. They sometimes open in the arterial cavity where they occupy the walls; and their content, mixed with blood, can be carried by the circulatory flow, penetrate small-diameter vessels, and produce often terrible cases of capillary embolism. To a less advanced degree, the atheromatous tumour only causes narrowing and later complete occlusion of the artery where it is found. This results in damage through lack of nutrition, at various points of the organism, which constitutes one of the most original chapters of geriatric pathology. We shall see that cases of cerebral softening and capillary apoplexy in the brain observed at an advanced age must be attributed to atheromatous occlusion of the arteries” [30]. This presentation is perfectly accurate and summarizes the findings mentioned above.

State of Knowledge in 1866

To determine the state of knowledge when Charcot treated Marie-Françoise Bouju-Chifflet and prepared his observation, below is a survey of some of the research by his contemporaries citing his publications on cerebrovascular pathology. We will start by recalling that François Bayle [31] (1622–1709) was the first to describe calcifications and plaques in cerebral arteries and proposed his explanation of apoplexy in his *Tractatus de apoplexia*, published in 1677. At the time, the word apoplexy is used mainly to describe cerebral hemorrhages. We should also note that Eugène Bouchut [32] (1818–1891), in his 1850 dissertation to enter the medical society of the Paris hospitals, described lesions in a carotid atheroma and deduced it was the cause of cerebral softening: “*The deposits of solid material that partially harden the walls of cerebral arteries in elderly patients cause the intima to rise, sometimes tearing it, and significantly narrow the diameter of*

these vessels [...]. The fibrinous clots enclosed within these small arteries always seem recent; that is, soft, easy to break, and mixed with a significant quantity of coloured material. They are always smaller than the diameter of their enveloping vessel, and I found them floating in the arteries at the base of the brain”. Already in 1841, Bouchut [33] had written a dissertation on angina pectoris in which he developed the argument that ischemia was caused by coronary narrowing.

Étienne Lancereaux [34] (1829–1910), another former resident of Cazalis, defended his thesis on 7 March 1862, entitled *De la thrombose et de l'embolie cérébrales considérées principalement dans leurs rapports avec le ramollissement du cerveau* (Cerebral thrombosis and embolism considered mainly in relation to cerebral softening), with Augustin Grisolle (1811–1869) presiding over the jury. As an example of embolism, he referred to a presentation made by Charcot, when he was a resident, to the Société de Biologie in 1850, in which he described the case of a young man who had died of cerebral softening accompanied by infarction of the kidneys, spleen, and intestines, a complication of rheumatic endocarditis [35]. The notion of embolism, especially multiple emboli, was unknown in France at this time. Charcot's clinical and pathophysiological descriptions were pioneering. Syphilis and rheumatic fever were the two most frequent causes identified for cerebral infarction. Lancereaux contested Charcot's opinion echoing that of Karl von Rokitansky (1804–1878) that excess blood coagulability favored cerebral infarction and added this curious remark: “*Dr. Charcot, who, in the interesting facts we have cited, tended to admit the possibility of this sort of deterioration in arterial blood, is now ready to abandon this interpretation.*”

In a presentation to the medical society of the Paris hospitals 3 years later, on 22 March 1865, Charcot contradicted Lancereaux: “*Contrary to this view (that of Lancereaux), Mr. Charcot established that, in subjects with old cases of cancer, arterial thrombosis without prior deterioration of the vessel wall can occur as well as venous thrombosis, even though the latter is infinitely more frequent*” [36, 37]. In any case, Lancereaux's conclusions do not lend themselves to interpretation: “*Cerebral thrombosis and embolism are the 2 major modes of occlusion of cerebral vessels.*” But he was more interested in brain lesions following thrombosis than in atheromatous lesions in arteries, which he did not describe in his thesis. As Léon Rostan (1790–1866) [38, 39] had been the first to do before him, and with determination, Lancereaux set out to contest the inflammatory nature of cerebral lesions secondary to thrombosis, a theory of François Broussais

(1772–1838) that was defended in 1825 by Jean-Baptiste Bouillaud (1796–1881) [40], in 1839 by Maxime Durand-Fardel (1815–1899) [41], and in 1859 by Louis-Florentin Calmeil (1798–1895) [42], among others.

An Experimental Pathophysiology

In December 1865, Jean-Louis Prévost (1838–1927), then a resident of Alfred Vulpian (1826–1887), and Jules Cotard (1840–1889), then Charcot's fourth resident, read a dissertation at the Société de Biologie relating the results of their unprecedented and original experiments in Vulpian's laboratory, to relate the chronology of changes in the lesions and thereby demonstrate the validity of arterial occlusion and its consequences on brain tissue. They used rabbits for their experiments on the effect of carotid ligation and injection of fine powder (clubmoss spores) or coarser substances (tobacco seeds). They established that paralysis differed according to the severity of the occlusion and whether it was proximal or peripheral. Tobacco seeds obstructed the middle cerebral artery and caused a nonhemorrhagic pinkish softening, comparable to the softening found during the autopsies of their patients. The lesions first showed "anemic" signs, then later hemorrhagic infiltrations. With the help of manometers and rubber tubes, Cotard demonstrated that blood pressure was highest at the blockage, generating "a collateral congestion in the small branches that formed around the occlusion" immediately after the blockage, but that it decreased when the collateral branches dilated in compensation. Later an inflammation started around the necrosed regions, explaining the inflammation theories of Cotard's predecessors at the beginning of the 19th century [43]. These experiments with animal models indicate Vulpian's involvement, who was trained by his teacher at the Paris Museum of Natural History, Pierre Flourens (1794–1867) [44], and by his benefactor and friend Jean-Marie Philippeaux (1809–1892). Charcot, a lover of animals, could not have conducted these experiments.

Inflammation or Ischemia: The Central Etiopathogenic Debate Around Apoplexy

Jean-Baptiste Vincent Laborde (1830–1903), another resident of Cazalis [45, 46], dedicated his 1866 book on cerebral softening to his teacher Rostan [38]. In it, he used microscopic examinations to demonstrate the absence of inflammation in brain tissue after spontaneous softening.

He concluded: *The deterioration we have described in detail mainly consists in the presence and accumulation of morbid elements characterising fatty degeneration, or to express it more generally, the atheromatous degeneration of the vascular wall [...]. It is almost a commonplace of geriatric pathology that the arteries in older people have a remarkable tendency to undergo certain structural modifications that, for a long time, were referred to by the inaccurate term of 'ossification' which should now be replaced by 'calcareous incrustation'.* He attributes the origin of softening 'to the partial and more or less complete obstruction of the vascular lumen', but does not clearly describe ulceration of the atheromatous plaque as the place of formation of a clot: 'a more or less condensed deposit of amorphous molecular elements and transparent adipose globules on the internal wall'. Microscopy techniques and the time before observation after death may explain why Laborde's research remained inconclusive.

Also in 1866, Adrien Proust [47] (1834–1903) wrote an *agrégation* thesis of which the first chapter gave an excellent historical overview of the concepts developed since the beginning of the century on cerebral softening. He then leveraged the very recent work of Prévost and Cotard and analyzed "all the observations of softening over the past 4 years in the departments of Mr. Charcot and Mr. Vulpian at La Salpêtrière." Proust discussed at length the pathological histology of the infarcted brain tissue, summarizing as follows: "We conclude by stating that the atheromas and vascular occlusions that cause cerebral softening firstly produce phenomena of stasis and hyperhaemia in the capillary network, and more rarely anaemia." He recalled the 1850 article of Charles Delacour [48] (1826–1902), which reported an observation of hemiplegia where the anatomical examination showed "ossification of cerebral capillaries in the striatum" and the absence of cerebral hemorrhaging, but ossification of the basilar artery. Proust distinguished cardioembolic infarctions by listing all of the lesional causes: "The arteries have become rigid, twisted tubes with thick walls; their diameter is irregular, and they are rough, shrunken, and almost blocked at certain points. This deterioration by itself is enough in some cases to produce cerebral softening, but most often thrombosis is also involved. Atheromatous deterioration of cerebral arteries is the most frequent cause of local coagulations." Proust only evoked the cause of atheromas tautologically, as the result of ageing; he considered embolic causes the most frequent.

Charcot was the associate professor in the thesis jury of his student Ivan Poumeau [49] on August 30, 1866. The main objective of this thesis, suggested by Charcot, was to confirm that cerebral softening had a vascular rather than

an inflammatory cause. In it, Poumeau copied the observation of Marie-Françoise Chifflet, faithfully detailing the clinical progression and the anatomopathological examination conducted by Charcot. He focused on explaining the condition of brain parenchyma. At the end, he briefly presented the pathophysiological interpretation: *The common carotid artery had no lesions; when it was divided, a thick plaque was found, salient internally and containing soft atheromatous material. This plaque was slightly ulcerated at the origin of the internal carotid and the ulceration was covered by a discoloured, grainy clot that almost completely blocked the artery [...]. These clots were particularly prevalent in the divisions of the middle cerebral artery, which were completely occluded by these clots; downstream of these clots, they were filled with recently coagulated blood. Treated with acetic acid, these clots were found to contain large quantities of cholesterin crystals.* Poumeau faithfully copied the observation of his teacher. This cholesterin-containing clot seems to correspond to artery-to-artery embolism, though neither Poumeau nor Charcot explicitly designate it as such (Fig. 2).

Karol (Charles) Benni (1843–1916), a Polish socialist refugee and future otolaryngologist in Warsaw [50], defended his thesis on July 17, 1867: *Recherches sur quelques points de la gangrène spontanée* (Research on spontaneous gangrene). Vulpian presided over the jury [51]. Benni compiled his observations in Charcot's department with the resident Charles Bouchard (1837–1915) in 1866. He clearly concluded: *What has up till this time been called spontaneous gangrene is, in most cases, the direct result of arterial occlusion.* The blocking clot was either caused by embolism or secondary to local thrombosis. *Inopexia, mainly characterised by increased coagulability of the blood, depends in many cases on an absolutely or relatively higher proportion of fibrin.* Benni attributed this *“inopexia”* to cachexia in cancer patients or phthisics, among others. He did not neglect to mention complications from diabetes and *“cases of endarteritis.”* This thesis demonstrates that the pathophysiological concepts of arterial ischemia, first presented by Charcot in 1859, were entirely accepted by 1866.

Pierre-Henri Soulier [52] (1834–1921), Charcot's first resident in 1862, affirmed in 1867 that *“cerebral softening is associated with occlusion of a healthy or atheromatous artery by a local clot (thrombosis) or by a travelling organic product (embolus)”* and that *“spontaneous cerebral softening is not inflammatory.”* As a sort of post-doctoral project, he proposed a clarification of the terms *“apoplexy”* (during the second half of the 19th, apoplexy means what we call, currently, a stroke), *“cerebral conges-*

tion,” “cerebral anaemia,” “état criblé” (“cribiform state” or “pisiform lacunes”) and helped differentiate cerebral softening from general paralysis (paralytic dementia). For Poirier and Drouesné, *“the term lacunae was first used by Dechambre (1838) referring to small cavities developed during the process of resorption within cerebral softening.* Some years later, lacunae was applied by Durand-Fardel (1843) to small cavities located in the basal ganglia and hypothetically attributed to old, healed cerebral softening. Durand-Fardel (1842, 1854) described *“l'état criblé”* as many round small holes (*“criblures”*) always containing a patient blood vessel and located in the hemispheric white matter” [53].

Charles Bricquebec (1842–?), a student of Charles Lasègue (1816–1883), defended his thesis on February 28, 1868, with Vulpian presiding over the jury and Charcot as associate professor. Based on 13 observations mainly provided by Bouchard, he discussed clinical and prognostic aspects (and acknowledged Charcot's work): paralyzed limbs are warmer than on the healthy side due to *“vasomotricity nerve paralysis”*; rapid increase in core temperature and appearance in <48 h of a pressure ulcer on the paralyzed side were sufficient to predict rapid death; and conjugate eye deviation to the side opposite to the paralysis, demonstrated by Prévost in his thesis defended one month earlier, was confirmed in each of his observations. According to Bricquebec, Charcot encouraged bloodletting in hemiplegics and observed that venous blood from the two sides of the body was of a different color. This clinical thesis only touched briefly on pathogenesis by indicating, in a few cases, sylvian thrombosis and the atheromatous condition of the arteries.

On August 10, 1868, Vulpian presided over the jury for the thesis of Achille Vauttier [54] (1844–1891) who thanked Charcot for having provided the necessary observations. He discussed what he called *“latent cerebral softening”*: *“There are cases where softening develops in a hidden or latent way, as this is the meaning appropriate to this form of disease.”* He described regressive accidents *“that result in irregular gait”* marked by global motor slowing, without patent hemiplegia: *“Simple slowing is the only movement disturbance”*; it was accompanied by variable *“intellectual disturbance”* and *“excessive stiffness.”* In conclusion, he proposed qualifying this softening *“with the epithet “insidious”* rather than latent. It seemed to him that the lesions were *“limited to the cortical layer and did not invade the white medullary masses of the hemispheres.”* Charcot thus also identified the clinical picture of the lacunar state, but without describing, at that time, specific pathological anatomy [53].

Discussion

When Charcot was a resident, the discussion that had started at the beginning of the 19th century between the advocates of the inflammatory theory of apoplexy and the vascular theory was nearly dead. For him, there was no doubt that the origin of the cerebral lesion was “*nutritive*”; that is, ischemic. The process is common to all localizations of arterial pathology, whether it develops in the arteries of the limbs or in the cerebral arteries. Charcot’s observation of claudication in a lower limb bears this out. Charcot also recognized the validity of the theory of embolism proposed by Virchow [55, 56], knowing that the examples at that time were almost exclusively cases of rheumatic endocarditis and syphilitic arteritis, and less frequently artery-to-artery embolism. He concluded by citing the chemical nature of clots: “*In the cerebral artery clot, treated by acetic acid, there are cholesterol crystals.*” A fatty embolus is rare; the vast majority of emboli are cruric in nature.

Cerebral hemorrhage had been recognized since the work of Johann Jakob Wepfer (1620–1695) in 1658 as a cause of apoplexy, which Jean-André Rochoux [57] (1787–1852) confirmed in his 1812 thesis: “*Apoplexy is internal hemorrhaging*”. Charcot and Bouchard provided a related etiopathogenic explanation in Bouchard’s 1866 thesis that attributed hemorrhage in older patients to “*miliary aneurism*” [58], with rupture resulting from “*exaggerated blood pressure in the vessels of the brain,*” which in turn results from “*preliminary vascular deterioration, always identical, and sclerosis in small arteries with atrophy of the tunica media and secondary production of aneurisms, the rupture of which is the direct cause of haemorrhage.*”

Parallel to supervising Bouchard’s research, Charcot explored cerebral ischemia secondary to an atheroma, which some 200 years earlier, in 1677, Bayle had proposed as the cause of apoplexy. The observation of Marie-Françoise Bouju-Chifflet shows Charcot’s perfect elucidation of this form of cerebral softening. At an arterial bifurcation (generating a predisposing hemodynamic modification), the accumulation of cholesterol in the tunica media of the arterial wall narrows the lumen of the vessel. This state can lead to rupture of the intima, releasing fatty emboli in rare cases and causing the formation of an occlusive clot at this point of arterial ulceration, which can in turn cause cerebral infarction or incomplete blockage with multiple emboli downstream. Charcot’s text, together with his drawings, covers all of these elements with perspicacity, even though the intimate mechanisms of thrombosis were unknown to him.

During this period, from 1862 to 1868, a time of intense and varied research for Charcot, he thus did not neglect cerebrovascular pathology. He clearly distinguished between cerebral softening that was ischemic in origin and cerebral hemorrhage. The observation of Marie-Françoise Bouju-Chifflet demonstrates the advances Charcot made in cerebral ischemic pathology. Although Poumeau’s thesis is recognized to be of historic interest, the theses Charcot helped write during this period, and presented here, lack the quality and relevance of those he oversaw once he was appointed to the Chair of the Clinic of Nervous System Diseases. The Master was himself still learning in 1866!

Charcot-Bouchard aneurisms are rare, but the corresponding description is most often considered as Charcot’s only publication concerning vascular neurology. According to Bogousslavsky and Paciaroni [59] and Goetz et al. [60], only 9 articles of the 462 publications by Charcot deal with neurovascular pathology. The observations compiled in his department and preserved in the archives of the Charcot library at La Salpêtrière, clearly indicate that he and his residents handled and studied numerous cases like that of Bouju-Chifflet.

Acknowledgments

We are grateful to Marie-Germaine Bousser, Martin Catala, Hubert Déchy, Jacques Poirier, and the reviewers for their careful readings and helpful suggestions. We would also like to thank the librarians at the Charcot library for providing Charcot’s observation: Chantal Lantin, Florian Horrein, and Véronique Leroux-Hugon.

Disclosure Statement

The author has no conflict or interests.

Funding Sources

The author is not having any financial interest.

References

- 1 Charcot JM. Études pour servir à l’histoire de l’affection décrite sous les noms de goutte athénique primitive, nodosités des jointures, rhumatisme articulaire chronique. Thèse Paris n°44: Rignoux; 1853.
- 2 Feltgen K. Le cholestérol (1758–1913): essai historique sur l’intérêt qu’il a suscité en médecine depuis sa découverte au milieu du XVIIIe siècle jusqu’à l’aube du XXe siècle. Thèse Rouen 1993; 1993ROUEM048.

- 3 Thiroux d'Arconville MGC (1720–1805). Essai pour servir à l'histoire de la putréfaction. Par le traducteur des Leçons de chymie de M. Shaw. Paris: chez P. Fr. Didot Le Jeune; 1766.
- 4 Macquer PJ. Dictionnaire de chymie, contenant la théorie et la pratique de cette science, son application à la physique, à l'histoire naturelle, à la médecine et à l'économie animale. A Paris: Didot le Jeune; 1778.
- 5 Pemberton H, Poulletier de La Salle FP. *Pharmacopée du Collège royal des médecins de Londres : traduite de l'Anglois sur la seconde édition*. Paris: Didot le Jeune; 1771.
- 6 Viçq d'Azyr F. Recherches et Observations sur divers objets de Médecine, de Chirurgie & d'Anatomie; les concrétions animales. Histoire de la Société royale de Médecine de Paris, avec les Mémoires de médecine et de physique médicale année 1779. Paris: imprimerie de Monsieur et Didot le Jeune; 1782. pp. 204–10.
- 7 Fourcroy AF. De la substance feuilletée et cristalline contenue dans les calculs biliaires et de la nature des concrétions cystiques cristallisées. *Ann Chim*. 1789;3:242–52.
- 8 Chevreul. Sixième mémoire : examen des graisses de l'homme, du mouton, de bœuf, de jaguar et d'oeie à l'Académie des Sciences le 26 août 1816. *Ann Chim Phys*. 1816;2:339–72.
- 9 Chevreul E. Recherches chimiques sur les corps gras d'origine animale. A Paris et à Strasbourg: chez FG. Levrault; 1823.
- 10 Lassaigne JL. Analyse de plusieurs calculs et concrétions trouvés dans différents animaux. *Ann Chim Phys*. 1818;9:324–9.
- 11 Couerbe JP. Du cerveau considéré sous le point de vue chimique et physiologique. *Ann Chim Phys*. 1834;56:160–93.
- 12 Boudet F. Nouvelles recherches sur la composition du sérum du sang humain. *Ann Chim Phys*. 1833;52:337–48.
- 13 Becquerel A, Rodier A. *Recherches et composition du sang dans l'état de santé et dans l'état de maladie*. Paris: Félix Malteste; 1844.
- 14 Berthelot M. *Chimie organique fondée sur la synthèse*. Paris: Mallet Bachelier; 1860.
- 15 McIlwain H. *Biochemistry and the Central Nervous System*. London: J. & A. Churchill Ltd.; 1955.
- 16 Lobstein JF. *Traité d'anatomie pathologique*. Paris, Strasbourg: F.-G. Levrault; 1829.
- 17 Lebert H. Physiologie pathologique, ou, recherches cliniques, expérimentales et microscopiques sur l'inflammation, la tuberculisation, les tumeurs, la formation du cal, etc. Paris: JB. Baillière; 1845.
- 18 Virchow R. Über die Erkenntniss von Cholestearin. *Archiv für Anatomie und Physiologie*. 1857;12:101–4.
- 19 Virchow R. *Die Cellularpathologie in ihrer Begründung auf physiologische und pathologische Gewebelehre : Zwanzig Vorlesungen gehalten während der Monate Februar, März und April 1858 in pathologischen Institute zu Berlin*. Berlin: A. Hirschwald; 1858.
- 20 Flint A Jr. Experimental Researches into a new Excretory Function of the liver consisting in the Removal of Cholesterine from the Blood and its Discharge from the Body in the form of Stercorine. *Am J Med Sci*. 1862;44(88):305–65.
- 21 Charcot JM. Gangrène du pied et de la jambe; dépôts fibrineux multiples dans les reins, la rate, le foie, etc. Comptes Rendus des séances de la Société de Biologie, année 1855. Paris: J. Hamel & JB. Baillière; 1856.
- 22 Lellouch A. *Jean-Martin Charcot et les origines de la gériatrie*. Paris: Payot; 1992.
- 23 Schiller F. Concepts of stroke before and after Virchow. *Med Hist*. 1970 Apr;14(2):115–31.
- 24 Paciaroni M, Bogousslavsky J. How did stroke become of interest to neurologists?: a slow 19th century saga. *Neurology*. 2009 Sep;73(9):724–8.
- 25 Van Swieten G. Commentaria in Hermani Boerhaave aphorismos de cognoscendis et curandis morbis. Taurini typogregia; 1744.
- 26 Legroux CJ. Recherches sur les concrétions sanguines dites polypiformes, développées durant la vie. Thèse Paris n°215: imp. Didot le Jeune; 1827.
- 27 Charcot JM. Note sur la claudication intermittente observée dans un cas d'oblitération complète de l'une des artères iliaques primitives. *Recueil de Médecine Vétérinaire* 1859;6 (4^e série):481–94.
- 28 Goubaux A. Mémoire sur les paralysies du cheval causées par l'oblitération de l'aorte postérieure et ses divisions terminales. *Recueil de Médecine Vétérinaire*. 1846;3(3^e série):578–617.
- 29 Bouley H. Des maladies de la moelle épinière et de ses enveloppes chez le cheval. *Rec Med Vet Ec Alfort*. 1830;7:90–269.
- 30 Charcot JM. *Leçons cliniques sur les maladies des vieillards et les maladies chroniques. Fascicule 1*. Paris: Delahaye; 1866.
- 31 Bayle F. Tractatus de apoplexia: in quo hujus affectionis causa penitus inquiritur & curatio exponitur. Tolosae: B. Guillemette; 1677.
- 32 Bouchut E. Mémoire sur la nature du ramollissement cérébral sénile. Actes de la Société médicale des Hôpitaux de Paris; 1850. pp. 37–43.
- 33 Bouchut E. *Mémoire sur la marche et la nature de l'angine de poitrine*. Paris: Béthune et Plon; 1841.
- 34 Lancereaux E. De la thrombose et de l'embolie cérébrales considérées principalement dans leurs rapports avec le ramollissement du cerveau. Thèse Paris n°39: imp. Rignoux; 1862.
- 35 Charcot JM. Un cas de tumeurs fibrineuses multiples contenant une matière puriforme situées dans l'oreillette droite du cœur; suivi de cas analogues et de quelques remarques critiques. *Compte Rendus des séances et mémoires de la Société de Biologie, année 1851. Paris: Au Bureau de la Gazette médicale*. 1852;3:189–200.
- 36 Charcot JM. Sur la paralysie douloureuse et sur la thrombose artérielle qui surviennent dans certains cas de cancer. *L'Union médicale*. 1865;26:195–99.
- 37 Charcot JM. Exposé des Titres scientifiques. Versailles: imp. Cerf et fils; 1878.
- 38 Rostan L. *Recherches sur une maladie encore peu connue qui a reçu le nom de ramollissement du cerveau*. Paris: Béchet & Crevot; 1820.
- 39 Poirier J, Derouesné C. [Neurology in Paris hospitals, particularly the Salpêtrière before Charcot: Rostan on brain softening]. *Rev Neurol (Paris)*. 2000;156(6-7):607–15.
- 40 Bouillaud JB. *Traité de l'encéphalite ou inflammation du cerveau*. Paris: JB. Baillière; 1825.
- 41 Durand-Fardel M. Mémoire sur une forme d'encéphalite peu connue. *Archives générales de Médecine*. 1839;4 (3^e série):164–84/317–38.
- 42 Calmeil LF. *Traité des maladies inflammatoires du cerveau*. Paris: JB. Baillière; 1859.
- 43 Prevost JL, Cotard J. *Études physiologiques et pathologiques sur le ramollissement cérébral*. Paris: A. Delahaye; 1866.
- 44 Déchy H. *Alfred Vulpian, neurologue, pionnier de la médecine moderne*. Paris: La Compagnie d'Hauteville; 2018.
- 45 Poirier J. Le docteur Jean-Baptiste Vincent Laborde (1830–1903), neurologue et neurophysiologiste oublié. *Geriatr Psychol Neuropsychiatr Vieil*. 2015 Mar;13(1):73–82.
- 46 Laborde JV. *Le ramollissement du cerveau, principalement considéré chez le vieillard, étude clinique et pathogénie*. Paris: A. Delahaye; 1866.
- 47 Proust A. Des différentes formes de ramollissement du cerveau. Thèse présentée au concours de l'agrégation et soutenue le 14 mars 1866. Paris: Asselin et Labé; 1866.
- 48 Delacour Ch. Ossification des capillaires du cerveau. *Gazette des Hôpitaux civils et militaires*. 1850;23:107.
- 49 Poumeau I. Du rôle de l'inflammation dans le ramollissement cérébral. Thèse Paris n°283: Hennuyer et fils; 1866.
- 50 Kierzek A, [Benni, Babiński, Bouchard, Charcot. Their contribution to the development of XIX-century Polish and French medical relations]. *Przegl Lek*. 2007;64(3):183–4.
- 51 Benni C. Recherches sur quelques points de la gangrène spontanée. Thèse Paris n°149: imp. E. Martinet; 1866.
- 52 Soulier PH. *Étude critique sur le ramollissement cérébral*. Lyon: P. Mégret; 1867.
- 53 Poirier J, Derouesné C. Le concept de lacune cérébrale de 1838 à nos jours. *Rev Neurol (Paris)*. 1985;141(1):3–17.
- 54 Vauttier A. Essai sur le ramollissement cérébral latent. Thèse Paris n°246: A. Parent; 1868.
- 55 Virchow R. Ueber die acute Entzündung der Arterien. *Virchows Arch*. 1847;1(2):272–378.
- 56 Virchow R. Thrombose und Embolie: Gefässenzündung und Septische Infektion. In *Gesammelte Abhandlungen zur wissenschaftlichen Medicin*. Frankfurt am Main: Meidinger; 1856.
- 57 Rochoux JA. Propositions sur l'apoplexie. Thèse Paris n°76: imp. Didot le Jeune; 1812.
- 58 Bouchard Ch. Etude sur quelques points de la pathogénie des hémorragies cérébrales. Thèse Paris n°328 : A. Parent. 1866.
- 59 Bogousslavsky J, Paciaroni M. Did Jean-Martin Charcot contribute to stroke? *Eur Neurol*. 2010;64(1):27–32.
- 60 Goetz CG, Bonduelle M, Gelfand T. *Charcot Constructing Neurology*. New York: Oxford University Press; 1995.