

# A Case of Leukoencephalopathy and Small Vessels Disease Caused by a Novel *HTRA1* Homozygous Mutation

Tuncay Gündüz, MD,\* Yasemin Demirkol, MD,†<sup>1</sup> Özlem Doğan, MD,†<sup>1</sup>  
Serkan Demir, MD,‡ and Nihan Hande Akçakaya, MD, PhD§<sup>1</sup>

---

Cerebral autosomal recessive arteriopathy with subcortical infarcts and leukoencephalopathy (CARASIL) is a heritable, rare small vessel disease, which is caused by *HTRA1* mutations and mostly reported Japanese and Chinese population. CARASIL is an orphan disease, which presents with progressive motor and cognitive impairment, alopecia, and spondylosis. The disease typically starts with lumbago at early twenties. Ischemic strokes start at mid-twenties. Patients have no cardiovascular or any other risk factors. Multiple lacunar infarcts and leukoencephalopathy cause progressive neurologic involvement. Leukoencephalopathy and small vessel disease without any risk factors is a significant finding for the differential diagnosis of *HTRA1* gene pathology. This report presents clinical and genetic features of a rare case of typical CARASIL from Turkey who was followed with uncertain diagnoses for years.

**Key Words:** *HTRA1*—CARASIL—leukoencephalopathy—small vessel disease—lacunar infarcts

© 2019 Elsevier Inc. All rights reserved.

---

Cerebral autosomal recessive arteriopathy with subcortical infarcts and leukoencephalopathy (CARASIL) is a heritable small vessel disease, which clinically causes to progressive motor and cognitive impairment with alopecia and spondylosis.<sup>1-3</sup> We wish to present a rare case of typical CARASIL who was followed with uncertain diagnoses for years.

Thirty five years old male patient whose parents were cousins complained of chronic lumbar pain since the age of his early-twenties. He was operated for lumbar disc herniations and spondylosis. He started to have ischemic strokes at the age of 26 and had numerous hemiparetic and dysarthric episodes for years. These episodes generally recovered within weeks. After age of 30, a progressive motor and mental deterioration started leading to progressive memory deficit,

emotional instability, dysphagia, gait problems, and urinary incontinence.

In his medical examination, he was cognitively impaired and could hardly perform two-stepped orders. He had severe dysarthria with pseudobulbar palsy, right-side dominant spastic tetra-paresis, and severe gait ataxia. Babinski sign and Hoffmann reflex were bilaterally positive. He had an atypical baldness; there was a tuft of hair on vertex. Urine, blood count, and blood chemistry were normal and metabolic and serologic screening tests were negative. Cerebrospinal fluid (CSF) analysis was normal without oligoclonal bands. There were no cardiovascular risks recorded.

The brain MRI showed leukodystrophic changes in bilateral periventricular and deep white matter. Beside the leukodystrophic changes, chronic lacunar infarcts in

---

From the \*Department of Neurology, Istanbul Faculty of Medicine, Istanbul University, Istanbul, Turkey; †Department of Medical Genetics, Umraniye Training and Research Hospital, Health Sciences University, Istanbul, Turkey; ‡Department of Neurology, Sultan Abdulhamid Han Training and Research Hospital, Health Sciences University, Istanbul Turkey; and §Council of Forensic Medicine, Istanbul, Turkey.

Received May 28, 2019; revision received August 4, 2019; accepted August 14, 2019.

The authors declare that they have no conflict of interest.

Ethics: Written informed consents were received for/from patients authorizing us to use their medical data in this publication.

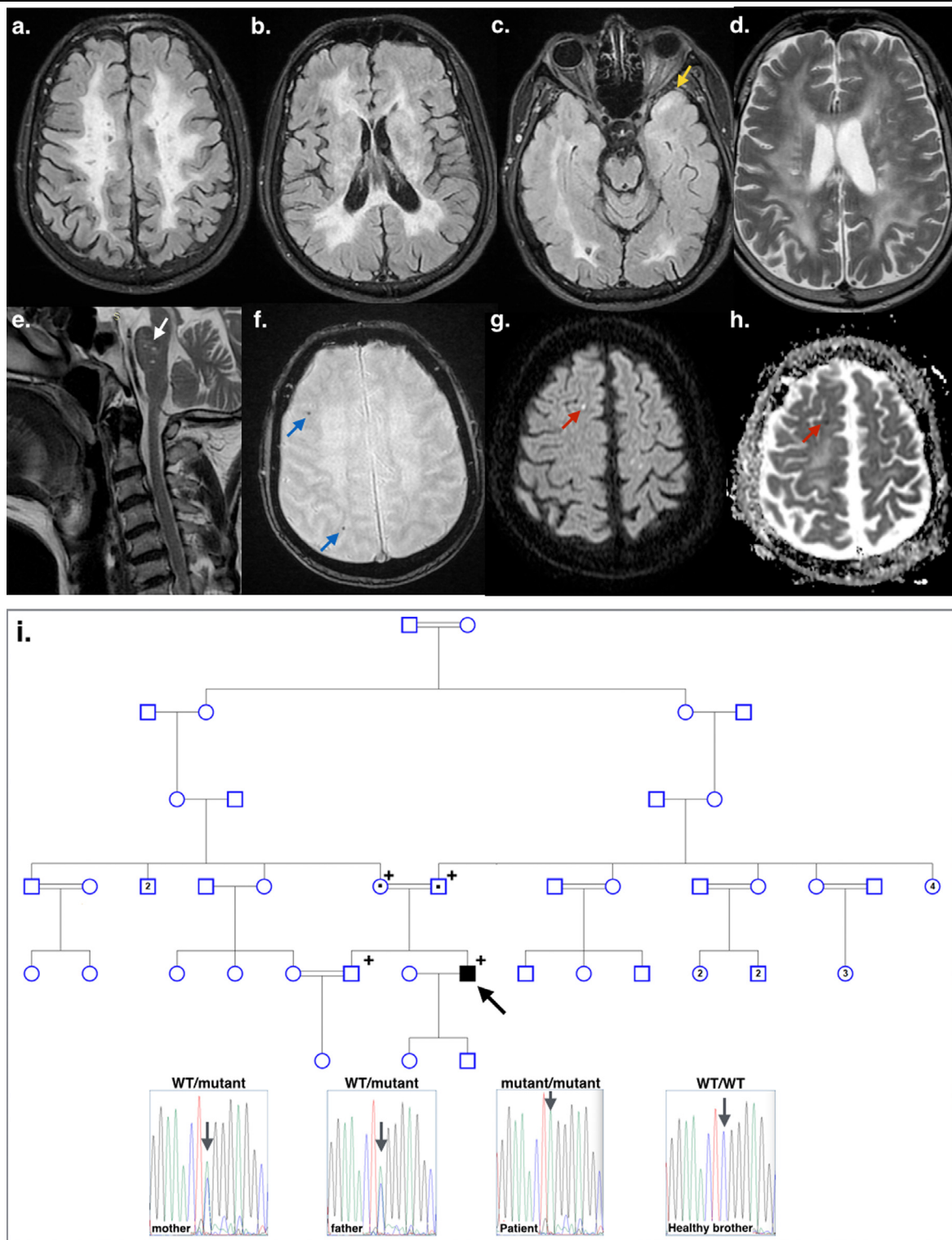
Address correspondence to Nihan Hande Akçakaya, MD, PhD, Council of Forensic Medicine, Fevzi Çakmak Mahallesi Sanayi Caddesi, Kimız Sokak, No. 1 Bahçelievler, Istanbul 34196, Turkey. E-mail: [nhakcakaya@gmail.com](mailto:nhakcakaya@gmail.com).

<sup>1</sup>MarmaRare Genetic Study Group.

1052-3057/\$ - see front matter

© 2019 Elsevier Inc. All rights reserved.

<https://doi.org/10.1016/j.jstrokecerebrovasdis.2019.104354>



**Figure 1.** MRI images of the patient. (a-c) Axial FLAIR brain MR images showed bilateral periventricular and deep white matter leukodystrophic changes including multiple lacunar infarctions. The brain MRI demonstrated abnormalities in the white matter of anterior temporal lobe (yellow arrow). (d) Leukodystrophic changes is seen on axial T2-weighted brain MR image as an extensive high signal intensity of cerebral white matter. Superficial white matter (U-fibers) is relatively spared. (e) Cervical sagittal T2-weighted MR image showed multiple chronic lacunar infarcts at pons (white arrow) and multilevel degenerative discopathy with spondylosis. (f) Microbleeds are shown in axial SWI weighted brain image at the level of centrum semiovale (blue arrows). (g, h) Diffusion and ADC-weighted axial brain MR images showed right parietal subcortical millimetric subacute lacunar infarct (red arrows). (i) The pedigree of the family and electropherogram images are shown. The parents, who were both healthy, were heterozygous carriers of the mutation. His healthy sibling was wild type (WT) for both allele. The mutation located on an evolutionary conserved position at trypsin-like serine protease domain and in silico tools showed (Polymorphism Phenotyping v2 and Mutation Taster) the amino acid substitution has a damaging effect on the protein. (Color version of figure is available online.)

pons and cerebral hemispheres and microbleeds in centrum semiovale were present (Fig 1). Spinal MRI revealed no lesion in the medulla spinalis. However, spondylosis and multiple disc herniations were observed in the cervical and lumbar segments.

Clinic exome sequencing was performed for the patient through the commercial service provided by Genera Diagnostic (Istanbul, Turkey). Exonic DNA for 4493 genes was captured with the Clinical Exome Solution v2 (Sophia Genetics, Switzerland) and sequenced on the Illumina Nextseq 500 platform. The data were filtered for both recessive and dominant inheritance patterns. These analyses revealed a novel homozygous c.983C>A;p.Ser328\* *HTRA1* (NM\_002775) nonsense mutation. By Sanger sequencing, the mutation confirmed and family segregation performed (Fig 1).

The *HTRA1* mutations are known to cause cerebral small vessel disease by decreasing *HTRA1* protease activity leading to an increase in TGF- $\beta$  signaling. Acceleration of TGF- $\beta$ 1 signaling might disrupt the differentiation of vascular smooth muscle cells mainly in cerebral small vessels due to expression of an extra domain of fibronectin (domain A) in central nervous system.<sup>2</sup> Homozygous mutations may cause early onset and extra-neurological features.<sup>4</sup> Multiple microbleeds are commonly seen in both autosomal dominant and recessive form of the disease.<sup>5,6</sup> Brain stem lacunar infarcts, external capsule, and anteroinferior leukodystrophic involvement of the temporal lobes are seen at *HTRA1* mutations.<sup>5</sup> At later stages, diffuse brain atrophy, thalamic, and cerebellar region involvement are

known but corpus callosum and U-fibers are not radiologically involved in the disease.<sup>2,5,7</sup> In conclusion, it is crucial to remember *HTRA1* gene pathologies in patients with leukoencephalopathy and small vessel disease.

## References

1. Maeda S, Nakayama H, Isaka K, et al. Familial unusual encephalopathy of Binswanger's type without hypertension. *Folia Psychiat Neurol Jpn* 1976;30:165-177.
2. Nozaki H, Nishizawa M, Onodera O. Features of cerebral autosomal recessive arteriopathy with subcortical infarcts and leukoencephalopathy. *Stroke* 2014;45:3447-3453.
3. Hara K, Shiga A, Fukutake T, et al. Association of *HTRA1* mutations and familial ischemic cerebral small-vessel disease. *New Eng J Med* 2009;360:1729-1739.
4. Verdura E, Hervé D, Scharrer E, et al. Heterozygous *HTRA1* mutations are associated with autosomal dominant cerebral small vessel disease. *Brain* 2015 Aug;138(Pt 8):2347-2358.
5. Kono Y, Nishioka K, Li Y, et al. Heterozygous *HTRA1* mutations with mimicking symptoms of CARASIL in two families. *Clin Neurol Neurosurg* 2018;172:174-176.
6. Bougea A, Velonakis G, Spantideas N, et al. The first Greek case of heterozygous cerebral autosomal recessive arteriopathy with subcortical infarcts and leukoencephalopathy: an atypical clinico-radiological presentation. *Neuroradiol J* 2017;30:583-585. 1971400917700168.
7. Ibrahim M, Nozaki H, Lee A, Onodera O, Reichwein R, Wicklund M, El-Ghanem M. A CARASIL patient from Americas with novel mutation and atypical features: case presentation and literature review. *Cerebrovasc Dis* 2017;44:135-140.