

Ischemic Stroke in a Girl with Lupus Anticoagulant

Roger E. Kelley, MD and

Joseph R. Berger, MD

A 16-year-old girl developed right middle cerebral artery infarction and deep venous thrombosis of the lower extremities in association with circulating lupus-like anticoagulant. Currently, she is functionally independent with no further vascular insults and is being treated with sodium warfarin. This patient illustrates that cerebral ischemia can occur in association with lupus anticoagulant in the pediatric population. This entity should be considered and appropriate screening tests performed in young patients with unexplained ischemic stroke or transient ischemic attack.

Kelley RE, Berger JR. Ischemic stroke in a girl with lupus anticoagulant. *Pediatr Neurol* 1987;3:58-61.

Introduction

Lupus anticoagulant (LA), a circulating immunoglobulin in the IgG or IgM class, is associated with a tendency toward thrombosis [1]. It is acquired spontaneously and can occur in association with systemic lupus erythematosus (SLE) [2], other systemic illnesses [2,3], or can develop during the administration of phenothiazines [4,5] or procainamide [6]. Recent studies [7,8] indicated that 23-58% of patients with LA suffer thromboembolism. There have been at least 24 reported patients who developed cerebral ischemia in association with LA [9-13]. We report a 16-year-old girl who suffered a right middle cerebral artery ischemic stroke and who had occlusion of this vessel, LA, as well as possible SLE. This patient illustrates that the coexistence of cerebral ischemia and LA can occur in younger patients and that the presence of LA should be a consideration in a pediatric patient with unexplained stroke.

Case Report

This 16-year-old right-handed girl was in excellent health until October, 1985. She observed progressive painless swelling of both

lower extremities. On examination 2 months later she had an elevated filaria titer by hemagglutination of 1:256 and microfilaria were found on blood smear. The patient was born in Massachusetts but she had traveled to Puerto Rico; a maternal grandfather in Puerto Rico reportedly had filariasis. She received diethylcarbamazine citrate (150 mg orally 3 times daily for 3 weeks).

Seven months later she experienced daily recurrent headache. The pain was throbbing, localized to the right, lasted approximately 10 minutes, and was not associated with concurrent symptoms. One month later she developed vaginal pain; metronidazole (8-250 mg tablets) was prescribed for trichomonas vaginitis. Two days later, she was admitted to the hospital because of increasing right-sided headache and left-sided weakness. On admission, she was afebrile, pulse was 80/min and regular, and blood pressure was elevated continuously with a systolic of 160-180 mm Hg and a diastolic of 100-120 mm Hg. She had no alopecia or skin rash. No cranial or cervical bruits were heard. Funduscopic examination was unremarkable. Cardiac auscultation revealed regular rhythm with no murmur, gallop, or rub. Her lungs were clear and abdominal examination was normal. There were no manifestations of arthritis or serositis. There was bilateral lower extremity swelling with mild tenderness of both calves on deep palpation.

Neurologic examination revealed the patient's mental status to be intact and her speech to be normal. Cranial nerve examination was remarkable for a mild, left central facial palsy. There was decreased motor tone on the left side with strength 0/5 distally, 2/5 proximally in the upper extremity, and 5/5 in the left leg. No sensory or cerebellar deficits were observed. Deep tendon reflexes were 2/4 bilaterally with a left extensor toe sign response. She favored her left leg mildly when walking.

Medical history, as well as family history, was unremarkable other than as mentioned above. The patient did not smoke, ingest illicit drugs, use oral contraceptives, and had no history of venereal disease. She had no history of hypertension or a connective tissue disorder.

Unenhanced cranial computed tomography (CT), obtained on the second day of presentation, was normal (Fig 1A). On day 5 of presentation, a repeat study was performed with and without contrast injection which demonstrated several small areas of low density compatible with acute ischemic infarction in the right middle cerebral artery distribution (Figs 1B,C). The hemoglobin was 12.6 gm/dl, hematocrit 36%, and white blood cell count 8,000/mm³ with 48% polymorphonuclear cells, 31% lymphocytes, 5% monocytes, and 10% eosinophils; platelet count was 139,000/mm³. The erythrocyte sedimentation rate was 67 mm/hr. A prothrombin time was 11 sec with a control of 10.9 sec and the PTT was prolonged at 57 sec with a control of 32 sec. The presence of LA was confirmed by the failure of the PTT to correct with the addition of normal plasma to the *in vitro* assay [2], positive platelet neutralization, and abnormal thromboplastin inhibition. At 1:1,000 dilution, control = 62.9 sec, patient = 125.5 sec, ratio = 1.99, (normal: < 1.7) [2].

The following tests were normal: serum chemistries, BUN, creatinine, cholesterol, and triglyceride. Rapid plasma reagent (RPR) was positive at 1:32 dilution, but the serum FTA-ABS, and cerebrospinal fluid VDRL were both negative. The cerebrospinal fluid was clear and colorless; white blood cells none, red cells 32/mm³, protein 17 mg/dl, and glucose 50 mg/dl. The ANA was positive at 1:160 dilution with a speckled pattern. The anti-double stranded DNA and anti-Smith nuclear antigen antibody were both negative. The C₃ complement level was normal at 89 mg/dl, but the C₄ complement level was low at 12 mg/dl (normal: 15-45 mg/dl). The serum protein electrophoresis revealed a total protein of 7.6 mg/dl, albumin 4.0 mg/dl, α_1 0.2 mg/dl, α_2 0.7 mg/dl, and β 0.8 mg/dl.

From the Department of Neurology; University of Miami School of Medicine; Miami, Florida.

Communications should be addressed to:
Dr. Kelley; Department of Neurology (D4-5); 1501 NW 9th Avenue;
Miami, Florida 33136.

Received December 18, 1986; accepted December 30, 1986.

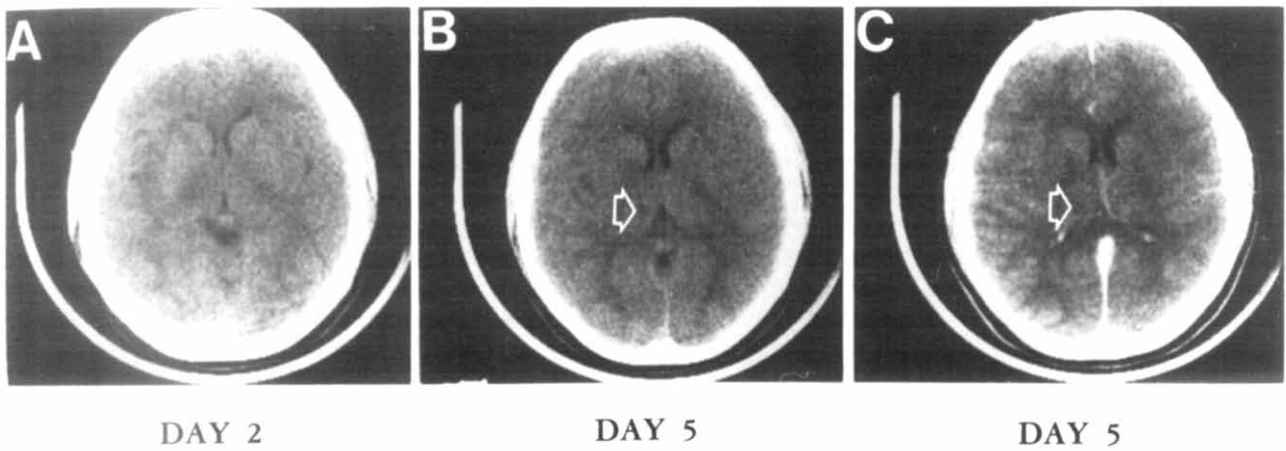


Figure 1. (A) Normal unenhanced cranial CT on the day after admission. Subsequent CTs (B) unenhanced and (C) enhanced demonstrate an area of infarction in the right middle cerebral artery distribution (arrow).

This pattern was compatible with a polyclonal hypergammaglobulinemia. The cerebrospinal fluid protein electrophoresis was normal. A skin biopsy with direct immunofluorescence demonstrated granular deposition of IgM at the dermal-epidermal junction.

Urinalysis was normal with no protein or casts. A 24 hour urine collection contained 406 mg protein (normal: 0-150 mg). Chest x-ray, electrocardiogram, and echocardiogram were normal. The patient remained hypertensive and required treatment with nifedipine (30 mg/day in divided doses). Serum renin content was elevated (8.3 mg/ml; normal: 0.15-2.33 mg/ml). A renal scan revealed no evidence of renovascular hypertension, no evidence of obstruction, and normal hippuran clearance bilaterally.

The patient remained stable during her hospital course and had progressive improvement in her left hemiparesis. A cerebral arteriogram of both carotid arteries and the right vertebral artery demonstrated a right middle cerebral artery occlusion just distal to the origin of the posterior temporal branch (Figs 2A,B). No evidence of

arteritis was found and the left carotid artery distribution was unremarkable. Collateral circulation of the right middle cerebral artery distribution was provided via leptomeningeal branches of the anterior cerebral artery and right posterior cerebral artery. Following this study, the patient was treated with aspirin (80 mg/day) for cerebrovascular prophylaxis. Sodium warfarin was substituted for aspirin after a right leg venogram demonstrated deep venous thrombosis of the right calf and lower thigh.

The patient was discharged with a mild residual left hemiparesis; she was normotensive without antihypertensive medication, and was discharged on sodium warfarin (5 mg/day). Subsequent examinations 2 and 6 weeks after discharge revealed normal strength in all extremities with mildly impaired dexterity of the left hand. There has been a mild diminution in the degree of leg swelling. She has not been treated with corticosteroids because the diagnosis of SLE has not been firmly established.

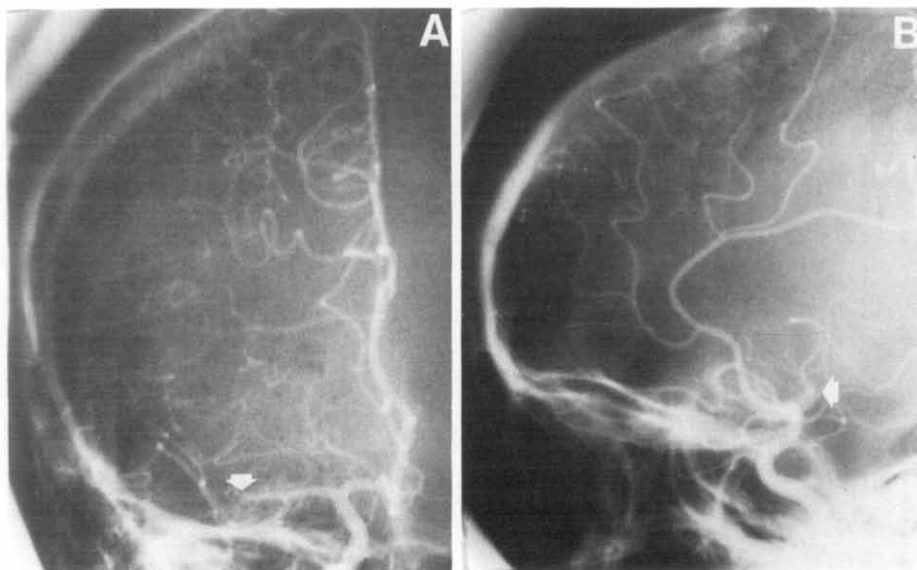


Figure 2. Carotid arteriogram (A) anterior-posterior and (B) lateral view that demonstrate a right middle cerebral artery occlusion just distal to the origin of the posterior temporal branch (arrow).

Discussion

This patient had a hypercoagulable state manifested by right middle cerebral artery occlusion and deep venous thrombosis of the lower extremities. She had evidence of multisystem disease, presumably on an autoimmune basis, but she did not fulfill the American Rheumatologic Association criteria for SLE [14]. She did not have a rash, photosensitivity, oral ulcers, serositis, hemolytic anemia, leukopenia, lymphopenia, significant thrombocytopenia, anti-DNA antibody, or anti-Smith antibody. She did have a neurologic disorder, but it did not consist of seizures or psychosis and there was no evidence of arteritis by arteriography or by skin biopsy. On admission she was hypertensive; however, this symptom was transient and she did not fulfill the renal criteria for the presence of either proteinuria >0.5 gm per day or cellular casts in the urine. In addition, a positive ANA and biologically false positive serologic test for syphilis have been reported in LA without coexistent SLE [1]. Thus, the patient fulfilled 2 of 11 possible criteria for SLE (positive ANA and biologically false positive serologic test for syphilis) [14], and had evidence of IgM deposition in the skin as well as a neurologic disorder and evidence of renal disease. Diagnosis is based upon at least 4 criteria being met; thus the patient remains at risk for the eventual development of SLE.

The association of LA with SLE accounts for approximately 50% of all LA patients [2]. It also can manifest in malignancies [2,3], other immunologic disorders [2,3], pregnancy [15], and with certain drugs [5,7]. LA is usually detected by prolongation of the activated PTT that does not fully correct when added to an equal amount of normal plasma [16]. PT also may be prolonged in some patients [2]. As mentioned previously, LAs are a heterogeneous group of immunoglobulins that have been termed "circulating anticoagulants" to emphasize their nonspecific characteristics and their inconsistent occurrence with SLE [17]. Some of these inhibitors of coagulation bind to phosphate esters of phospholipids which has led to the designation antiphospholipid antibodies [11].

It appears that LA is an inhibitor of coagulation tests performed *in vitro* rather than a true inhibitor of hemostasis [18]. This property explains the finding that hemorrhagic complications in the presence of LA are uncommon unless there is a coexistent cause of bleeding diathesis such as thrombocytopenia [17,19]. Evidence suggests that the prolongation of the activated PTT is related to inhibition of the extrinsic phospholipid reagent (cephaloplastin, activated thromboplastin) that substitutes for the platelets *in vitro* in the coagulation cascade [7]. There has been conjecture that the strong association between the presence of LA and biological false-positive tests for syphilis, which use the phospholipid cardiolipin as the antigen, is reflective of

the phospholipid being the active site in promotion of thrombosis [20]. In support of this theory, Harris et al. [21] demonstrated a strong correlation between thrombosis in SLE and raised titers of anticardiolipin antibody.

Thrombosis in association with LA was the presumptive mechanism of stroke in this patient; she had no evidence of arteritis and no source of cerebral embolus. Middle cerebral artery occlusion is not common in pediatric patients. In addition, the presence of coexistent deep venous thrombosis strongly suggested a hypercoagulable state. The predisposition toward thrombosis, in the presence of LA, may be related to inhibition of prostacyclin or its receptors [22]. It also may be related to decreased fibrinolytic activity [23]. LA in this patient may have been related to early SLE but it does not appear to be drug-related. Diethylcarbamazine is a piperazine derivative which has not been reported to be associated with LA or with an SLE-like picture [24].

Concerns were raised recently about the use of immediate anticoagulation in pediatric patients with acute ischemic stroke [25]. In light of the coexistence of deep venous thrombosis in this patient, there was a definite indication for the use of anticoagulant therapy and this emergent condition was believed to justify the risk of converting an initially ischemic cerebral infarct into a hemorrhagic infarct. PTT was not a reliable indicator of the *in vitro* degree of anticoagulation with heparin in this patient. Warfarin was administered because PT was not affected. Anticoagulant therapy is safe in patients with thrombosis and LA, although its efficacy in preventing recurrent cerebral infarction remains to be determined [10].

To our knowledge, this patient is the first in the pediatric age group to suffer a well-documented ischemic stroke in association with LA. There have been reports of thrombotic complications in young patients with LA but other organs were involved and most had well-documented SLE [18]. LA should be screened for routinely in pediatric patients with unexplained cerebral ischemia by measuring PTT.

References

- [1] Shapiro SS, Thiagarajan P. Lupus anticoagulants. In: Spaet TH, ed. Progress in hemostasis and thrombosis. New York: Grune and Stratton, 1982;6:263-85.
- [2] Schleider MA, Nachman RL, Jaffe EA, Coleman M. A clinical study of lupus anticoagulant. Blood 1976;48:499-509.
- [3] Boxer M, Ellam L, Carvalho A. The lupus anticoagulant. Arthritis Rheum 1976;19:1244-8.
- [4] Canoso RT, Hutton RA, Deykin D. A chlorpromazine-induced inhibitor of blood coagulation. Am J Hematol 1977; 2:189-91.
- [5] Zarabi MH, Zucker S, Miller F, et al. Immunologic and coagulation disorders in chlorpromazine-treated patients. Ann Intern Med 1979;91:194-9.

- [6] **Bell WR**, Boss GR, Wolfson JS. Circulating anticoagulant in the procainamide-induced lupus syndrome. *Arch Intern Med* 1977;137:1471.
- [7] **Mueh JR**, Herbst KD, Rapaport SI. Thrombosis in patients with the lupus anticoagulant. *Ann Intern Med* 1980;92:156-9.
- [8] **Boey ML**, Colaco CB, Gharavi AE, Elkon KB, Loizou S, Hughes GRU. Thrombosis in systemic lupus erythematosus: Striking association with the presence of circulating lupus anticoagulant. *Br Med J* 1983;287:1021-3.
- [9] **Kelley RE**, Gilman PB, Kovacs A. Cerebral ischemia in the presence of lupus anticoagulant. *Arch Neurol* 1984;41:521-3.
- [10] **Fisher M**, McGehee W. Cerebral infarct, TIA, and lupus inhibitor. *Neurology* 1986;36:1234-7.
- [11] **Jacobson DM**, Lewis JH, Bontempo FA, Spero JA, Raggi MV, Reinmuth OM. Recurrent cerebral infarction in two brothers with antiphospholipid antibodies that block coagulation reactions. *Stroke* 1986;17:98-102.
- [12] **D'Alton JG**, Preston DN, Bormanis J, Green MS, Kraag G. Multiple transient ischemic attacks, lupus anticoagulant and verrucous endocarditis. *Stroke* 1985;16:512-4.
- [13] **Tabachnik-Schor NF**, Lipton SA. Association of lupus-like anticoagulant and nonvasculitic cerebral infarction. *Arch Neurol* 1986;43:851-2.
- [14] **Tan EM**, Cohen AS, Fries JF, et al. The 1982 revised criteria for the classification of systemic lupus erythematosus. *Arthritis Rheum* 1982;25:1271-7.
- [15] **Feinstein DI**. Lupus anticoagulant, thrombosis, and fetal loss. *N Engl J Med* 1985;313:1348-50.
- [16] **Conley CL**, Hartman RC, Morse WI. Circulating anti-coagulant: A technique for their detection and clinical studies. *Bull Johns Hopkins Hosp* 1949;844:255-9.
- [17] **Margolis A Jr**, Jackson DP, Ratnoff OP. Circulating anti-coagulant: A study of 40 cases and review of the literature. *Medicine* 1961;40:145-202.
- [18] **Elias M**, Eldor A. Thromboembolism in patients with the "lupus"-type circulating anticoagulant. *Arch Intern Med* 1984;144:510-15.
- [19] **Feinstein DI**, Rapaport SI. Acquired inhibitors of blood coagulation. *Prog Hemost Thromb* 1972;1:75-95.
- [20] **Hughes GRV**. Thrombosis, abortion, cerebral disease, and the lupus anticoagulant. *Br Med J* 1983;287:1088-9.
- [21] **Harris EN**, Gharavi AE, Boey ML, et al. Anticardiolipin antibodies: Detection by radioimmunoassay and association with thrombosis in systemic lupus erythematosus. *Lancet* 1983;2:1211-4.
- [22] **Carreras LO**, Vermeylen JG. "Lupus" anticoagulant and thrombosis: Possible role of inhibition of prostacyclin formation. *Thromb Haemost* 1982;48:38-40.
- [23] **Sanfelippo MJ**, Drayona CJ. Prekallikrein inhibition associated with the lupus anticoagulant: A mechanism of thrombosis. *Am J Clin Pathol* 1982;77:275-9.
- [24] **Webster LT Jr**. Drugs used in the chemotherapy of helminthiasis. In: Gilman AG, Goodman LS, Rall TW, Murad F, eds. *The pharmacological basis of therapeutics*, 7th ed. New York: MacMillan, 1985;1010-1.
- [25] **Kelley RE**. Hemorrhagic cerebral infarction in pediatric patients. *Pediatr Neurol* 1986;2:111-4.