


Pipeline embolization for an iatrogenic intracranial internal carotid artery pseudoaneurysm after transsphenoidal pituitary tumor surgery: Case report and review of the literature

Yasuhiko Nariai , Yosuke Kawamura, Tomoji Takigawa, Akio Hyodo and Kensuke Suzuki

Abstract

Intracranial pseudoaneurysms are uncommon and among the most difficult lesions to treat with surgery or endovascular means without parent artery sacrifice. Here, we report on a patient who underwent successful treatment using a flow-diverting stent for an iatrogenic intracranial internal carotid artery pseudoaneurysm following a vessel injury after endoscopic pituitary tumor resection via the transsphenoidal approach. A 62-year-old man with a Rathke's cleft cyst presenting with bitemporal hemianopia and progressive decline of left visual acuity underwent endoscopic transsphenoidal pituitary tumor resection. During dura incision, brisk arterial bleeding was encountered from the right internal carotid artery. Immediate packing was performed, and hemostasis was achieved. Three days after the vessel injury, an angiography revealed a pseudoaneurysm (2.9 × 2.1 mm) at the cavernous segment of the right internal carotid artery, which showed enlargement on follow-up magnetic resonance imaging at six days postoperatively. Pipeline embolization was performed nine days after the vessel injury. Angiography performed one month after Pipeline embolization revealed significant stagnation but not complete occlusion of blood flow inside the pseudoaneurysm cavity. Dual antiplatelet therapy was replaced with single antiplatelet therapy. Follow-up angiograms three months after Pipeline embolization confirmed complete obliteration of the pseudoaneurysm and successful endoluminal reconstruction of the damaged vessel. Despite the possibility of short-term bleeding and the need for dual antiplatelet therapy administration for a certain period, the use of flow-diverting stents is a feasible vessel-sparing option in the management of intracranial internal carotid artery pseudoaneurysms resulting from transsphenoidal surgery injuries if intraoperative hemodynamic stability can be achieved with effective packing.

Keywords

Intracranial pseudoaneurysm, transsphenoidal surgery, Pipeline

Received 22 July 2019; accepted 19 August 2019

Introduction

Intracranial pseudoaneurysms are uncommon and among the most difficult lesions to diagnose and treat. Internal carotid artery (ICA) pseudoaneurysms resulting from iatrogenic injuries during transsphenoidal surgery (TSS) are not true aneurysms, as they lack a true, full-thickness wall and are covered only by a fragile connective tissue layer.¹ Intracranial pseudoaneurysms can occur from blunt or penetrating trauma, arterial dissection, infection, radiation, associated collagen vascular disease, or may be detected following surgery.^{2–5}

The treatments for intracranial pseudoaneurysms include a wide variety of microsurgical and

endovascular techniques such as clipping, trapping, carotid artery ligation, balloon occlusion, coil embolization, stent-assisted coil embolization, covered stent placement, and the use of onyx.^{6–11}

With the recent increase in the on-label use of flow-diverting stent embolization, cases of flow-diverting

Department of Neurosurgery, Dokkyo Medical University Saitama Medical Center, Saitama, Japan

Corresponding author:

Yasuhiko Nariai, Department of Neurosurgery, Dokkyo Medical University Saitama Medical Center, 2-1-50 Minamikoshigaya, Koshigaya Shi, Saitama 343-8555, Japan.

Email: nariainari@gmail.com

stents for blood blister-type aneurysms, pseudoaneurysms, and dissecting aneurysms have been reported, despite off-label use.^{1,2,4,12-15} Flow-diverting stents can decrease the velocity and pressure of intraaneurysmal blood flow and promote delayed thrombosis with reconstruction of the parent artery. In addition, they provide a scaffold for long-term endothelialization across an aneurysm neck by diverting blood flow away from the aneurysmal sac, leading to clotting of the aneurysm.¹⁶

Here, we present the case of a patient who underwent successful treatment for an iatrogenic intracranial ICA pseudoaneurysm using a flow-diverting stent after vessel injury during endoscopic tumor resection via transsphenoidal approach. We review the relevant literature and discuss the use of a flow-diverting stent in the treatment of iatrogenic intracranial pseudoaneurysms.

Case presentation

A 62-year-old man with a Rathke's cleft cyst who presented with bitemporal hemianopia and progressive decline of left visual acuity underwent endoscopic transsphenoidal surgical resection of a pituitary cystic lesion (Figure 1). After dura incision and cyst opening, we performed dura incision on the right side. Subsequently, unexpected brisk arterial bleeding was encountered from the right ICA. Immediate packing was performed and hemostasis was achieved.

After the operation, the patient remained neurologically intact, and his visual acuity and bitemporal hemianopia improved. Three days after intraoperative vessel injury, we performed angiography. The angiogram showed a pseudoaneurysm (2.9×2.1 mm) at the

cavernous segment of the right ICA as a result of vessel injury (Figure 2(a)).

By using the Matas maneuver, angiography confirmed cross-flow via the anterior and posterior communicating artery. However, the delay of the venous phase was 6 s. Therefore, we concluded that the patient could not tolerate parent artery occlusion (Figure 3).

Follow-up magnetic resonance imaging six days after the operation revealed enlargement of the pseudoaneurysm. Therefore, we decided to place a Pipeline Flex (Medtronic Neurovascular, Irvine, CA, USA) as primary treatment for the pseudoaneurysm because the pseudoaneurysm was too small for safe and complete insertion of coils. The day before Pipeline embolization, the patient was administered dual antiplatelet agents (DAPT) (loading doses of prasugrel 20 mg and aspirin 200 mg).

Cerebral angiography nine days after the vessel injury showed enlargement of the pseudoaneurysm with dimensions of 3.6×2.9 mm (Figure 2(b)).

On the same day as the Pipeline Flex placement, a 7Fr French (Fr) Cook shuttle sheath (Cook Medical, Bloomington, IN, USA) and a 5Fr Navien guide catheter (Medtronic Neurovascular, Irvine, CA, USA) were placed at the right ICA under general anesthesia nine days after the vessel injury. During the procedure, we administered 6000 units of heparin intravenously to reach an activated clotting time of >250 s. A 150 cm, 3.2Fr, Marksman microcatheter (Medtronic Neurovascular) was then advanced through the Navien guide catheter beyond the vessel injury. Next, a 4.75×16 mm Pipeline Flex was deployed across the neck of the pseudoaneurysm via the Marksman microcatheter. We performed percutaneous transluminal angioplasty for the proximal and distal sides of the

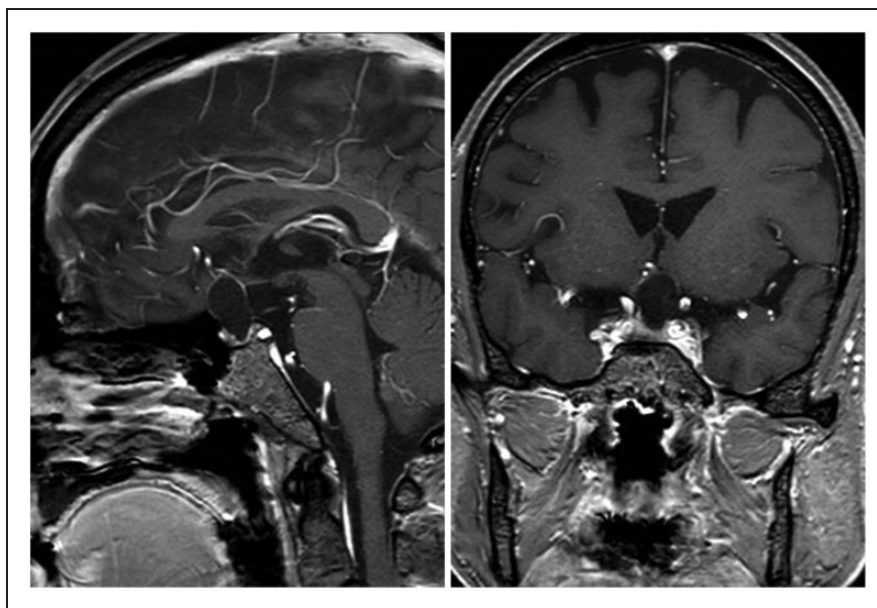


Figure 1. Preoperative contrast T1-weighted magnetic resonance imaging (left, sagittal view; right, coronal view) demonstrating an oval-like mass lesion extending from the sella turcica to the suprasellar space with the circuit of the tumor enhanced.

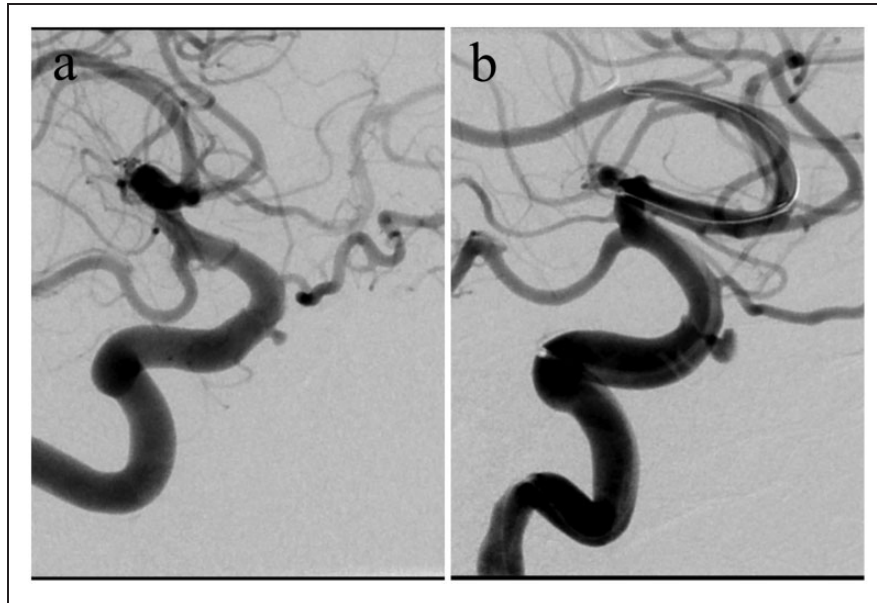


Figure 2. (a) Cerebral angiography three days after transsphenoidal surgery injury showing no active bleeding from the injured site of the right internal carotid artery and a pseudoaneurysm at the cavernous portion of the right internal carotid artery on digital subtraction angiography (size of the pseudoaneurysm: 2.9×2.1 mm). (b) Cerebral angiography nine days after transsphenoidal surgery showing enlargement of the pseudoaneurysm both on digital subtraction angiography and three-dimensional views (size of the pseudoaneurysm: 3.6×2.9 mm).

Pipeline Flex with a HyperForm compliant balloon catheter (MicroTherapeutics, Irvine, CA, USA). Postprocedural angiography revealed immediate and significant stagnation but not complete occlusion of blood flow inside the cavity of the pseudoaneurysm (Figure 4(a)). Multiplanar reconstructed dyna-computed tomography confirmed optimal stent placement and wall apposition (Figure 4(b)).

Subsequently, prasugrel (3.75 mg daily) and aspirin (100 mg daily) were maintained after the surgery. Follow-up angiography two weeks and one month after the Pipeline Flex deployment showed only slight contrast within the pseudoaneurysm without in-stent thrombosis (Figure 5(a)). Therefore, we replaced DAPT with single antiplatelet therapy (SAPT) (only aspirin 100 mg daily). Follow-up angiography three months after Pipeline embolization confirmed complete obliteration of the pseudoaneurysm and successful endoluminal reconstruction of the damaged vessel (Figure 5(b)).

Twelve months after the Pipeline embolization, the patient's modified Rankin scale score was 0, and follow-up angiography demonstrated complete obliteration of the pseudoaneurysm. We finished administration of aspirin 12 months after the Pipeline embolization.

Discussion

This case indicates the prospective possibility of using flow-diverting stents for the treatment of pseudoaneurysms, especially for those caused following TSS. Flow-diverting stents can enable us to treat the pseudoaneurysms with preservation of the parent artery in a less invasive manner.

In TSS, life-threatening complications such as hemorrhage from ICA injuries can arise. The cavernous segments of the ICA are at risk during surgical exploration of the pituitary gland such as when removing the sellar floor, opening the sellar dura, and resecting tumors.^{14,17–21} The reported incidence of ICA injuries during TSS for pituitary tumors ranges between 0.55 and 1.1%.^{6,8,22} ICA pseudoaneurysms resulting from iatrogenic injuries during TSS are similar to blood blister-type aneurysms histologically (indicating focal artery laceration), and geographically (occurring at non-branching sites of the ICA), with the possibility for rapid enlargement and rupture with a 30–50% reported mortality rate.^{10,14,18} Although shrinkage and spontaneous resolution of intracranial pseudoaneurysms have been reported, clinical series have reported rupture rates of up to 60% prior to definitive treatment.¹ In a review by Alzhrani et al., the time of diagnosis of pseudoaneurysms after TSS injuries ranges from 2 days to 10 years postoperatively.¹⁸ Patients with ICA pseudoaneurysms present with cranial neuropathy, carotid-cavernous fistula (CCF), pituitary apoplexy, or epistaxis. Prompt angiography after initial management of acute bleeding with nasal packing allows assessment of whether there is ongoing hemorrhage and can be used to identify the presence of pseudoaneurysms or CCF. Among Michael et al.'s cohort, 23% of patients with cavernous carotid pseudoaneurysm after TSS did not show evidence of vascular injury or hemorrhage during the operation, implying likely subtle carotid injuries that were unrecognized during the surgery.⁷ Patients with a history of TSS should be immediately inspected for iatrogenic vascular

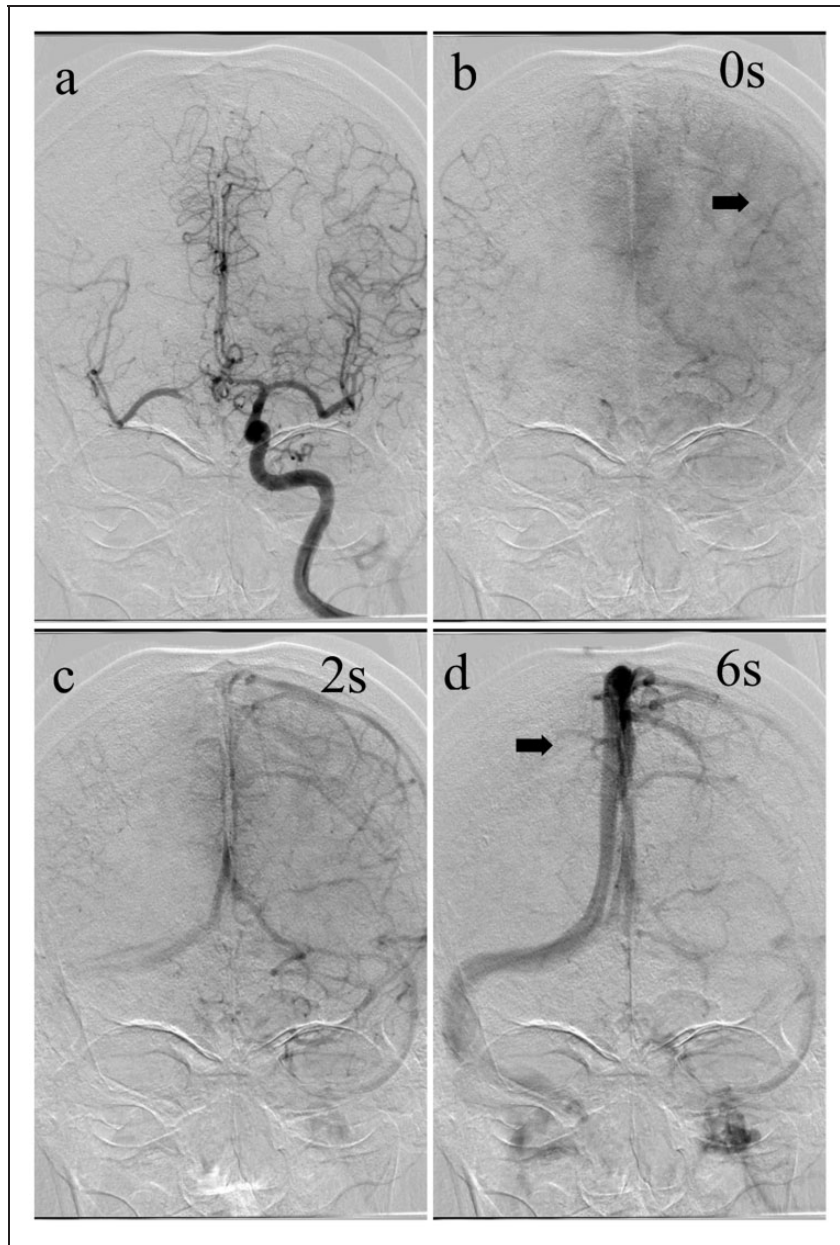


Figure 3. (a) Angiography with a Matas maneuver showing the ipsilateral anterior cerebral artery and middle cerebral artery visualized by cross-flow via the anterior communicating artery in the late arterial phase. (b) The beginning of the venous phase in the left hemisphere (black arrow) and certain cortical arteries in the right hemisphere are visible 1 s (s) after the first image; defined as 0 s. (c) The venous phase at 2 s; the cortical veins on the right hemisphere are still invisible. (d) The venous phase at 6 s; the veins are starting to fill in the right hemispheres (black arrows). This patient had a 6 s venous drainage delay.

abnormalities once they present with epistaxis, visual impairment, external ophthalmoplegia, or bruit, even if there is no evidence of injury in the ICA.²³

With regard to traditional surgical and endovascular treatments for intracranial pseudoaneurysms, parallel clipping, wrapping, external or internal trapping, carotid artery ligation, coiling, and stent-assisted coiling have been performed.^{22,23} If simple clipping or coiling is performed with preservation of the injured ICA, direct manipulation of the friable aneurysm wall is required, and there may be compromise with increased possibility of severe life-threatening intraoperative ruptures and incomplete occlusion, leading to delayed fatal

hemorrhage (epistaxis).^{2,15,23} As for trapping, revascularization by low or high flow bypass must be established, depending on collateral flow. Parent artery occlusion (PAO) may be the most reliable and definitive treatment for ICA injuries. However, PAO is an invasive and deconstructive treatment. There remains a 5–20% possibility of developing ischemic complications after PAO of the affected ICA even when sufficient compensatory collateral flow is initially confirmed on balloon occlusion test (BOT).^{24,25}

Recently, the management of this lesion has changed from an invasive vessel destructive strategy to a vessel reconstructive strategy, which only excludes the

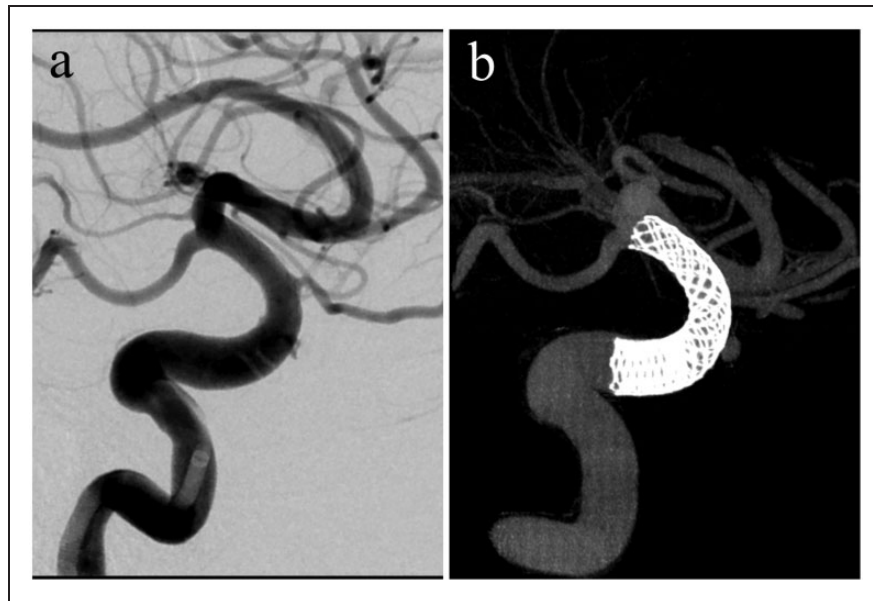


Figure 4. (a) Post-Pipeline embolization cerebral angiography showing decreased contrast intra-pseudoaneurysmal flow and (b) good apposition of the Pipeline Flex for the vessel wall in the right internal carotid artery.

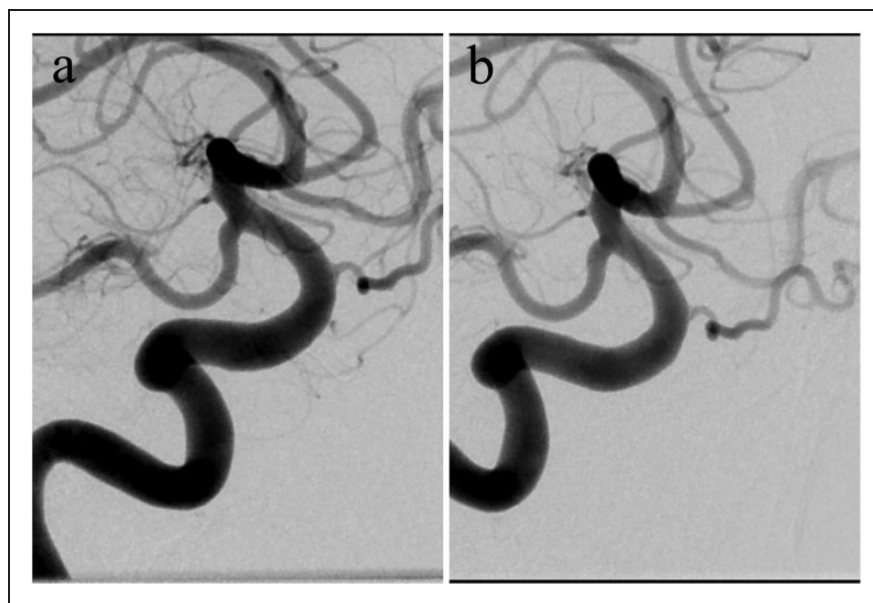


Figure 5. (a) Cerebral angiography one month after Pipeline embolization showing only contrast remaining within the pseudoaneurysm with no evidence of stenosis proximal, distal, or within the Pipeline Flex. (b) Cerebral angiography three months after Pipeline embolization showing complete obliteration of the pseudoaneurysm and no evidence of stenosis proximal, distal, or within the Pipeline Flex.

aneurysm from the circulation while maintaining vessel patency. The Pipeline Flex is a type of flow-diverting stent with endoluminal and self-expanding properties. The device is designed with greater metal surface area coverage to obtain a greater change in aneurysm hemodynamics resulting in diversion of blood flow away from the aneurysm, leading to thrombosis of the aneurysm and endothelialization of the neck of the aneurysm while maintaining the patency of the parent vessel.^{16,26,27} Recently, off-label use of the Pipeline Flex has expanded to include various aneurysmal

types such as ruptured aneurysms, posterior circulation aneurysms, small aneurysms, distal aneurysms, fusiform aneurysms, dissecting aneurysms, pseudoaneurysms, and CCF.³ Some intracranial pseudoaneurysm cases treated with such vessel-reconstructive endovascular techniques as flow-diverting stents or covered stents have been reported.^{1,2,4, 8,11,13–15,22,28} However, in addition to the lack of flexibility, tortuous anatomy at the location of the injury can prohibit adequate wall apposition of the covered stents to vessel laceration.¹¹ A flow-diverting stent enables full coverage of the

aneurysm neck without direct intra-aneurysmal manipulation with greater flexibility, adaptable radial force, and metal surface area coverage compared to that of traditional balloon-expandable or self-expandable stents.¹⁶ Sylvester et al. reviewed 98 cases of ICA injuries treated with endovascular methods after TSS.²² The rate of persistent neurological complications in the endovascular sacrifice of the ICA was 21.7%. Endoluminal reconstruction was performed by placement of covered stents (24 cases) and flow diverters (5 cases). Covered stents involved a low percentage of major technical complications (8.3%) but a high rate of technical complications (41.7%). Flow diverter placement was well tolerated with only one minor technical complication.

In this case, we performed a Matas maneuver and determined that the venous phase delay was 6 s (>4 s), although we could not confirm cross-flow via the anterior and posterior communicating artery. Chen et al. discussed venous phase delay assessment in BOT of ICA and demonstrated that their patients with a venous phase delay of >4 s could not tolerate PAO.²⁹ The venous phase delay observed when performing the Matas maneuver made us avoid PAO for our patient. Therefore, when deciding how to treat the pseudoaneurysm safely and completely, we considered only two options: Pipeline embolization or PAO with low or high flow bypass. The latter would necessitate more invasive surgery and may create more complications generally accompanying open surgery. Conversely, regarding the former method, there are multiple case reports detailing successful use of flow-diverting stents in treating intracranial pseudoaneurysms of varying etiologies, although flow-diverting stents for pseudoaneurysms are beyond the original on-label application.^{1,2,4,7,8,11,13–15,17,19–22,28,30,31} To our knowledge, there are only 11 cases reported of pseudoaneurysms caused after TSS for pituitary tumors, including ours (Table 1).^{14,17,19–22,31}

In the 11 cases, one was lost to follow-up immediately after the Pipeline embolization. Among the remaining 10 cases, a complete occlusion state was confirmed in nine and near complete occlusion in one case. There were no cases with complications and decline of modified Rankin scale due to PED (Pipeline Embolization Device (Medtronic, Neurovascular))-related causes. Given the efficiency and durability of flow-diverting stents for pseudoaneurysms based on the clinical series, we decided on treatment with flow-diverting stents even though we were unable to obtain the information on the long-term follow-up results of flow-diverting stents for pseudoaneurysms. We propose that flow-diverting stents are feasible in pseudoaneurysm cases, especially in those without sufficient collateral flow and without a contraindication for DAPT, and those with the cessation of bleeding confirmed. In addition, it may be useful for patients who are unable to withstand invasive surgical procedures.

Considering the safety of the flow-diverting stent, there is also the risk of hemorrhagic and thromboembolic complications with intra-stent clot formation and parent vessel occlusion. A recent systematic review of 2002 patients with 2243 aneurysms with Pipeline embolization for cerebral aneurysms reported that the total ischemic complication rate was 7% (95% confidence interval (CI), 6–9%), and the hemorrhagic complication rate was 5% (95% CI, 4–6%).³² At present, Pipeline embolization often necessitates DAPT administration for a certain period. Nevertheless, guidelines for the use of DAPT in Pipeline embolization, including the terms and optimal combinations of antiplatelet drugs, have not been determined. In our case study, we achieved complete occlusion of pseudoaneurysm with changing DAPT to SAPT one month after Pipeline employment, although there is a lack of evidence regarding the benefits of maintaining DAPT. Changing DAPT to SAPT early meant that we expected the progression of aneurysmal thrombosis but accepted the increased risk of thromboembolic complications of Pipeline. Tsang et al. reported two delayed ICA occlusion cases secondary to in-stent thrombosis of Pipeline embolization for pseudoaneurysms.¹³ In their report, clopidogrel was maintained only for the initial one to four weeks, and aspirin was prescribed for six months in total after surgery because the patients were constantly at risk of life-threatening bleeding from the pseudoaneurysms. Of the two cases, one had lacunar infarction 14 months after Pipeline embolization and the other remained asymptomatic 22 months after Pipeline embolization.

The limitations of flow-diverting stents for intracranial pseudoaneurysms are as follows: (1) contraindication under active bleeding, (2) persistent rebleeding possibility in the short-term after a flow-diverting stent deployment, (3) the need for DAPT after PED placement with the possibility of complicating the risk of rebleeding, and (4) the indefinite terms and optimal combinations of antiplatelet drugs. The PED cannot attenuate ongoing bleeding, especially in the setting of DAPT.^{2,4,15} Achieving hemodynamic stability with effective packing is the first step for using a flow-diverting stent. If refractory hemorrhage occurs after a flow-diverting stent deployment, endovascular or surgical parent vessel occlusion must be taken into consideration because a microcatheter cannot be navigated through the mesh of the Pipeline Flex.³

Flow-diverting stents may perform better in the treatment of ICA pseudoaneurysms, especially after TSS. However, the long-term safety and efficacy of flow-diverting stents under these conditions remain unclear. Therefore, additional case studies are required to illuminate the most effective and safe management strategies.

In conclusion, despite the possibility of short-term rebleeding and need for DAPT for a certain period, the use of flow-diverting stents is a feasible vessel-sparing option in the management of intracranial ICA

Table 1. The clinical course of flow-diverting stents for pseudoaneurysms following an injury during transsphenoidal surgery.

References	Age (years)	Sex	Preangiography presentation	Prior treatment	PA negative in initial angiography	Confirmation of pseudoaneurysm	Injury location in the ICA	BOT	Good collateral flow	Time from TSS to stent placement	Flow-diverting stent	Duration of DAPT	mRS final FU	Mx clinical FU	Mx angiographical FU	Occlusion state
Our case	62	M	Intraoperative hemorrhage	No	No	Three days after TSS	Cavernous segment	No	No	Nine days	PED	One month	0	12 Months	12 Months	Complete
Ali Karadag ¹⁹	56	M	Intraoperative hemorrhage	No	No	The same day as TSS	Cavernous segment	No	Not reported	Not reported	PED	Three months	0	Three months	Not reported	Complete
Daniela Iancu ³¹	47	F	CCF (proptosis, chemosis, double vision, right oculomotor nerve palsy)	No	No	Five days after TSS	Unknown	Yes	No	Five days	Silk	Three months	Not reported	Not reported	12 Months	Complete
Mario Zanaty ²¹	55	M	Intraoperative hemorrhage	No	No	The same day as TSS	Immediately proximal to Acho A	No	Not reported	One week	PED	Not reported	Not reported	Not reported	Not reported	Complete
Andrea Giorgianni ¹⁷	66	M	Intraoperative hemorrhage	No	No	The same day as TSS	Cavernous segment	Yes	No	The same day	PED	One month	0	Two weeks	Six months	Complete
Mairaj T. Sami ²⁰	Elderly	Not reported	Hemoptysis after surgery	Yes (coiling)	No	20 Years after TSS	Cavernous segment	Yes	No	Not reported	PED	Six months	0	Not reported	12 Months	Near complete
Peter T. Sylvester ²²	Young adult	Not reported	Intraoperative hemorrhage	No	No	Several days after TSS	Cavernous segment	Yes	No	Not reported	PED	Six months	0	Not reported	Six months	Complete
	21	M	Epistaxis after surgery	No	Yes (the same day as TSS)	Five days after TSS	Cavernous segment	No	Yes	15 Days	PED	Not reported	0	16 Months	Six months	Complete
	78	F	Epistaxis and extrusion through the nose	Yes (coiling)	No	20 Years after TSS	Cavernous segment	No	Yes	20 Years	PED	Lost to follow-up	Lost to follow-up	One day	Lost to follow-up	Lost to follow-up
John D Nerva ¹⁶	30s	Not reported	Intraoperative hemorrhage	No	Yes (the same day as TSS)	Nine days after TSS	Cavernous segment	Not reported	Not reported	15 Days	PED	Not reported	0	Nine months	Four months	Complete
	60s	Not reported	Intraoperative hemorrhage	No	No	Not reported	Cavernous segment	Not reported	Not reported	Four days	PED and coils	Not reported	6 (died of PED-unrelated causes)	Three months	Not reported	Complete

CCF: carotid-cavernous fistula; PA: pseudoaneurysm; TSS: transsphenoidal surgery; ICA: internal carotid artery; Acho A: anterior choroidal artery; BOT: balloon occlusion test; PED: Pipeline embolization device; DAPT: dual antiplatelet therapy; mRS: modified Rankin scale; FU: follow-up; Mx: maximum; M: male; F: female.

pseudoaneurysms after TSS injuries if intraoperative hemodynamic stability is achieved with effective packing.

Declaration of conflicting interests

The authors declared no potential conflicts of interest with respect to the research, authorship, and/or publication of this article.

Funding

The authors received no financial support for the research, authorship, and/or publication of this article.

Informed consent

The patient has consented to the submission of this case report to the journal.

ORCID iD

Yasuhiko Nariai  <https://orcid.org/0000-0001-6391-1002>

References

1. Amenta PS, Starke RM, Jabbour PM, et al. Successful treatment of a traumatic carotid pseudoaneurysm with the Pipeline stent: case report and review of the literature. *Surg Neurol Int* 2012; 3: 160.
2. Ambekar S, Sharma M, Smith D, et al. Successful treatment of iatrogenic vertebral pseudoaneurysm using pipeline embolization device. *Case Rep Vasc Med* 2014; 2014: 341748.
3. Patel PD, Chalouhi N, Atallah E, et al. Off-label uses of the Pipeline embolization device: a review of the literature. *Neurosurg Focus* 2017; 42: E4.
4. Kadkhodayan Y, Shetty VS, Blackburn SL, et al. Pipeline embolization device and subsequent vessel sacrifice for treatment of a bleeding carotid pseudoaneurysm at the skull base: a case report. *J Neurointerv Surg* 2013; 5: e31.
5. Laws ER Jr. Vascular complications of transsphenoidal surgery. *Pituitary* 1999; 2: 163–170.
6. Ciceri EF, Regna-Gladin C, Erbetta A, et al. Iatrogenic intracranial pseudoaneurysms: neuroradiological and therapeutical considerations, including endovascular options. *Neurol Sci* 2006; 27: 317–322.
7. Fu M, Patel T, Baehring JM, et al. Cavernous carotid pseudoaneurysm following transsphenoidal surgery. *J Neuroimaging* 2013; 23: 319–325.
8. Zhang Y, Tian Z, Li C, et al. A modified endovascular treatment protocol for iatrogenic internal carotid artery injuries following endoscopic endonasal surgery. *J Neurosurg*. Epub ahead of print 25 January 2019. DOI: 10.3171/2018.8.JNS181048.
9. Maras D, Lioupis C, Magoufis G, et al. Covered stent-graft treatment of traumatic internal carotid artery pseudoaneurysms: a review. *Cardiovasc Intervent Radiol* 2006; 29: 958–968.
10. Medel R, Crowley RW, Hamilton DK, et al. Endovascular obliteration of an intracranial pseudoaneurysm: the utility of Onyx. *J Neurosurg Pediatr* 2009; 4: 445–448.
11. Griauzde J, Gemmete JJ, Pandey AS, et al. Emergency reconstructive endovascular management of intraoperative complications involving the internal carotid artery from trans-sphenoidal surgery. *J Neurointerv Surg* 2015; 7: 67–71.
12. Griauzde J, Ravindra VM, Chaudhary N, et al. Use of the Pipeline embolization device in the treatment of iatrogenic intracranial vascular injuries: a bi-institutional experience. *Neurosurg Focus* 2017; 42: E9.
13. Tsang AC, Leung KM, Lee R, et al. Primary endovascular treatment of post-irradiated carotid pseudoaneurysm at the skull base with the Pipeline embolization device. *J Neurointerv Surg* 2015; 7: 603–607.
14. Nerva JD, Morton RP, Levitt MR, et al. Pipeline embolization device as primary treatment for blister aneurysms and iatrogenic pseudoaneurysms of the internal carotid artery. *J Neurointerv Surg* 2015; 7: 210–216.
15. Dolati P, Eichberg DG, Thomas A, et al. Application of Pipeline embolization device for iatrogenic pseudoaneurysms of the extracranial vertebral artery: a case report and systematic review of the literature. *Cureus* 2015; 7: e356.
16. Leung GK, Tsang AC and Lui WM. Pipeline embolization device for intracranial aneurysm: a systematic review. *Clin Neuroradiol* 2012; 22: 295–303.
17. Giorgianni A, Pozzi F, Pellegrino C, et al. Emergency placement of a flow diverter stent for an iatrogenic internal carotid artery injury during endoscopic pituitary surgery. *World Neurosurg* 2019; 122: 376–379.
18. Alzhrani G, Sivakumar W, Park MS, et al. Delayed complications after transsphenoidal surgery for pituitary adenomas. *World Neurosurg* 2018; 109: 233–241.
19. Karadag A, Kinali B, Ugur O, et al. A case of pseudoaneurysm of the internal carotid artery following endoscopic endonasal pituitary surgery: endovascular treatment with flow-diverting stent implantation. *Acta Medica (Hradec Kralove)* 2017; 60: 89–92.
20. Sami MT, Gattozzi DA, Soliman HM, et al. Use of Pipeline embolization device for the treatment of traumatic intracranial pseudoaneurysms: case series and review of cases from literature. *Clin Neurol Neurosurg* 2018; 169: 154–160.
21. Zanaty M, Chalouhi N, Jabbour P, et al. The unusual angiographic course of intracranial pseudoaneurysms. *Asian J Neurosurg* 2015; 10: 327–330.
22. Sylvester PT, Moran CJ, Derdeyn CP, et al. Endovascular management of internal carotid artery injuries secondary to endonasal surgery: case series and review of the literature. *J Neurosurg* 2016; 125: 1256–1276.
23. Raymond J, Hardy J, Czepko R, et al. Arterial injuries in transsphenoidal surgery for pituitary adenoma; the role of angiography and endovascular treatment. *AJNR Am J Neuroradiol* 1997; 18: 655–665.
24. Arustamyan SR, Yakovlev SB, Shakhnovich AR, et al. Results of deconstructive endovascular surgery in treatment of large and giant intracranial aneurysms. *Zh Vopr Neurokhir Im N N Burdenko* 2016; 80: 22–31.
25. Standard SC, Ahuja A, Guterman LR, et al. Balloon test occlusion of the internal carotid artery with hypotensive challenge. *AJNR Am J Neuroradiol* 1995; 16: 1453–1458.
26. Fiorella D, Lylyk P, Szikora I, et al. Curative cerebrovascular reconstruction with the Pipeline embolization device: the emergence of definitive endovascular therapy for intracranial aneurysms. *J Neurointerv Surg* 2009; 1: 56–65.

27. Murthy SB, Shah J, Mangat HS, et al. Treatment of intracranial aneurysms with Pipeline embolization device: newer applications and technical advances. *Curr Treat Options Neurol* 2016; 18: 16.
28. Shakir HJ, Garson AD, Sorkin GC, et al. Combined use of covered stent and flow diversion to seal iatrogenic carotid injury with vessel preservation during transsphenoidal endoscopic resection of clival tumor. *Surg Neurol Int* 2014; 5: 81.
29. Chen Z, Hu LN, Zhu H, et al. Validity of venous phase delay assessment in balloon occlusion test of internal carotid artery. *Exp Ther Med* 2019; 17: 948–952.
30. Dong X, Zhang Y, Zhang JM, et al. Endovascular stent-graft placement for an iatrogenic internal carotid artery pseudoaneurysm following transsphenoidal surgery. *Neurol India* 2012; 60: 670–672.
31. Iancu D, Lum C, Ahmed ME, et al. Flow diversion in the treatment of carotid injury and carotid-cavernous fistula after transsphenoidal surgery. *Interv Neuroradiol* 2015; 21: 346–350.
32. Saber H, Kherallah RY, Hadied MO, et al. Antiplatelet therapy and the risk of ischemic and hemorrhagic complications associated with Pipeline embolization of cerebral aneurysms: a systematic review and pooled analysis. *J Neurointerv Surg* 2019; 11: 362–366.