



ELSEVIER

Available online at  
**ScienceDirect**  
[www.sciencedirect.com](http://www.sciencedirect.com)

Elsevier Masson France  
**EM|consulte**  
[www.em-consulte.com](http://www.em-consulte.com)



## Original article

# Leukoencephalopathy with calcifications and cysts (LCC): 5 cases and literature review

O. Osman<sup>a</sup>, P. Labrune<sup>b</sup>, P. Reiner<sup>a</sup>, M. Sarov<sup>c</sup>, G. Nasser<sup>d</sup>, F. Riant<sup>e</sup>,  
 E. Tournier-lasserve<sup>e</sup>, H. Chabriat<sup>a</sup>, C. Denier<sup>c,f,\*</sup>

<sup>a</sup> Department of neurology, Lariboisière hospital, Assistance publique–Hôpitaux de Paris (AP–HP), 75010 Paris, France

<sup>b</sup> Department of pediatrics (PL), Bécélère hospital, AP–HP, 92140 Clamart, France

<sup>c</sup> Department of neurology, Bicêtre hospital, AP–HP, 94270 Le Kremlin-Bicêtre, France

<sup>d</sup> Department of neuroradiology, Bicêtre hospital, AP–HP, 94270 Le Kremlin-Bicêtre, France

<sup>e</sup> Department of molecular genetics, Lariboisière hospital, AP–HP, 75010 Paris, France

<sup>f</sup> Paris-Sud university, Paris Saclay, 91400 Orsay, France

## INFO ARTICLE

## Article history:

Received 19 March 2019

Received in revised form

3 June 2019

Accepted 4 June 2019

Available online xxx

## Keywords:

Leukoencephalopathy

Intracranial calcifications and cysts

Small vessel disease

## ABSTRACT

**Introduction.** – Leukoencephalopathy with calcifications and cysts (LCC) is a rare autosomal recessive cerebral angiomas-like microangiopathy characterized by diffuse and asymmetric white-matter lesions associated with multiple calcifications and cysts. The disease is caused by SNORD118 mutations. The entire clinical spectrum of LCC is not yet fully determined. **Material and methods.** – To define the clinical spectrum of LCC, we analyzed data from recently diagnosed cases and from the literature. Both clinical and imaging features from our five LCC cases harboring compound heterozygous SNORD118 mutations were presented and all cases reported in the literature reviewed.

**Results.** – Ninety-two LCC cases including our five patients were identified. Consanguinity was rare (4%), and 97% of cases were symptomatic. Mean age of first clinical manifestations was  $16.1 \pm 16.1$  years (range 1 month–71 years) and was earlier in men ( $10.3 \pm 14.3$  years) than in women ( $20.2 \pm 22.8$  years) ( $P = 0.02$ ). The main inaugural symptoms were seizures (36%; mean age at onset:  $5.2 \pm 9.5$  years) and progressive neurological symptoms including ataxia, dystonia and spasticity (26%;  $27.8 \pm 23.6$  years). Intracranial hypertension was less frequently observed (14%), mostly in adults (mean age  $31.5 \pm 13.2$  years). Ischemic or hemorrhagic strokes were inaugural symptoms in two adults (2%). During follow-up, most patients developed progressive extrapyramidal, cerebellar and pyramidal signs (83%), cognitive decline (56%), seizures (37%), intracranial hypertension (30%) or stroke (2%).

**Conclusion.** – In LCC, the clinical spectrum is largely heterogeneous and the course of the disease appears highly variable in contrast to other hereditary cerebral small vessel diseases.

© 2019 Elsevier Masson SAS. All rights reserved.

\* Corresponding author at: Department of neurology, centre hospitalier de Bicêtre, 78, rue du Général-Leclerc, 94275 Le Kremlin-Bicêtre cedex, France.

E-mail address: [christian.denier@aphp.fr](mailto:christian.denier@aphp.fr) (C. Denier).

<https://doi.org/10.1016/j.neurol.2019.06.006>

0035-3787/© 2019 Elsevier Masson SAS. All rights reserved.

## 1. Introduction

Leukoencephalopathy with intracranial calcifications and cysts (LCC), also known as Labrune syndrome, is a rare hereditary cerebral microangiopathy characterized by a triad of neuroimaging findings including diffuse and asymmetric leukoencephalopathy, extensive calcifications and parenchymal brain cysts [1]. Clinical presentations of LCC include progressive pyramidal or cerebellar signs, slower cognitive performance and seizures. These clinical manifestations have been shown to result from a cerebral microangiopathy characterized by angiomatous-like blood vessels associated with gliosis, in which Rosenthal fiber deposition appears as the most noticeable pathological feature [1]. LCC has long been associated with another rare genetic disorder, “Coats plus” disease, with which LCC shares the cerebral imaging features [2]. However, conversely to LCC, “Coats plus” syndrome is characterized by extraneurological systemic lesions such as bilateral retinal telangiectasias and exudations (as observed in “Coats” disease), intrauterine growth retardation, skeletal and hematological abnormalities, recurrent gastrointestinal bleedings, sparse hair and dysplastic nails [3]. Recently, recessively inherited compound heterozygous mutations in CTC1, the gene that encodes the GTS telomere maintenance complex component 1, have been reported in “Coats plus” patients [4,5]. More recently, biallelic SNORD118 mutations have been described in unrelated families with LCC, which has led to these two disorders being considered as two separate entities [6,7].

Because only a few cases of LCC have been extensively reported, characteristics of the disease remain unclear. Herein, we report five of our own genetically confirmed LCC cases and review the literature to collect clinical and imaging data from all previous case reports in order to better delineate clinical and radiological features of this rare cerebral autosomal recessive disorder.

## 2. Materials and methods

Five LCC patients harboring both the most typical radiological features and a compound heterozygous SNORD118 mutation

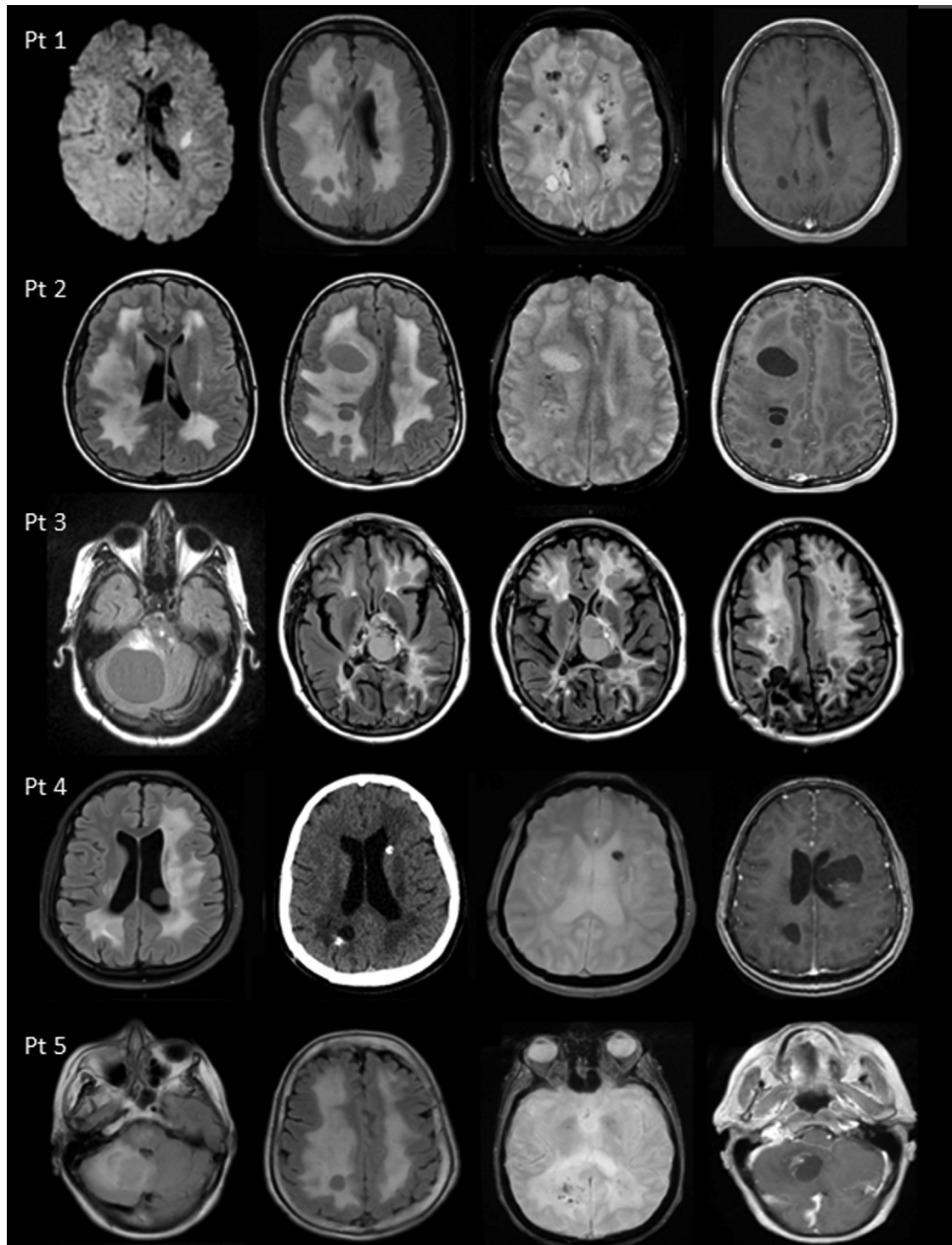
have been diagnosed in two referral centers in Paris, France (Bicêtre and Lariboisière Hospitals) over the last few decades. Two of these patients have been very briefly reported in the past (Labrune et al., 1996 and Wargon et al., 2008). Imaging and clinical data from all these cases have been analyzed as well as all data available from the English-language literature up to January 2019. For this review, a Medline search was performed crossing the words “leukoencephalopathy” with “cysts” and “calcifications”. Eighty articles were identified. All LCC cases were selected from these articles or mentioned in their associated bibliographies, based on the presence of the typical and pathognomonic triad associating leukoencephalopathy, cerebral cysts and calcifications, in the absence of extraneurological lesions (including a normal ophthalmologic examination) and/or the identification of a compound heterozygous SNORD118 mutations.

Statistical analyses were performed with R (<http://www.r-project.org>) on the complete sample of patients. Between-group comparisons were performed with t-tests or Wilcoxon tests for numeric variables depending on their distributions. Chi<sup>2</sup> tests or Fisher tests were used for categorical variables and comparisons of proportions. For all analyses, P-values < 0.05 were considered to be significant.

Whole exome sequencing was performed for our patients at IntegraGen platform (Evry, France) using SureSelect XT Human All Exon V5–50 Mb kits (Agilent). Image analysis, base calling and variant annotation were performed by IntegraGen’s internal bioinformatics pipeline, as previously described [8]. Only missense, nonsense, insertion/deletion variants or variants potentially affecting splicing (located  $\pm 4$  bp from exon-intron junctions for SNPs  $\pm 30$  bp for indels) were considered. Variants absent from the IntegraGen exome database (150 French exomes), and variants reported with a minor allele frequency higher than 0.1% in 1000 Genomes Project or EVS (Exome Variant Server) were excluded. An IGV tool was used to screen visually the .bam files in order to search for regions with low coverage or unreported variants. Sanger sequencing of SNORD118 was done for all patients to confirm the presence of the variants. The SNORD118 variants identified in our five cases are reported in Table 1.

**Table 1 – SNORD118 variants identified in our five cases.**

	Variants detected	Frequency in gnomAD	Previously reported
Patient 1	n.3C>T	0.15%	Jenkinson et al., 2016 [6]
	n.72A>G	0.0069%	Jenkinson et al., 2016 [6]
Patient 2	n.74G>T	Absent	Novel
	n.*9C>T	0.19%	Jenkinson et al., 2016 [6]
Patient 3	n.72A>G	0.0069%	Jenkinson et al., 2016 [6]
	n.92C>T	0.10%	Novel
Patient 4	n.72A>G	0.0069%	Jenkinson et al., 2016 [6]
	n.39_40insT	0.011%	Novel
Patient 5	n.131C>T	0.012%	Novel
	n.*9C>T	0.19%	Jenkinson et al., 2016 [6]



**Fig. 1 – Neuroradiological aspects of our five patients: patients no. 1 to 5 (Pt 1 to Pt 5) are respectively illustrated on first to fifth lanes. First lane: patient 1: sudden R-hemiparesis revealing ischemic stroke at 30 years old, on diffusion MR sequence, associated with leukopathy on FLAIR, multiple calcifications on T2\* and contrast enhancement of cystic walls (first to fourth column). Second lane: patient 2: intracranial hypertension in a 28-year-old woman with leukopathy and cysts on FLAIR, calcifications on T2\* and contrast enhancement of cystic walls on T1 sequences. Third lane: patient 3: generalized seizure at 11 years of age revealing multiple cysts and asymmetric leukopathy on FLAIR sequences. Fourth lane: patient 4: seizure in a 18-year-old woman unravelling leukopathy, calcifications and cysts on FLAIR, CT-scan, T2\* and T1 sequences. Fifth lane: patient 5: asymmetric progressive cerebellar ataxia in a 60-year-old woman with leukopathy and cysts on FLAIR, calcifications on T2\* and contrast enhancement of cystic walls on T1 sequences.**

### 3. Results

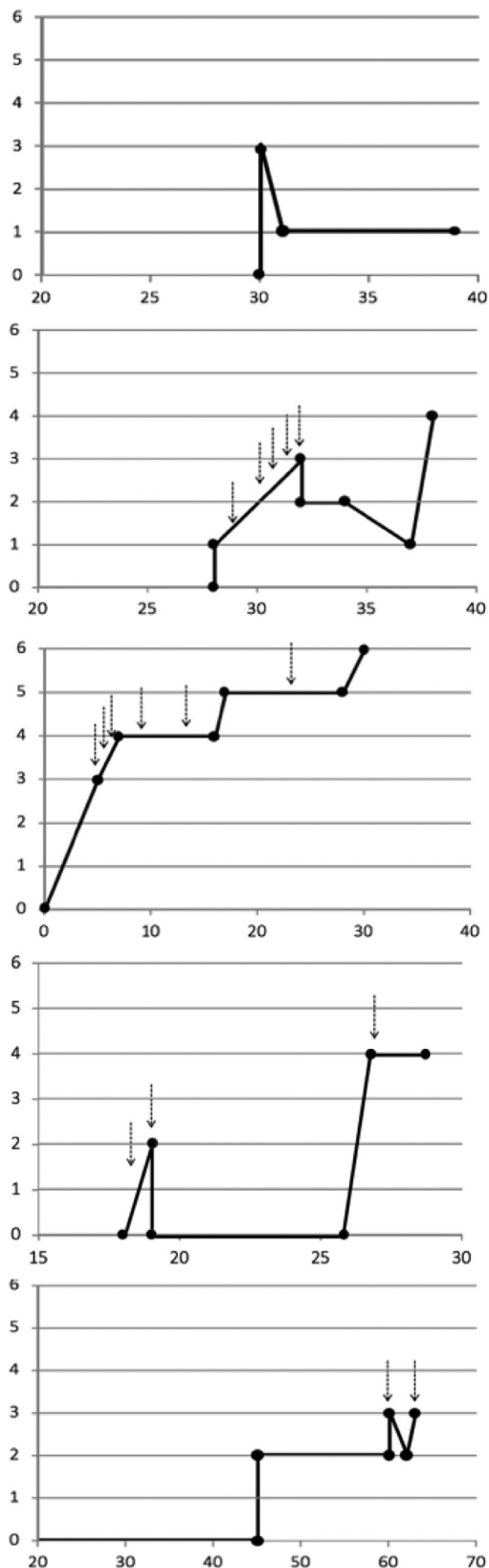
#### 3.1. Clinical reports of five personal LCC SNORD118 mutations carriers

##### 3.1.1. Case 1

A 30-year-old Caucasian woman presented with a sudden right hemiparesis. She was born from healthy and unrelated parents. Previously, she had only suffered from attacks of migraine without aura for the last 5 years. MRI showed a small recent subcortical infarct associated with bilateral and asymmetric white-matter lesions, multiple calcifications and a cystic formation on the right parietal lobe with a ring-contrast enhancement (Fig. 1, first lane). Ophthalmological examination did not show any retinal abnormality. Both magnetic resonance (MR) and computed tomography (CT) angiography, cervical and transcranial ultrasound examination, electrocardiogram, transesophageal echocardiography, and thoracic and abdominal CT-scans were normal. Serum levels of antinuclear antibodies, anticardiolipids, anti-B2GP1 antibodies, antithrombin III, protein C and S, prothrombin and factor V mutations, cholesterol, and homocystein were negative or within the normal limits. Moreover, serological tests for cysticercosis, human immunodeficiency virus (HIV1/2), treponema pallidum and TPHA/VDRL were negative. The patient was treated by aspirin after the stroke event. She recovered and presented only with a mild residual paresis of the right arm (modified Rankin scale (mRS) score = 1). Genetic analysis disclosed two compound heterozygous SNORD118 mutations; n.3C>T and n.72A>G. After a 10-year follow-up period, no new neurological manifestation was observed (Fig. 2).

##### 3.1.2. Case 2

A 28-year-old Caucasian woman born from healthy and non-consanguineous parents suffered from progressive onset headaches of over several weeks that were finally related to intracranial hypertension (ICH). She had no personal or family medical history. Physical examination only showed pyramidal reflexes. Cerebral magnetic resonance imaging (MRI) revealed severe bilateral and asymmetric white-matter lesions associated with extensive calcifications and multiple cysts with ring-enhancement of their wall (Fig. 1, second lane). Standard biological tests and thoraco-abdominal CT-scan were normal. Ophthalmological examination was also normal. Despite the negativity of all investigations looking for parasites (toxoplasmosis, cysticercosis, bilharzia, distomatosis, hydatidosis, paragonimiasis, gnasthotomiasis, histoplasmosis, coccidioidomycosis) and the absence of meningitis, antiparasitic treatment was initiated with no clinical or radiological improvement. Despite repeated surgical cystic punctures, clinical worsening was observed with progressive motor deficit and epileptic seizures that were attributed to the appearance of additional cysts. Genetic analysis disclosed two compound heterozygous SNORD118 mutations; n.74G>T and n.\*9C>T. At 38 years of age, after a period of 10 years, the patient had a mRS at 4 (Fig. 2).



**Fig. 2 – Clinical courses in our five LCC patients: patients (Pt 1 to Pt 5) are represented according to age and handicap (Rankin score from 0 (symptom free) to 6 (death) (age is represented on the x-axis, Rankin score on the y-axis). Arrows represent surgical interventions (mostly because of intracranial hypertension).**

### 3.1.3. Case 3

This Caucasian woman had a first generalized seizure at 11 years of age. She was born after an uneventful pregnancy from unrelated and healthy parents. At 4 years of age she had a skull radiograph that fortuitously showed intracranial calcifications. She only had slurred speech (justifying speech therapy) at neurological examination and ophthalmological investigations were normal. Cerebral MRI showed bilateral and asymmetric white-matter lesions, multiple calcifications and cysts (Fig. 1, third lane). One year later, a voluminous cerebellar cyst occurred that was surgically removed because of clinical signs of increased intracranial pressure. Histological examination revealed angiomatous proliferative microangiopathy. Over the next 15 years, a progressive clinical worsening occurred. The patient developed spastic tetraparesis, dystonia, bulbar symptoms, visual deficiency and a significant cognitive decline. SNORD118 screening revealed compound heterozygous mutations; n.72A>G and n.92C>T. Repeated ICH related to cysts' enlargement were observed and numerous surgical procedures were performed (Fig. 2). The patient died at the age of 30 years after a fall from her wheelchair and a cervical fracture.

### 3.1.4. Case no. 4

A 18-year-old Asian woman presented with generalized seizures. She had no personal or family medical history and was born from unrelated parents after an uneventful pregnancy. Cerebral MRI showed many cysts, calcifications and diffuse asymmetric white-matter lesions (Fig. 1, fourth lane). Ophthalmologic examination was normal. Despite the negativity of all investigations looking for parasites (toxoplasmosis, bilharzia, amebiasis, cysticercosis, echinococcosis, paragonimiasis) and normal cerebrospinal fluid analysis, antiparasite treatment was administered with no improvement in the clinical presentation or cerebral lesions. Over the following years, new cysts progressively appeared, responsible for motor deficits and aphasia. Many cystic punctures and repeated surgical resections were performed. At 30 years old, after a period of 12 years, mRS was at 4 (Fig. 2). SNORD118 screening revealed compound heterozygous mutations; n.72A>G and n.39\_40insT.

### 3.1.5. Case no. 5

A 60-year-old Caucasian woman presented with a progressive cerebellar ataxia that she had had for a few years. She was born from healthy and unrelated parents. Idiopathic Parkinson's disease was diagnosed at 47 years of age with a good response to dopamine treatment. At 60 years old, neurological examination showed extrapyramidal and cerebellar signs. Cerebral MRI showed multiple cysts, one of which was voluminous and located in the right cerebellum. Bilateral and asymmetric white-matter lesions with many calcifications were detected (Fig. 1, fifth lane). A cerebellar cystic puncture was performed to reduce an acute episode of ICH during the course of the disease. Histological examination was not conclusive. Multiple biological tests were negative including those looking for different infectious agents (toxoplasmosis, bilharzia, cysticercosis, echinococcosis, HIV1-2). Thoracic and abdominal CT-scans were normal. Ophthalmological examination did not show any retinal abnormality. The

cerebellar cyst was removed after a new episode of ICH caused by its recurrence. SNORD118 screening revealed compound heterozygous mutations; n.131C>T and n.\*9C>T. After two years of follow-up, only slight parkinsonian signs were observed (mRS = 2) (Fig. 2).

## 3.2. Analyses of our five personal cases and cases from the literature

We identified 87 other LCC cases in the English literature up to January 2019. Including our five patients, out of these 92 LCC patients, 59 harbored SNORD118 disease-causing mutations and 33 did not have genetic analysis (mostly because these cases were published before LCC gene identification). There was no difference between the groups of patients with or without identified SNORD118 mutations concerning sex ratio, age at diagnosis, presence of consanguinity, developmental delay or the distribution of the signs revealing the disease. The 92 LCC patients were considered as a whole. The main clinical and imaging features of all cases ( $n = 92$ ) including our cases are presented in Table 2. Female/Male ratio was 1.42. Evidence of consanguinity was obvious in only 4% of cases (Table 2).

The mean age of first clinical manifestations was 16.1 years, but ranged from 1 month to 71 years. They occurred earlier in men (10.3 years) than in women (20.2 years,  $P = 0.02$ ). Diagnosis was often delayed with a mean age at diagnosis of 31.2 years. LCC diagnosis was rarely made in asymptomatic cases (age from 5 to 55 years; fortuitous diagnosis on MRI). No specific comorbidity was found associated with LCC.

The inaugural symptoms and clinical course of the disease are summarized in Table 2. Epileptic seizures were the first clinical manifestations in one-third of cases (36%) and were observed at a mean age of 5.2 years. Progressive neurological deficits were reported at onset in 26% of patients at a median age of 27.8 years. They consisted in more or less focal motor, sensory or visual deficits, dystonia, ataxia or aphasia related to the location of cysts. Less frequently, in 14% of cases, developmental delay and intracranial signs of hypertension were inaugural signs of LCC. Intracranial hypertension was almost constant in adults, contrary to development retardation observed in children. One ischemic and one hemorrhagic stroke were the inaugural manifestations in two different adult patients (2%) (Tables 2 and 3).

The analysis of the clinical course of the disease showed that slow progression of various neurological deficits was frequent (79% of cases). During follow-up, almost half of the cases presented with cognitive impairment (45%). Epileptic seizures and ICH were also frequently observed, in 38% and 30% of published cases, respectively. Two patients developed symptomatic hemorrhagic strokes during the course of the disease (2%).

To treat cystic expansion often causing ICH, oral or intravenous corticosteroids or acetazolamide were used in a few cases but with no real efficiency or only transient improvement. When surgical treatment was needed and undertaken, an immediate improvement of symptoms was observed. Different surgical techniques were used, such as cystic puncture, cystic resection, cysto-ventriculo-peritoneal by-pass or craniotomy. Due to the recurrence of cysts, use of Ommaya reservoir has been reported. Biweekly infusion of

**Table 2 – Clinical characteristics of our five LCC patients pooled with the 87 previously published cases.**

Clinical characteristics	Patients (n = 92)
Female/Male (number, %)	54/38 (59%/41%)
Age at disease onset: mean age (range)	16.1 ± 20.2 (0–71)
Female	20.2 ± 22.8 (0–71)
Male	10.3 ± 14.3 (0–54)
Age at diagnosis: mean age (range)	31.2 ± 19.1 (5–71)
Parental consanguinity (number (%) when available)	3/80 (4%) [6,10]
Developmental delay (number, %) when available	36/80 (45%) [6–9,13–21]
Prematurity (number, %) when available	6/29 (21%) [6,16,19,23,24]
Signs revealing the disease (mean age ± SD, range and sex ratio)	
Epilepsy	n = 33 (36%) [1,6,7,11,12,19,20,24–28] (5.2 ± 9.5 y (0–24); males: 52%)
Progressive neurological deficit	n = 24 (26%) focal motor [10,20,29–31] or visual [14] deficits, aphasia [18], dystonia [1,10,23], ataxia [10,14,18,32] (27.8 ± 23.6 y (2–70); males: 29%)
Developmental delay	n = 13 (14%) [6,24] (0.6 ± 1.5 y (0–4); males: 54%)
Intracranial hypertension	n = 13 (14%) [6,7,9,10,12,16,19,22,30,33–35] (31.5 ± 13.2 y (14–55); males: 31%)
Stroke	n = 2 (2%) [13,15] (50.5 ± 29.0 (30–71); males: 0%)
Incidental finding	n = 3 (3%) [6,17,22] (31.6 ± 25.2 y (5–55); males: 0%)
New events during the disease course	
Progressive neurological deficit	72 (79%) aphasia [20,32,33], focal motor deficit [10–13,18,19,21,24,26,30,32,36,37], dystonia [11,18,27,37], ataxia [9–11,19,37] 41 (45%) [1,6,7,9–12,18–20,24–26,32,33,36]
Cognitive impairment	41 (45%) [1,6,7,9–12,18–20,24–26,32,33,36]
Epilepsy	35 (38%) [1,6,7,9,11,12,19–21,23–27,32,36,38]
Intracranial signs of hypertension	27 (30%) [1,6,7,9,10,12,13,16,19–22,29–34,37]
Stroke	2 (2%) [9,12]
Treatment (when available)	
Surgical treatment (cystic puncture or resection, or cysto-ventriculo-peritoneal by-pass, craniotomy) (with Ommaya reservoir because of cysts recurrence)	n = 28 [1,7,9,11,13,16,18–22,26,29–37] (n = 2 [11])
Anti-epileptic	n = 14 [1,7,12,21,23,24,26,27,32,38]
Corticoid and acetazolamide	n = 7 [1,7,17,22,32]
Other treatment	
Antiplatelet	n = 1 [15]
Anticoagulant	n = 2 [9,32]
Bevacizumab	n = 1 [39]

bevacizumab for more than one year showed clinical improvement in one patient (Tables 2 and 3). Additional symptomatic treatments such as anti-epileptic or analgic were used in most cases.

One patient of the cohort was treated with antiplatelet medications for 10 years after an ischemic stroke and had no hemorrhagic complication (case 1). Another one was treated with anticoagulant medication after an episode of deep venous thrombosis and developed a fatal intracranial hematoma [9].

#### 4. Discussion

Clinical presentation of LCC patients is heterogenous, as illustrated by our five LCC patients. Symptoms generally appear in childhood and young adulthood but the first signs of the disease may occur at an advanced age. Epileptic seizures were the most common inaugural sign but many other symptoms due to the development of cysts, such as ICH and various focal neurological signs, may occur. The exact origin of cognitive impairment, frequently observed, remains unclear: recurrent cysts and/or the accumulation of white-matter lesions might be involved. Symptomatic ischemic or hemorrhagic strokes can exist, but represent rare clinical events. Our data suggest that the early onset of first symptoms is possibly related to worse prognosis [1,10–12]. In contrast,

adult-onset cases often develop a less aggressive form of LCC, probably because of a slower development of cerebral cysts over several years that remain asymptomatic for a long time [13,14]. The wide variability in the age of onset of the disease and its evolution may be related to genetic variants with different phenotypic consequences. For example, it has been previously reported that homozygosity for some SNORD118 “hypomorphic” variants were associated with no disease or later onset [6].

The existence of ischemic and hemorrhagic events, with extended negative investigations, may imply that, like other hereditary small vessel diseases such as CADASIL, CARASIL, HERNs, cerebrotretinal angiopathy with COL4A1 or familial angiopathy amyloid, LCC might predispose patients to strokes. Because symptomatic ischemic and hemorrhagic strokes are rare in LCC, no recommendation can yet be made concerning the benefit and risk of antithrombotic or anticoagulant medication in primary or secondary prevention, knowing that the LCC microangiopathy is characterized by angioma-like blood vessels.

This study has some limitations. Firstly, because of the rarity of this disease, data were collected retrospectively, mostly from case reports, with no systematic clinical or radiological evaluation during follow-up and there may be possible reporting bias. A prospective cohort is thus needed for describing the variable course of LCC in more detail. Secondly,

**Table 3 – Summary of our five cases and the previously reported LCC patients, with their main clinical characteristics (sex, age at onset, symptoms and clinical course).**

	Sex (M/F)	Consanguinity	Age at first symptom	Age at diagnostic	Prematurity	Developmental delay	Symptom revealing LCC	New symptoms during evolution ICH/PND/Seizures/Stroke
Patient 1 <sup>a</sup>	F	–	30 y	30 y	–	+	Stroke	– + – –
Patient 2 <sup>a</sup>	F	–	28 y	28 y	–	+	ICH	+ + + –
Patient 3 <sup>a</sup>	F	–	11 y	11 y	+	–	Epilepsy	+ + + –
Patient 4 <sup>a</sup>	F	–	18 y	18 y	–	+	Epilepsy	– + + –
Patient 5 <sup>a</sup>	F	–	60 y	60 y	–	+	PND	+ + – –
Banks et al.	F	nr	65 y	71 y	nr	nr	Stroke	+ + – +
Berry-Candelario et al.	M	–	24 y	24 y	+	+	ICH	+ + – –
Bertotti et al.	M	–	22 y	30 y	–	–	ICH	+ + – –
Brenner et al.	F	–	1 m	NN	–	–	Epilepsy	– + + –
Coeytaux et al.	F	–	69 y	69 y	–	+	PND	– + – –
Corboy et al.	F	–	44 y	44 y	–	+	ICH	+ + + +
Daglioglu et al.	M	–	26 y	26 y	–	–	PND	+ + – –
Gulati et al.	M	nr	31 y	36 y	nr	nr	PND	– + + –
Kaffenburger et al.	F	–	59 y	59 y	–	+	PND	– + – –
Kleinschmidt et al.	F	nr	–	55 y	nr	+	Incidental finding	– – – –
Labrune et al.	M	–	5 y	5 y	–	–	PND	– + + –
Labrune et al.	F	nr	3 m	8 y	–	–	Epilepsy	+ + + –
Li et al.	F	nr	28 y	30 y	nr	nr	PND	+ + – –
Liu et al.	F	–	34 y	36 y	nr	nr	PND	+ + – –
Liu et al.	F	nr	19 y	19 y	nr	nr	ICH	+ + – –
Marelli et al.	F	–	27 y	27 y	nr	+	ICH	+ + – –
Marelli et al.	M	–	12 y	45 y	+	+	Epilepsy	– + + –
Nagae-Poetscher et al.	F	–	2 y	9 y	–	+	PND	– + – –
Nagae-Poetscher et al.	F	+	14 y	14 y	–	+	ICH	+ + – –
Ogles et al.	F	+	25 y	25 y	–	+	PND	+ + – –
Ogles et al.	F	–	3 m	18 y	–	–	Epilepsy	– – + –
Ooba et al.	M	nr	2 m	25 y	–	–	Epilepsy	– + + –
Osman et al.	F	–	2 y	42 y	+	–	PND	– + + –
Pessoa et al.	M	–	24 y	31 y	–	–	Epilepsy	– + + –
Sener et al.	M	–	15 y	19 y	–	+	Epilepsy	+ + + –
Stephani et al.	F	–	70 y	70 y	–	–	PND	+ + + –
Ummer et al.	M	nr	50 y	50 y	nr	nr	ICH	+ + – –
Wang et al.	M	nr	19 y	19 y	nr	nr	PND	+ + – –
Jenkinson et al. (F172) <sup>a</sup>	M	–	8 w	nr	nr	+	Epilepsy	– – + –
Jenkinson et al. (F278) <sup>a</sup>	M	–	1 y	nr	nr	+	Epilepsy	– + + –
Jenkinson et al. (F281) <sup>a</sup>	M	–	4 y	nr	nr	–	Other	– + – –
Jenkinson et al. (F285) <sup>a</sup>	M	–	12 y	nr	nr	–	Epilepsy	– + + –
Jenkinson et al. (F309) <sup>a</sup>	F	–	2 y	nr	nr	+	PND	– + – –
Jenkinson et al. (F330) <sup>a</sup>	M	–	3 y	nr	nr	–	Other	– + – –
Jenkinson et al. (F331_1) <sup>a</sup>	F	–	2 y	nr	nr	–	Epilepsy	– + – –
Jenkinson et al. (F331_2) <sup>a</sup>	F	–	5 m	nr	nr	+	Epilepsy	– + – –
Jenkinson et al. (F334) <sup>a</sup>	F	–	6 y	nr	nr	–	Other	– + – –
Jenkinson et al. (F337) <sup>a</sup>	M	–	18 m	nr	nr	+	Epilepsy	– – + –
Jenkinson et al. (F343) <sup>a</sup>	M	–	9 y	nr	nr	–	PND	+ – – –
Jenkinson et al. (F344) <sup>a</sup>	M	+	7 w	nr	nr	–	Epilepsy	– + + –
Jenkinson et al. (F362_1) <sup>a</sup>	F	–	6 m	nr	nr	+	Developmental delay	– – – –
Jenkinson et al. (F362_2) <sup>a</sup>	F	–	18 m	nr	nr	+	Developmental delay	– – – –
Jenkinson et al. (F362_3) <sup>a</sup>	M	–	6 m	nr	nr	+	Developmental delay	– – – –
Jenkinson et al. (F414) <sup>a</sup>	M	–	25 y	nr	nr	–	ICH	+ + – –
Jenkinson et al. (F426_1) <sup>a</sup>	M	–	6 m	nr	nr	+	Developmental delay	– + – –
Jenkinson et al. (F426_2) <sup>a</sup>	M	–	6 m	nr	nr	+	Developmental delay	– + – –
Jenkinson et al. (F433) <sup>a</sup>	M	–	54 y	nr	nr	–	PND	– + – –

**Table 3 (Continued)**

	Sex (M/F)	Consanguinity	Age at first symptom	Age at diagnostic	Prematurity	Developmental delay	Symptom revealing LCC	New symptoms during evolution ICH/PND/Seizures/Stroke
Jenkinson et al. (F445) <sup>a</sup>	F	–	6 m	nr	nr	–	Epilepsy	– + + –
Jenkinson et al. (F446) <sup>a</sup>	M	+	10 m	nr	nr	–	Epilepsy	– + + –
Jenkinson et al. (F454_1) <sup>a</sup>	F	–	–	5 y	nr	–	Incidental finding	– + – –
Jenkinson et al. (F454_2) <sup>a</sup>	F	–	7 m	nr	nr	+	Epilepsy	– + + –
Jenkinson et al. (F465) <sup>a</sup>	M	–	15 m	nr	nr	+	Epilepsy	– + – –
Jenkinson et al. (F521_1) <sup>a</sup>	F	–	12 m	nr	nr	+	Developmental delay	– – – –
Jenkinson et al. (F521_2) <sup>a</sup>	M	–	6 m	nr	nr	+	Developmental delay	– – – –
Jenkinson et al. (F551) <sup>a</sup>	F	–	nr	nr	nr	–	PND	– + – –
Jenkinson et al. (F564) <sup>a</sup>	F	–	9 m	nr	nr	+	Developmental delay	– + – –
Jenkinson et al. (F691) <sup>a</sup>	M	–	4 m	nr	nr	+	Developmental delay	– – – –
Jenkinson et al. (F730) <sup>a</sup>	F	–	2 m	nr	nr	+	Epilepsy	– – + –
Jenkinson et al. (F766) <sup>a</sup>	F	–	12 y	nr	nr	–	PND	– + – –
Jenkinson et al. (F780_1) <sup>a</sup>	F	–	7 y	nr	+	+	PND	– + + –
Jenkinson et al. (F780_2) <sup>a</sup>	F	–	Nr	6 y	nr	+	Developmental delay	– – – –
Jenkinson et al. (F819_1) <sup>a</sup>	M	–	nr	nr	nr	+	Epilepsy	– + + –
Jenkinson et al. (F819_2) <sup>a</sup>	F	–	nr	nr	nr	–	Epilepsy	– – + –
Jenkinson et al. (F906) <sup>a</sup>	M	–	18 m	nr	nr	+	Developmental delay	– + – –
Jenkinson et al. (F1127) <sup>a</sup>	M	–	6 m	nr	nr	+	Developmental delay	– – – –
Jenkinson et al. (F1172) <sup>a</sup>	F	–	50 y	nr	nr	–	PND	– + – –
Jenkinson et al. (F1288) <sup>a</sup>	F	–	3 y	nr	nr	–	PND	– + – –
Jenkinson et al. (F1424) <sup>a</sup>	F	–	6 m	nr	nr	–	Epilepsy	– + – –
Jenkinson et al. (F1445) <sup>a</sup>	F	–	10 y	nr	nr	–	PND	– + – –
Iwama et al. <sup>a</sup>	F	–	45 y	nr	nr	–	ICH	+ + – –
Iwama et al. <sup>a</sup>	F	–	53 y	nr	nr	–	PND	– + + –
Iwama et al. <sup>a</sup>	F	–	11 m	nr	nr	+	Epilepsy	+ + + –
Iwama et al. <sup>a</sup>	M	–	nr	nr	nr	nr	NN	nr nr nr –
Iwama et al. <sup>a</sup>	M	–	1 m	nr	nr	+	Epilepsy	+ + + –
Iwama et al. <sup>a</sup>	M	–	9 y	nr	nr	+	PND	– + – –
Iwama et al. <sup>a</sup>	F	–	37 y	nr	nr	–	ICH	+ + – –
Iwama et al. <sup>a</sup>	M	–	1 y	nr	nr	+	Epilepsy	– – + –
Armstrong et al.	F	–	30 m	32 y	nr	–	Epilepsy	– + + –
Hermens et al. <sup>a</sup>	M	–	11 m	9 y	+	–	Epilepsy	– + + –
Hermens et al. <sup>a</sup>	F	–	nr	4 y	–	–	Developmental delay	– – – –
Ma et al.	F	–	–	35 y	–	+	Incidental finding	– – – –
Ma et al.	F	–	20 y	20 y	nr	+	ICH	+ – – –
Novo et al.	F	nr	55 y	55 y	nr	nr	ICH	+ – – –
Taglia et al. <sup>a</sup>	M	nr	2 m	23 y	nr	nr	Epilepsy	– + + –
Taglia et al. <sup>a</sup>	M	nr	nr	nr	nr	nr	Epilepsy	– + + –
Iwasaki et al. <sup>a</sup>	F	–	4 y	61 y	–	+	Epilepsy	+ + + +
Villar-Quiles	F	nr	42 y	42 y	nr	nr	Epilepsy	– – – –

Sex: male/female; nr: not reported; ICH: intracranial hypertension; PND: progressive neurological deficit.

<sup>a</sup> If SNORD118 mutations have been identified.

because most cases in the literature were published prior to the discovery of the SNORD118 gene, we have included cases which were necessarily not diagnosed by genetic testing. For this reason, in order to reduce this potential bias, all cases

were selected based on the presence of the typical and striking pathognomonic radiological triad and absence of extraneurological symptoms (including a normal ophthalmological examination).



## 5. Conclusion

In conclusion, the present data support that the diagnosis of LCC should be suggested in cases of white-matter lesions associated with cerebral cysts and calcifications, regardless of the patient's age and even in the absence of a family history of neurological disorder. LCC should also be suspected when cystic parasitosis is suspected but cannot be confirmed.

## Contributions

Drs Osman and Denier had full access to all of the data in the study and take responsibility for the integrity of the data and the accuracy of the data analysis. Concept and design: Denier. Acquisition, analysis, or interpretation of data: All authors including Tournier-Lasserre and Riant for genetic analysis. Drafting of the manuscript: Osman, Chabriat and Denier. Critical revision of the manuscript for important intellectual content: All authors. Statistical analysis: Osman and Denier. Supervision: Denier.

## Ethics approval

In accordance with the French legislation, the study did not need approval by an ethics committee nor written informed consent from patients, since it only implied retrospective analysis of anonymized data prospectively collected as part of routine clinical care.

## Fundings

No funding was received for this research.

## Disclosure of interest

The authors declare that they have no competing interest.

## REFERENCES

- [1] Labrune P, Lacroix C, Goutieres F, et al. Extensive brain calcifications, leukodystrophy, and formation of parenchymal cysts: a new progressive disorder due to diffuse cerebral microangiopathy. *Neurology* 1996;46:1297–301.
- [2] Linnankivi T, Valanne L, Paetau A, et al. Cerebroretinal microangiopathy with calcifications and cysts. *Neurology* 2006;67:1437–43.
- [3] Tolmie JL, Browne BH, McGettrick PM, Stephenson JB. A familial syndrome with coats' reaction retinal angiomas, hair and nail defects and intracranial calcification. *Eye* 1988;2(Pt 3):297–303.
- [4] Anderson BH, Kasher PR, Mayer J, et al. Mutations in CTC1, encoding conserved telomere maintenance component 1, cause Coats plus. *Nat Genet* 2012;44:338–42.
- [5] Polvi A, Linnankivi T, Kivela T, et al. Mutations in CTC1, encoding the CTS telomere maintenance complex component 1, cause cerebroretinal microangiopathy with calcifications and cysts. *Am J Hum Genet* 2012;90:540–9.
- [6] Jenkinson EM, Rodero MP, Kasher PR, et al. Mutations in SNORD118 cause the cerebral microangiopathy leukoencephalopathy with calcifications and cysts. *Nat Genet* 2016;48:1185–92.
- [7] Iwama K, Mizuguchi T, Takashi JI, et al. Identification of novel SNORD118 mutations in seven patients with leukoencephalopathy with brain calcifications and cysts. *Clin Genet* 2017;92:180–7. <http://dx.doi.org/10.1111/cge.12991>.
- [8] Verdura E, Hervé D, Scharrer E, et al. Heterozygous HTRA1 mutations are associated with autosomal dominant cerebral small vessel disease. *Brain* 2015;138:2347–58.
- [9] Corboy JR, Gault J, Kleinschmidt-DeMasters BK. An adult case of leukoencephalopathy with intracranial calcifications and cysts. *Neurology* 2006;67:1890–2.
- [10] Nagae-Poetscher LM, Bibat G, Philippart M, et al. Leukoencephalopathy, cerebral calcifications, and cysts: new observations. *Neurology* 2004;62:1206–9.
- [11] Ooba H, Abe T, Hisamitsu Y, Fujiki M. Repeated cyst formation in a patient with leukoencephalopathy, cerebral calcifications, and cysts: effectiveness of stereotactic aspiration with Ommaya reservoir placement. *J Neurosurg Pediatr* 2013;12:155–9.
- [12] Iwasaki Y, Hoshino KI, Mori K, et al. Longitudinal clinical and neuro-radiological findings in a patient with leukoencephalopathy with brain calcifications and cysts (Labrune syndrome). *eNeurological Sci* 2017;8:28–30.
- [13] Banks GP, Weiss SA, Pisapia D, Willey JZ. A case of late-onset leukoencephalopathy, calcifications, and cysts presenting with intracerebral hemorrhage resembling a neoplasm. *Cerebrovasc. Dis Basel Switz* 2013;35:396–7.
- [14] Coeytaux A, Lobrinus J-A, Horvath J, Kurian M, Vargas M-I. Late onset of leukoencephalopathy with cerebral calcifications and cysts. *J Neuroradiol* 2011;38:319–20.
- [15] Wargon I, Lacour M-C, Adams D, Denier C. A small deep infarct revealing leukoencephalopathy, calcifications and cysts in an adult patient. *J Neurol Neurosurg Psychiatry* 2008;79:224–5.
- [16] Berry-Candelario J, Kasper E, Eskandar E, Chen CC. Neurosurgical management of leukoencephalopathy, cerebral calcifications, and cysts: a case report and review of literature. *Surg Neurol Int* 2011;2:160.
- [17] Kleinschmidt-DeMasters BK, Cummings TJ, Hulette CM, Morgenlander JC, Corboy JR. Adult cases of leukoencephalopathy, cerebral calcifications, and cysts: expanding the spectrum of the disorder. *J Neuropathol Exp Neurol* 2009;68:432–9.
- [18] Kaffenberger T, Valko PO, von Meyenburg J, et al. A case of late onset leukoencephalopathy with cerebral calcifications and cysts in a 59-year-old woman. *Eur J Neurol* 2009;16:278–81.
- [19] Marelli C, Savoirdo M, Fini N, et al. Late presentation of leukoencephalopathy with calcifications and cysts: report of two cases. *J Neurol Neurosurg Psychiatry* 2008;79:1303–4.
- [20] Ogles RL, Joshi CL, Miller DC, Litofsky NS, Travis MD. Leukoencephalopathy, cerebral calcifications, and cysts in two sisters. *Pediatr Neurol* 2014;51:576–9.
- [21] Sener U, Zorlu Y, Men S, Bayol U, Zapanalioglu U. Leukoencephalopathy, cerebral calcifications, and cysts. *AJNR Am J Neuroradiol* 2006;27:200–3.
- [22] Ma Y, Zhang X, Cheng C, et al. Leukoencephalopathy with calcifications and cysts: a case report. *Medicine (Baltimore)* 2017;96:e7597.
- [23] Osman NI, Lorincz MT, Hulsing KL, Gebarski SS. Leukoencephalopathy, cerebral calcifications, and cysts: case report. *Clin Neurol Neurosurg* 2012;114:806–9.

- [24] Hermens M, van der Knaap MS, Kamsteeg E-J, Willemsen MA. A brother and sister with intellectual disability and characteristic neuroimaging findings. *Eur J Paediatr Neurol* 2018. <http://dx.doi.org/10.1016/j.ejpn.2018.06.005>.
- [25] Brenner C, Del Negro MC, Borigato EMV, Miranda RV. Leukoencephalopathy with cerebral calcifications and cysts. *Neurology* 2006;66:E32.
- [26] Pessoa AL, Monteiro Ado V, Queiroz RF, Malveira GL, Kok F. Leukoencephalopathy with cerebral calcifications and cyst: Labrune syndrome. *Arq Neuropsiquiatr* 2012;70:230-1.
- [27] Taglia I, Di Donato I, De Stefano N, et al. Blood-brain barrier permeability in a patient with Labrune syndrome due to SNORD118 mutations. *Eur J Neurol* 2018;25:e86-7.
- [28] Villar-Quiles RN, Gómez-Ruiz N, Jorquera-Moya M, Matías-Guiu J, Matias-Guiu JA. Teaching NeuroImages: adult-onset leukoencephalopathy with intracranial calcifications and cysts (Labrune syndrome). *Neurology* 2017;88:e113-4.
- [29] Li Z, Han K, Yao W, Wei W, Li Y, Lan X. Adult-onset leukoencephalopathy with calcifications and cysts: focusing on hemorrhagic propensity and cysts development. *World Neurosurg* 2016;85:366e9-366e13.
- [30] Liu X, Zheng X, Sui Q, Xu W, Zee C-S. Leukoencephalopathy with cerebral calcifications and cysts: clinical and pathological features in two adults. *Acta Neurol Belg* 2016;116:47-52.
- [31] Wang Y, Cheng G, Dong C, Zhang J, Meng Y. Adult-onset leukoencephalopathy, brain calcifications and cysts: a case report. *J Med Case Rep* 2013;7:151.
- [32] Stephani C, Pfeifenbring S, Mohr A, Stadelmann C. Late-onset leukoencephalopathy with cerebral calcifications and cysts: case report and review of the literature. *BMC Neurol* 2016;16:19.
- [33] Bertotti MM, Linhares MN, Ferreira R, et al. Leukoencephalopathy, cerebral calcifications, and cysts: entity that can mimic a neoplasm. *Arq Neuropsiquiatr* 2011;69:717-22.
- [34] Ummer K, Salam KA, Noone ML, Pradeep Kumar VG, Mampilly N, Sivakumar S. Leukoencephalopathy with intracranial calcifications and cysts in an adult: case report and review of literature. *Ann Indian Acad Neurol* 2010;13:299-301.
- [35] Novo J, Lin D, Shanks M, Kocak M, Arvanitis L. A 55-year-old female with leukoencephalopathy with cerebral calcifications and cysts: case report and radiopathologic description. *Pathol Res Pract* 2017;213:1440-4.
- [36] Armstrong MJ, Hacein-Bey L, Brown H. Cerebroretinal microangiopathy with calcifications and cysts: demonstration of radiological progression. *J Comput Assist Tomogr* 2009;33:571-2.
- [37] Daglioglu E, Ergungor F, Hatipoglu HG, et al. Cerebral leukoencephalopathy with calcifications and cysts operated for signs of increased intracranial pressure: case report. *Surg Neurol* 2009;72:177-81.
- [38] Gulati A, Singh P, Ramanathan S, Khandelwal N. A case of leukoencephalopathy, cerebral calcifications and cysts. *Ann Indian Acad Neurol* 2011;14:310-2.
- [39] Fay AJ, King AA, Shimony JS, Crow YJ, Brunstrom-Hernandez JE. Treatment of leukoencephalopathy with calcifications and cysts with bevacizumab. *Pediatr Neurol* 2017;71:56-9.