


Journal Pre-proof

Mechanical thrombectomy for middle cerebral artery occlusion suspected of ovarian hyperstimulation syndrome.

Atsushi Kuwano, Yuichi Kubota, Taku Nonaka, Satoru Miyao, Hidetoshi Nakamoto, Takakazu Kawamata



PII: S1878-8750(19)32453-2

DOI: <https://doi.org/10.1016/j.wneu.2019.09.023>

Reference: WNEU 13322

To appear in: *World Neurosurgery*

Received Date: 28 July 2019

Revised Date: 4 September 2019

Accepted Date: 5 September 2019

Please cite this article as: Kuwano A, Kubota Y, Nonaka T, Miyao S, Nakamoto H, Kawamata T, Mechanical thrombectomy for middle cerebral artery occlusion suspected of ovarian hyperstimulation syndrome., *World Neurosurgery* (2019), doi: <https://doi.org/10.1016/j.wneu.2019.09.023>.

This is a PDF file of an article that has undergone enhancements after acceptance, such as the addition of a cover page and metadata, and formatting for readability, but it is not yet the definitive version of record. This version will undergo additional copyediting, typesetting and review before it is published in its final form, but we are providing this version to give early visibility of the article. Please note that, during the production process, errors may be discovered which could affect the content, and all legal disclaimers that apply to the journal pertain.

© 2019 Published by Elsevier Inc.

Mechanical thrombectomy for middle cerebral artery occlusion suspected of ovarian hyperstimulation syndrome.

Atsushi Kuwano¹⁾²⁾, Yuichi Kubota¹⁾²⁾, Taku Nonaka¹⁾²⁾, Satoru Miyao¹⁾²⁾, Hidetoshi Nakamoto¹⁾²⁾, Takakazu Kawamata²⁾

¹⁾Department of Neurosurgery, stroke and Epilepsy Center, TMG Asaka Medical Center, Saitama, Japan

²⁾Department of Neurosurgery, Tokyo Women's Medical University, Tokyo, Japan

*Corresponding author

Yuichi Kubota, MD., D.Med.Sci

Department of Neurosurgery, stroke and Epilepsy Center, TMG Asaka Medical Center
1-134- Mizonuma, Asaka, Saitama

Phone: +81-48-466-2055

Fax: +81-48-466-2059

Email: kubota.yuichi@twmu.ac.jp

Atsushi Kuwano, MD

Department of Neurosurgery, stroke and Epilepsy Center, TMG Asaka Medical Center
1-134- Mizonuma, Asaka, Saitama

Phone: +81-48-466-2055

Fax: +81-48-466-2059

Email: cho_hunseki@yahoo.co.jp

Taku Nonaka, MD

Department of Neurosurgery, stroke and Epilepsy Center, TMG Asaka Medical Center
1-134- Mizonuma, Asaka, Saitama

Phone: +81-48-466-2055

Fax: +81-48-466-2059

Email: taku.nonaka7@gmail.com

Satoru Miyao, MD

Department of Neurosurgery, stroke and Epilepsy Center, TMG Asaka Medical Center
1-134- Mizonuma, Asaka, Saitama

Phone: +81-48-466-2055

Fax: +81-48-466-2059

Email: satoru.miyao14@gmail.com

Hidetoshi Nakamoto, MD

Department of Neurosurgery, stroke and Epilepsy Center, TMG Asaka Medical Center

1-134- Mizonuma, Asaka, Saitama

Phone: +81-48-466-2055

Fax: +81-48-466-2059

Email: hidetossimo@yahoo.co.jp

Takakazu Kawamata, MD., PhD

Department of Neurosurgery, Tokyo Women's Medical University

8-1 Kawada cho, Shinjuku, Tokyo

Phone: +81-3-3353-8111

Fax: +81-48-466-2059

Email: tkawamata@twmu.ac.jp

Highest academic degrees for all authors

Atsushi Kuwano, M.D.

Yuichi Kubota, M.D., D.Med.Sci .

Taku Nonaka, M.D.

Satoru Miyao, M.D.

Hidetoshi Nakamoto, M.D.

Takakazu Kawamata, M.D., Ph.D.

Keywords

ovarian hyperstimulation syndrome; thrombectomy; cerebral infarction

Mechanical thrombectomy for middle cerebral artery occlusion suspected of ovarian hyperstimulation syndrome. Case report and review of literature.

Atsushi Kuwano¹⁾²⁾, Yuichi Kubota¹⁾²⁾, Taku Nonaka¹⁾²⁾, Satoru Miyao¹⁾²⁾, Hidetoshi Nakamoto¹⁾²⁾, Takakazu Kawamata²⁾

¹⁾Department of Neurosurgery, stroke and Epilepsy Center, TMG Asaka Medical Center, Saitama, Japan

²⁾Department of Neurosurgery, Tokyo Women's Medical University, Tokyo, Japan

*Corresponding author:

Yuichi Kubota

Department of Neurosurgery, stroke and Epilepsy Center, TMG Asaka Medical Center
1-134- Mizonuma, Asaka, Saitama

Phone: +81-48-466-2055

Fax: +81-48-466-2059

Email:

Highest academic degrees for all authors

Yuichi Kubota, M.D., Ph.D : kubota.yuichi@twmu.ac.jp

Hidetoshi Nakamoto, M.D. : hidetossimo@yahoo.co.jp

Satoru Miyao, M.D. : satoru.miyao14@gmail.com

Takakazu Kawamata, M.D., Ph.D. : tkawamata@twmu.ac.jp

Keywords: antiepileptic drugs; poststroke epilepsy; seizure; vagal nerve stimulation

Short title: Mechanical thrombectomy for ovarian hyperstimulation syndrome.

Abstract

Background

Ovarian hyperstimulation syndrome (OHSS) is an iatrogenic disorder associated with infertility treatment. The main pathology of OHSS is intravascular dehydration and hyperestrogenemia. In mild cases, abdominal symptoms are the main symptoms, but in severe cases, thrombosis such as cerebral infarction may occur.

Case Description

A 36-year-old woman was undergoing infertility treatment in obstetrics and gynecology for infertility. She received HMG-HCG therapy and artificial insemination one week before onset, and on the day of onset she had mild abdominal distension and was suspected of OHSS. She was prescribed aspirin for prevention of thrombosis. She presented with right upper hemiparesis and aphasia. MRI showed left middle cerebral artery occlusion. We performed mechanical thrombectomy and finally got Thrombolysis in Cerebral Infarction scale (TICI) 3 recanalization. We suspected embolism as the etiology of cerebral infarction and started anticoagulation therapy. Various examinations were conducted to investigate the embolism source, but no anatomical abnormality or thrombophilia factors were observed. The patient had admitted OHSS since admission, we concluded that OHSS was suspected as the cause of this stroke.

Conclusions

We experienced the first case of mechanical thrombectomy for middle cerebral artery occlusion suspected to be caused by OHSS. It is necessary to suspect OHSS involvement if young women, especially those on infertility treatment, show neurological deficits.

Keywords

ovarian hyperstimulation syndrome; thrombectomy; cerebral infarction

Abbreviations and Acronyms

DWI-ASPECTS, diffusion weighted image-Alberta Stroke Programme Early Score

MCA, Middle Cerebral Artery

MRA, Magnetic Resonance Angiography

MRI, Magnetic Resonance Image

mRS, modified Rankin Scale

NIHSS, National Institutes of Health Stroke Scale

OHSS, Ovarian hyperstimulation syndrome

TICI, Thrombolysis in Cerebral Infarction scale

t-PA, tissue plasminogen activator

Journal Pre-proof

Introduction

Ovarian hyperstimulation syndrome (OHSS) is a rare and serious complication of infertility treatment. OHSS is an iatrogenic disorder caused by using an ovulation inducer.¹ The pathologies are intravascular dehydration and hyperestrogenemia. Moderate cases may be only electrolyte abnormality, but severe cases may cause thrombosis. Although multiple cases of cerebral infarction associated with OHSS have been reported so far, middle cerebral artery occlusion has occurred in a pregnant woman caused by OHSS, and there are almost no cases where thrombectomy has been performed. We report a case of middle cerebral artery occlusion suspected of OHSS and successfully treated with mechanical thrombectomy.

Case Report

A 36-year-old woman was undergoing infertility treatment in obstetrics and gynecology for infertility. She received HMG-HCG therapy and artificial insemination one week before onset, and on the day of onset she had mild abdominal distension and was suspected of OHSS. She was prescribed aspirin for prevention of thrombosis. She presented with right upper hemiparesis and aphasia and was transferred to another hospital for emergency department. The doctor diagnosed her as left middle cerebral artery occlusion and she was referred to our hospital for further treatment. Five hours have passed from the onset of this hospital transportation. Physical examination showed disturbance of consciousness (Glasgow Coma Scale E2V1M5), right hemiparesis (Manual Muscle Testing upper limbs 2/5, lower limbs 1/5), global aphasia, National Institutes of Health Stroke Scale (NIHSS) 27. Estradiol was 4599 pg./mL by blood test. MRI showed left middle cerebral artery M1 occlusion (Figure 1), and Diffusion Weighted Image-Alberta Stroke Programme Early Score (DWI-ASPECTS) 8/11. At the time of transportation to our hospital, five hours had passed since onset, so we could not perform tissue plasminogen activator (t-PA). In addition to being at an early onset, clinical image mismatch was recognized, so we decided to perform mechanical thrombectomy. We consulted with the family before treatment and confirmed that the treatment was given with maternal priority, although the patient may be pregnant. Angiography showed occlusion in the left middle cerebral artery at proximal region. We performed thrombectomy and finally got Thrombolysis in Cerebral Infarction scale (TICI) 3 recanalization (Figure 2). After 24 hours of treatment, right hemiparesis improved to MMT4 and aphasia moderately remained, resulting in NIHSS score 14. We suspected embolism as the etiology of cerebral infarction and started anticoagulation therapy. We performed various physiological examinations including holter electrocardiography, carotid artery ultrasound, ultrasonography of the lower limbs,

transesophageal echocardiography, and also checked blood tests such as tumor markers, coagulation function, and autoantibodies of collagen diseases to investigate the embolic sources. But no anatomical abnormality or thrombophilia factors were observed. An examination of abdominal distension, which had been observed since admission, resulted in swelling of the ovaries and ascites, leading to a diagnosis of ovarian hyperstimulation syndrome.

About a week after treatment, she fainted during rehabilitation. Ascites was markedly increased, and exacerbation of ovarian hyperstimulation syndrome was noted. She was referred to another hospital for OHSS management. She turned out to be pregnant at the next hospital, eventually she aborted for OHSS control. Then OHSS stabilized and she finally recovered to about modified Rankin Scale (mRS) 2 at six months of treatment.

Discussion

OHSS is an iatrogenic disorder associated with infertility treatment.¹ By using follicle stimulating agents and ovulation stimulating agents, the follicle overgrown and OHSS is triggered. According to previous reports, OHSS is estimated to develop in 0.3% to 6% of infertility treatments.² OHSS is classified as mild, moderate or severe from clinical symptoms. Mild cases are mainly abdominal symptoms such as diarrhea, vomiting and abdominal distension, but severe cases may show thrombosis. Risk factors reported to be associated with OHSS include young age, polycystic ovary-like patients, low body mass index, polycystic ovarian syndrome, history of previous OHSS, and estradiol high.³ The pathophysiology of thrombosis has not been accurately elucidated, it is thought that intravascular dehydration and hyperestrogenemia are involved. Ovary is stimulated by administering HMG, and hyperestrogenemia occurs. In addition, luteinizing hormone is secreted by HMG administration, and ovulation is promoted by HCG administration, so that the follicle is luteinized and VEGF and angiotensin are secreted. VEGF and angiotensin enhance permeability and are thought to contribute to intravascular dehydration.⁴⁻⁶ Treatment of OHSS is usually symptomatic therapy. Antiplatelets may be given to pregnant thrombosis, but no cure for thrombosis has been established. If symptomatic treatment cannot control OHSS, abortion may eventually be required.⁷

In this case, it was a cerebral infarction of a young woman with a low vascular risk, and the cause was carefully examined. She was free of thrombophilia factors, atrial fibrillation and other anatomical abnormalities such as shunt disease. Risk factors for OHSS include youth, elevated estradiol, and hCG administration. Since OHSS was

recognized from the time of admission after having conducted various cause tests, it was finally determined that OHSS could be considered as the cause of cerebral infarction.

In the first place, thrombosis due to intravascular dehydration and hyperestrogenemia tends to cause venous thrombosis. However, this time she developed a cerebral infarction. The thrombosis associated with OHSS is said to be 75% for venous thrombosis and 25% for arterial thrombosis.⁸ We performed transesophageal echocardiography in the cause search and confirmed that she had no patent foramen ovale, but shunt disease such as pulmonary arteriovenous fistula may have been hidden. In fact, the thrombus recovered was a red thrombus, so the vein thrombus has passed through the shunt site, which may cause cerebral infarction. The thrombus was a red thrombus, but the component was mainly platelets. Generally, arterial thrombus is said to be mainly platelets, and venous thrombus is said to be mainly fibrin. However, there is also a report that venous thrombus is rich in platelets as well as arterial thrombosis, and it is difficult to determine whether the thrombus is arterial thrombosis or venous thrombosis with the thrombus component alone.⁹

There are several reports of thrombectomy for pregnant women as in this case.¹⁰ The prognosis of the pregnant woman who had thrombectomy was as good as mRS2 or more at the stage after half a year of treatment as in this case. Among reports, few reports have been found that OHSS is considered to be the cause of cerebral infarction in pregnant women. This report is the first report of thrombectomy for a cerebral infarction suspected to be caused by OHSS.

With regard to OHSS aggravation after thrombectomy and eventually termination for OHSS control, it is necessary to always consider the possibility of pregnancy during the course. Although the frequency of abortion is not high, abortion may be necessary to protect the mother as in this case.

Conclusion

We experienced the first case of mechanical thrombectomy for middle cerebral artery occlusion suspected to be caused by OHSS. It is necessary to suspect OHSS involvement if young women, especially those on infertility treatment, show neurological deficits. In addition, even if the patient is a pregnant woman, if it is indicated, we should perform thrombectomy. To clarify the pathogenesis thrombus formation associated with OHSS, we need to accumulate more cases. This case tells us that this condition is more commonly seen in the current era of aggressive infertility management.

Figure legends

Figure 1.

MRA (Magnetic Resonance Angiography) shows left MCA (Middle Cerebral Artery) occlusion. (A)

DWI shows infarct images in MCA area. (B and C)

Figure 2

Angiography shows left MCA occlusion. (A)

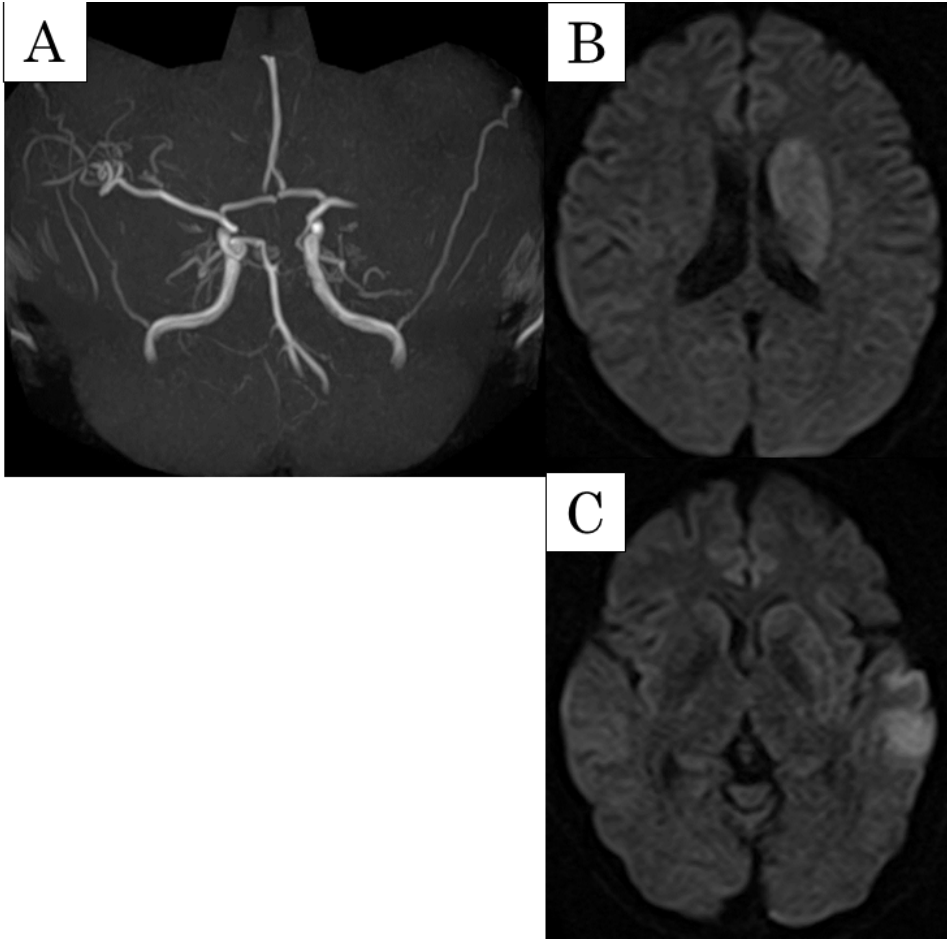
The recanalization of TICI3 was obtained by thrombectomy. (B)

References

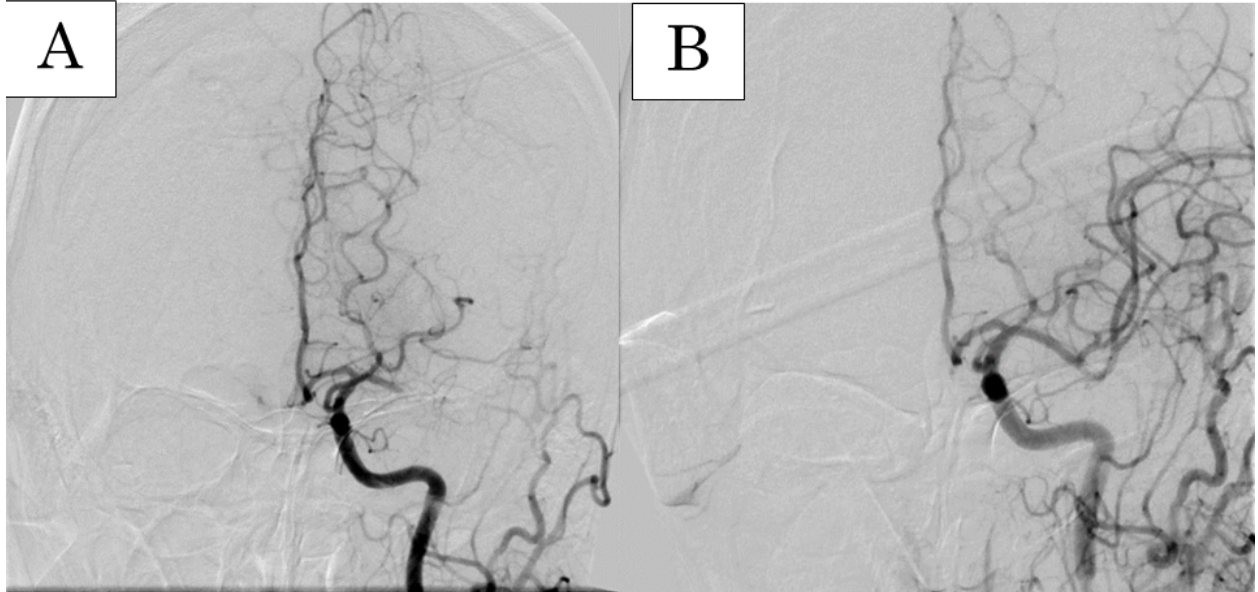
1. Mor YS, Schenker JG. Ovarian hyperstimulation syndrome and thrombotic events. *Am J Reprod Immunol.* 2014;72(6): 541-548. <https://doi.org/10.1111/aji.12310>.
2. Qazi A, Ahmed AN, Qazi MP, Usman F, Ahmad A. Ischaemic stroke with ovarian hyperstimulation syndrome. *JPMA The Journal of the Pakistan Medical Association.* 2008;58(7): 411-413.
3. Practice Committee of American Society for Reproductive M. Ovarian hyperstimulation syndrome. *Fertil Steril.* 2008;90(5 Suppl): S188-193. <https://doi.org/10.1016/j.fertnstert.2008.08.034>.
4. Pellicer A, Albert C, Mercader A, Bonilla-Musoles F, Remohi J, Simon C. The pathogenesis of ovarian hyperstimulation syndrome: in vivo studies investigating the role of interleukin-1beta, interleukin-6, and vascular endothelial growth factor. *Fertil Steril.* 1999;71(3): 482-489.
5. Whelan JG, 3rd, Vlahos NF. The ovarian hyperstimulation syndrome. *Fertil Steril.*

2000;73(5): 883-896.

6. Naredi N, Talwar P, Sandeep K. VEGF antagonist for the prevention of ovarian hyperstimulation syndrome: Current status. *Medical journal, Armed Forces India*. 2014;70(1): 58-63. <https://doi.org/10.1016/j.mjafi.2012.03.005>.
7. Namavar Jahromi BM, Parsanezhad MM, Shomali ZM, et al. Ovarian Hyperstimulation Syndrome: A Narrative Review of Its Pathophysiology, Risk Factors, Prevention, Classification, and Management. *Iranian journal of medical sciences*. 2018;43(3): 248-260.
8. Stewart JA, Hamilton PJ, Murdoch AP. Upper limb thrombosis associated with assisted conception treatment. *Human Reproduction*. 1997;12(10): 2174-2175. <https://doi.org/10.1093/humrep/12.10.2174>.
9. Takahashi M, Yamashita A, Moriguchi-Goto S, et al. Critical role of von Willebrand factor and platelet interaction in venous thromboembolism. *Histology and histopathology*. 2009;24(11): 1391-1398. <https://doi.org/10.14670/hh-24.1391>.
10. Watanabe TT, Ichijo M, Kamata T. Uneventful Pregnancy and Delivery after Thrombolysis Plus Thrombectomy for Acute Ischemic Stroke: Case Study and Literature Review. *J Stroke Cerebrovasc Dis*. 2019;28(1): 70-75. <https://doi.org/10.1016/j.jstrokecerebrovasdis.2018.09.002>.



Journal



Journal

Abbreviations and Acronyms

DWI-ASPECTS, diffusion weighted image-Alberta Stroke Programme Early Score

MCA, Middle Cerebral Artery

MRA, Magnetic Resonance Angiography

MRI, Magnetic Resonance Image

mRS, modified Rankin Scale

NIHSS, National Institutes of Health Stroke Scale

OHSS, Ovarian hyperstimulation syndrome

TICI, Thrombolysis in Cerebral Infarction scale

t-PA, tissue plasminogen activator

Journal Pre-proof