

# Childhood Small Vessel Primary Angiitis of the Central Nervous System: A Treatable Cause of Super-refractory Status Epilepticus

Journal of Child Neurology  
1-6

© The Author(s) 2019

Article reuse guidelines:

sagepub.com/journals-permissions

DOI: 10.1177/0883073819872579

journals.sagepub.com/home/jcn

Michelle Chiu, MD<sup>1</sup> , and Anita Datta, MD, FRCPC<sup>1</sup> 

## Abstract

Childhood primary angiitis of the central nervous system (cPACNS) is a rare inflammatory disease of brain vessels. The small vessel subtype is diagnosed on brain biopsy and often presents with cognitive and behavioral changes, headaches, and seizures. However, there are few reported cases of super-refractory status epilepticus in children. We present a case of small vessel cPACNS complicated by super-refractory status epilepticus requiring burst suppression for 4 weeks in addition to multiple antiseizure medications and the ketogenic diet. Our patient was also treated with intravenous and oral steroids, intravenous immunoglobulin, and cyclophosphamide before starting maintenance therapy with mycophenolate mofetil. After prolonged rehabilitation, he recovered almost completely and has a normal neurologic examination with rare epileptiform activity on electroencephalogram (EEG). This is one of the longest cases of status epilepticus in small vessel cPACNS in the literature. We illustrate that super-refractory status epilepticus can be the first manifestation of small vessel cPACNS in previously healthy children and that symptomatic management of seizures with concurrent immunosuppression to treat the underlying pathology resulted in favorable neurologic outcomes.

## Keywords

pediatric, refractory, seizures, status epilepticus, EEG, autoimmune

Received December 17, 2018. Received revised June 9, 2019. Accepted for publication July 11, 2019.

Childhood primary angiitis of the central nervous system (cPACNS) is a rare inflammatory disease of cerebral vessels resulting in neurologic or psychiatric symptoms in previously healthy children. The small vessel subtype affects small muscular arteries, arterioles, and capillaries. It is diagnosed on brain biopsy based on histologic findings of non-necrotizing, lymphocytic predominant vasculitis in the absence of systemic illness.<sup>1</sup> Other supportive findings include an inflammatory cerebrospinal fluid profile, elevated inflammatory markers, nonspecific magnetic resonance imaging (MRI) multifocal hyperintensities and normal vascular imaging.<sup>2</sup>

The clinical presentation of small vessel cPACNS is heterogeneous, with female predominance and median age of 10 years.<sup>3</sup> Most commonly, it presents with cognitive and behavioral changes, headaches, and seizures including status epilepticus.<sup>3</sup> However, there are few reported cases of super-refractory status epilepticus.

## Methods

We report a case of cPACNS that was complicated by super-refractory status epilepticus. The details of the case and related diagnostics were reviewed by the authors. A PubMed search was performed using the keywords *small-vessel vasculitis*, *super-refractory status epilepticus*,

*status epilepticus and small-vessel vasculitis*, and *seizures and vasculitis* from 1971 to the present. We reviewed all identified papers and contacted corresponding authors for details if needed. Informed consent for treatment was obtained in accordance with hospital policies.

## Case Report

### Initial Presentation

Our patient is a previously healthy 11-year-old boy who presented with new-onset generalized tonic clonic seizures in the context of fever. Initial examination was unremarkable. Bloodwork revealed normal chemistry, inflammatory markers, and toxicology screen. The cerebrospinal fluid showed lymphocyte-predominant pleocytosis with normal glucose and protein. Computed tomography of the head was normal.

<sup>1</sup> University of British Columbia and BC Children's Hospital, Division of Neurology, Department of Pediatrics, Vancouver, BC, Canada

### Corresponding Author:

Anita Datta, MD, FRCPC, CSCN Diplomate (EEG), Pediatric Neurologist and Epileptologist, BC Children's Hospital, 4480 Oak Street, Vancouver, BC, Canada, V6 H 3V4.

Email: anita.datta@cw.bc.ca

He was admitted with the working diagnosis of infectious encephalitis, but his confusion worsened on the ward despite empiric antibiotic and antiviral therapy.

### *Super-refractory Status Epilepticus*

A routine electroencephalography (EEG) on day 2 of admission was performed in order to rule out subclinical seizures in the context of agitation and altered mental status. It demonstrated continuous generalized frontal predominant slowing consistent with a mild encephalopathy of nonspecific etiology.

As his mental status continued to deteriorate, a repeat routine EEG was performed 2 days later that demonstrated frequent generalized high-amplitude frontal predominant rhythmic delta activity of 0.5-2 Hz of intermediate duration (1-5 minutes). In addition, there were electrographic seizures lasting for 30 seconds to 1 minute. The seizures had multifocal onset from the right temporal, left temporal, and bilateral frontal regions and evolved in frequency and morphology without clinical correlate (Figure 1).

Owing to the presence of subclinical seizures, our patient was transferred to the pediatric intensive care unit for continuous EEG monitoring. He was electively intubated and commenced on a midazolam infusion, but his multifocal subclinical seizures continued and ketamine infusion was also started.

As subclinical seizures subsided, ketamine was discontinued, resulting in continuous generalized frontal predominant rhythmic delta activity lasting for 6 hours, followed by continuous frontal predominant generalized spike wave discharges ranging from 0.5 to 4 Hz. This later evolved to continuous generalized periodic discharges of 0.5 to 2 Hz that were sharply contoured. Ketamine was restarted and pentobarbital was initiated, and the EEG changed to a burst suppression pattern. The bursts ranged from 1 to 20 seconds, and periods of suppression varied from 15 seconds to 5 minutes. Attempts to decrease ketamine and pentobarbital led to continuous generalized spike wave activity followed by generalized periodic discharges.

He remained in super-refractory status epilepticus, requiring burst suppression for 4 weeks with intravenous infusions. Midazolam was weaned by day 25 and pentobarbital was discontinued on day 27 because the patient developed a diffuse rash, which was thought to be drug related. The burst suppression pattern was lost and EEG showed multifocal spikes and sharp waves, predominantly in the temporal and occipital regions, and frequent subclinical seizures arising independently from the right and left temporal regions.

With propofol and ketamine, then isoflurane and ketamine, the burst suppression pattern resumed. As isoflurane was weaned, there were frequent multifocal spikes and sharp waves, predominantly in the right frontal region and occipital head regions. Subclinical seizures developed from the right frontal region lasting for 1 to 3 minutes. A midazolam infusion was reinitiated, leading to continuous generalized slowing. After 48 hours, infusions were gradually weaned without further seizures, and the patient started to become more alert.

In addition, he was tried on 8 maintenance antiseizure medications: valproic acid, phenobarbital, lacosamide, topiramate, perampanel, clobazam, stiripentol (Figure 2). The ketogenic diet with a 4:1 ratio was also started, but effective ketosis was difficult to achieve because of his multiple infusions. His median beta-hydroxybutyrate level was 1.8.

### *Diagnosis and Management of Small-Vessel cPACNS*

Extensive infectious, autoimmune, and metabolic workup was unremarkable. Empiric intravenous methylprednisolone pulse was administered for possible neuroinflammatory brain disease after his second lumbar puncture ruled out an active CNS infection. Brain MRI on day 4 and 7 of admission revealed nonspecific fluid attenuated inversion recovery hyperintensity in the periventricular white matter and frontal operculum. There was no diffusion restriction or enhancement, nor any vessel abnormalities (Figure 3).

On day 10 of admission, our patient underwent a brain biopsy confirming small vessel cPACNS. He was treated with immunosuppressive therapies based on a consensus protocol,<sup>3</sup> including continued induction therapy with intravenous methylprednisolone pulses, long-term oral steroids, intravenous immunoglobulin, and cyclophosphamide. Repeat MRI at 3 weeks showed postoperative change from his right frontal craniotomy, without new areas of signal change.

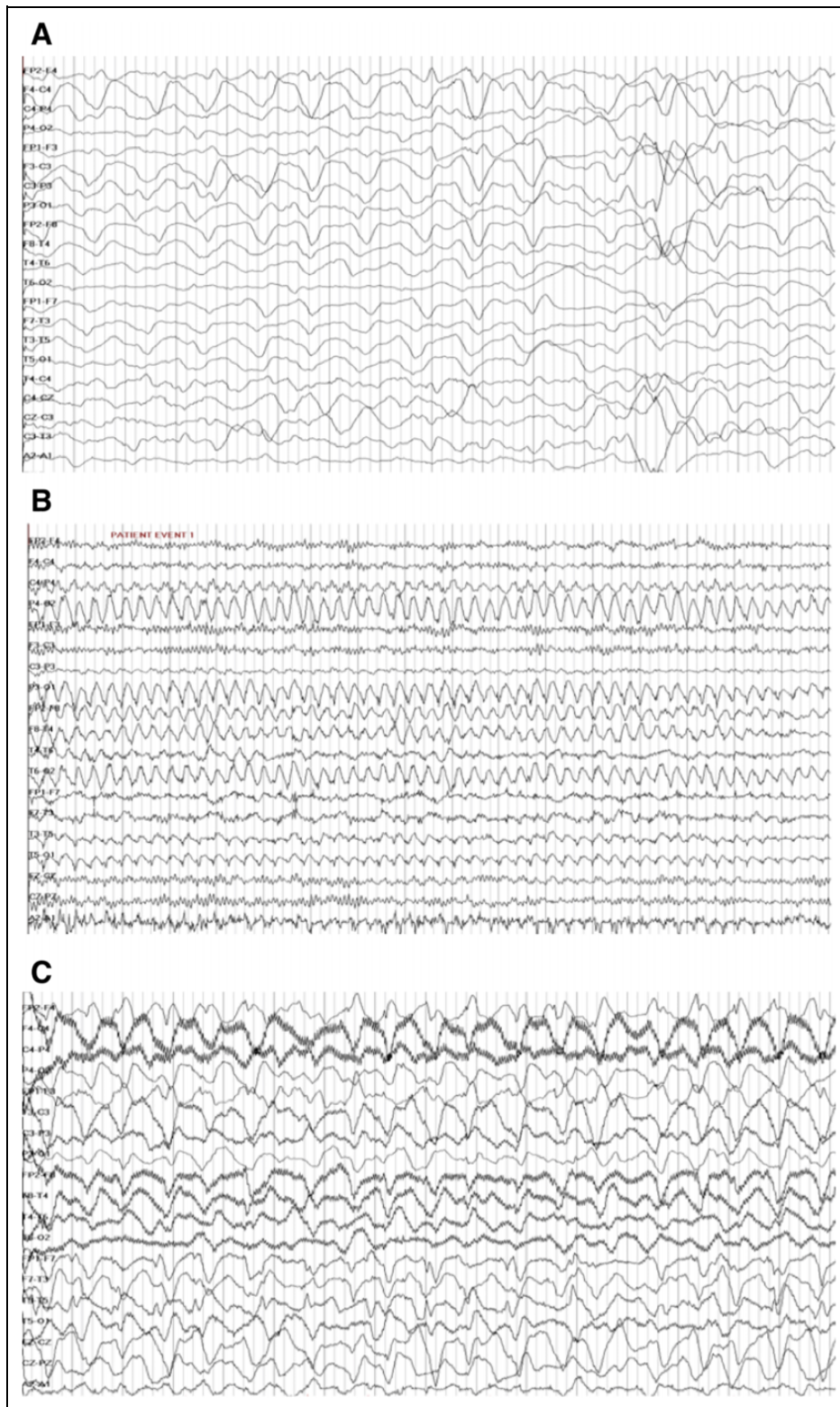
Three months after presentation, he was transferred to a pediatric rehabilitation center where he made significant neurologic gains and was discharged home 6 weeks later. He has continued to recover well and is now attending school and participating in organized sports. He continues to have mild impairments in executive function and memory, behavioral issues, and seizures that are well controlled on antiseizure medications. He has no focal neurologic deficits, and EEG shows rare spike activity in the right frontal area.

For treatment of small vessel cPACNS, his prednisone was weaned over 9 months and he completed 7 cycles of cyclophosphamide before receiving mycophenolate mofetil maintenance therapy for 18 months. An MRI near the end of his treatment course revealed T2/ fluid attenuated inversion recovery hyperintense signal at the trigones of the lateral ventricles and in the deep and subcortical white matter, which have decreased in extent compared to prior imaging.

## **Discussion**

Small vessel cPACNS was first identified in children in 1990,<sup>4</sup> and small cohorts of patients have since been described (Table 1).<sup>2,5-8</sup> Both generalized and focal seizures are common. Status epilepticus occurs in 23% of patients, more often in boys.<sup>11</sup> Refractory status epilepticus has been described in the pediatric literature, including in 3 patients without a systemic prodrome.<sup>9</sup>

However, super-refractory status epilepticus requiring multiple anesthetic agents has rarely been reported in small-vessel PACNS. In the adult population, a literature search identified a

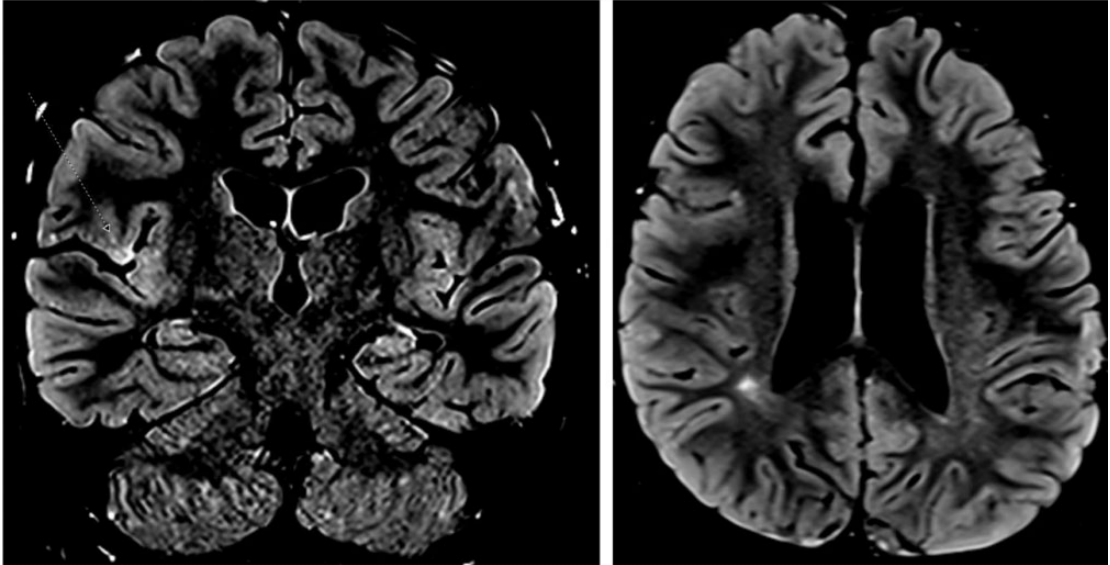


**Figure I.** Continuous electroencephalography EEG in the pediatric intensive care unit. (A) Initial continuous EEG demonstrated rhythmic delta appearance suggestive of status epilepticus. EEG parameters: sensitivity 20  $\mu\text{V}/\text{mm}$ , band-pass filter 0.50-70 Hz, paper speed 15 mm/s. (B) Seizure in right posterior quadrant. EEG parameters: sensitivity 20  $\mu\text{V}/\text{mm}$ , band-pass filter 0.50-70 Hz, paper speed 15 mm/sec. (C) Weaning of his ketamine infusion resulted in deterioration into continuous generalized frontal predominant rhythmic delta activity lasting for 6 hours, followed by continuous frontal generalized spike wave discharges ranging from 0.5 to 4 Hz, which later evolved to continuous sharply contoured generalized periodic discharges (GPDs) of 0.5-2 Hz. EEG parameters: sensitivity 20  $\mu\text{V}/\text{mm}$ , band-pass filter 0.50-70 Hz, paper speed 30 mm/s.

**A Summary of Investigations**

Routine bloodwork	<ul style="list-style-type: none"> <li>Initial CBC, electrolytes, glucose, renal function, liver enzymes normal</li> <li>Coagulation studies normal</li> <li>CRP normal</li> </ul>
Autoimmune workup	<ul style="list-style-type: none"> <li>ANA, ENA, ANCA, complement, IgG negative</li> <li>Anti-smooth muscle antibody weakly positive</li> </ul>
Metabolic workup	<ul style="list-style-type: none"> <li>Lactate, ammonia, acylcarnitine bloodspot, plasma amino acids negative</li> </ul>
Infectious workup	<ul style="list-style-type: none"> <li>Blood culture and nasopharyngeal swab negative</li> <li>Serum virology, ASOT, Lyme, cryptococcus negative for active infections</li> </ul>
CSF results	<ul style="list-style-type: none"> <li>Mild pleocytosis (lymphocyte dominant) with normal glucose and protein</li> <li>Cultures, virology (HSV, HHV6, enterovirus, parechovirus, VZV, Japanese encephalitis, Powassan virus, St. Louis, West Nile), AFB stain negative</li> <li>Autoimmune antibodies, oligoclonal bands, and amino acids unremarkable</li> </ul>
Imaging results	<ul style="list-style-type: none"> <li>3 CT heads normal</li> <li>2 MRI head demonstrated non-specific findings of FLAIR hyper intensity in the periventricular white matter and frontal operculum, MRA normal</li> </ul>
Brain biopsy (non-lesional)	<ul style="list-style-type: none"> <li>Consistent with small-vessel, non-necrotizing, lymphocytic predominant vasculitis in the absence of systemic findings</li> </ul>

**B**



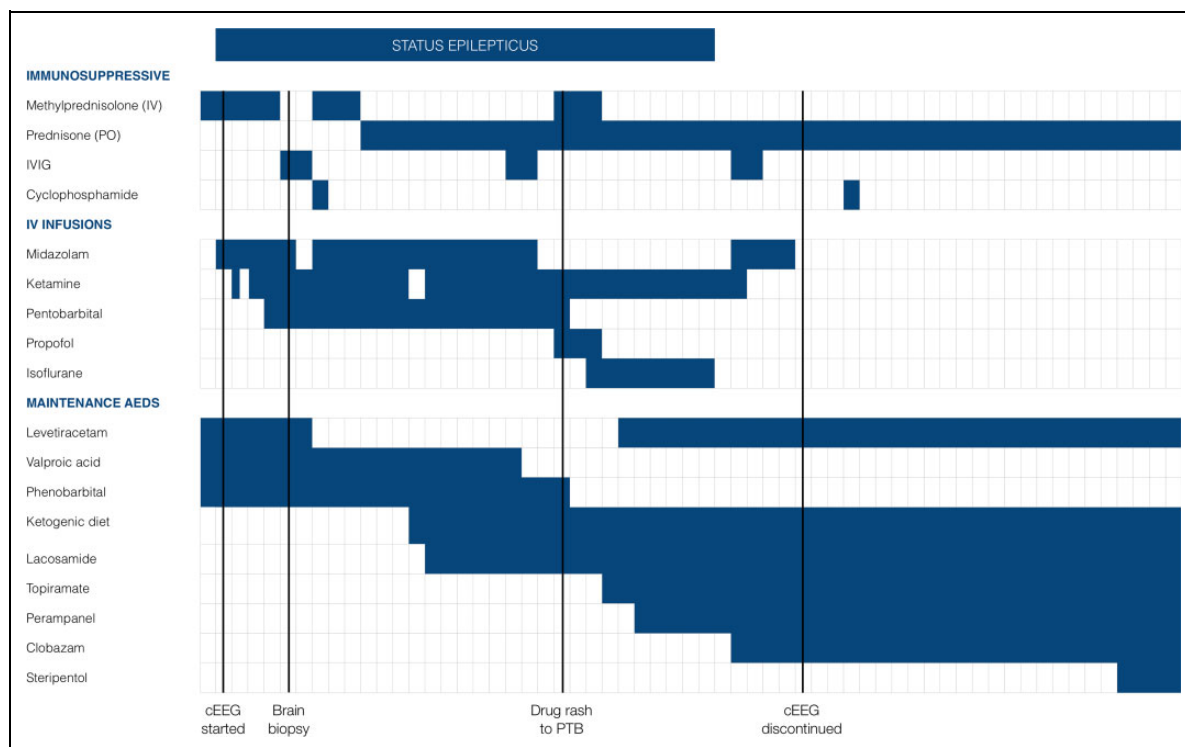
The figure shows two axial MRI brain scans. The left scan is a FLAIR sequence, showing bright white matter signal (hyperintensity) in the periventricular region and the frontal operculum. The right scan is a T2-weighted sequence, showing similar hyperintensity in the same areas. The scans are presented in a side-by-side comparison.

**Figure 2.** Summary of treatments in the pediatric intensive care unit. The patient remained in super-refractory status for 4 weeks in the pediatric intensive care unit. During this time, his symptomatic seizures required multiple intravenous infusions in order to achieve burst suppression and were treated with 8 antiepileptic drugs (AEDs) as well as the ketogenic diet. Concurrently, the patient received immunosuppressive therapies to treat his underlying pathology, including intravenous methylprednisolone pulses followed by a long course of tapering oral steroids, intravenous immunoglobulin, and cyclophosphamide.

case report of a 20-year-old man in nonconvulsive focal status epilepticus for 8 weeks who had a favorable outcome with long-term steroid treatment, surgical resection of his epileptic focus, and intensive rehabilitation.<sup>12</sup> Our patient's presentation is similar, but his treatment differed because he did not have a cortical lesion that was amenable to resection; instead, he received more intensive immunosuppression with intravenous immunoglobulin, cyclophosphamide, and mycophenolate mofetil.

Another case report describes a 46-year-old man with refractory nonconvulsive status epilepticus in the context of small vessel PACNS.<sup>13</sup> He had subacute onset with several months of headaches, focal seizures, and unsteadiness before development of status epilepticus, and seizure control was obtained without anesthetic infusions.

On the contrary, our patient was previously healthy without seizure risk factors and presented acutely with refractory seizures. We believe that his altered mental status initially was a



**Figure 3.** Summary of investigations. (A) Extensive infectious, autoimmune, and metabolic workup was unremarkable. Two cerebrospinal fluid samples obtained during the first week of admission revealed an inflammatory profile with lymphocytic-dominant pleocytosis and normal chemistries. Small vessel cPACNS was confirmed on brain biopsy on day 10 of admission, which revealed non-necrotic lymphocytic vasculitis. (B) Our patient’s first brain MRI was performed on day 4 of admission and revealed nonspecific T2 / fluid attenuated inversion recovery hyperintensities in the right frontal operculum and periventricular white matter.

**Table 1.** Previously Reported Cases of Small Vessel cPACNS in the Pediatric Population.

Authors	Year	No. of patients	Age; Sex	% (n) of patients with seizures	% (n) of patients with S
Matsell et al <sup>4</sup>	1990	1	8 y; 1 M	100 (1)	100 (1)
Lanthier et al <sup>5</sup>	2001	5	6-16 y; 2 M, 3 F	60 (3)	—
Yaari et al <sup>6</sup>	2004	2	3-12 y; 1 M, 1 F	50 (1)	—
Benseler et al <sup>7</sup>	2005	4	5-16 y; 4 F	50 (2)	—
Hutchinson et al <sup>3</sup>	2010	19	5-17 y; 4 M, 15 F	79 (15)	16 (3)
Elbers et al <sup>9</sup>	2010	13	5-17 y; 4 M, 15 F	85 (11)	27 (3)
De Tiège et al <sup>8</sup>	2011	3	9-15 y; 2 M, 1 F	100 (3)	33 (1)
Cellucci et al <sup>10</sup>	2012	26	Median age 9.6 y; 5 M, 21 F	85 (22)	—
Krakovská et al <sup>11</sup>	2013	39	Mean age 10.1 y; 14 M, 25 F	67 (26)	23 (9)

Abbreviations: cPACNS, childhood primary angiitis of the central nervous system; F, female; M male; SE, status epilepticus.

direct manifestation of the underlying small-vessel vasculitis. His first EEG showed continuous generalized slowing consistent with a mild encephalopathy. However, 2 days later, a repeat EEG showed frequent generalized high amplitude frontal predominant rhythmic delta activity. This periodic EEG pattern, which can represent ictal activity, and multifocal electrographic seizures likely contributed to his worsening mental status. Other etiologies, such as CNS infection and metabolic disorders, were ruled out through bloodwork and lumbar puncture.

The diagnosis of small vessel cPACNS requires an invasive procedure for confirmation. Brain biopsies are well tolerated with a high diagnostic yield of up to 69%.<sup>14</sup> As illustrated in

this case, pediatric nonlesional biopsies have a comparable yield to that of lesional biopsies and should be performed within 2 weeks of steroid initiation.<sup>9</sup>

With treatment, 70% of small vessel cPACNS have no or mild neurologic deficit at 24 months. Patients with seizures at onset of presentation have a slower recovery and higher levels of disease.<sup>10</sup> In particular, children with status epilepticus are more likely to have poorer long-term clinical outcome.<sup>11</sup> During our patient’s prolonged admission, many multidisciplinary family meetings were held to discuss his prognosis and to weigh the risks of continued intensive support with the potential for a favorable outcome.

Even though our patient had one of the most prolonged courses of status epilepticus in the pediatric literature, he made a substantial recovery and has a normal examination, well controlled seizures on 4 antiseizure medications, and rare epileptiform discharges on EEG. He has returned to school in the regular classroom with an individualized education plan and full-time supervision. He participates in organized team sports and is doing well socially. However, he continues to have significant behavioral challenges particularly with impulsivity, judgment, and safety awareness and was diagnosed with mild intellectual disability on recent neuropsychological evaluation.

## Conclusion

Our patient expands the clinical spectrum of small vessel cPACNS in the pediatric population and this disease should be considered in the differential diagnosis of super-refractory status epilepticus in previously healthy children. In addition, patients with small vessel cPACNS may initially have subtle EEG findings, such as rhythmic delta activity, and in the context of encephalopathy there should be a low threshold for suspicion of status epilepticus.

Because small vessel cPACNS is a treatable disease with good prognosis, early consideration of a diagnostic brain biopsy should occur in cases of super-refractory status epilepticus with unknown etiology despite extensive labwork, lumbar puncture, and neurovascular imaging. In addition, empiric therapy with intravenous steroids may be trialed once infectious causes have been ruled out, particularly in the context of an inflammatory cerebrospinal fluid profile.

Even with poor prognostic factors, such as seizures at initial presentation and development of super-refractory status epilepticus, patients can have a favorable neurologic outcome with symptomatic management of seizures and immunosuppression to treat the underlying pathology.

## Author Contributions

MC drafted, reviewed, and edited the manuscript for important intellectual content. AD provided valuable clinical information. She also reviewed and edited the manuscript for important intellectual content. All authors gave approval to the final version of the manuscript to be submitted and all authors are in agreement to be accountable for all aspects of the work in ensuring that questions related to the accuracy or integrity of any part of the work are appropriately investigated and resolved.


## Declaration of Conflicting Interests


The authors declared no potential conflicts of interest with respect to the research, authorship, and/or publication of this article.

## Funding

The authors received no financial support for the research, authorship, and/or publication of this article.

## ORCID iDs

Michelle Chiu, MD  <https://orcid.org/0000-0002-7585-2764>

Anita Datta, MD, FRCPC  <https://orcid.org/0000-0001-7620-4868>

## Ethical Approval

The University of British Columbia does not require ethics approval for case reports or case series with fewer than 3 patients. Patient's family provided consent to have the information published.

## References

1. Twilt M, Benseler SM. Treatment of CNS vasculitis in children. *Curr Treat Option Rheumatol*. 2015;1:365.
2. Twilt M, Benseler SM. The spectrum of CNS vasculitis in children and adults. *Nat Rev Rheumatol*. 2011;8(2):97-107.
3. Hutchinson C, Elbers J, Halliday W, et al. Treatment of small vessel primary CNS vasculitis in children: an open-label cohort study. *Lancet Neurol*. 2010;9(11):1078-1084.
4. Matsell DG, Keene DL, Jimenez C, Humphreys P. Isolated angiitis of the central nervous system in childhood. *Can J Neurol Sci*. 1990;17:151-154.
5. Lanthier S, Lortie A, Michaud J, Laxer R, Jay V, deVeber G. Isolated angiitis of the CNS in children. *Neurology*. 2001;56(7):837-842.
6. Yaari R, Anselm IA, Szer IS, Malicki DM, Nespeca MP, Gleeson JG. Childhood primary angiitis of the central nervous system: two biopsy-proven cases. *J Pediatr*. 2004;145:693-697.
7. Benseler SM, deVeber G, Hawkins C, et al. Angiography-negative primary central nervous system vasculitis in children: a newly recognized inflammatory central nervous system disease. *Arthritis Rheum*. 2005;52:2159-2167.
8. De Tiège X, Van Bogaert P, Aeby A, et al. Primary angiitis of the central nervous system: neurologic deterioration despite treatment. *Pediatrics*. 2011;127:e1086-e1090.
9. Krakovská V, Twilt M, Sheikh S, Dolezalova P, Benseler SM. PRoS-FINAL-2364: Status epilepticus as an initial manifestation of central nervous system small vessel vasculitis is related to unfavourable neurological outcome in paediatric patients. *Pediatr Rheumatol*. 2013;11(suppl 2):P354.
10. Elbers J, Halliday W, Hawkins C, Hutchinson C, Benseler S. Brain biopsy in children with primary small-vessel central nervous system vasculitis. *Ann Neurol*. 2010;68:602-610.
11. Atkinson M, Atkinson B, Norris G, Shah A. Refractory status epilepticus secondary to CNS vasculitis, a role for epilepsy surgery. *J Neurol Sci*. 2011;315:156-159.
12. Matar RK, Alshamsan B, Alsaleh S, et al. New onset refractory status epilepticus due to primary angiitis of the central nervous system. *Epilepsy Behav Case Rep*. 2017;8:100-104.
13. Venkateswaran S, Hawkins C, Wassmer E. Diagnostic yield of brain biopsies in children presenting to neurology. *J Child Neurol*. 2008;23(3):253-258.
14. Cellucci T, Tyrrell PN, Sheikh S, Benseler SM. Childhood primary angiitis of the central nervous system: identifying disease trajectories and early risk factors for persistently higher disease activity. *Arthritis Rheum*. 2012;64(5):1665-1672.