

ORIGINAL RESEARCH

A systematic review of non-trunk basilar perforator aneurysms: is it worth chasing the small fish?

Manuel F Granja,¹ Andre Monteiro,² Guilherme Jose Agnoletto,² Sara Jamal,² Eric Sauvageau,¹ Amin Aghaebrahim ,³ Ricardo Hanel ²

► Additional material is published online only. To view please visit the journal online (<http://dx.doi.org/10.1136/neurintsurg-2019-015311>).

¹Lyerly Neurosurgery, Baptist Neurological Institute, Jacksonville, Florida, USA

²Stroke & Cerebrovascular Center, Baptist Medical Center Jacksonville, Jacksonville, Florida, USA

³Neurological Institute, Lyerly Neurosurgery, Baptist Medical Center Jacksonville, Jacksonville, Florida, USA

Correspondence to

Dr Ricardo Hanel, Stroke & Cerebrovascular Center, Baptist Medical Center Jacksonville, Jacksonville, Florida 32227, USA; rhanel@lyerlyneuro.com

Received 24 July 2019

Revised 18 September 2019

Accepted 22 September 2019

ABSTRACT

Background and purpose Non-trunk basilar artery perforator aneurysms (BAPAs) are rare intracranial vascular pathologies that have long been underdiagnosed, under-reported, and under-analyzed. We performed a systematic review of the efficacy and safety endpoints between conservative and active treatment approaches for non-trunk BAPAs.

Methods Major databases were analyzed for relevant publications between 1995 and 2019. Studies comparing the outcomes between conservative and active treatment approaches such as coiling, stenting, clipping, liquid embolization, and flow diversion were included. Mortality rate, rate of permanent neurological deficit as determined by the modified Rankin Score (mRS), rate of second treatment occurrence, and perioperative complication rate were also assessed.

Results A total of 24 studies, including 54 patients with 56 non-trunk BAPAs, were included. The mean maximum aneurysm diameter was 2.70 mm (range 1–10). A diagnosis was achieved with the initial DSA in 50.0% (27/54) of the patients. A conservative approach was used in 16 patients while active treatment was used in the other 38. Thirteen of 15 (86.7%) patients in the conservative group and 27/34 (79.4%) in the active treatment group had an mRS score 0–2. A non-significant higher odds of a positive outcome was observed in the conservative group (OR 1.51, 95% CI 0.50 to 4.54). The event-related mortality rate was 3.55% (3/54) with one procedure-related death in the active treatment group.

Conclusions In patients with non-trunk BAPAs unamenable to active treatment, conservative approaches may result in acceptable functional outcomes and low morbidity. Small sample sizes and under-reporting of outcomes warrant further study.

the basilar trunk.² A second classification system aimed at standardizing angiographic descriptions was introduced by Satti *et al* in 2016 ([figure 1](#)).³ In 1996, Ghogawala *et al* published the first case of BAPAs,⁴ and since then there has been a shift from microsurgical clipping to endovascular treatment. However, given the rarity of this pathology, there is not a clear understanding of the optimal management approach for BAPAs to date. A full understanding of the natural history of this condition and clarification of the post-treatment outcomes would provide evidence-based management protocols for BAPAs. We conducted a systematic literature review to collectively report and analyze previously published data on the management of BAPAs.

METHODS

Study design

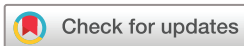A systematic review of PubMed, Science Direct, and Ovid/EMBASE databases was conducted based on the Preferred Reporting Items for Systematic Reviews and Meta-Analyses (PRISMA) guidelines. Key words or Medical Subject Heading (MeSH) terms such as cerebral aneurysm, intracranial aneurysm, basilar artery, perforator, coiling, and conservative treatment were used in combination with Boolean operators to maximize search sensitivity. The search was limited to studies published between January 1995 and August 2019. Initial screening and study selection was performed using the Ryyan app, a web and mobile application for systematic reviews.⁵ The protocol was finalized after consensus between all authors. Two authors independently searched publications, selected articles with valid cases, and extracted data accordingly. Discrepancies were resolved by open discussion between two authors.

Eligibility criteria

Inclusion criteria were: (1) articles published in English, Portuguese, and Spanish; (2) studies reporting BAPAs, such as case reports or case series with no minimum patient number; (3) case reports or case series including both radiographic and clinical outcomes. BAPAs associated with the simultaneous presence of arteriovenous malformation (AVM), as well as pseudoaneurysms, were considered as separate entities and thus were excluded from the systematic review. Review articles, editorials, technical notes, animal studies, and cases missing angiographic or clinical follow-ups were also excluded. Aneurysms arising from the basilar

INTRODUCTION

Aneurysms of perforating arteries are rare intracranial vascular pathologies that have long been underdiagnosed, under-reported, and under-analyzed. Guidance as far as an optimal treatment strategy is lacking. The prevalence of perforator aneurysms of the anterior circulation is less than 1%, with no more than 50 cases reported in the literature.¹ Basilar artery perforator aneurysms (BAPAs) are an even rarer and under-reported subtype. Categorizing these aneurysms is a challenging task; Aboukais *et al* described these aneurysms as those whose neck is entirely located on a perforator artery without direct involvement of



© Author(s) (or their employer(s)) 2019. No commercial re-use. See rights and permissions. Published by BMJ.

To cite: Granja MF, Monteiro A, Agnoletto GJ, *et al*. *J NeuroIntervent Surg* Epub ahead of print: [please include Day Month Year]. doi:10.1136/neurintsurg-2019-015311

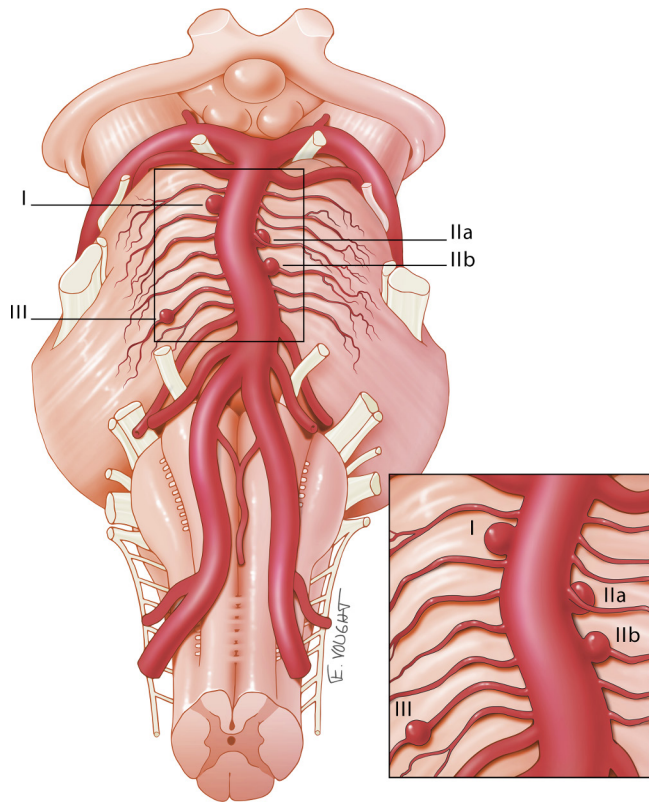


Figure 1 Basilar artery perforator aneurysm classification system as described by Satti *et al.*

artery trunk adjacent to a perforating branch but not involving a perforating artery (Satti type I aneurysms) were excluded from the analysis. Satti type IIa, IIb, and III were included; Satti type IIa aneurysms are defined as incorporating the perforating artery origin, whereas Satti type IIb aneurysms have a perforating artery arising from the dome of the aneurysm. Satti type III aneurysms are fusiform lesions along the course of a perforating artery beyond the parent vessel (figure 1).³ A specific BAPA Satti type³ was assigned when a full anatomical description and a complete imaging set was provided by the author.

Data synthesis

Data collected included patient age, sex, presenting symptoms, subarachnoid hemorrhage (SAH), anatomical location and severity (Fisher scale), initial imaging modality, number of digital subtraction angiographies (DSAs) performed until actual diagnosis, number of aneurysms per patient, and maximum aneurysm diameter. Several treatment details were collected, including the modality of the first active treatment (clipping, stenting/coiling alone, stent-assisted coiling, and embolization), treatment approach (active vs conservative), spontaneous resolution, recurrence after first treatment, second treatment modality, incidence of periprocedural complications (3rd or 4th cranial nerve palsy, cerebrospinal fluid leak, hemiparesis, vasospasm, hydrocephalus, tension pneumocephalus, in-stent thrombosis), time at follow-up when the aneurysm resolved, mortality, longest follow-up, last documented modified Rankin Scale (mRS) score, and permanent residual deficit.

Study endpoints

Efficacy endpoints included (a) mortality rate, defined as mRS score of 6, Glasgow Outcome Scale (GOS) 1, or otherwise

stated in the source paper; (b) rate for the presence/absence of permanent neurological deficit, defined as mRS 3–5 or GOS 2–4; (c) aneurysm regrowth rate, defined as a new aneurysm occurrence at the same location after an initial treatment; (d) rate of second treatment occurrence, defined as any endovascular or open approach due to aneurysm regrowth or any other reason; (e) spontaneous resolution rate, defined as initially documented BAPA and no subsequent evidence of the same lesion in follow-up imaging for those patients who were approached conservatively. Aneurysm suboptimal occlusion was defined as any postprocedural result different from complete aneurysm occlusion (Raymond–Roy class I). The safety endpoint was the perioperative complication rate, defined as any neurovascular complication in the immediate postoperative period (up to 24 hours after the procedure). Efficacy outcomes were subsequently split into favorable and unfavorable outcomes when rough or vague descriptions of clinical outcomes were reported.

Risk of bias determination

The risk of bias was assessed by the Newcastle–Ottawa Scale according to the proposed items by Zhao *et al.*^{6,7} Two investigators independently performed a critical appraisal to determine the most common bias in the actual set of case reports. Studies were considered to have a low risk of bias if they missed one of the following: clear demographic data, severity at presentation, active treatment effectiveness, radiological follow-up, or clinical follow-up. Studies with a medium risk bias missed two of the aforementioned criteria, and those considered to have a high risk of bias had neither a complete treatment effectiveness report nor clinical follow-up detail (see online supplementary table 1).

Statistical analysis

Efficacy and safety endpoints were analyzed for patients with and without active treatments in an effort to identify potential differences between the two groups. Continuous variables are reported as means and ranges for normal distributions and as medians with interquartile ranges for skewed distributions. Categorical variables are presented as rates. Univariate comparisons were performed using a Fisher exact test, given the small expected frequencies. Continuous variables were compared using the Mann–Whitney U test or an unpaired t-test. ORs and 95% CI for each prespecified outcome were calculated accordingly. No particular heterogeneity or publication bias analysis was reported because the maximum number of cases per published series was eight.⁸ All statistical tests were performed using SPSS (IBM, Armonk, New York, USA). Two-sided test results with $p < 0.05$ were considered statistically significant.

RESULTS

Study selection

Out of 59 articles identified, 32 were duplicates and 15 were excluded according to our prespecified protocol (figure 2). The remaining 31 studies were assessed in full text and, after revision of cross references, 24 retrospective case series met our predefined inclusion criteria and were included in the evidence synthesis. Of the 24 included articles, 19 (79%) had a low risk of bias,^{2–4 8–23} three (12%) had a medium risk of bias,^{24–26} and two (8%) had a high risk of bias^{27 28} (see online supplementary table 1).

Patient demographics

A total of 54 patients with 56 non-trunk BAPAs (Satti type IIa, IIb, III)³ were included in the analysis. Patient baseline

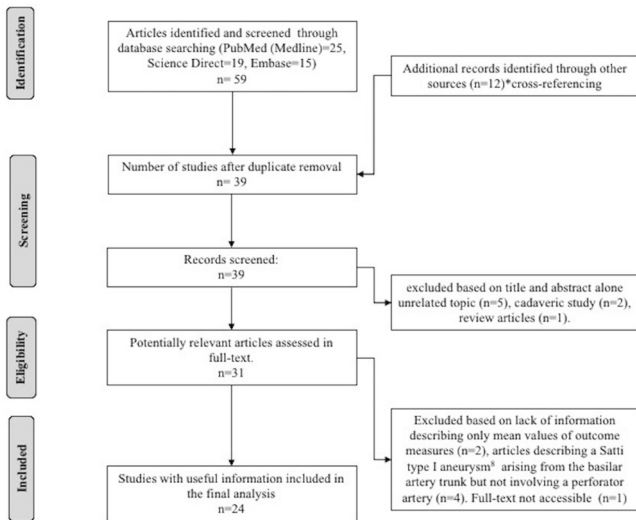


Figure 2 Flow chart of study selection.

characteristics are presented in [table 1](#). The mean patient age was 56.5 years (range 27–82 years) and 27.8% (15/54) were female. The overall mean maximum aneurysm diameter was 2.70 mm (range 1–10 mm). Thirty-eight cases were actively treated and 16 cases were managed conservatively. Patients in the active treatment group had a significantly larger aneurysm diameter than those in the conservative treatment group (3.32 mm vs 1.52 mm, $p < 0.001$). At admission, 100% of patients presented with SAH. Non-contrast head CT revealed a diffuse bleed in 37.0% (20/54) of patients, a perimesencephalic bleed in 18.5% (10/54), and a prepontine bleed in 11.1% (6/54) of

the study population. Eighteen cases had a non-specified intracranial bleeding pattern. Fisher grade 3 or 4 was documented in 39.0% (21/54) of patients. All patients had a non-contrast head CT as the first-line imaging modality. However, when considering the second-line modality, non-trunk BAPAs were identified by a CT angiogram (CTA) in 31.4% (17/54) of patients, and in 65.0% (35/54) DSA led to a certain diagnosis. The final imaging modality was not reported in two patients.¹⁰ Diagnosis was achieved with the initial DSA in 50.0% (27/54) of patients, in 41.0% (22/54) of cases by the second, and in 9.2% (5/54) by the third. Our analysis identified aneurysm Satti type IIa in 5.5% (3/54) of cases, type IIb in 11.1% (6/54), and type III in 63.0% (34/54).

Treatment characteristics and outcomes

Among the 38 patients in the active treatment group, coiling was the most commonly used treatment modality (39.5%, 15/38); stenting (n=9), clipping (n=6), Onyx liquid embolization (n=1), and flow diversion (n=5) were also utilized ([table 1](#)). Regarding aneurysm occlusion rates, 23.7% (9/38) of patients had suboptimal occlusion after a first treatment attempt.^{3 8 9 16 18 21 25} Failure to place a coil was the most common reason for an unsuccessful first treatment attempt (18.4%, 7/38). Of the nine patients with suboptimal occlusion, only five underwent an active second treatment (two clipping,^{9 25} one wrapping,¹⁸ two stenting^{3 16}), three of which had an mRS 0–2 in the final follow-up. The remaining 4/9 (44.4%) patients were managed conservatively after the first attempt.^{8 13 21}

Spontaneous aneurysm resolution was documented in 50.0% (8/16) of patients in the conservative treatment group on subsequent follow-ups and 80.0% (4/5) in whom suboptimal

Table 1 Baseline patient characteristics and outcomes

	Treatment approach		Overall	P value
	Conservative (n=16)	Active (n=38)		
Demographics				
Age, years (range)	58.7 (35–76)	55.3 (27–82)	56.5	0.830
Female	25.0 (4/16)	29.0 (11/38)	27.8	0.767
Imaging features				
Fisher grade 3 or 4	37.5 (6/16)	39.5 (15/38)	38.9	0.892
Initial diagnostic modality				
CTA	25.0 (4/16)	34.2 (13/38)	31.5	0.506
DSA	75.0 (12/16)	60.5 (23/38)	64.8	0.309
Aneurysm identified on initial diagnostic imaging*				
Aneurysm maximum diameter, mm	1.52 (1–3)	3.32 (1.2–10)	2.70	<0.001
Treatment modality				
Coiling	–	39.5 (15/38)		
Stenting	–	23.7 (9/38)		
Clipping	–	15.8 (6/38)		
Liquid embolization	–	2.60 (1/38)		
Flow diversion	–	13.2 (5/38)		
Spontaneous aneurysm resolution				
mRS 0–2 at last follow-up	50.0 (8/16)	80.0 (4/5)†	57.1	0.338
mRS 0–2 at last follow-up	86.7 (13/15)	79.4 (27/34)	74.1	0.023

Data are mean (range) or % (n/N).

*No repeat imaging was required.

†Suboptimal angiographic result and second treatment attempt was not made (n=5). Fisher's exact test for all categorical variables.

.CTA, CT angiography; DSA, digital subtraction angiography; mRS, modified Rankin Scale.

angiographic results were obtained but a second attempt was not made. Five out of nine patients reported a subsequent follow-up after an initial suboptimal treatment. The mean time for spontaneous aneurysm resolution for the entire population was 3.6 months (range 1–7) (n=12). A total of 49 mRS scores were available as reported by each of the different authors. In the conservative and active treatment groups 86.7% (13/15) and 79.4% (27/34) had an mRS score of 0–2, respectively, indicating a non-significant higher odds of a positive outcome in the conservative group (OR 1.51, 95% CI 0.50 to 4.54). Mean clinical follow-up time for the whole population was 16 months

(range 0.5–78). The overall event-related mortality rate was 3.55% (3/54)^{10 11 15} with one procedure-related death reported in the active treatment group (table 2).¹¹

DISCUSSION

This systematic review found that both active treatment and conservative approaches are used to treat non-trunk BAPAs with positive outcomes. The rate of successful functional outcome (mRS 0–2) was similar between the two groups. After consideration of the several limitations of this review, probing a

Table 2 Summary of reports of non-trunk basilar perforator aneurysms

Study	Total cases (n)	Periprocedural transient complications (detail, n)	Mean FU period clinical (months)	Mortality ratio (n/total)	Neurological deficit during FU (deficit, n)	mRS 0–2 at last FU (n/total)
Studies reporting conservative approach						
Park <i>et al</i> ²⁰	3	N/A	11	0/0	Hemiparesis (n=1)	3/3
Forbrig <i>et al</i> ⁸	2	N/A	10.5	0/0	Hemiparesis (n=1)	2/2
Daruwalla <i>et al</i> ¹⁵	1	N/A	0.5	1/1	NR	0/1
Aboukais <i>et al</i> ²	1	N/A	6.5	0/0	NR	3/3
Buell <i>et al</i> ¹¹	3	N/A	35	0/0	No	3/3
Sahu <i>et al</i> ²²	2	N/A	NR	NR	NR	NR
Chau <i>et al</i> ¹²	1	N/A	12	0/0	No	1/1
Bhagal <i>et al</i> ¹⁰	3	N/A	6	1/3	(n=1), non-specified	1/3
Studies reporting active treatment						
Ghogawala <i>et al</i> ⁴	1	3rd cranial nerve palsy	6	0/0	No	1/1
Hamel <i>et al</i> ¹⁸	1	Tension pneumocephalus	7	0/0	Ataxia	0/1
Sanchez-Mejia <i>et al</i> ²⁶	3	No	NR	0/0	No	3/3
Mathieson <i>et al</i> ²⁵	1	CSF leak and hydrocephalus	NR	0/0	Amnesia	1/1
Deshai <i>et al</i> ¹⁶	1	No	6	0/0	No	1/1
Chen <i>et al</i> ¹⁴	2	No	21	0/0	Lower extremity weakness (n=1)	2/2
Nyberg <i>et al</i> ²⁸	2	No	9	0/0	NR	NR
Apok <i>et al</i> ⁹	1	Hemiparesis	20	0/0	Hemiparesis (n=1)	0/1
Ding <i>et al</i> ¹⁷	1	Dysarthria, lethargy, severe quadriplegia, R-facial nerve palsy	NR	0/0	Severe disability	0/1
Chalouhi <i>et al</i> ²⁷	1	No	6	0/0	No	1/1
Gross <i>et al</i> ²⁴	1	Vasospasm, 3rd cranial nerve palsy	12	0/0	No	1/1
Sivakanthan <i>et al</i> ²³	1	No	6	0/0	No	1/1
Chavent <i>et al</i> ¹³	2	No	6	0/0	No	1/1
Peschillo <i>et al</i> ²¹	2	Hemiparesis, in-stent thrombosis* (n=2)	21	0/0	Upper extremity monoparesis (n=1)	2/2
Forbrig <i>et al</i> ⁸	6	Hemiparesis, vasospasm, hydrocephalus (n=3)	30.5	0/0	Hemiparesis (n=2)	5/6
Buell <i>et al</i> ¹¹	4	NR	32	1/4	(n=3), non-specified	2/4
Sahu <i>et al</i> ²²	2	No	7.5	0/0	No	2/2
Satti <i>et al</i> ³	1	Vessel dissection and 4th cranial nerve palsy (n=1)	7	0/0	No	1/1
Lockwood <i>et al</i> ¹⁹	1	Vasospasm	5	0/0	No	1/1
Chau <i>et al</i> ¹²	1	No	6	0/0	No	1/1
Bhagal <i>et al</i> ¹⁰	3	No	6	0/0	(n=3), non-specified	3/4

*Reversed with tirofiban.
FU, follow-up; NR, not reported.

significantly higher benefit in terms of functional outcome for any of the specific modalities included in the active treatment group (ie, coiling, stenting, clipping, liquid embolization, and flow diversion) seems to be elusive. However, the data compiled in this review provide enlightening facts about these uncommon lesions. We found that (1) a maximum aneurysm diameter of ≥ 3.32 mm was significantly associated with an active approach; (2) 41% of patients required a second DSA in order to achieve a certain diagnosis; (3) suboptimal occlusion rates can be observed in up to 23.7% of patients after an active treatment modality is provided; and (4) failure to place a coil is the most common reason for an unsuccessful first treatment attempt.

As a framework for future studies, Satti *et al* proposed a distinctive BAPA classification system where type I aneurysms are defined as lesions arising from the basilar artery trunk adjacent to a perforating branch but not involving a perforating artery.³ This rare type of aneurysm can be found in up to 2.1% of patients among overall aneurysm locations.³ Whether this new classification system translates into differential treatment strategies is yet to be elucidated. Trunk BAPAs are often described and compared along with non-trunk BAPAs. Nevertheless, trunk BAPAs have been subclassified into four different categories based on imaging findings, including acute dissecting aneurysms, segmental ectasia, chronic mural bleeding ectasia, and saccular.²⁹ Saccular aneurysms seem to be stable over time with little or no change in size. However, segmental ectasia and chronic dissecting aneurysms are characterized by increasing size and carry a risk of SAH, especially in men with positive vascular risk factors, and require prompt intervention.²⁹ Type I trunk BAPAs were excluded from this review based on their high complexity, heterogeneity, different natural history, and uncertainty regarding best treatment modality. AVM-related basilar artery aneurysms were also considered a separate and secondary entity and were therefore excluded from the present systematic review.

Typically, non-trunk BAPAs are angiographically occult, requiring three-dimensional rotational angiography for final diagnosis. Indeed, only one-third of non-trunk BAPAs included in this review were diagnosed after a second-line CTA and 50% after a single DSA. Other authors have reported performing up to three conventional angiograms before a final diagnosis was achieved, raising serious concerns regarding under-diagnosis.²¹ The introduction of improved microcatheter/microware technologies to the neurointervention armamentarium has allowed endovascular management of trunk and non-trunk BAPAs as a first-line treatment approach. Peschillo *et al* retrospectively analyzed results of three patients diagnosed with trunk Satti type I BAPAs treated with flow diversion. Long-term outcomes for all patients were acceptable and the following periprocedural complications were described: 2/3 patients experienced in-stent thrombosis and 1/3 experienced intracranial hemorrhage.²¹ Although initial series of flow diverters in the posterior circulation reported high morbidity and mortality rates, most of these series included giant or fusiform aneurysms.^{30 31} Recently, the use of a single long flow diverter instead of multiple telescoped devices as well as adequate compliance with antiplatelet regimens have shown considerable efficacy and safety in the treatment of intracranial aneurysms of the vertebrobasilar system.^{32 33}

On the other hand, non-trunk Satti type II BAPAs have been successfully managed after placement of lower-metal coverage stents (ie, Enterprise and Neuroform stents). However, we cannot state whether these results were due to a favorable balance between adequate metal coverage and low risk of perforator occlusion or to natural history of spontaneous aneurysm

resolution as seen in 50.0% of the cases in the group who underwent a conservative approach. Multiple interventions and staged approaches may also be expected when treating non-trunk BAPAs. Every time a first treatment attempt was unsuccessful, mostly due to failure to place a coil, a second treatment was not attempted, especially in those cases where the initial maximum aneurysm diameter was < 2.5 mm, which raises questions about the indication and benefit of any active treatment in this subgroup of patients.^{8 9 13 18 25} This review demonstrated that up to 24% of patients had a suboptimal occlusion rate after an initial treatment attempt; however, 66% of those had a favorable mRS score at final follow-up.

This systematic review has several limitations. There was significant under-reporting of objective scales regarding aneurysm occlusion grades; hence, criteria for reintervention after any degree of recanalization was not well defined. All the included articles were retrospective studies. In addition, small sample sizes and under-reporting of functional outcomes among the conservative approach limit the scope of these results. A heterogeneous body of evidence on diagnostic methods, occlusion rates, clinical outcomes, and periprocedural complication rates preclude any robust conclusion favoring a specific treatment modality.

In conclusion, case reports and case series on either active treatment modalities and conservative approaches can be found across the literature for the treatment of BAPAs. In this contemporary systematic review, conservative approaches may result in acceptable functional outcomes and low morbidity in patients not amenable to active treatment. Small sample sizes and under-reporting of outcomes warrant further study to explore the effects of individual treatment strategies on BAPAs.

Twitter Amin Aghaebrahim @drnimajax

Contributors MFG: manuscript design, writing, editing, and statistical analysis. AM: data gathering, editing, and statistical analysis. GJA, SJ, ES, AA: manuscript writing, editing. RH: original idea, manuscript writing, and editing.

Funding The authors have not declared a specific grant for this research from any funding agency in the public, commercial or not-for-profit sectors.

Disclaimer RH is a consultant and scientific advisor for Microvention, Stryker, and Covidien.

Competing interests RH is a consultant for Medtronic, Stryker, Codman, and MicroVention. The remaining authors have nothing to disclose.

Patient consent for publication Not required.

Provenance and peer review Not commissioned; externally peer reviewed.

ORCID iDs

Amin Aghaebrahim <http://orcid.org/0000-0002-9126-2932>

Ricardo Hanel <http://orcid.org/0000-0001-7195-5806>

REFERENCES

- Vargas J, Walsh K, Turner R, *et al*. Lenticulostriate aneurysms: a case series and review of the literature. *J Neurointerv Surg* 2015;7:194–201.
- Aboukais R, Zairi F, Estrade L, *et al*. A dissecting aneurysm of a basilar perforating artery. *Neurochirurgie* 2016;62:263–5.
- Satti SR, Vance AZ, Fowler D, *et al*. Basilar artery perforator aneurysms (BAPAs): review of the literature and classification. *J Neurointerv Surg* 2017;9:669–73.
- Ghogawala Z, Shumacher JM, Ogilvy CS. Distal basilar perforator artery aneurysm: case report. *Neurosurgery* 1996;39:393–6.
- Ouzzani M, Hammady H, Fedorowicz Z, *et al*. Rayyan—a web and mobile APP for systematic reviews. *Syst Rev* 2016;5:210.
- Zhao B, Yin R, Lanzino G, *et al*. Endovascular coiling of wide-neck and wide-neck bifurcation aneurysms: a systematic review and meta-analysis. *AJNR Am J Neuroradiol* 2016;37:1700–5.
- Stang A. Critical evaluation of the Newcastle-Ottawa scale for the assessment of the quality of nonrandomized studies in meta-analyses. *Eur J Epidemiol* 2010;25:603–5.
- Forbrig R, Eckert B, Ertl L, *et al*. Ruptured basilar artery perforator aneurysms—treatment regimen and long-term follow-up in eight cases. *Neuroradiology* 2016;58:285–91.

- 9 Apok V, Tarnaris A, Brydon HL. An unusual aneurysm of a basilar perforating artery presenting with a subarachnoid haemorrhage. *Br J Neurosurg* 2013;27:105–7.
- 10 Bhogal P, AlMatter M, Hellstern V, et al. Basilar artery perforator aneurysms: report of 9 cases and review of the literature. *J Clin Neurosci* 2019;63:122–9.
- 11 Buell TJ, Ding D, Raper DMS, et al. Posterior circulation perforator aneurysms: a proposed management algorithm. *J Neurointerv Surg* 2018;10:55–9.
- 12 Chau Y, Sachet M, Sédat J. Should we treat aneurysms in perforator arteries from the basilar trunk? Review of 49 cases published in the literature and presentation of three personal cases. *Interv Neuroradiol* 2018;24:22–8.
- 13 Chavent A, Lefevre P-H, Thouant P, et al. Spontaneous resolution of perforator aneurysms of the posterior circulation. *J Neurosurg* 2014;121:1107–11.
- 14 Chen L, Chen E, Chotai S, et al. An endovascular approach to ruptured aneurysms of the circumferential branch of the basilar artery. *J Clin Neurosci* 2012;19:527–31.
- 15 Daruwalla VJ, Syed FH, Elmokadem AH, et al. Large basilar perforator pseudoaneurysm: a case report. *Interv Neuroradiol* 2016;22:662–5.
- 16 Deshaies EM, Jacobsen W, Krishnamurthy S. Enterprise stent-within-stent embolization of a basilar artery perforator aneurysm. *World J Neurosci* 2011;01:45–8.
- 17 Ding D, Starke RM, Jensen ME, et al. Perforator aneurysms of the posterior circulation: case series and review of the literature. *J Neurointerv Surg* 2013;5:546–51.
- 18 Hamel W, Grzyska U, Westphal M, et al. Surgical treatment of a basilar perforator aneurysm not accessible to endovascular treatment. *Acta Neurochir* 2005;147:1283–6.
- 19 Lockwood J, Scullen T, Mathkour M, et al. Endovascular management of a ruptured basilar perforator artery aneurysm associated with a pontine arteriovenous malformation: case report and review of the literature. *World Neurosurg* 2018;116:159–62.
- 20 Park SQ, Kwon O-K, Kim SH, et al. Pre-mesencephalic subarachnoid hemorrhage: rupture of tiny aneurysms of the basilar artery perforator. *Acta Neurochir* 2009;151:1639–46.
- 21 Peschillo S, Caporlingua A, Cannizzaro D, et al. Flow diverter stent treatment for ruptured basilar trunk perforator aneurysms. *J Neurointerv Surg* 2016;8:190–6.
- 22 Sahu C, Ashpilaya A. Case series on perforator aneurysm: endovascular stenting—a safe strategy. *J Clin Interv Radiol ISVIR* 2017;01:179–83.
- 23 Sivakanthan S, Carlson AP, van Loveren H, et al. Surgical clipping of a basilar perforator artery aneurysm: a case of avoiding perforator sacrifice. *J Neurol Surg A Cent Eur Neurosurg* 2015;76:79–82.
- 24 Gross BA, Puri AS, Du R. Basilar trunk perforator artery aneurysms. Case report and literature review. *Neurosurg Rev* 2013;36:163–8.
- 25 Mathieson CS, Barlow P, Jenkins S, et al. An unusual case of spontaneous subarachnoid haemorrhage - a ruptured aneurysm of a basilar perforator artery. *Br J Neurosurg* 2010;24:291–3.
- 26 Sanchez-Mejia RO, Lawton MT. Distal aneurysms of basilar perforating and circumferential arteries. Report of three cases. *J Neurosurg* 2007;107:654–9.
- 27 Chalouhi N, Tjoumakaris S, Dumont AS, et al. Treatment of posterior circulation aneurysms with the pipeline embolization device. *Neurosurgery* 2013;72:883–9.
- 28 Nyberg EM, Chaudry MI, Turk AS, et al. Report of two cases of a rare cause of subarachnoid hemorrhage including unusual presentation and an emerging and effective treatment option. *J Neurointerv Surg* 2013;5:e30.
- 29 Saliou G, Sacho RH, Power S, et al. Natural history and management of basilar trunk artery aneurysms. *Stroke* 2015;46:948–53.
- 30 Siddiqui AH, Ablal AA, Kan P, et al. Panacea or problem: flow diverters in the treatment of symptomatic large or giant fusiform vertebrobasilar aneurysms. *J Neurosurg* 2012;116:1258–66.
- 31 van Rooij WJ, Sluzewski M. Perforator infarction after placement of a pipeline flow-diverting stent for an unruptured A1 aneurysm. *AJNR Am J Neuroradiol* 2010;31:E43–E44.
- 32 Albuquerque FC, Park MS, Ablal AA, et al. A reappraisal of the pipeline embolization device for the treatment of posterior circulation aneurysms. *J Neurointerv Surg* 2015;7:641–5.
- 33 Brouillard AM, Sun X, Siddiqui AH, et al. The use of flow diversion for the treatment of intracranial aneurysms: expansion of indications. *Cureus* 2016;8:e472.