

Severe skull deformity in a child with shunted hydrocephalus

Alireza Tabibkhomei, Morteza Taheri & Feyzollah Ebrahimniya

To cite this article: Alireza Tabibkhomei, Morteza Taheri & Feyzollah Ebrahimniya (2019): Severe skull deformity in a child with shunted hydrocephalus, British Journal of Neurosurgery, DOI: [10.1080/02688697.2019.1671954](https://doi.org/10.1080/02688697.2019.1671954)

To link to this article: <https://doi.org/10.1080/02688697.2019.1671954>



Published online: 10 Oct 2019.



Submit your article to this journal [↗](#)

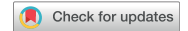

View related articles [↗](#)




View Crossmark data [↗](#)

SHORT REPORT



Severe skull deformity in a child with shunted hydrocephalus

Alireza Tabibkhouei^a, Morteza Taheri^b  and Feyzollah Ebrahimniya^c

^aDepartment of Neurosurgery, Rasool Akram Hospital, Iran University of Medical Sciences, Tehran, Iran; ^bDepartment of Neurosurgery, 7Tir Hospital, Iran University of Medical Sciences, Tehran, Iran; ^cDepartment of Neurosurgery, Shahroud University of Medical Sciences, Shahroud, Iran

ABSTRACT

Introduction: We report a rare case of skull deformity in a child with shunted hydrocephalus.

Case report: A 2.5-year-old boy with a history of cerebral palsy (CP), shunted hydrocephalus and seizures was admitted to our children's hospital with status epilepticus. This was initially controlled with anesthesia. He referred to us intubated. Head examination found a skull deformity (brachycephaly). Head CT revealed a remarkable deformity and bilateral chronic subdural hematomas. MRI demonstrated voluminous extra-axial masses over the cerebral convexities with high signal on T1 and T2 sequences in favor of hematoma. The patient had a bilateral frontoparietal craniotomy and evacuation of subdural/epidural hematomas. Neurological status improved on the next day but because of co-existent medical problems, the patients gradually deteriorated and died.

Conclusion: Shunt-induced craniosynostosis is rarely seen nowadays thanks to early detection and treatment of infantile hydrocephalus. But in the setting of child neglect or low socioeconomic culture, it can occur. Although it usually results in a skull deformity similar to the primary craniosynostosis such as scaphocephaly, brachycephaly, it can induce a macrocephalic skull and subsequently associated chronic haematomas.

ARTICLE HISTORY

Received 5 February 2019
Revised 17 September 2019
Accepted 19 September 2019

KEYWORDS

Skull deformity;
hydrocephalus; shunting;
craniosynostosis; prema-
ture fusion

Introduction

In cases of hydrocephalus who underwent shunting in infancy, premature craniosynostosis can occur.¹ This is prone to happen if the head becomes enlarged with widened sutures before shunting results in re-approximation of the sutures. This process can lead to marked deformity of the skull. We report such a case.

Case report

A 2.5-year-old boy with cerebral palsy (CP) had a history of shunted hydrocephalus when he was 3 months old. He was bed-ridden and had seizures under variable medical control. He was admitted under our care with status epilepticus for 6 days controlled with anesthesia that was discontinued for assessment. Examination found a GCS of 8 (intubated) with bilateral normal-sized, reactive, and symmetrical pupils. All the lab exams were normal except for the Hemoglobin level of 9.7 and ammonia level of 126 mg/dL.

On brain CT scan, the scout view and bone window revealed a marked skull deformity, and brain window demonstrated bilateral chronic subdural hematoma (SDH) (Figure 1(A–C)). Brain MRI demonstrated voluminous extra-axial mass over the cerebral convexities with high signal on T1 and T2 sequences in favor of hematoma. T1 sequences with Gadolinium demonstrated peripheral enhancement (Figure 2(A–D)). He had a bilateral frontoparietal craniotomy and evacuation of SDH and epidural hematoma. Later, skull reconstruction and deformity correction will be performed. The patient was transferred to our Pediatric Neuro Intensive Care Unit postoperatively. Neurological status

improved the next day. His medical and metabolic condition slowly deteriorated, however, and he ultimately died.

Discussion

Ventricular shunting is one cause of secondary craniosynostosis² so early surgical treatment of hydrocephalus is important from two aspects; functional and cosmetic.³ Hydrocephalus with raised intracranial pressure and excessive head circumference in infancy results in calvarial suture diastasis. If the hydrocephalus is untreated and the patient lives, the suture will be closed late and the head will be large.⁴ The exact mechanism for post-shunting craniosynostosis is unclear, but rapid decompression results in cranial plate collapse and overlapping of the sutures, and ultimate premature suture fusion and subsequent craniosynostosis with deformity.¹

Loop and Foltz followed the 111 patients who underwent ventriculoatrial (VA) shunting for hydrocephalus up to 4 years. They demonstrated that if the patients had more excessive skull circumference growth than normal before the surgery, were more likely that demonstrated the abnormal change after surgery. Moreover, they revealed that younger infants may tolerate skull enlargement, without subsequent post-operation skull change, provided shunting be performed early. They concluded that these changes occur after shunting in infants and has no association with the reason of hydrocephalus and number of revision surgery but in the setting of early shunting, (before cranium is larger), the likelihood of occurrence of these changes is low.⁵

Takahashi et al.⁶ reported two cases of shunt-induced craniosynostosis. One was an 8 year-old-boy presented by severe

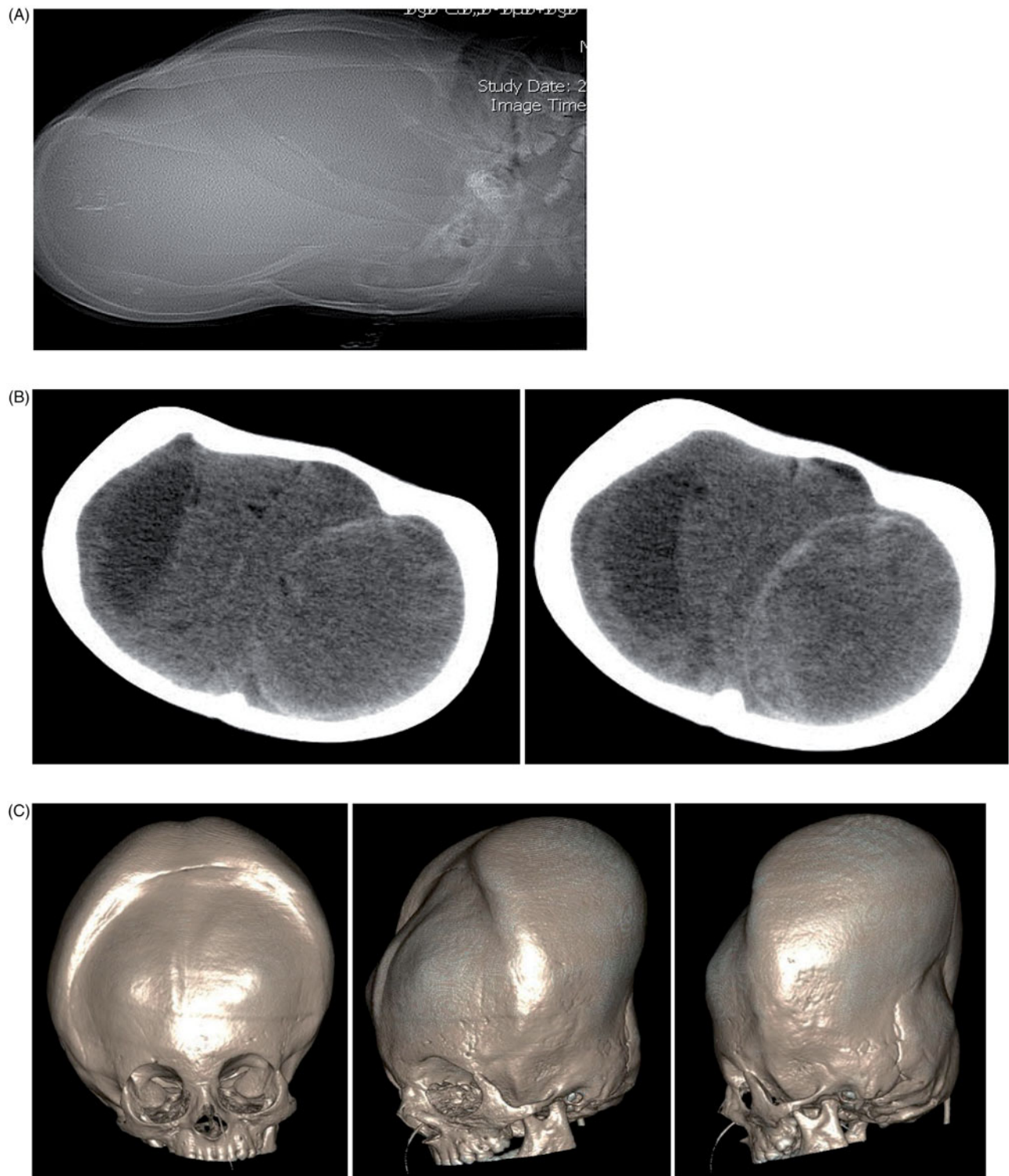


Figure 1. Brain CTscan; (A) scout view, (B) axial cut, and (C) 3D reconstruction demonstrated bizarre skull shape and deformity associated with mixed density change with the skull.

macrocephaly. He had a history of shunted hydrocephalus when he was 3 years old. He had a head circumference of 85 cm and massive frontal bossing. The second was a 3-year-old boy with a history of ventriculoperitoneal (VP) shunting at 1 month after birth. He had scaphocephaly with a head circumference of 54 cm. Both of them underwent reduction cranioplasty.

Golinko et al.⁷ presented 13 patients with cranial vault remodeling after shunt surgery. Seven of them had shunt-related craniosynostosis. They explained that although the exact mechanism

of this complication is unclear, it is probably at the results of excess cranial vault thickening (due to lack of brain tension over the dura and suture line). They concluded that aiming to prevent this side effect, in the case of shunt over drainage, programmable shunt or high-pressure differential pressure valve is preferable.

In a study by Roberts and Richham,⁸ 800 shunt operations were surveyed and 8 cases of post-surgery craniosynostosis were reported. After analysis, they explained that seven of them had a treatment delay of more than 2 weeks. All of them had a large

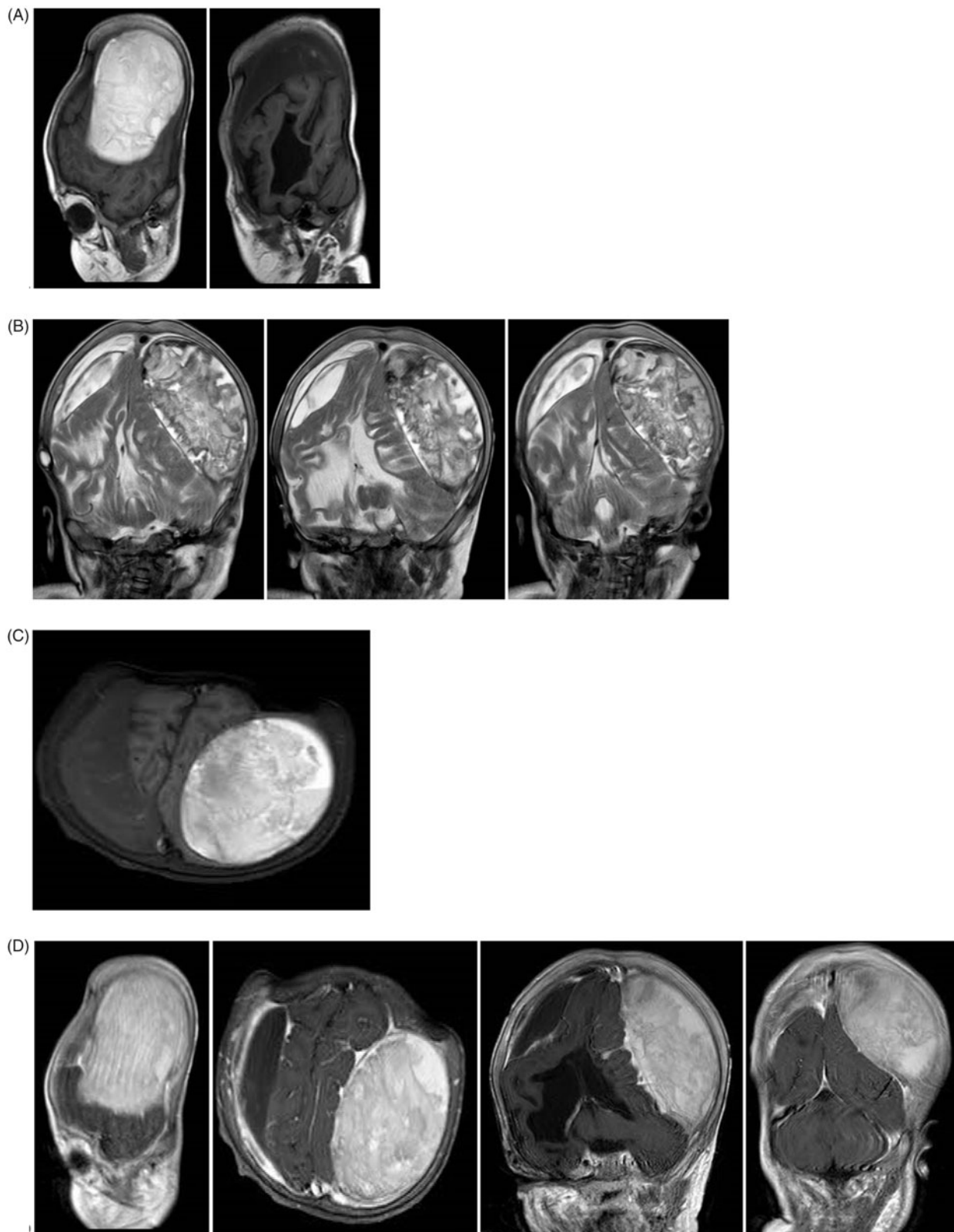


Figure 2. Brain MRI; (A) sagittal, (B) coronal, (C) axial, and (D) T1 after gadolinium injection image sequences reveal skull deformity and space occupying lesion.

head circumference. Despite using the medium pressure valve rather than low-pressure in all of the patients (aiming to avoid over drainage and subsequent craniosynostosis), the craniosynostosis occurred. Moreover, all of them had a rapid diminish in head circumference after surgery.

Andersson reported three cases of early craniosynostosis following VA shunting. One case demonstrated scaphocephaly 6 months after shunting, and another showed multisuture craniosynostosis 5 months later. Aiming to prevent of craniosynostosis, he did not use low-pressure valve shunt after this report.⁴

Our case was shunted at the age of 3 months. He had hydrocephalus from the neonatal period of unknown cause. It appears that shunting was done too late when the head had already reached a large size. After surgery, the widened sutures collapsed with an overlap of calvarial plates, synostosis, and deformity.

The difference between our case and the other reported cases is that in other cases shunt-induced craniosynostosis resulted in a skull deformity similar to those of primary craniosynostosis such as scaphocephaly or brachycephaly and the main problem caused is microcephaly, not macrocephaly.⁹ But in our case, the deformity was macrocephaly. This macrocephaly meant the large size and heavyweight of the skull interfered with mobility. The large dead space within the skull predisposes to the hematoma formations. Also, the deformity had significant cosmetic consequences. We believe this may have been seen in the early days of shunt surgery but that was before the era of modern imaging.

We believe that child neglect or low socioeconomic status are risk factors that may contribute to similar scenarios.

Conclusion

Shunt-induced craniosynostosis is rarely seen nowadays thanks to early detection and treatment of infantile hydrocephalus. But in the setting of child neglect or low socioeconomic culture, it can occur.

Disclosure statement

The authors have declared that no competing interests exist.

ORCID

Morteza Taheri  <http://orcid.org/0000-0001-5308-8040>

References

1. Bhadkamkar MA, Albright SB, Wolfswinkel EM, Bollo R, Buchanan EP. Posterior cranial vault distraction in the treatment of shunt-induced craniosynostosis. *J Craniofac Surg* 2015;26:e70–72.
2. Ghizoni E, Denadai R, Raposo-Amaral CA, Joaquim AF, Tedeschi H, Raposo-Amaral CE. Diagnosis of infant synostotic and nonsynostotic cranial deformities: a review for pediatricians. *Rev Paul Pediatr* 2016;34:495–502.
3. Schendel SA, Shuer LM. Multiple-suture synostosis subsequent to ventricular shunting. *Plast Reconstr Surg* 1994;93:1073–7.
4. Andersson H. Craniosynostosis as a complication after operation for hydrocephalus. *Acta Pzdiatrica Scand* 1966;55:192–6.
5. Loop JW, Foltz EL. Craniostenosis and diploic lamination following operation for hydrocephalus. *Acta Radiol Diagn (Stockh)* 1972;13:8–13.
6. Takahashi Y, Tajima Y, Okura A, Tokutomi T, Shigemori M, Kiyokawa K. Reduction cranioplasty for macrocephaly. Two case reports. *Neurol Med Chir (Tokyo)* 1999;39:459–62.
7. Golinko MS, Atwood DN, Ocal E. Surgical management of craniosynostosis in the setting of a ventricular shunt: a case series and treatment algorithm. *Childs Nerv Syst* 2018;34:517–25.
8. Roberts JR, Rickham PP. Craniostenosis following Holter valve operation. *Dev Med Child Neurol Suppl* 2008;12:145–9.
9. Mander M. Secondary craniosynostoses. In: Di Rocco C, Pang D, Rutka JT, eds. *Textbook of pediatric neurosurgery*. Cham: Springer International Publishing; 2017:1–11.