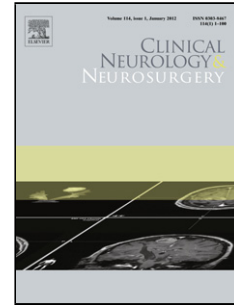


Journal Pre-proof

Pure word deafness revealing ischemic stroke in a Tunisian patient

Thouraya Ben Younes, Mariem Messelmani, Malek Mansour, Jamel Zaouali, Ridha Mrissa



PII: S0303-8467(19)30337-3

DOI: <https://doi.org/10.1016/j.clineuro.2019.105541>

Reference: CLINEU 105541

To appear in: *Clinical Neurology and Neurosurgery*

Received Date: 13 November 2018

Accepted Date: 28 September 2019

Please cite this article as: Younes TB, Messelmani M, Mansour M, Zaouali J, Mrissa R, Pure word deafness revealing ischemic stroke in a Tunisian patient, *Clinical Neurology and Neurosurgery* (2019), doi: <https://doi.org/10.1016/j.clineuro.2019.105541>

This is a PDF file of an article that has undergone enhancements after acceptance, such as the addition of a cover page and metadata, and formatting for readability, but it is not yet the definitive version of record. This version will undergo additional copyediting, typesetting and review before it is published in its final form, but we are providing this version to give early visibility of the article. Please note that, during the production process, errors may be discovered which could affect the content, and all legal disclaimers that apply to the journal pertain.

© 2019 Published by Elsevier.

Title: Pure word deafness revealing ischemic stroke in a Tunisian patient

Thouraya Ben Younes; Mariem Messelmani; Malek Mansour;Jamel Zaouali; Ridha Mrissa

Corresponding Author: Dr. Thouraya Ben Younes,

National Institute Mongi Ben Hmida of Neurology of Tunis

Highlights

- Pure word deafness (PWD) is a rare neurological disorder which refers to the inability to understand spoken language in absence of any other linguistic disturbance.
- The etiology is usually attributed to cerebrovascular accidents.
- PWD differs from auditory agnosia and from cortical deafness.

Keywords

Pure word deafness, ischemic stroke, temporal cortex

1. Introduction

Pure word deafness (PWD) is a very rare condition which refers to the inability to understand spoken language in absence of any other linguistic disturbance. Patients with PWD are perfectly able to speak, write and read. However, they present with an impairment of auditory comprehension [1]. The etiology is usually attributed to cerebrovascular accidents [2].

We report herein a case of a left-handed man who developed PWD revealing bilateral Ischemic stroke.

2. Case report

A 49 year-old left-handed man, arabic native speaker, was referred to our department of neurology on Jun 2016 for sudden onset difficulties understanding words. His family history was unremarkable. He had no prior medical history. The patient was a user of neither alcohol nor illicit drugs.

One week before his consultation, he presented two transient episodes of prosopagnosia and phonemic paraphasia.

On admission, he said that he heard words but could not understand them. The lip reading helped him a lot. On examination, he had a semantic and phonemic aphasia. He was unable to comprehend words. Speech was fluent and grammatically correct. The patient was able to recognize the national anthem, the usual noises and sounds (noise of a truck, song of the birds). He could also recognize a famous song from his tone but without being able to identify his words. Writing and reading were preserved. There was defective writing to dictation and inability to repeat speech. He had neither motor deficit nor disturbance of tactile and thermo-algic sensitivity nor coordination disorder. Osteotendinous reflexes were normal. He had not homonymous lateral hemianopsia.

The rest of the physical examination was unremarkable, in particular no arterial hypertension nor rhythm disorder nor heart or carotid murmur. The otoscopic examination was normal.

A brain Computed Tomography showed lesions of old ischemic stroke in the territory of the left posterior and middle cerebral artery and a recent right sylvian artery stroke (Figure 1). Further exploration by brain Magnetic Resonance Imaging (MRI) revealed the same stroke lesions. The MRI of the supra-aortic trunks showed neither cervical artery dissection nor stenosis. The cardiac ultrasound and the rhythmic holter were normal.

Routine biological tests were normal. The assay of protein S was abnormal (60%, normal values: 75-146%). The search for factor II, V and Methylenetetrahydrofolate reductase (MTHFR) mutation was negative. An immunological assessment (antinuclear, anti DNA, anti-neutrophil cytoplasmic, anticardiolipin, antiphospholipid, and anti-endothelial antibodies) was negative. Homocystein, folic acid and vitamin B12 levels were normal. Serologies for human immunodeficiency virus, hepatitis B and C viruses and syphilis in blood were all negative.

The patient was treated by oral anticoagulant (Acenocoumarol). The evolution was marked by the stability of symptoms. At three-month follow up, he presented a significant improvement in the comprehension of spoken language. On December 2017, 18 months after onset, he developed generalized seizures. He was treated by Levetiracetam without recurrence of seizures.

3. Discussion

We report an additional case of an isolated loss of the ability to recognize words that conforms to pure word deafness caused by a bilateral temporal ischemic stroke.

Pure word deafness is a rare neurological disorder which is defined by a selective deficit in comprehending spoken words, while the identification of nonverbal sounds remains intact [1]. It is one of the most disabling cortical hearing disorders. Individuals with PWD had selective damage to speech input processing and intact reading comprehension, speech and writing [1, 2]. Hallmarks that dissociate PWD from aphasia are the ability to understand written language and the intact expressive language function, including spoken as well as written language [1]. However, PWD is often accompanied by some degree of aphasic symptoms [3]. Our patient had semantic and phonemic paraphasia.

PWD differs from auditory agnosia, which designates intact auditory acuity without the ability to comprehend verbal and nonverbal auditory stimuli, or from cortical deafness which refers to

apparent unawareness of auditory stimuli combined with abnormal pure tone threshold with absence of brainstem or peripheral damage [4].

The brain damage that causes PWD generally involves unilateral lesions of the Heschl's gyrus in the dominant hemisphere or bilateral lesions of the temporal lobe and rarely at the subcortical or brainstem levels like bilateral lesions of the inferior colliculi [2]. PWD is most frequently associated with cerebrovascular accidents, such as the case of our patient. However, it was observed in individuals with arteriovenous malformation, intracranial tumors, central pontine myelinolysis, neurodegenerative disease, multiple sclerosis, paraneoplastic and infectious encephalitis [2, 4].

Given that our patient is left-handed, he did not manifest verbal deafness after his first stroke affecting the left temporal lobe. It was only when he had a second stroke affecting the right temporal lobe that he presented with verbal deafness. This shows that bilateral lesions of the superior temporal cortex cause PWD and probably his major hemisphere is the right one.

Various types of neurophysiological tests such as auditory brainstem response (ABR) and middle latency auditory-evoked responses (MLR) are used in case of PWD. Patients with PWD generally had normal thresholds in the pure tone audiometry, severe abnormality in speech audiometry, and normal ABR. The MLR shows normal or abnormal responses [5].

4. Conclusion

PWD is a rare condition which differs from cortical deafness and auditory agnosia. It is characterized by severely impaired speech perception despite good hearing ability and preserved functioning in other domains of language. It is usually attributed to cerebrovascular accidents.

References

- [1] Gutschalk A, Uppenkamp S, Riedel B, Bartsch A, Brandt T, Vogt-Schaden M. Pure word deafness with auditory object agnosia after bilateral lesion of the superior temporal sulcus. *Cortex*. 2015;73:24-35.
- [2] Maffei C, Capasso R, Cazzolli G, Colosimo C, Dell'Acqua F, Piludu F, et al. Pure word deafness following left temporal damage: Behavioral and neuroanatomical evidence from a new case. *Cortex*. 2017;97:240-54.
- [3] Verma A, Post JD. Reversible Pure Word Deafness. *JAMA Neurol*. 2013;70(11):1454-5.
- [4] Bervini D, Oxenham V, Morgan MK. Pure word deafness after resection of a Vein of Galen aneurysm and arteriovenous malformation: Report of a case. *Clin Neurol Neurosurg*. 2014;123:146.
- [5] Hayashi K, Hayashi R. Pure word deafness due to left subcortical lesion: neurophysiological studies of two patients. *Clin Neurophysiol*. 2007;118(4):863-8.

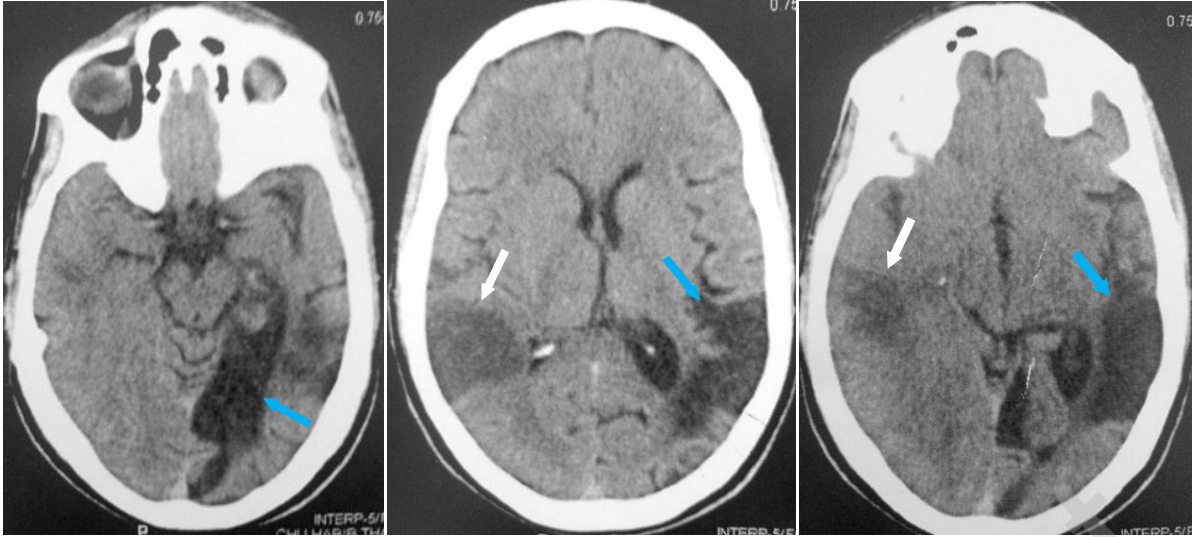


Figure 1: Brain Computed Tomography showing lesions of old ischemic stroke in the territory of the left posterior and middle cerebral artery (blue arrow) and a recent right middle cerebral artery stroke (white arrow).